

## Original Research Article

# Evaluation of effectiveness of Ponseti's method in the clubfoot management under 1-year children: a prospective study

Prateek Girotra, K. Prashanth Kumar\*, Rejo Varghese Jacob

Department of Orthopedics, Hindu Rao Hospital and NDMC Medical College, Delhi, India

**Received:** 09 December 2020

**Revised:** 20 December 2020

**Accepted:** 23 December 2020

### \*Correspondence:

Dr. K. Prashanth Kumar,

E-mail: [drprashanthkumarkokkula@gmail.com](mailto:drprashanthkumarkokkula@gmail.com)

**Copyright:** © the author(s), publisher and licensee Medip Academy. This is an open-access article distributed under the terms of the Creative Commons Attribution Non-Commercial License, which permits unrestricted non-commercial use, distribution, and reproduction in any medium, provided the original work is properly cited.

## ABSTRACT

**Background:** Congenital talipes equino Varus is common congenital orthopedic foot deformity in children characterized by hindfootequinus, hind foot varus, midfoot cavus, and forefoot adduction deformities. There is a necessity to analyze the number of casts employed in the treatment, compliance of bracing, relapse pattern and percentages of surgical referral under 1 year of age for clear understanding and better practice to achieve successful outcomes. This study aimed to judge the effectiveness of Ponseti in the treatment of clubfoot under 1-year old children.

**Methods:** The patients were selected in the OPD and evaluated for virgin idiopathic clubfoot under 1-year age. Serial casting done weekly by Ponseti method after assessing Pirani and Demeglio score before every cast.

**Results:** In our study all 29 clubfeet that were treated by Ponseti method showed complete correction. Minimum cast being 5 and maximum being 10 casts. Corrected feet were supple, plantigrade and painless of which 1 foot had relapse < 3 weeks due to ill-fitting shoes. Which was subsequently corrected with repeat tenotomy and cast application.

**Conclusions:** The Ponseti method is a safe, effective, cheap and reproducible method for correction of CTEV which significantly reduces the rate of extensive corrective surgeries for correction of clubfoot under 1-year age. For successful outcome and to prevent relapse, this technique must be applied strictly in accordance to the protocol and parents must be taught the importance of full compliance with bracing. Our series has a short follow up. Longer follow-up is needed for further evaluation of effectiveness of Ponseti method.

**Keywords:** Ponseti method, CTEV, Serial casting, Tenotomy, Bracing

## INTRODUCTION

Idiopathic clubfoot is a complex musculoskeletal deformity occurring in an otherwise normal child. Although most cases are sporadic occurrences, families have been reported with clubfoot presenting as an autosomal dominant trait with incomplete penetrance. It is seen more commonly in males and is bilateral in about 50% of the cases.<sup>1</sup> Most orthopaedic surgeons agree that the initial treatment of congenital clubfoot should be nonoperative and should be instituted as soon as possible after birth, so as to utilise advantage of the favorable fibroelastic properties of the connective tissues that forms

the ligaments, joint capsules and tendons. Many different methods of nonsurgical treatment are being used with success rates from 15 to 90%, but still there is no consistency of results about the percentage of patients who can be corrected nonoperatively.

Although Ponseti's method of treatment has been there for around 50 years it has aroused interest only in the recent past after the long-term results of this method were published. In a 34 year follow-up of patients treated by Ponseti's method Cooper and Dietz reported 78% good to excellent results.<sup>2</sup> Ponseti following his landmark work argued that an essentially conservative treatment should be

definite in 85 to 90% of cases of idiopathic clubfoot.<sup>2</sup> He believed that the operative management had been popular just due to the lack of understanding of the pathoanatomy of clubfoot. He said that the tarsal joints are mechanically interrelated and calcaneus has to be abducted from under the talus in order to evert it. He, considering the pathoanatomy of clubfoot, advised to use head of talus as a fulcrum during manipulation and pointed out that abducting the foot at the midtarsal joints with thumb pressing on the lateral side of the foot near calcaneocuboid joint as taught by Kite was a major error<sup>12</sup>.

He also stated that French taping method is very lengthy and expensive. Ponseti method of treatment of clubfoot is gaining popularity worldwide but its efficacy is yet to be established. This study is being undertaken to evaluate clinically effectiveness of Ponseti method in the management of clubfoot under 1-year age.

## METHODS

This study was conducted in the Department of orthopaedics between September 2018 to August 2019.

A total of 29 feet of 20 patients were included in the study between the ages of 0 to 1 year of age.

### Selection of cases

Children with untreated idiopathic clubfoot of age less than 1 year at the time of presentation were included in the study. A thorough clinical examination was done to exclude all cases of secondary clubfoot.

### Type of study design

Prospective observational study

### Pretreatment workup

Patients were worked up thoroughly; a detailed history was taken regarding the onset of deformity, other associated deformity, family history of similar deformity and history of treatment. A general examination was done to detect any other associated congenital anomaly.

### Clinical assessment

Quantification of various components of clubfoot deformity using the Dimeglio score and Pirani score.<sup>7-10</sup>

### Treatment protocol

After selection of patient's, history and preliminary clinical examination done to rule out secondaries. Order of correction is Cavus- adduction, Varus- equinus (if tenotomy done). Pirani and Dimeglio score noted before every cast application. Cast changed every week. After satisfactory correction, foot abduction braces were applied until 3 years of age.

## Statistical analysis

Wilcoxon Signed Ranks Test is used to see the significance of the change of the clinical score between pre and post treatment values because distribution of the different parameters under pre and post treatment are not following a normal distribution.

For the clinical Dimeglio score there is very significant change from pre to post treatment of equinus parameter with a Z score of -4.903 and p value<0.001.

## RESULTS

### Age

Out of 20 patients, 11 were males and 9 were females. Age distribution of patients (Figure 1).

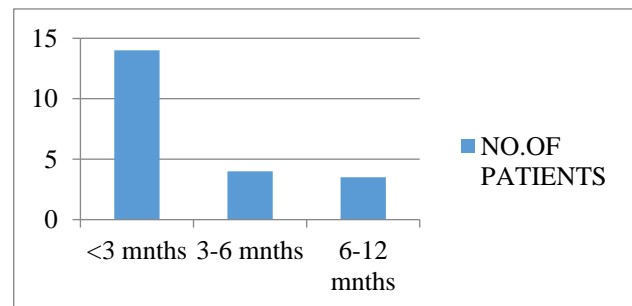


Figure 1: Age distribution of patients.

### Laterality

Among the 20 cases, 9 cases had bilateral clubfoot, and 11 cases had unilateral clubfoot out of which 18 were right-sided and 11 were left-sided.

### Consanguinity and family history

We found that 3 cases were born out of consanguineous marriages of parents and 5 cases had a positive family history of clubfoot.

### Pirani score

In our study Pirani scoring was done for each of the 6 components viz; lateral border, medial crease, palpation of head of talus, posterior crease, emptiness of heel and equines. Total no. of feet=29

Clinical results show in Figure 2.

Minimum number and maximum number of cast required for correction deformity (Figure 3)

For lateral border minimum no. cast required was 2 and maximum was 6, For medial crease minimum no. cast required was 3 and maximum was 10, head of talus minimum no. cast required was 4 and maximum was

9,Posterior crease minimum no. cast required was 5 and maximum was 10, emptiness of heel minimum no. cast required was 5 and maximum was 10, equinus minimum no. cast required was 5 and maximum was 9.

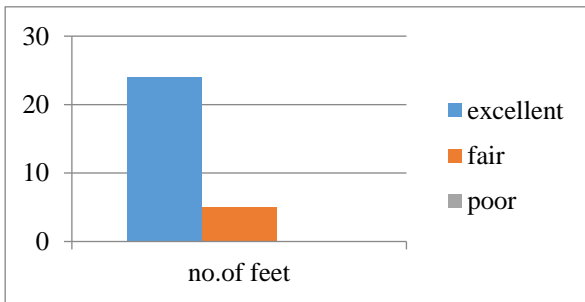


Figure 2: Clinical results.

**Dimeglio score**

1) for the pretreatment data (number of feet=29). Distribution of patients in various Dimeglio score (Table 1) 2) for the posttreatment data (number of feet=29).

Table 1: Distribution of patients in various Dimeglio score.

Clinical angle	Score	No. of feet	Percentage
≥20	0	0	0
20 to 0	1	0	0
0 to 20	2	6	20.6
20 to 45	3	18	62
45-90	4	5	17.2

**Clinical score**

Distribution of patients in various Dimeglio score (Table 2).

Table 2: Distribution of patients in various Dimeglio score.

Clinical angle	Score	No. of feet	Percentage
≥20	0	4	13.9
20 to 0	1	25	86.2
0 to 20	2	0	0
20 to 45	3	0	0
45-90	4	0	0

**Tenotomy**

In our study we performed percutaneous tenotomy of tendoachilles in 72% of cases after correction of other components of clubfoot in order to achieve dorsiflexion upto or beyond 15 degrees. This is comparable with Ponseti's work where percutaneous tenotomy of

tendoachilles is done in nearly 70% of cases after correction of other components of clubfoot in order to achieve dorsiflexion upto or beyond 15 degrees

**Replase**

Out of 20 patients with 29 club feet, 1 patient with unilateral clubfoot developed relapse of equinus within 4 weeks of application of foot abduction brace. On careful examination it was found that their heels were getting lifted inside the shoes, probably because shoes were ill-fitting & were of slightly large size allowing the heel to get lifted up inside the shoes. They were treated with repeat percutaneous tenotomy of tendoachilles and corrective casts were given in 15 degree of dorsiflexion for 3 weeks. Equinus got corrected and a well fitted foot abduction braces were given.

**Complications**

Out of 29 feet, 5 patients had redness of skin due to pressure, 3 patients had slight swelling of toes, 1 patient had erythema and 1 patient had cast spillage (Figure 4).

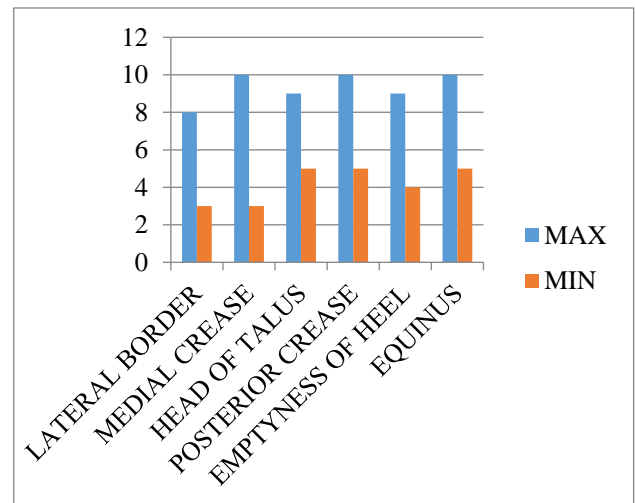


Figure 3: Distribution of patients in various Dimeglio score.

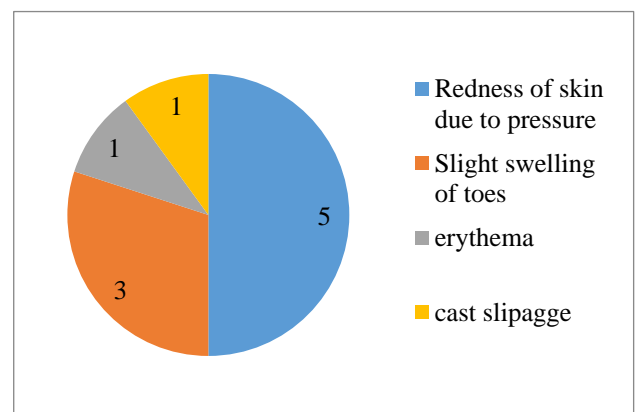
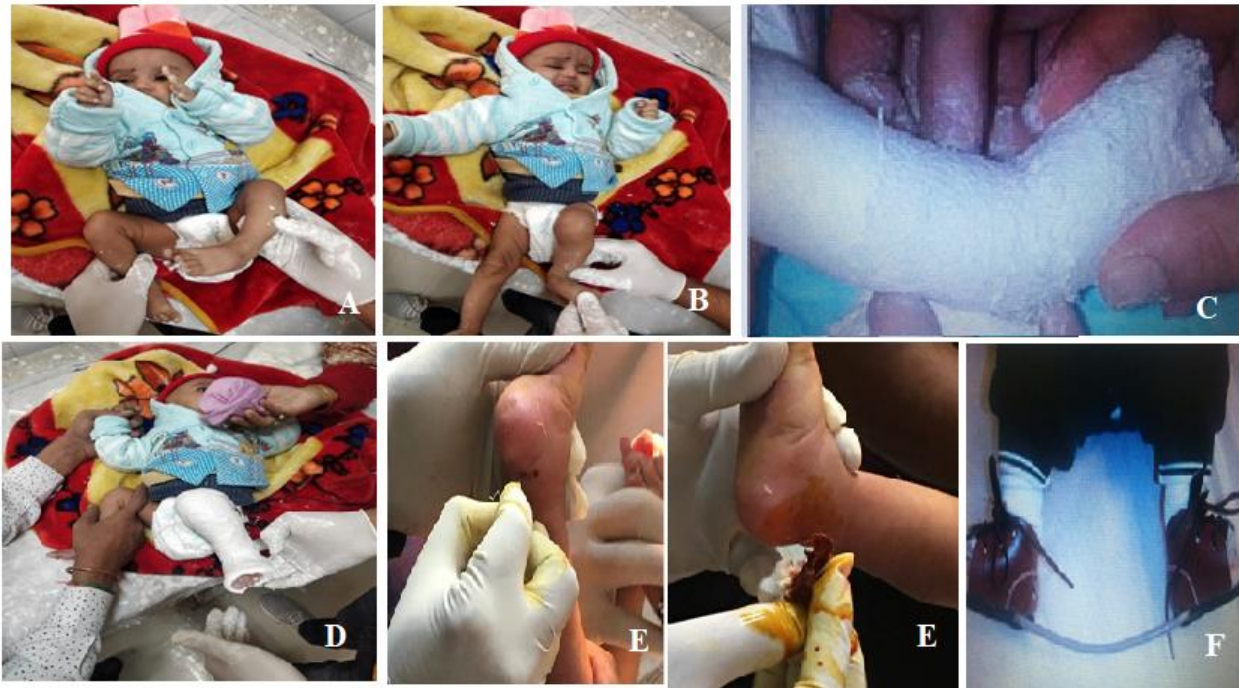


Figure 4: Complications.



**Figure 5: (A) On clinical examination (B) on manipulation, correction of total deformity (C) 1st step: cavus correction by pop by (D) 2nd step: correction of forefoot adduction and varus (E) tenotomy done if desirable equinus not corrected (F) dennis brown splinting after post correction.**

## DISCUSSION

This study was conducted to evaluate Ponseti method in the management of clubfoot which recently has gained popularity worldwide. Corrections of deformities were evaluated clinically using Dimeglio and Pirani score.<sup>7-10</sup>

In our study, 20 patients with 29 virgin idiopathic clubfeet between the age group of 0-1yr were included to take advantage of the favorable fibroelastic properties of the connective tissues that forms the ligaments, joint capsules and tendons.<sup>2</sup> Maximum number of cases (70 %) were between 0 to 3 months. We observed that males (55%) were more commonly involved than females (45%) as mentioned in the literature. Kite in his series of 1509 cases has reported 70% males and 30% females. In Turco's series of 468 patients, there were 334 (71.3%) males and 134 (28.6%) females.<sup>11,12</sup> There were about 45% bilateral cases in our study. Chung observed a 50% bilaterality. Turco's series of 468 patients had 56% bilaterality.<sup>12,13</sup> In our study, 35% cases had right sided involvement and 32.5% cases had left sided involvement which corresponds somewhat to Turco's series which had a similar profile.<sup>12</sup> Average number of casts: plasters were applied according to the Ponseti regimen. The average number of casts were 5.7 with an average of 1.5 months of duration of casting. Stephen MD has reported an average of 2.5 months of treatment in his series of 37 patients. In our study also minimum 5 plasters were required to achieve correction, but some feet which were more deformed at the start of treatment took few more plasters, up to a maximum of 10 plasters to achieve correction which is consistent with the

results reported in the literature by Ponseti.<sup>2-6</sup> As per Ponseti it takes 5-6 Plaster on an average to correct the deformity in virgin idiopathic clubfeet by his method of plaster treatment and few more in more deformed club foot.<sup>2-6</sup> Tenotomy: Ponseti reported performing Tenotomy in about 85% of his patients.<sup>2-6</sup> Of the total number of cases done in our study, 72% of the involved feet underwent Tenotomy (21 out of 29 feet).

Current study also shows that patients with comparatively lower Pirani scores (mean 4.8) and who present early (mean 14.4 days) are associated with lower incidences of percutaneous tenotomy. At the time of Tenotomy, no significant bleeding was noted and no blood staining of the cast occurred. There were no cases of infection

Our study agrees with the findings of Sharma et al who suggested that those feet presenting with a Pirani score of more than 5 are highly likely to need an Achilles Tenotomy.<sup>14</sup> Pirani 6-point score: Pirani 6-point scoring was done after removal of every consecutive corrective cast. It is an important parameter used as a road map in the evaluation of trend and direction of treatment. It is further classified into forefoot score represented by lateral border, medial crease and palpation of head of talus, and hindfoot score represented by posterior crease, emptiness of heel and equinus. Each component carries a maximum score of 1 and can be graded as score 0, 0.5, or 1.

In our study Pirani scoring was done for each of the 6 components viz; lateral border, medial crease, palpation of head of talus, posterior crease, emptiness of heel and

equinus. Total no. of feet=29. when at least 15° dorsiflexion was achieved with or without percutaneous tenotomy of tendoachillis and with foot in 70° abduction, the foot was labelled as corrected and FAB given.

No. of plasters required to achieve desired correction in each component of deformity of clubfoot (Figure 3).

In one patient even after achievement of 15° of dorsiflexion and clinical correction of cavus, it was difficult to palpate the tuberosity of calcaneum (Pirani score=0.5 for emptiness of heel) and had a partially correction.

Another patient had 1 deep posterior crease not affecting contour of the heel (Pirani score=0.5 for posterior crease) but the foot was considered corrected after achievement of 15° of dorsiflexion in that patient.

#### **Evaluation of various components of deformities in clubfoot**

##### *Evaluation of equinus component*

Max. No of cases i.e 18 had score 3 for equinus deformity 20- <45.

Post treatment all patients achieved correction of equinus. 20 feet dorsiflexion 0 to -20 (dimeglio score=1), While 9 feet achieved dorsiflexion beyond 20 (dimeglio score=0). Max no. of cases had dimeglio score=1 for equinus i.e equinus deformity was correctable between 0 to -20

##### *Evaluation of varus component*

Max no of cases had score 2 for varus component 0-200. posttreatment had score of 1 in 20 patients and score 0 in 9 patients.

##### *Evaluation of adduction deformity component*

Total 27 patients had score 2 before treatment after treatment 15 patients had score 1 and 14 had score 0.

##### *Evaluation of cavus deformity component*

Pre-treatment 29 feet had cavus, score 1, post treatment no feet had cavus, score 0

For the clinical dimeglio score there is significant change from pre to post treatment of equinus, varus, adduction, cavus parameters with Z score of -4.90 and p value<0.001.

Thus, with ponseti method, there is good correction of equinus, varus, adduction and cavus clinically.

#### **Limitations**

Our series has a short follow up. Longer follow-up is needed for further evaluation of effectiveness of ponseti method.

#### **CONCLUSION**

The Ponseti method is a safe, effective, cheap and reproducible method for correction of CTEV which significantly reduces the rate of extensive corrective surgeries for correction of clubfoot under 1-year age. For successful outcome and to prevent relapse, this technique must be applied strictly in accordance to the protocol and parents must be taught the importance of full compliance with bracing.

*Funding: No funding sources*

*Conflict of interest: None declared*

*Ethical approval: The study was approved by the institutional ethics committee*

#### **REFERENCES**

1. Wallace B, Lehman. The clubfoot. J. B. Lippincott Company. 1980.
2. Ponseti IV. Current concepts review: Treatment of congenital clubfoot. J Bone Joint Surg. 1992;74-A:4
3. Ponseti IV, Smoley EN. Congenital clubfoot. The results of treatment. Bone Joint Surg. 1963;45A:261:48-454.
4. Ponseti IV. Common errors in the treatment of congenital clubfoot. Int Orthopaed. 21:137-141:1997.
5. Ponseti IV. Editorial, Clubfoot management. Pediatr Orthop. 20:699-700:2000.
6. Ponseti IV, Campos J. Observations on pathogenesis and treatment of congenital clubfoot. Clin Orth Rel Res. 1972;84:50-60.
7. Dimeglio A. Classification of talipes equinovarus. The Clubfoot. The present and a view of the future. Ed. Simons, G.W. Springer Verlag. 1994.
8. van Mulken JM, Bulstra SK, Hoefnagels NH. Evaluation of the treatment of clubfeet with the Dimeglio score. J Pediatr Orthop. 2001;21(5):642-7.
9. Pirani S. A method of evaluating the virgin clubfoot with substantial inter-observer reliability. Miami Florida. 1995.
10. Pirani, Pirani S, Outerbridge H, Moran M. A method of evaluating the virgin clubfoot with substantial interobserver reliability. Presented at the annual meeting of the Pediatric Orthopaedic Society of North America, Miami, Fla, 1995
11. Kite H. The classic. Principles involved in the treatment of congenital clubfoot. Clin Orth Rel Res. 1972;84:4-8.
12. Turco VJ. Club foot. Churchill Livingstone 1981.
13. Chung CS, Nemecek RW, Larsen IJ, Chung GHS. Genetic and epidemiological studies of clubfoot in Hawaii Human Heredity. 1969;19:321

14. Sharma A, Shukla S, Kiran B, Michail S, Agashe M. Can the Pirani Score Predict the Number of Casts and the Need for Tenotomy in the Management of Clubfoot by the Ponseti Method? *Malays Orthop J.* 2018;12(1):26-30.
15. McKay DW. New concept of an approach to clubfoot treatment: section III. *Evaluat Res Pediatr Ort.* 1983;41.
16. Heilig MR, Matern RV, Rosenzweig SD, Bennett JT. Current management of idiopathic clubfoot questionnaire: a multicentric study. *J Pediat Orthopaed.* 2003;23(6):780-7.
17. Richards BS, Johnston CE, Wilson H. Nonoperative clubfoot treatment using the French physical therapy method. *J Pediat Orthopaed.* 2005;25(1):98-102.
18. Simons GW. Complete subtalar release in club feet. Part II--Comparison with less extensive procedures. *J Bone Joint Surg.* 1985 Sep;67(7):1056-65.
19. Aronson J, Puskarich CL. Deformity and disability from treated clubfoot. *J Pediat Orthoped.* 1990;10(1):109-19.
20. Cooper DM, Dietz FR. Treatment of idiopathic clubfoot: A thirty-year follow-up note. *J Bone Joint Surg.* 1995;77:1477-89.
21. Laaveg SJ, Ponseti IV. Long-term results of treatment of congenital club foot. *J Bone Joint Surg.* 1980;62(1):23-31.
22. Fan H, Liu Y, Zhao L, Chu C, An Y, Wang T, et al. The correlation of Pirani and Dimeglio scoring systems for Ponseti management at different levels of deformity severity. *Scientif Rep.* 2017;7(1):1-8.
23. Gurzu S. Congenital Clubfoot in Children After Walking Age: Management and Evaluation of 41 Feet with the Dimeglio Score. *J Clin Diagn Res.* 2013
24. Jochymek J, Peterková T. Are scoring systems useful for predicting results of treatment for clubfoot using the ponseti method?. *Acta ortopedica brasileira.* 2019;27(1):8-11.
25. Hussain FN. The role of the Pirani scoring system in the management of club foot by the Ponseti method. *J Bone Joint Surg Br.* 2007;89-B(4):561.
26. Dyer PJ, Davis N. The role of the Pirani scoring system in the management of club foot by the Ponseti method. *J Bone Joint Surg.* 2006;88(8):1082-4.

**Cite this article as:** Girotra P, Kumar KP, Jacob RV. Evaluation of effectiveness of Ponseti's method in the clubfoot management under 1-year children: a prospective study. *Int J Res Orthop* 2021;7:228-33.