

Case Report

Bilateral floating knee: a rare case report with review of literature

Umesh Yadav^{1*}, Vasudha Dhupper², Jyotirmay Das¹, Akshay Lamba¹, Gaurav¹,
Kshitish Chandra Behera¹, Ashish Devgan¹, Naresh Kumar¹

¹Department of Orthopaedics, ²Department of Biochemistry, PGIMS, Rohtak, Haryana, India

Received: 14 April 2020

Accepted: 30 April 2020

***Correspondence:**

Dr. Umesh Yadav,

E-mail: drumeshyadav735@gmail.com

Copyright: © the author(s), publisher and licensee Medip Academy. This is an open-access article distributed under the terms of the Creative Commons Attribution Non-Commercial License, which permits unrestricted non-commercial use, distribution, and reproduction in any medium, provided the original work is properly cited.

ABSTRACT

Floating knee injuries are commonly seen nowadays due to increase in road traffic accidents. However, bilateral presentation of floating knee is a rare injury and challenging to orthopaedicians for a good functional outcome. We hereby present a rare case of bilateral floating knee injury in a 45 year old male treated with open reduction and internal fixation in a staged procedure. Functional assessment was done using modified Karlstrom-Olerud criteria which showed excellent outcome. Union was achieved in approximately 7 months. Decreased knee movements over left side as compared to right side was only complication seen.

Keywords: Floating knee, Trauma, Damage control orthopaedics

INTRODUCTION

Floating knee is defined as fractures of the ipsilateral femur and tibia ranging from simple diaphyseal to complex articular type.¹ Floating knee injuries (FKI) are associated with high-velocity mechanisms like road side accident, fall from height. Although exact incidence of a FKI is not known, they are relatively uncommon. They are usually associated with extensive soft tissue injuries and life threatening multiorgan injuries. With advancement of fracture fixation methods and operative technique management of FKI has improved over decades.^{2,3}

CASE REPORT

A 45 year old obese male, with no medical history, presented in emergency room with a closed trauma of the bilateral knee secondary to a traffic accident. He was hit by a car while biking. General examination revealed no other significant injury. On physical examination, the patient was totally unable to step on or move his both lower limb. There was a significant swelling around his both knees with no skin defect. Bilateral distal pulses were well

palpable. The capillary filling of the toes was present. No motor or sensitive defect was found. Plain radiograph revealed fracture of bilateral distal femur and proximal tibia. A diagnosis of bilateral floating knee was made and skeletal traction was given on both sides. As per protocol of damage control orthopaedics, surgical fixation was done in staged method, first on right side and then left side. Open reduction and internal fixation (ORIF) were done using lateral approach first on right side and after a week on left side under spinal anesthesia. Distal femoral locking plate was used for femur while proximal tibial locking plates were used for tibia in both sides. Post-operative plater pf Paris slab was used in both limbs. Post-operative radiographs showed a good reduction of the distal femur and proximal tibia. Knee movements were started time of post-operative day 3 at time of drain removal. Patient was in follow up at regular intervals at 2 weeks, 1 month, 3 months, 6 months and one year. On each follow up clinical and radiological assessment was done. Radiological assessment was done by X-ray to assess bony union. Functional assessment was done using modified Karlstrom and Olerud score after bony union was confirmed.⁴

Radiological union was seen in 7 months. Knee movements were good in right knee while knee stiffness was seen in left knee. No other complication like infection was seen.

Functional assessment was done using modified Karlstrom-Olerud criteria which showed excellent outcome. No angular deformity or shortening of the left lower limb was noted.

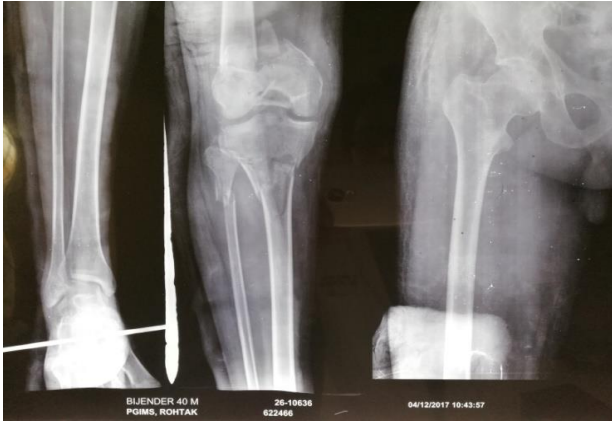


Figure 1: Preoperative X-rays.

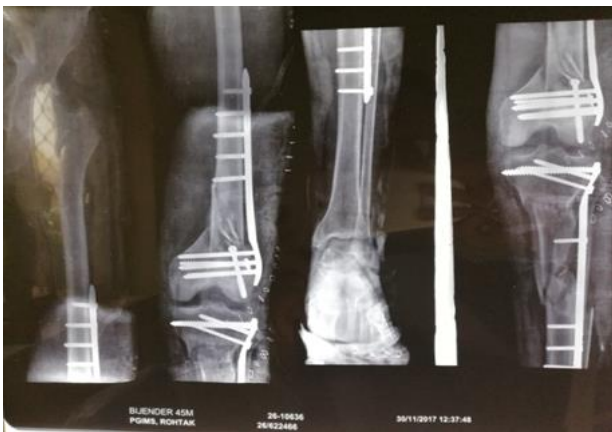

Figure 2: Immediate postoperative X-rays.

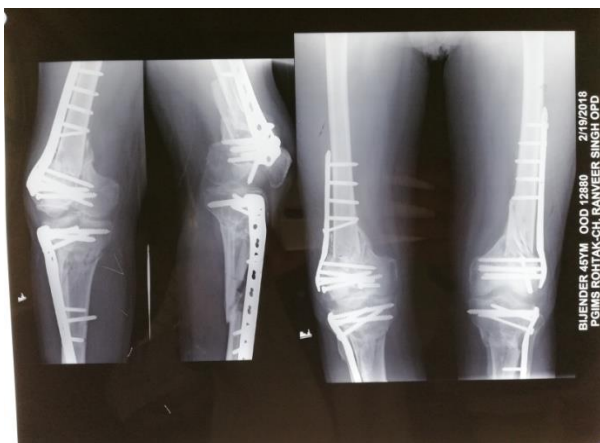

Figure 3: 3 months follow up with signs of healing.

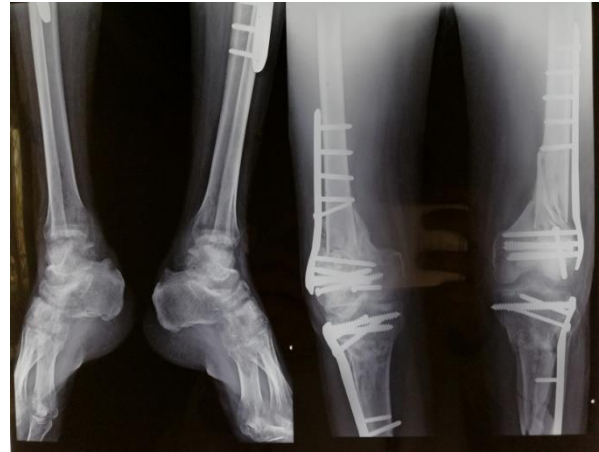

Figure 4: Final follow up at 7 months.

DISCUSSION

Although floating knee injury with is a rare injury but increasing population and rise in motor vehicles, there is a rise in incidence of these injuries. Management protocol for these patients involves haemodynamic stabilisation followed by surgical fixation. Following the principles of damage control orthopaedics, overall patient stabilization is priority and skeletal stabilization is done by fixators at first and final definitive fixation is to be done once patient is stable.⁵

Rethnam et al treated FKI injuries with intramedullary nail for most of extraarticular fracture and plate for most of intraarticular fracture, and found the fracture union time and functional recovery was better in those patient which were treated with intramedullary nail.⁶ Theodoratus et al in their study recommended intramedullary nail as method of choice for treatment of ipsilateral diaphyseal tibia and femur fracture except open grade 3b and c fracture.⁷ Dwyer et al compare four treatment modalities to fix FKI and concluded that excellent to good result were obtained when shaft femur and tibia fracture were treated with intramedullary nail or combined modality (intramedullary nail for femur fracture and cast brace for tibia fracture), and poor result when both fracture treated with external fixator. The incidence of amputation was reported up to 27% in FKI which had massive soft tissue crushing, severe infection and neurovascular injuries.⁸

Knee stiffness remains the main complication after treatment. Decreased range of motion and diffuse pain persists years after treatment and fracture healing. Although early range of motion and knee physiotherapy can somehow decrease the knee stiffness but final outcome is still unpredictable. Although soft tissue damage, type of fracture may affect the functional outcome but final results are totally variable in literature. Manipulation under general anaesthesia remains the next treatment option. Complications related to union are also frequently common in floating knee injuries. Malunion (17%) was main problem in study conducted by Kulkarni et al while

delayed union was a complication mainly noted in study conducted by Yadav et al.⁹⁻¹¹ In our case also, knee stiffness was seen as only complication that too on one side.

The functional assessment after treatment of floating knee injuries is evaluated by most authors using the Karlström and Olerud grading system. In order to simplify it, most surgeons consider a satisfactory outcome as those cases with excellent or good results, and an unsatisfactory outcome as those with just acceptable or poor results. By using these criteria, most series described excellent and good results (86% by Karlström et al, 72% by Veith et al, 81% by Anastopoulos et al and 65% by Gregory et al).¹²⁻¹⁴ Present case also showed excellent functional outcome.

CONCLUSION

The simultaneous occurrence of ipsilateral fractures of the femur and tibia causes isolation of the knee joint from the rest of the lower limb skeleton called “floating knee”. It is an extremely serious injury, causing immediate local and general complications that can result in death of the patient in the short term. A multidisciplinary approach is essential for management of these injuries including hemodynamic stabilization. Bilateral occurrence of these types of injuries is extremely rare and underreported in literature.

Funding: No funding sources

Conflict of interest: None declared

Ethical approval: Not required

REFERENCES

1. Blake R, McBryde A Jr. The floating knee: ipsilateral fractures of the tibia and femur. *South Med J*. 1975;68:13-6.
2. Kao FC, Tu YK, Hsu KY, Su JY, Yen CY, Chou MC. Floating knee injuries: a high complication rate. *Orthopedics*. 2010;33(1):14.
3. Rethnam U, Yesupalan RS, Nair R. The floating knee: epidemiology, prognostic indicators & outcome following surgical management. *J Trauma Manag Outcomes*. 2007;1(1):2.
4. Karlström G, Olerud S. Ipsilateral fracture of the femur and tibia. *J Bone Joint Surg Am*. 1977;59(2):240-3.
5. Vallier HA, Super DM, Moore TA, Wilber JH. Do patients with multiple system injury benefit from early fixation of unstable axial fractures? The effects of timing of surgery on initial hospital course. *J Orthop Trauma*. 2013;27(7):405-15.
6. Rethnam U, Yesupalan RS, Nair R. Impact of associated injuries in the floating knee: aretrospective study. *BMC Musculoskelet Disord*. 2009;10:7.
7. Theodoratos G, Papanikolaou A, Apergis E, Maris J. Simultaneous ipsilateral diaphyseal fractures of the femur and tibia: treatment and complications. *Injury*. 2001;32(4):313-5.
8. Dwyer AJ, Paul R, Mam MK, Kumar A, Gosselin RA. Floating knee injuries: long-term results of four treatment methods. *Int Orthop*. 2005;29(5):314-8.
9. Feron JM, Bonnevalle P, Pietu G, Jacquotl F. Traumatic floating knee: A review of a multi-centric series of 172 cases in adult. *Open Orthop J*. 2015;1:356-60.
10. Kulkarni MS et al. Variables affecting functional outcome in floating knee injuries. *Injury*. 2018;49;8:1594-601.
11. Yadav V, Suri HS, Vijayvargiya M, Agashe V, Shetty V. "Floating knee," an Uncommon Injury: Analysis of 12 Cases. *Rev Bras Ortop (Sao Paulo)*. 2019;54(1):53-9.
12. Rethnam U, Yesupalan RS, Nair R. The floating knee: epidemiology, prognostic indicators & outcome following surgical management. *J Trauma Manag Outcomes*. 2007;1:2.
13. Ran T, Hua X, Zhenyu Z, Yue L, Youhua W, Yi C, et al. Floating knee: a modified Fraser's classification and the results of a series of 28 cases. *Injury*. 2013;44:1033-42.
14. Nouraei MH, Hosseini A, Zarezadeh A, Zahiri M. Floating knee injuries: results of treatment and outcomes. *J Res Med Sci*. 2013;18:1087-91.

Cite this article as: Yadav U, Dhupper V, Das J, Lamba A, Gaurav, Behera KC, et al. Bilateral floating knee: a rare case report with review of literature. *Int J Res Orthop* 2020;6:851-3.