

## Original Research Article

# Outcome analysis of patients with proximal humerus fractures treated with locking plates

Ritesh Kumar<sup>1</sup>, S. Natarajan<sup>2\*</sup>, Sanjeev Kumar<sup>1</sup>, R. Kalanithi<sup>2</sup>

Department of Orthopedics, <sup>1</sup>Hindu Rao Hospital, Malka Ganj, Delhi, India; <sup>2</sup>Saveetha Medical College and Hospital, Kanchipuram District, Tamil Nadu, India

**Received:** 24 March 2017

**Revised:** 01 April 2017

**Accepted:** 15 April 2017

**\*Correspondence:**

Dr. S. Natarajan,  
E-mail: drsnats@gmail.com

**Copyright:** © the author(s), publisher and licensee Medip Academy. This is an open-access article distributed under the terms of the Creative Commons Attribution Non-Commercial License, which permits unrestricted non-commercial use, distribution, and reproduction in any medium, provided the original work is properly cited.

### ABSTRACT

**Background:** Fracture of proximal humerus incidence has been reported to be 73 cases per 100,000 individuals per year. There are different methods of treatment of proximal humeral fractures. The aim of our study is to analyse the functional outcome of proximal humerus fractures treated with proximal humerus locking plates and to analyse the possible benefits and complications of the procedure.

**Methods:** This is a retrospective study of 34 patients with proximal humeral fractures treated with ORIF using Proximal humeral locking plates from October 2010 to November 2012 at Saifee Hospital, Mumbai. The cases are evaluated as regards to functional outcome using constant score, fracture healing clinically, radiologically and complications if any and reason for them.

**Results:** Our study shows that proximal humerus fractures are now increasingly seen in younger population with good bone stock following high energy trauma. In elderly it was low energy trauma. The average time of radiological fracture union in our study was 10 weeks (8-16 weeks). The mean constant score at final follow up was 66.7 (35-90). A total of 17 patients (51%) had excellent or good results, but in 9 (27%) the outcome was poor. Eight (23%) complications were noted resulting in poor functional outcome.

**Conclusions:** Proximal humeral locking plate is a good method of osteosynthesis for complex proximal humerus fractures allowing early mobilization, good functional outcome. A reproducible standard surgical technique is absolutely necessary for improved patient outcome. Most of the complications in our study were related to the surgical technique. The precise surgical technique, stable fracture fixation and restoration of correct neck shaft angle are absolutely necessary for improved outcome.

**Keywords:** Proximal humerus fractures, Locking plates, Constant score, PHILOS and PHLIP

### INTRODUCTION

Fractures of proximal humerus represent no more than 3% of all upper extremity fractures.<sup>1</sup> Their overall incidence has been reported to be 73 cases per 100,000 individuals per year.<sup>2</sup> As indicated by Cofield, areas still in question include radiographic diagnosis, operative or non operative treatment, consideration of patient age in

treatment decision making, surgical approach, fracture fixation or hemiarthroplasty, type of internal fixation, and rehabilitation protocol.<sup>3</sup> About 85% fractures are minimally displaced and are effectively treated symptomatically with immobilization followed by early motion. The remaining 15% of fractures are displaced, unstable and may have disruption of blood supply. Treatment of these fractures is a therapeutic challenge.

Various therapeutic options for displaced proximal humeral fractures are k wires, tension band wiring, humeral nails, anatomic plate osteosynthesis like PHILOS (proximal humeral interlocking system) and PHLP (proximal humeral locking plate) and hemiarthroplasty.<sup>2,4</sup> The choice of technique and device depends on type of fracture, quality of bone, age and reliability of patients. Recently, open reduction and internal fixation (ORIF) with locked plating has demonstrated promise in the treatment of displaced, comminuted proximal humerus fractures. The benefits reported include improved fracture stability because of the fixed-angle construct, particularly in more comminuted fracture patterns and in osteoporotic bone; a short period of immobilization with the opportunity for earlier rehabilitation, lower risk of damage to the rotator cuff or need for implant removal, reduced hardware complications and in patients with more complex fractures, the potential to avoid the use of hemiarthroplasty.<sup>5</sup>

This study is conducted to study the functional outcome of proximal humerus fractures treated with proximal humerus locking plates and to analyse the possible benefits and complications of the same. Proximal humerus locking plates are a part of latest generation of anatomically precontoured locking compression plates. In our study we have used both PHLP and PHILOS plates both of them developed by AO/ASIF group. Both the plates are designed to provide angular stability, adequate buttressing and load sharing support to prevent collapse of fragments to overcome most of the main hardware problems. In these plates the screws in the humeral head are locked into the plate and cannot back out or toggle. The plate thus acts as an external fixator put internally. The screws alternately diverge and converge improving the purchase in the head. The crossed screws increase the pullout strength dramatically.

## METHODS

In this series 34 patients with fracture of proximal humerus, treated from October 2010 to November 2012 at Saifee Hospital, Mumbai were evaluated. All the patients operated for proximal humerus fractures in the above mentioned period were included in our study based on the criteria mentioned below. Their operative and follow up records were accessed from the hospital data base.

The inclusion criteria were closed fractures of proximal humerus - two, three and four parts, adult patients age more than 18 years, fracture with dislocation. Exclusion criteria include distal neurovascular deficit, severe soft tissue injury, open injuries, patients on immunosuppressive therapy and with manifest infection.

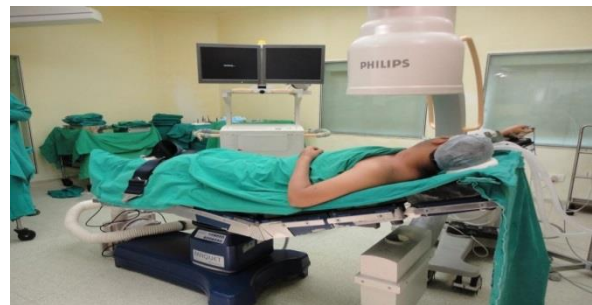X rays taken include true antero-posterior view of shoulder joint, transcapular lateral view and/or axillary view of scapula. If abduction of shoulder cannot be

performed due to pain a Velpeau axillary view was taken. All radiographs were evaluated to assess the fracture configuration and the extent of comminution. In selected cases CT scan with 3D reconstruction was done to improve the understanding of fracture pattern. CT scan is useful in multifragmentary fractures, to quantify displacement of the tuberosity, when plain X-rays fail to clearly show the fracture and when there is a concern for concomitant glenoid or scapular injury. MRI studies were not carried out in any of our patients.

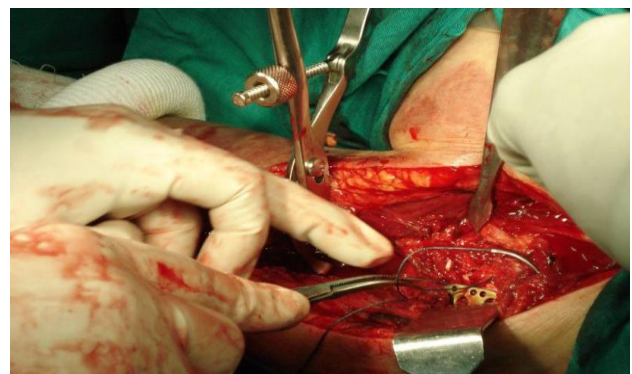
All patients were operated within average period of 4.17 days (5 hours 20 days). 28 patients were operated under general anaesthesia and 6 patients were operated under local block.

## Surgical technique

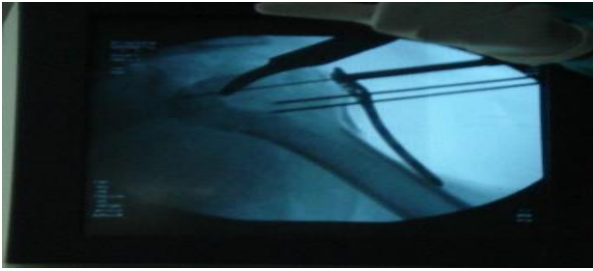
All patients were operated in a beach chair position (30 degree head elevation) through Deltopectoral approach with C arm from opposite side (Figure 1). Good imaging should be ensured before preparing the patient. The long head of biceps in the bicipital groove identified and preserved. Care should be taken to avoid excessive disruption through bicipital groove so as to preserve the ascending branch of the anterior circumflex humeral artery. Fracture exposed and Biceps tendon identified. To mobilize the fracture fragment, sutures through cuff muscles are passed with No 2 Ethibond (Figure 2). If the tuberosities are detached, the sutures should be placed around the tendon bone interface. This allows for control of the fracture and substantially assists with reduction.



**Figure 1: Patient positioning.**



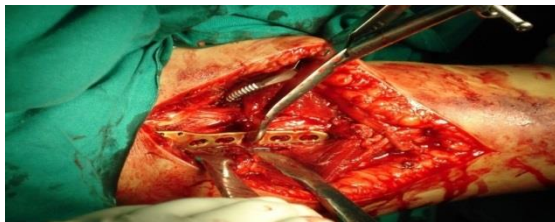**Figure 2: Cuff sutures.**



**Figure 3: Plate positioning with k wires.**



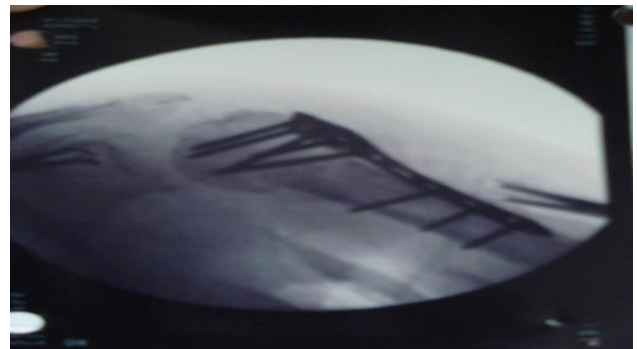
**Figure 4: Correction of varus.**



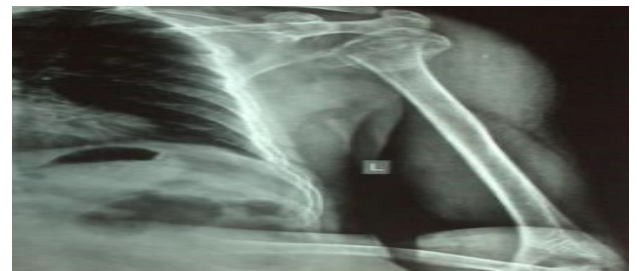
**Figure 5: Holding the plate.**

The rotator cuff sutures are passed through the suture holes of plate but not knotted to the plate as aiming block will not sit perfectly then. The fracture is reduced before plate application. The locking proximal humeral plate inserted along the humerus shaft and fixed temporarily with k wires (Figure 3). Correct position of the plate confirmed with image intensifier. The plate is first fixed to distal fragment with a cortical screw in oblong hole so that the height of the plate can be adjusted accordingly. If the head is in varus position, a small periosteum elevator or spike is used to reduce it into proper alignment (Figure 4). Now with the help of aiming block and K wire sleeve define the position of locking proximal head screw under C arm guidance, determine the length with depth gauge and lock it with a locking screw after predrilling (Figure 5). All proximal screws are locked in sequence under C arm guidance. Oblique views are done for inspecting each screw separately to avoid intra articular penetration. Screws were exchanged when necessary to obtain intended position of the screw tip relative to subchondral bone. The inferomedial locking screw to prevent varus collapse was inserted in most cases. The proximal locking screws were inserted into the humerus head before the distal screws were inserted into the humeral metaphysis or diaphysis. In patients with good reduction we used locking screw first and used the plate as an internal fixator. Position of the head was secured with

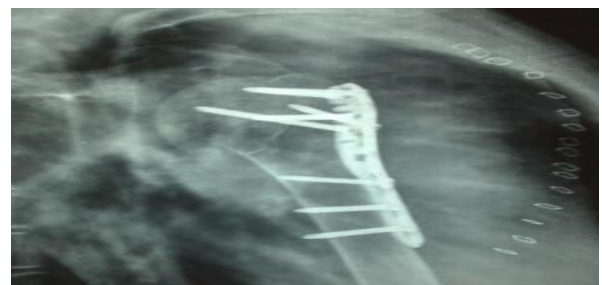previously placed rotator cuff sutures knotted to plate. Final position of plate and all screws are confirmed under C arm (Figure 6). Wound was closed over drain. For patients who had large medial metaphyseal void after elevation of humeral head, we used bone graft substitutes hydroxyapatite. This allows for structural support of the articular head segment and reduces the risk of postoperative varus collapse. We had three patients with vertical head splitting where antero-posterior cancellous screws were used. Encircle wiring over plate was done in two patients around shaft region. The PHLP is usually positioned 5 mm caudal to the proximal end of greater tuberosity and 10 mm dorsal to the posterior border of the intertubercular sulcus. PHILOS plate is positioned 8 mm caudal to the proximal end of greater tuberosity. The K wire is passed through the proximal guide hole of aiming device to check the position of the plate. The guide wire just touches the superior surface and is directed at the proximal joint surface. Placing the plate too high a level increases the risk of subacromial impingement. Placing the plate too low can prevent the optimal distribution of screw in the humeral head (Figure 6-9).



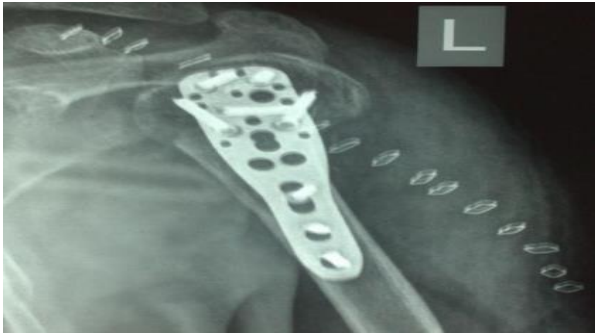
**Figure 6: Final confirmation.**



**Figure 7: Preoperative X-ray.**



**Figure 8: Postoperative AP view.**



**Figure 9: Postoperative lateral view.**

Postoperative pouch arm sling was given to all patients. Patients were allowed controlled active mobilization from second postoperative day. In 0-3 weeks, pendulum exercises and gentle active assisted exercises except external rotation are given. In 3-9 weeks, if there is clinical evidence of healing and fragments move as a unit and no displacement, then active assisted movements flexion and abduction are started.

Radiographs were taken regularly to check the position of the plate and progress of fracture healing. The shoulder range of movement was recorded. The patients were evaluated using the Constant and Murley shoulder scoring system at 3 and 6 months postoperatively when the fracture theoretically had healed. Constant and Murley score comprises both clinician-assessed physical examination findings and subjective patient-reported assessments.<sup>6</sup> This scoring system consists of four variables that are used to assess the function of the shoulder. The subjective variables are pain (15) and ADL (20) sleep, work, recreation/sport which give a total of 35 points. The objective variables are range of motion (40) and strength (25) which gives a total of 65 points.

**Statistical analysis**

For statistical analysis to compare the functional outcome between two age groups (older than 65 years and younger than 65 years) and relationship between radiographic outcome and functional scores, we used a students ‘t’ test with 95% confidence intervals. Significance was set at P =0.05.

**RESULTS**

The age of patients ranged from 17 to 92 years with mean of 55.2 year. Out of the thirty four patients in our study twenty four (71%) were less than 65 years and ten (29%) were older than 65 years of age (Table 1). Out of the twenty four patients younger than 65 years eleven (46%) had sustained proximal humerus fractures along with severe multiple injuries in road traffic accident. In this study, we had 19 male and 15 female patients (Table 2). Left side was involved in 55.9% of patients and right in 44.11% of patients. Non dominant side was involved in 53% of patients.

**Table 1: Age distribution of patients.**

| Age in years | No of cases | Percentage |
|--------------|-------------|------------|
| 15-30        | 2           | 5.88       |
| 31 –45       | 8           | 23.52      |
| 46 –60       | 10          | 29.41      |
| 61-85        | 13          | 38.23      |
| ≥86          | 1           | 2.94       |
| <b>Total</b> | <b>34</b>   | <b>100</b> |

**Table 2: Sex distribution of patients.**

| Sex           | No of cases | Percentage   |
|---------------|-------------|--------------|
| <b>Male</b>   | <b>19</b>   | <b>55.88</b> |
| <b>Female</b> | <b>15</b>   | <b>44.11</b> |

Eighteen patients (53%) were injured due to fall on outstretched hand, twelve (35%) were injured in road traffic accidents, one patient (3%) had twisting injury and two (6%) patients were injured during seizures (Table 3). Out of the thirty four patients in our study twenty four (71%) were less than 65 years and ten (29%) were older than 65 years of age. Of the twenty four patients younger than 65 years, eleven (46%) had sustained proximal humerus fractures along with severe multiple injuries in road traffic accident. Of the ten patients older than 65 years, nine patients (90%) had sustained this fracture due to fall on outstretched hand. Our study thus shows that proximal humerus fractures are now increasingly seen in younger population with good bone stock following high energy trauma and in elderly it is essentially a low energy trauma. Of the 34 cases there were 16 patients (47.1%) who had sustained AO type 11.C.3 fracture (Table 4). According to Neer’s classification there were 22 (64.70%) two part fracture (Table 5).<sup>7</sup>

**Table 3: Mechanism of injury according to age.**

| Mechanism of injury              | <65 years      | ≥65 years      | Total            |
|----------------------------------|----------------|----------------|------------------|
| <b>Fall on outstretched hand</b> | 9              | 9              | 18 (52.94%)      |
| <b>Road traffic accident</b>     | 11             | 1              | 12 (35.29%)      |
| <b>Seizures</b>                  | 2              | 0              | 2 (5.88%)        |
| <b>Twisting injury</b>           | 1              | 0              | 1 (2.94%)        |
| <b>Fall from height</b>          | 1              | 0              | 1 (2.94%)        |
| <b>Total</b>                     | <b>24(71%)</b> | <b>10(29%)</b> | <b>34 (100%)</b> |

**Table 4: Types of fracture according to AO classification.**

| Type of fracture | No. of cases | Percentage |
|------------------|--------------|------------|
| <b>11.C.1</b>    | 12           | 35.3       |
| <b>11.C.2</b>    | 6            | 17.6       |
| <b>11.C.3</b>    | 16           | 47.1       |
| <b>Total</b>     | <b>34</b>    | <b>100</b> |

**Table 5: Neer's classification.**

| Type of fracture  | No. of cases | Percentage |
|-------------------|--------------|------------|
| <b>Two part</b>   | 22           | 64.70      |
| <b>Three part</b> | 8            | 23.53      |
| <b>Four part</b>  | 4            | 11.76      |
| <b>Total</b>      | 34           | 100        |

The mean constant score at 3 months was 51.6 (22-80), at 6 months was 63.8 (35-87), and at one year was 67.3 (35-87). Constant score continues to improve till 24 months (Table 6). The average range of motion at final follow up was 130° (80-180) of flexion, 128° (80-180) of abduction, 59° (20-90) of external rotation and 74.8° (50-100) of internal rotation (Table 7).

Four (44%) patients above 65 years had good results whereas seven (29%) below 65 years of age had poor results (Table 8).

**Table 6: Mean functional scores.**

| Period since surgery | Constant and Murley score | Range of score |
|----------------------|---------------------------|----------------|
| <b>1 month</b>       | 25.87                     | 4-60           |
| <b>2 months</b>      | 38.52                     | 8-73           |
| <b>3 months</b>      | 51.64                     | 22-80          |
| <b>6 months</b>      | 63.85                     | 35-87          |
| <b>12 months</b>     | 67.38                     | 35-90          |
| <b>24 months</b>     | 87.3                      | 85-90          |

**Table 7: Range of motion.**

| Parameters (in degrees)  | 1 month | 2 months | 3 months | 6 months | 12 months | 24 months |
|--------------------------|---------|----------|----------|----------|-----------|-----------|
| <b>Forward flexion</b>   | 55      | 77.36    | 93.6     | 119      | 130       | 170       |
| <b>Abduction</b>         | 56.25   | 77.4     | 99.2     | 118.6    | 123.3     | 170       |
| <b>Internal rotation</b> | 31.87   | 44.21    | 54       | 68.92    | 75.7      | 93.3      |
| <b>External rotation</b> | 18.75   | 27.89    | 40.4     | 57.9     | 57.61     | 90        |

**Table 8: Final functional scores.**

| Constant score              | Age <65 | Age ≥65 |
|-----------------------------|---------|---------|
| <b>86-100 (excellent)</b>   | 4 (17%) | 0       |
| <b>71-85 (good)</b>         | 9 (37%) | 4 (44%) |
| <b>56-70 (satisfactory)</b> | 4 (17%) | 3 (33%) |
| <b>0-55 (poor)</b>          | 7 (29%) | 2 (22%) |
| <b>Total</b>                | 24      | 9       |

The mean constant score in patients who sustained AO type 11.C.3 fracture was 61.2 whereas in patients who sustained 11.C.1 and 11.C.2 type fractures was 71.3 (Table 9).

**Table 9: Functional scores of patients according to AO classification.**

| Fracture type        | No. of patients | Mean constant scores |
|----------------------|-----------------|----------------------|
| <b>11C1 and 11C2</b> | 18              | 71.3                 |
| <b>11C3</b>          | 15              | 61.2                 |

The mean constant score in patients who sustained two part fracture was 69.95 whereas in patients who sustained three and four part fractures was 59.9 (Table 10). The average duration of stay in our hospital was 7.14 days (3-30 days) and the average time to return to preinjury function was 9 weeks (4-16 weeks). The average time of radiological fracture union in our study was 10 weeks (8-16 weeks). The mean constant score at final follow up was 66.7 (35-90). A total of 17 patients (51%) had

excellent or good results, but in 9 (27%) the outcome was poor.

**Table 10: Functional scores of patients according to Neer's classification.**

| Fracture type              | No. of patients | Mean constant scores |
|----------------------------|-----------------|----------------------|
| <b>Two part</b>            | 21              | 69.95                |
| <b>Three and four part</b> | 12              | 59.92                |

## DISCUSSION

Complex proximal humerus fractures frequently presents difficulty in obtaining stable fixation because of comminution and poor bone quality.<sup>8</sup> The goal of surgery is obtaining and maintaining satisfactory reduction in order to allow early motion, achieve healing and restore function.<sup>1</sup> Several authors have presented short term results with mixed outcome.<sup>2</sup> Frankhauser et al reviewed their experience of 28 patients with 29 proximal humerus fractures treated with locking proximal humeral plate.<sup>9</sup> Twenty four of these fractures were AO type B and C. All fractures healed. Five complications were noted with one broken plate and four instances of loss of reduction (one related to deep infection). Two patients developed partial osteonecrosis one after deep infection.

The mean constant score in patients aged more than 65 years was 63.1 (48-82) and in those aged less than 65 years was 68.08 (41-90). The mean constant score with

11C3 fractures was 61.2 (41-87) and rest fractures (C1 and C2) was 71.3 (41-90). These differences were not statistically significant (t- test,  $p = 0.05$ ). Most of the complications that one comes across in our study were related to the technique.

There was varus collapse in 2 (6 %) patients, but was not significant (change in head shaft angle  $< 100$ ) and both of them were symptom free. Two (6%) patients had neck shaft angle on lower side 980 and 1000 respectively. Both of them had poor functional outcome with restriction of movements. Our findings suggest that avoiding varus malreduction is necessary for better functional outcome. Agudelo et al in his study concluded that there is a significant association between varus reduction and loss of fixation.<sup>10</sup> Varus malreduction substantially increases the risk of post op failures. Owsley et al reported about 12(23%) of patients treated with proximal humeral locking plate had intraarticular screw cutout.<sup>1</sup> He commented that unstable proximal humeral fracture like an unstable intertrochanteric fracture "wants to settle" into a position of stability even when rigid implants are placed. The phenomenon of locked screw cutting out through the cancellous humeral head bone particularly in osteoporotic patients has been attributed to the stiffness of screw and implant construction which has been confirmed in a biomechanical study.<sup>11</sup> In our study position of each screw while inserting was checked under C arm in oblique and anteroposterior views, and not every hole was filled with a screw. This may be possible explanation of comparative lower rate of screw cutout in our study.

The risk of osteonecrosis after open reduction has been reported to be 50%.<sup>7</sup> However in our study we had only one case (3%) of avascular necrosis. The patient was relatively symptom free and required no further treatment. This lower rate can be attributed to minimal soft tissue dissection; taking care of anterolateral branch of anterior circumflex humeral artery. Surgeon should approach proximal humeral fractures as not only a bony procedure but also a soft tissue procedure. To prevent potential complications like avascular necrosis, meticulous surgical dissection to preserve vascularity of humeral head is necessary.<sup>12</sup>

Eight (23%) complications were noted resulting in poor functional outcome. There were two (6%) cases of subacromial impingement out of which one patient underwent implant removal, one (3%) patient with longer screw with intraarticular penetration who underwent implant removal, one (3%) patient developed AVN but was relatively symptom free and required no further treatment, three patients (9%) had stiffness of shoulder two underwent implant removal and one patient underwent manipulation under general anesthesia four months after surgery. Of the three patients one patient had ipsilateral compound fracture of radius ulna due to which her rehabilitation remained poor, in another patient

the greater tuberosity was not reduced well resulting in limitation of movements and in third patient there was significant varus malunion with neck shaft angle of 980. All the patients who underwent implant removal had good functional outcome and improvement in range of movements. Four (12%) revision surgeries (implant removal) after fracture union, one for longer screw with intraarticular penetration, one for subacromial impingement due to higher placement of plate than ideal, two for stiffness of shoulder were performed. No cases of revision surgery for readjustment of plate, infection, or hardware failure required. Four (13%) of our patients underwent implant removal. Implant removal was a difficult procedure in two of our cases. In both the cases the plate had to be cut with Midas Rex. The implant removal should be advocated early and all the locking head screws must be loosened first followed by removal in sequence to avoid jamming of particular screw or loss of hexagonal head serrations.

## CONCLUSION

A reproducible standard surgical technique is necessary for improved patient outcome. Most of the complications that one comes across in our study were related to the technique. The precise surgical technique, stable fracture fixation and restoration of correct neck shaft angle are absolutely necessary for improved outcome. Meticulous preoperative surgical planning is a must. Minimal dissection, proper placement of plate, judicious use of aiming block with k wire sleeves to judge the correct placement and order of locking and nonlocking screws under image intensifier play very important role. Incorporation of sutures through the rotator cuff into the plate is a critical step and should not be skipped, because it allows the deforming forces of the rotator cuff to be counterbalanced and neutralized. We advocate passing these sutures around the tendon bone interface to provide a bony buttress and prevent the stitch from pulling through soft tissue. Varus malreduction increases the risk of failure of fixation. The mechanical support of the medial region is important for maintenance of reduction. Proximal humeral fixed angle locked plate in complex proximal humeral fractures is a good method allowing early mobilisation and good functional outcome. We accept that a longer follow up to know the incidence of AVN is required for the completion of study.

*Funding: No funding sources*

*Conflict of interest: None declared*

*Ethical approval: The study was approved by the institutional ethics committee*

## REFERENCES

1. Owsley KC, Gorczyca JT. Displacement/Screw cut out after open reduction and locked plate fixation of humeral fractures. *JBJS Am.* 2008;90:233-40.
2. Badman BL, Mighell M. Fixed angle locked plating of two, three, and four part Proximal Humerus

- Fractures. *J Am Acad Orthop Surg.* 2008;16:294-302.
3. Cofield RH. Comminuted fractures of the proximal humerus. *Clin Orthop Relat Res.* 1988;(230):49-57.
  4. Palvanen M, Kannus P, Niemi S, Parkkari J. Update in the epidemiology of proximal humeral fractures. *CORR.* 2006;442:87-92.
  5. Koukakis A, Constantinou D, Apostolou, Tanaje T, Korres DS, Amini A. Fixation of proximal humerus fractures using the PHILOS plate. *CORR.* 2006;442:115-120.
  6. Constant CR, Murley AH. A clinical method of functional assessment of the shoulder *J Clin Orthop Relat Res.* 1987;214:160-4.
  7. Neer C. Displaced proximal humerus fractures. Classification and evaluation: *J Bone Joint Surg Am.* 1970;52:1077-89.
  8. Gardner MJ, Weil Y, Barker JU, Kelly BT, Helfet DL, Lorich DG. The importance of Medial support in Locked Plating of proximal humerus fractures. *J Orthop Trauma.* 2007;21:185-91.
  9. Fankhauser F, Boldin C, Schippinger G, Haunschmid C, Szyszkowitz R. A new locking plate for unstable fractures of the proximal humerus. *CORR.* 2005;430:176-81.
  10. Agudelo JF, Schurmann M, Stahel P, Helwig P, Morgan SJ, Zechel W, et al. Analysis of efficacy and failure in proximal humerus fractures treated with locking plates. *J Orthop Trauma.* 2007;21:676-81.
  11. Lill H, Hepp P, Korner J, Kassi JP, Verheyden AP, Josten C, et al. Proximal humeral fractures: how stiff should an implant be? A comparative mechanical study with new implants in human specimens. *Arch Orthop Trauma Surg.* 2003;123(2-3):74-81.
  12. Kirankumar GN, Sharma G, Sharma V, Jain V, Farooque K, Morey V. Surgical treatment of proximal humerus fractures using PHILOS plate. *Chinese J Traumatol.* 2014;17:279-84.

**Cite this article as:** Kumar R, Natarajan S, Kumar S, Kalanithi R. Outcome analysis of patients with proximal humerus fractures treated with locking plates. *Int J Res Orthop* 2017;3:401-7.