

Original Research Article

Dynamic hip screw technique in the management of trochanteric fracture

N. V. Narasimha Rao¹, C. Siva Rama Krishna^{1*}, K. Aditya¹, T. Jaya Chandra²

¹Department of Orthopedics, ²Central Research Laboratory, G.S.L. Medical College, Rajahmundry, Andhra Pradesh, India

Received: 12 October 2019

Revised: 04 December 2019

Accepted: 05 December 2019

***Correspondence:**

Dr. C. Siva Rama Krishna,

E-mail: gslcentralresearchlab@gmail.com

Copyright: © the author(s), publisher and licensee Medip Academy. This is an open-access article distributed under the terms of the Creative Commons Attribution Non-Commercial License, which permits unrestricted non-commercial use, distribution, and reproduction in any medium, provided the original work is properly cited.

ABSTRACT

Background: Study was conducted to find the results of dynamic hip screw in the management of trochanteric fracture by analyzing the factors which influence post-operative mobility.

Methods: Study was conducted in the department of orthopedics, GSL Medical College. Individuals >18 years, both genders who were diagnosed having trochanteric type I and II Boyd and Griffin stable fractures were included in the study. All surgeries were performed under spinal anesthesia, internal fixation with dynamic hip screw and 135o angled blade plate. Injectable third generation cephalosporins were used 24 hours preoperatively, intra-operatively and 5 days post-operatively, and oral antibiotics till suture removal. Patients allowed to sit on bed on 2nd and 3rd day and static quadriceps exercises were started from 2nd day onwards, hip and knee flexion exercises from 6 or 7th day and weight bearing walking from 10th day.

Results: The average age was of the participants was 61.53 years, ranged between 41 to 80 years; 65% were female participants and 35% were male patients. In the study, 20 (50%) patients had right side fracture and left sided affection of trochanteric fracture to the remaining 50%. Most of the patients (67.5%) in this study were classified as type II Boyd and Griffin criteria, and 32.5% were type I. The clinical and functional outcome was calculated using the Kyle's criteria; 25% (10) showed excellent response, followed by good (50%), fair (15%) and poor (10%) results.

Conclusions: Dynamic hip screw is the operative treatment of choice for stable trochanteric fractures. However, studies on large sample for long time are recommended.

Keywords: Femur, Fracture, Operative

INTRODUCTION

Trochanteric fractures (TFs) of femur are common in old age group, but it is not uncommon in younger age. These fractures unite readily with conservative line of treatment. Unlike fractures of neck of femur, there is no fear of complication like, avascular necrosis of head and its sequelae of osteoarthritis. Though TF unite without surgical intervention, malunion with coxa vara deformity resulting in shortening of limb and limp are commonly

seen.¹ Until operative treatment involving the use of various implants were introduced in 1950s, hip fractures were managed using conservative methods such as traction and bed rest.²

Various operative procedures with different implants have been described for the treatment of TF. Earlier active treatment was usually delayed for as long as three to four weeks because it was believed that attempts to immobilize the limb by splints traction or open reduction

with internal fixation would prove fatal but this usually leads to secondary complications.

The primary goal of treatment has to be early mobilization to avoid secondary complications which can be achieved by dynamic hip screw which is operative treatment of choice for TFs as it allows early weight bearing and lower complication than other implants.

With these, a study was conducted to find the results of dynamic hip screw in the management of trochanteric fracture by analyzing the factors which influence post-operative mobility.

METHODS

This was a case control study, conducted in the Department of Orthopedics, GSL Medical College from May 2015 to August 2017. Study protocol was approved by the institutional ethics committee; informed written consent was taken from the study participants. Individuals >18 years, both genders who were diagnosed having a trochanteric type I and II Boyd and Griffin Stable fractures were included in the study.

Patients <18 years, sub trochanteric and reverse oblique trochanteric types III and IV Boyd and Griffin unstable fractures, patients with old un-united TF, who were not fit for surgery, compound fractures, polytrauma, pathological fractures and patients with uncontrolled diabetes mellitus and chronic renal failure were not considered in the study.³

Patients admitted with TF were examined and x-rays of the hip were taken. Skin traction was applied routinely in all cases.

Routine blood and urine examination were done. In addition, blood urea, serum creatinine, blood sugar, ECG and chest X-ray examinations were done; if required, opinions of physician and cardiologist were taken. The fractures were classified as stable according to Boyd and Griffin's classification (Type I and II).³ Radiological grading of osteoporosis was done using Singh's Index.^{4,5} The clinical and functional outcome was calculated using the Kyle's criteria.^{6,7}

All surgeries were performed under spinal anesthesia, internal fixation with dynamic hip screw and 135° angled blade plate. Injectable third generation cephalosporin were used 24hours preoperatively, intra-operatively and 5 days postoperatively, and oral antibiotics till suture removal. Patients allowed to sit on bed on 2nd and 3rd day and static quadriceps exercises were started from 2nd day onwards, hip and knee flexion exercises from 6 or 7th day and weight bearing walking form 10th day.

Statistical analyses were done by using SPSS software version 21.0. The analysis was carried by calculating the percentages of the participants.

RESULTS

In this study, 42 patients with TF were included; data were analyzed with 40 as the remaining 2 lost follow up. The average age was of the participants was 61.53 years, ranged between 41 to 80 years (Table 1); 65% were female participants and 35% were male patients (Figure 1). In the study, 20 (50%) patients had right side fracture and left sided affection of TF to the remaining 50% (Table 3). Most of the patients (67.5%) in this study were classified as type II Boyd and Griffin criteria, and 32.5% were type I (Table 3).

Table 1: Age wise distribution of the study participants.

Age (in years)	Participants (%)
41–50	7 (17.5)
51–60	15 (37.5)
61–70	7 (17.5)
71–80	11 (27.5)
Total	40 (100)

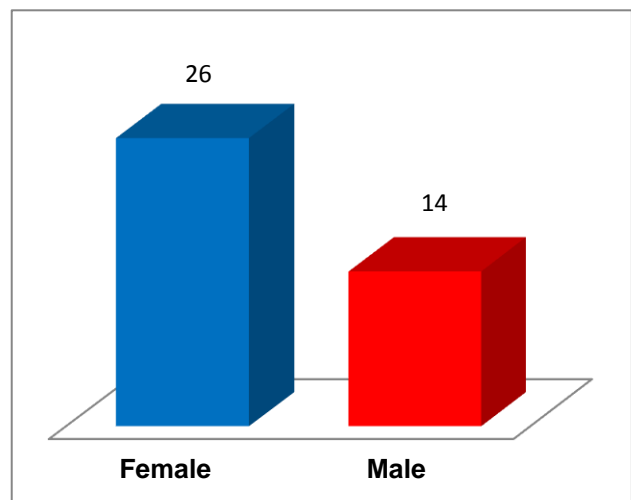


Figure 1: Gender wise distribution of the study participants.

Table 2: Distribution of the study participants according to the effected side.

Side affected	Participants (%)
Right	20 (50)
Left	20 (50)
Total	40 (100)

Table 3: Distribution of fracture according to Boyd and Griffin's classification.

Type of fracture	Participants (%)
Type I	13 (32.5)
Type II	27 (67.5)
Total	40 (100)

As per the Kyle's criteria, 25% (10) showed excellent response, followed by good by 20 (50%) members, fair by 6 (15%) members. Poor results were shown by 4 (10%) members (Table 4).

As per the Singh's index, 16 (40%) cases had grade III osteoporosis. 12 (30%) had grade IV osteoporosis, 8 (20%) had grade II, 3 (7.5%) had grade V and 1 (2.5%) had grade I. None of the participants had grade I (Table 5).

Table 4: Results of evaluation according to Kyle's criteria.

Results	Participants (%)
Excellent	14 (35)
Good	20 (50)
Fair	6 (15)
Poor	0
Total	40 (100)

Table 5: Distribution of fractures according to Singh's index.

Type of osteoporosis	No. of patients (%)
Grade III	16 (40)
Grade IV	12 (30)
Grade II	8 (20)
Grade V	3 (7.5)
Grade VI	1 (2.5)
Grade I	0
Total	40 (100)

DISCUSSION

At present it is generally believed that, all TF should be internally fixed to reduce the morbidity and mortality by early ambulation, but differences still exist regarding the type of implant to be used, hence in this study results after treatment with DHS were analyzed.

In the present study, the average age of the study participants were 61.53 years. Ganz et al also reported 70% patients were female, with mean age 70 years.⁸ This was comparable to those of other Indian authors, and most of the western authors. We had female preponderance, unlike male preponderance in most of Indian authors, as in most western authors.

In this report 67.5% patients had type II fractures; this was comparable to Boyd et al.⁹ But, these findings were in contrast with Pathak et al report.¹⁰ The pathological fractures were reported to be 20 to 25% by Waddell et al but these were not included in this study.¹¹

Ecker et al, in their study mentioned that operation is the treatment choice for TFS provided with the availability of a skilled anesthetist, surgeon, sophisticated instruments,

operation theatre conditions.¹² By considering the financial aspect, Parker et al., reported that surgical treatment is cost effective than conservative treatment and also improved quality of life.¹³ In this study all cases were operated.

Dolk et al found no difference in mortality and hospital stay between those operated within 8hrs of admission and those treated within 48 hrs of admission, indicating that there was no need to operate on those as emergencies.¹⁴

It is important before treatment to distinguish using radiograph stable or unstable TF, based on fracture geometry and the ability to restore the cortical contact medially and posteriorly by reduction. Without posteromedial contact the proximal fragment remains unstable in varus and retroversion. The number one error in the treatment of TF is poor evaluation of fracture stability preoperatively, therefore proper tracing and planning based on roentgenograms is essential, which was strictly carried out in our study.

Kyle et al reported deep infection rate was 3 to 5% without preoperative prophylactic antibiotics.¹⁵ In this report, we didn't find deep infection; but superficial infections were seen in 2 (5%) cases. The patients were given povidone-iodine local application before entering Operation Theatre and all patients were given intravenous prophylactic antibiotics at the time of anesthesia and for 48 hours in the postoperative period.

All the cases in this study were operated using fracture table and we have found the following advantages easy reduction done with traction, requirement of less assistance, reduced trauma and shock. The goal of surgical treatment is strong stable fixation of the fragments; Kaufer has listed the variables such as bone quality, fragment geometry, reduction, implant design and implant placement that determine the strength of the fracture fragment and implant assembly.¹⁶

Most patients with TFS have considerable osteopenia with quality of the bone for purchase of fixation within the head is less than desirable. It is therefore important that the lag screw is placed in that part of the head and neck where the quality of the bone is best.

Davis et al favored the central portion on both views but according to Mains et al ventral or inferior portion in anteroposterior view is the best.^{17,18} In this study, most of the cases were either 3 or 4 Singh's index confirming that these fractures are mainly osteoporotic fractures (Table 5). According to Parker MJ., screw should be placed inferiorly on anteroposterior view and centrally on lateral view. In this study, the same principle of placement of screw was followed.¹⁹

Cutting out of DHS is related to its position according to Jensen study was 53% and that according to Davis et al it

was 16.8%.^{17,20} Reduction of the TFS may be carried out either by open or closed means. In either circumstance the objective is to achieve as table reduction, be it anatomical or non-anatomical in configuration. Closed manipulation should be initially attempted with anaesthetized patient on fracture table securing extremities in the foot pieces and by traction on slightly abducted extremities to reduce the fracture.

If the fracture is severely comminuted, anatomical reduction even by open reduction may be difficult. If adjusting the rotation does not close posteromedial defect and the lesser trochanter remains significantly displaced, anatomic reduction is difficult. In such circumstances non-anatomic but stable reduction obtained by elective medial displacement of the femoral shaft has been used by Dimon Hugston to achieve stability followed by internal rotation.²¹ Sarmiento and Williams have advocated an osteotomy to position the head and neck fragment in more valgus thus securing better medial stability than can be achieved by simple medial displacement.²² Most of the currently available internal fixation devices for treatment of TF can be exceeded to yield satisfactory results. Regardless of the device selected, fracture reduction and stability are most important factors.

The depth of insertion of the lag screw into the head is critical for maximum purchase on the proximal fragment. Most agree that it should be inserted within 1cm of the subchondral bone. This principle has been followed in this study.

Kuffer et al studied the influence on type of implant and the geometry of reduction and they concluded that geometry of reduction has no effect on fixation.¹⁶ They think that most of the load is borne by the implant rather than the bone and that the strength of the dynamic hip screw appliance exceeds the normal load and results in few incidence of failure compared to other implants.

Esser et al found no difference between dynamic hip screw and Jewett Nail plate regards to length of hospital stay, mortality and morbidity, but at the end of six months more patients treated with dynamic hip screw were mobile with significant radiological evidence of better compression without loss of fixation.²³

CONCLUSION

Trochanteric fractures are essentially the fractures of elderly, with osteoporotic bones. Dynamic hip screw is the operative treatment of choice for stable TF. However, studies on large sample for long time are recommended.

Funding: No funding sources

Conflict of interest: None declared

Ethical approval: The study was approved by the institutional ethics committee

REFERENCES

1. Falch JA, Liebekk A, Slungaard U. Epidemiology of hip fractures in Norway. Acta Orthop Scand. 1986;56:12-6.
2. Wong PCN. Femoral neck fracture among the major racial groups in Singapore. Incidence pattern compared with nonasian communities. Singapore Med. 1984;J5:150-7.
3. Boyd HB, Griffin LL. Classification and treatment of trochanteric fractures. Arch Surg. 1949;58:853.
4. Singh M, Nagrath AR, Maini PS. Changes in trabecular pattern of the upper end of the femur as an index of osteoporosis. J Bone Joint Surg Am. 1970;52(3):457-67.
5. Liu Z, Gao H, Bai X, Zhao L, Li Y, Wang B. Evaluation of Singh Index and Osteoporosis Self-Assessment Tool for Asians as risk assessment tools of hip fracture in patients with type 2 diabetes mellitus. J Orthop Surg Res. 2017;12(37):2-7.
6. Kyle RF, Gustilo RB, Premer RF. Analysis of six hundred and twenty two cases of intertrochanteric fractures of the femur. J Bone Joint Surg Am. 1979;61:216-21.
7. Endigeri P, Pattanashetty OB, Banapatti DB, Pillai A, Ullas T. Outcome of intertrochanteric fractures treated with proximal femoral nail: A prospective study. J Orthop Traumatol Rehabil. 2015;8:25-9.
8. Ganz R, Thomas RJ, Hammerle CP. Trochanteric fractures of the femur treatment and results. Clin Orthop. 1979;138:30-40.
9. Boyd HB, Anderson LD. Management of unstable trochanteric fractures. Surg Gynecol Obstet. 1961;112:633
10. Pathak KP. Trochanteric fractures. Ind J Orthop. 1984;22:123-5.
11. Waddell JP, Czitrom A, Simmons EH. Enders nailing in fractures of proximal femur. J Trauma. 1987;27:911-6.
12. Ecker ML, Joyce JJ, Kohl EJ. The treatment of trochanteric hip fractures using compression screw. J Bone Joint Surg. 1975;57:23-7.
13. Parker MJ. Cutting of dynamic hip screw related to its position. J Bone Joint Surg. 1992;74:625-69.
14. Dolk T. Operation on hip fracture patient Analysis of the time factor. Injury. 1990;21:369-92.
15. Kyle RR, Gustilo RB, Fremer RR. Analyses of six hundred and twenty two inter trochanteric fractures. J Bone Joint Surg. 1979;61:216-22.
16. Kufer K, Matthews LS, Sonstegard D, Michigan AA. Stable fixation in inter trochanteric fractures. J Bone Joint Surg. 1974;56:889-907.
17. Davis RTC, Sher JL, Horsman A, Simpson M, Checketts RG. Inter trochanteric femoral fracture, mechanical failure after internal fixation. J Bone Joint Surg 1990;72:26-31.
18. Mains CC, Newman RJ. Implants failure in proximal fractures of femur treated with sliding screw device. Injury. 1989;20:98-100.

19. Parker MJ. Cutting of dynamic hip screw related to its position. *J Bone Joint Surg.* 1992;74:625-8.
20. Jensen JS, Tondvald E, Sonnee HS. Stable inter trochanteric fractures: A Comparative analysis of four methods of internal fixation. *Acta Orthop Scand.* 1980;51:811-6.
21. Dimon JH, Hughston JC. Unstable intertrochanteric fractures of the hip. *J Bone Joint Surg.* 1967;49:440.
22. Sarmiento A, Williams EM. The unstable inter troch anteric fracture of the femur. *Clin Orthop.* 1973;92:77.
23. Esser MP, Kassab JY, Jones DHA. Troch anteric fracture of the femur. *J Bone Joint Surg.* 1986;68:557-60.

Cite this article as: Narasimha Rao NV, Rama Krishna CS, Aditya1 K, Chandra TJ. Dynamic hip screw technique in the management of trochanteric fracture. *Int J Res Orthop* 2020;6:58-62.