

Original Research Article

A study of surgical management of distal femoral fractures in adults using locking compression plate

Srinivas Bachu*, Ramulu L.

Department of Orthopaedics, Government Medical College, Nizamabad, India

Received: 29 December 2016

Accepted: 30 January 2017

***Correspondence:**

Dr. Srinivas Bachu,

E-mail: srinibachu71@gmail.com

Copyright: © the author(s), publisher and licensee Medip Academy. This is an open-access article distributed under the terms of the Creative Commons Attribution Non-Commercial License, which permits unrestricted non-commercial use, distribution, and reproduction in any medium, provided the original work is properly cited.

ABSTRACT

Background: The introduction of locking compression plates with option of locked screws has provided the means to increase the stability of fracture fixation.

Methods: In this study, 30 distal femoral fractures were treated using the distal femoral locking compression plate. All fractures were fresh, closed and operated within 12 days. Follow up duration ranged from 6 to 18 months.

Results: In this study, 20 patients were males and 10 were females. The 23 of the fractures (76.66%), were caused by road traffic accidents, 3 were due to accidental falls (10%), one was due to assault and 3 were due to fall from height. 9 patients had associated injuries. All patients were treated with open reduction and internal fixation using Locking Compression Plate. 6 to 9 holed plates were used. Out of 30 patients 2 went for delayed union and 3 went for non-union. Average knee flexion was 109° having knee range of motion more than 100 with 50% patients. Average knee extensor lag was 2.4 degrees with only 4 patients with lag more than 5. 2 patients developed 2 cm shortening. 4 patients had less than 5 degrees of malalignment. 2 patients had deep infection. Functional outcome was measured using NEER's scoring system and was done at the end of 5- 7 months (average of 6 months). Excellent results- 17 (56.66%) good results-8 (26.66%) fair results-2 (6.66%) poor results-3 (10%).

Conclusions: LCP condylar plate represents an evolutionary approach to the surgical management and is an important armamentarium in distal femur fracture fixation, especially when fracture is severely comminuted and in situations of osteoporosis.

Keywords: Distal femoral fractures, Locking compression plate, Knee flexion, Knee extensor lag

INTRODUCTION

The incidence of distal femur fractures is approximately 37 per 1,00,000 person-years, is high in young and old people, showing bimodal distribution.^{1,2} Distal femoral fractures mainly are the result of two different injury mechanisms. One is high energy trauma mainly sustained in road traffic accidents with considerable comminution of condyles and metaphysis, often open, in which problem is restoring the function in a destroyed knee joint. Another is the low energy trauma, relating to elderly patients with severe osteoporosis, in which the problem is anchoring the implants to bone.³

Most surgeons agree that distal femur fractures need to be treated operatively to achieve optimal patient outcomes.⁴ The options for operative treatment are traditional plating that require compression of the implant to the femoral shaft (blade plate, dynamic condylar screw, non-locking condylar buttress plate), antegrade and retrograde nailing, sub muscular locked internal fixation and external fixation.⁴

However, as the complexity of fractures needing treatment has changed from simple extra-articular supra-condylar types to complex inter-condylar and metaphyseal comminuted types, these implants may not be ideal. In double plating there is often extensive soft tissue

stripping on both sides of the femur, resulting in reduced blood supply and potential non-union and failure of the implants.^{2,5,6}

The LCP is a single beam construct where the strength of its fixation is equal to the sum of all screw-bone interfaces rather than a single screw's axial stiffness or pullout resistance as seen in unlocked plates. Its unique biomechanical function is based on splinting rather than compression resulting in flexible stabilization, avoidance of stress shielding and callus formation. Further when it is applied via a minimally invasive technique, in a biological manner, it allows for prompt healing, lower rates of infection and reduced bone resorption as blood supply is preserved. Internal fixation with locking plates creates a toggle free, fixed angle construct, increases the stability of fixation in osteoporotic bone or in the presence of peri or juxta-articular fractures.⁵

The implant offers multiple points of fixed-angle contact between the plate and screws in the distal part of femur, theoretically reducing the tendency for varus collapse that is seen with traditional lateral plates.⁷⁻⁹ The shaft holes on the DF-LCP are oval allowing for the options of a compression screw or a locking screw which leads to a more precise placement of the plate, as it is able to be compressed more closely to the bone.

Since there have been less published studies focusing specifically on the LCP, this study will help us in defining the role of locking compression plate in the treatment of distal femur fractures. The study is undertaken to evaluate the outcome of management of distal femoral fractures using LCP which may be helpful to find the solutions for the complications associated with management of these complex fractures.

METHODS

Study was conducted in Government medical college, Nizamabad for a period of 1 year. In study 30 patients with distal femoral fractures (distal 15 cm) treated with ORIF with LCP were studied, in relation to the demography, union time and complications were studied with duration of follow up ranged from 6 to 18 months. Institutional ethical clearance and informed patient consent was obtained.

Inclusion criteria

Age group of 20 years or above of both genders, Post-traumatic fresh and closed distal femoral fractures with or without osteoporotic changes.

Exclusion criteria

Open fractures, Children fractures, non-operatively treated, peri-implant, pathological and supra condylar fractures.

In every case general, systemic and local examination of the patient was done, stabilised with intravenous fluids, oxygen and blood transfusion as and when required, radiographs were taken, limb immobilized in slab support with a cotton pad below the distal fragment. Implants, DF-LCP are manufactured from 316L stainless alloy with gun drilling technique. With 4.5 mm thickness plate has anatomically pre-contoured plate head with soft edges, the head of the locking screw is threaded which gets locked to the plate as it is tightened and gives secure support. Combi holes in the plate shaft, provides intra operative choice between angular stability and/or compression. LCP have 50° of longitudinal screw angulation and 14° of transverse screw angulation with 4.0 mm and 5.0 mm self-tapping locking screws with 3.2 mm and 4.3 mm drill bits respectively along with threaded drill sleeves.

Preoperatively all required investigations were done, clearance from physician or cardiologist and PAC by anaesthetist were done. Fractures were classified with the help of radiographs according to the AO-ASIF classification.

Surgical technique

Patient under anaesthesia, supine on radiolucent table with support under buttock and knee joint, aseptic, lateral incision parallel to the shaft from Gerdy's tubercle extended proximally to required length, vastus lateralis is reflected anteriorly exposing the underlying fracture. First reduction of condyles is performed using pins and clamps, later condyles are to be reduced to the shaft, sagittal deformity by traction and support, coronal deformity with the plate itself. Postoperatively vitals and drain were monitored, foot end elevation, antibiotics and analgesics were given and check radiographs were taken, splints were removed and mobilization of the limb started from 3 to 5 days, mobilization with non-weight bearing was started from the first postoperative week till 6-8 weeks depending on the fracture pattern and then partial weight bearing after confirmation of beginning of healing process till fracture union.

All patients were followed up at 6, 10, 14, 18 weeks and every 6 weeks thereafter till fracture union is noted. Subsequently at 6, 9 month and 1 year. During follow up patients were assessed clinically, radiologically and functionally by NEERS criteria.

RESULTS

Table 1 presents the demographic data of the patients. Male: Female ratio was 1:2. Most of the patients were under the age group of 20-10. The common mechanism of injury was RTA seen in 23 patients. Table 2 presents the relationship of age with mechanism of injury. Relationship of sex with cause of injury was presented in Table 3.

Table 1: Demographic distribution.

Characteristics	No. of distal femur fractures	Percentage
Gender		
Male	20	66.6
Female	10	33.3
Age		
20-30	10	30
31-40	9	27
41-50	5	15
51-60	3	9
>60	3	9
Mechanism of injury		
Road traffic accident	23	76.6
Accidental fall	3	10
Fall from height	3	10
Assault	1	3.3

26.6% cases united within 15 weeks of time and overall 76.66% cases united by 4 months (18 weeks). 2 cases

went for delayed union and 3 cases went for non-union. The mean time for the union was 16.6 weeks as shown in Figure 1.

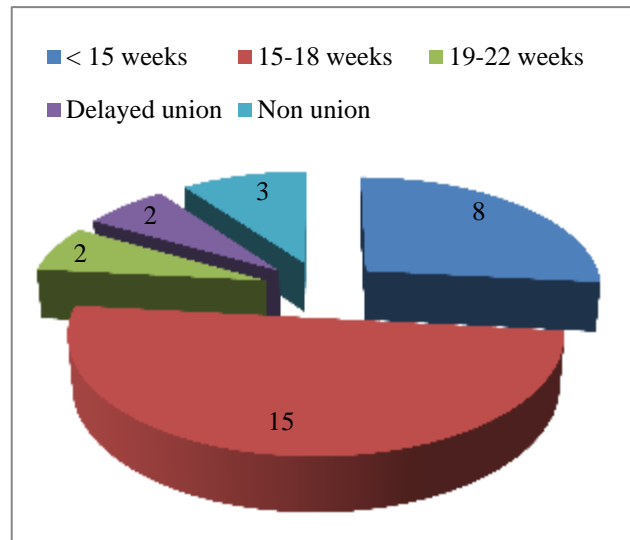


Figure 1: Representing union of fracture.

Table 2: Relationship between age and mechanism of injury.

Age group		Mechanism of injury				Total
		RTA	Fall from height	Accident fall	Assault	
< 50 years	No. of patients	21	2	0	1	24
	%	87.5%	8.3%	0%	4.2%	100.0%
> 50 years	No. of patients	2	1	3	0	6
	%	33.3%	16.7%	50.0%	.0%	100.0%
Total	No. of patients	23	3	3	1	30
	%	76.7%	10%	10.0%	3.3%	100.0%

Table 3: Relationship between sex and cause of injury.

Sex	RTA		Fall		Assault		Others	
	No.	Percentage	No.	Percentage	No.	Percentage	No.	Percentage
Male	17	56.66	1	3.30	1	3.33	1	3.30
Female	6	20	2	6.60	0	0	2	6.60

Knee flexion was more than 100° in 50% of study group. The average knee flexion was greater than 110°, in 43.3% of the study group and which was considered optimal for daily activities by Laubenthal and is less than 40° in 13.33% of study group as given in Table 4.

Table 4: Knee flexion.

Knee flexion	No. of cases	Percentage
> 100 Degrees	15	50
80 - 100 Degrees	7	23.33
60- 80 Degrees	4	13.33
40 - 60 Degrees	0	0
< 40 Degrees	4	13.33

Table 5: Limb length discrepancy.

Shortening	No. of cases	Percentage
0.5- 1 cm	3	10%
1 - 2 cm	2	6.66%
> 2 cm	2	6.66
Total	7	23.33%
No length Discrepancy	23	76.66%

Functional outcome was assessed using NEER score at the end of 5 months to 7 months depending on the patient follow-up.¹⁰

The scores were excellent in 56.66% of the study group. Good to excellent results were seen in 83.33% of the study group as shown in Figure 2.

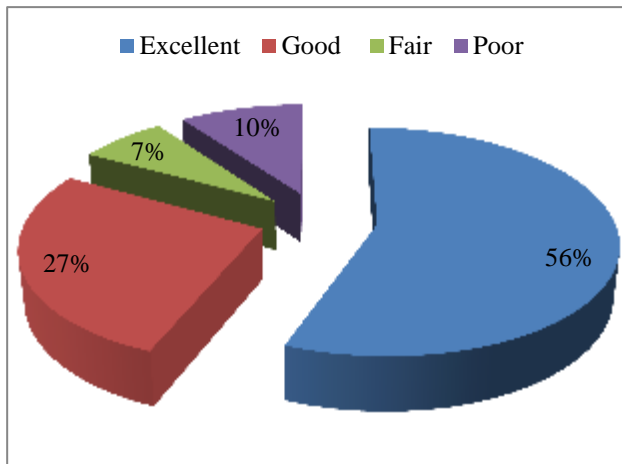


Figure 2: Functional outcome based on NEER'S scores.

Table 6: Complications.

Complications	No of cases	Percentage
Superficial infection	2	6.66%
Deep infection	2	6.66%
Delayed union	2	6.66%
Non-union	3	10%
Plate backout	0	0
Implant failure-screw/plate breakage	1	3.33%
Varus/ valgus of > 5 degrees	2	6.66%
Extension lag > 5 degrees	4	16.66%

DISCUSSION

In this study 30 fresh and closed fractures of distal femur were treated with LCP. Overall outcome of the surgical management of fracture lower end of femur using LCP was assessed in terms of regaining the lost knee function using NEER'S score.¹⁰

The median age was 40 years ranging from 20-75 years. 16 patients were with fracture on right side and 14 on left side. The LCP is a single beam construct where the strength of its fixation is equal to the sum of all screw-bone interfaces rather than a single screw's axial stiffness and pullout resistance as in unlocked plates. Its unique biomechanical function is based on splinting rather than compression resulting in flexible stabilization, avoidance of stress shielding and callus formation.⁵ When applied via a minimally invasive technique, it allows for prompt healing, lower rates of infection and reduced bone resorption as blood supply is preserved.

We tried to compare our study with other studies where distal femoral fracture fixation is done by condylar buttress plate. According to study by Kolb, 41 cases of AO type 3.3 there were 3 delayed union, 1 non-union and two infection, >10% of cases developed varus and valgus malalignment which required another corrective surgery.⁷ According to study by Davison, 26 cases (26 months follow - up) observed >5° varus collapse in 42% of cases.⁸ In our study, we used LCP, where increased rigidity of fracture fixation even in osteoporotic bone prevented malalignment during fracture healing than that of condylar plate.

We also compared with other studies where LCP is used. Yeap and Deepak conducted a retrospective review on eleven patients who were treated with titanium distal femoral locking compression plate.¹¹ The patient's ages ranged from 15 to 85 with a mean of 44. Clinical assessment was conducted at least 6 months post-operatively using the Schatzker score system. Results showed that four patients had excellent results, four good, two fair and one failure. The results are consistent with the current study.

Henderson et al reviewed the literature on locking plate for acute distal femur fractures in a total of 18 studies and observed that rate of complications related to healing ranged from 0% to 32% and implant failures occurred late with 75% after 6 months.¹² This is consistent with the current study where the complication rate is 16.66 % (10% non-union and 6.6% delayed union) and one case of implant failure occurred at the end of 8 months.

Hoffmann et al, analyzed in a retrospectively distal femur fractures treated with LCP for the clinical outcomes and complications in 243 cases and found that 18 % developed non-union and 74.8% of the fractures healed.¹³ Four resulted in a recalcitrant non-union. They analyzed that closed injuries had a higher tendency to heal than open injuries (p = 0.057). Closed and minimally open (Gustilo/Anderson types I and II) fractures healed at a significantly higher rate compared to type III open fractures (80.0% versus 61.3%, p = 0.041) and sub-muscular group had better outcomes than openly reduced cases. They concluded that despite modern fixation techniques, distal femoral fractures often result in persistent disability and worse clinical outcomes. Soft tissue management seems to be important, sub-muscular plate insertion reduced the non-union rate. This study contradicts some of the previous studies in terms of complications and union with proposed increased incidence of implant failure and non-union with LCP, but also stated that multiple factors influence the results.

The present study showed better results than Hoffman et al with 90% union results with less incidence of implant failure and overall complications.¹³ The better results in this study may be related to the that none of the cases in this study were open fractures leading to less soft tissue trauma and decreased chances of infection and more

cases were younger with the mean age of 40 years as opposed to the above study where more than 40% cases were open fractures with mean age of 54 years which shows more percentage of osteoporotic bones due to older age group.

In the current study, 30 cases of distal femur fractures were studied with an average age of 40 years. The average union time was 16.6 weeks. 10% incidence of non-union, 3 % implant failure, 7% deep infection, 3% each of >5 degrees varus and valgus malalignment, There were two cases of delayed union may be due to severe metaphyseal comminution both were treated with secondary bone grafting and protected partial weight bearing, united subsequently, there were 3 cases of non-union, two of which were found to be due to deep infection, managed with implant removal, wound debridement with application of local antibiotic beads and application of Ilizarov ring fixator.

The other case was a case of comminuted supra condylar fracture Muller type C3, which went for a complication of screw breakage and implant failure because of shorter plate length and severe metaphyseal comminution developed gap non-union which required exchange plating with a longer plate with bone grafting. Normal knee flexion is 140 degree. Acceptable knee flexion compatible with daily activity would be around 110 degree. In this study, at a mean follow-up of 10 months, the mean knee flexion was 109 degrees. The average

knee extensor lag was 2.4 degrees. Functional outcome at the end of 5 to 7 months (mean of 6 months) was assessed using NEER's scoring system. Results were excellent in 17 patients (57%), good in 8 (27%), fair in 2 (6%) and poor in 3 (10%). In our study, functional results are better than that of non-locking condylar plates and close to the functional results achieved in other LCP studies so are the rate of complications.

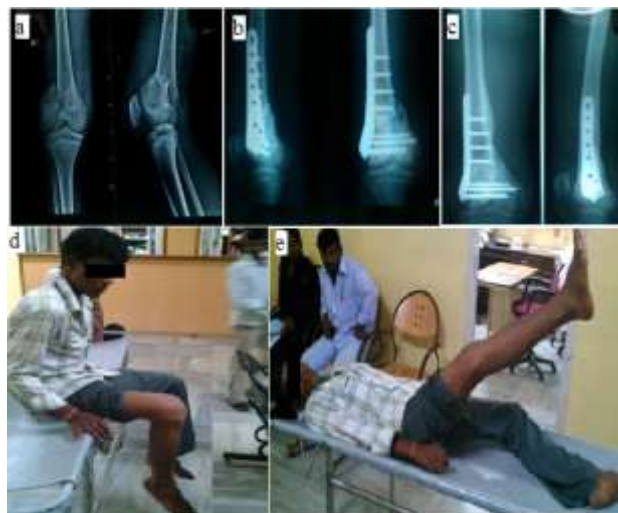

Figure 3: Case study. (a) Preoperative; (b) Immediate postoperative; (c) 6 months follow up (d) Knee flexion; (e) knee extension.

Table 7: Comparison studies of distal femur fractures.

Author	No. of cases	Open # (%)	Age	Follow up (in months)	ROM degrees	Union (in weeks)	Bone graft (%)	Deep infection (%)	Implant fail (%)	Malalignment degree
Yeap et al ¹¹	11	36	44	9.7	1-107	18	18.2	9	9	
Hoffmann et al ¹³	243	40	54	23.3	1.4 - 114	N/A	18	7.2	9.9	7
Kolb ⁷	41	8	51	9.5	3	1	5	2	-	5
Our study	30	0	40	10	3-109	16.6	26.6	6.6	3	6.6

CONCLUSION

In conclusion, the LCP condylar plate represents an evolutionary approach to the surgical management of distal femoral fractures, but it does not completely solve the problems of non-union and mal-union. Locking Compression Plate is an important armamentarium in distal femur fracture fixation, especially when fracture is severely comminuted and in situations of osteoporosis, where system provides good angular stability, hence early mobilization is allowed and knee stiffness is avoided. However as some of the other recent studies show more incidence union related problems and poor functional outcomes, a more comprehensive study with longer follow up periods is essential to throw more light into the

advantages, complications and attention to the long term outcomes.

Funding: No funding sources

Conflict of interest: None declared

Ethical approval: The study was approved by the institutional ethics committee

REFERENCES

- Arneson TJ, Melton LJ 3rd, Lewallen DG, O'Fallon WM. Epidemiology of diaphyseal and distal femoral fractures in Rochester, Minnesota, 1965-1984. Clinorthop. 1988;234:188-94 .

2. Martinet O, Cordey J, Harder Y, Maier A, Bühler M, Barraud GE. The epidemiology of fractures of the distal femur. *Injury.* 2000;31(3):62-3.
3. Schandelmaier P, Partenheimer A, Koenemann B, Grun OA, Krettek C. Distal Femoral Fractures and LISS Stabilization. *Injury.* 2001;32:55-63.
4. Michael Z, Mohit B, Marek DJ, Cole PA, Kregor PJ. Operative treatment of acute distal femur fractures: systematic review of 2 comparative studies and 45 case series (1989-2005). *J Orthop Trauma.* 2006;20:366-71.
5. Kregor PJ, Stannard J, Zlowodzki M, Cole PA, Alonso J. Distal femoral fracture fixation utilizing the Less Invasive Stabilization System (L.I.S.S.): The technique and early results. *Injury.* 2001;32:32-47.
6. Schutz M, Muller M, Regazzoni P, Hontzsch D, Krettek C, Van der Werken C, et al. Use of the Less Invasive Stabilization System (LISS) in patients with distal femoral (AO33) fractures: a prospective multicenter study *Arch Orthop Trauma Surg.* 2005;125(2):102-8.
7. Kolb K, Grutzner , Koller H, Windisch C, Marx F, Kolb W. Condylar plate for treatment of distal femur fractures : a long – term follow - up study. *Injury.* 2009;40(4):440-8.
8. Davison BL. Varus collapse of comminuted distal femur fractures after open reduction and internal fixation with a lateral condylar buttress plate. *Am J Orthop.* 2003;32(1):27-30.
9. Heather V, Theresa H, John S. Failure of LCP condylar plate fixation in the distal part of the femur. *J Bone Joint Surg.* 2006;88:846-53.
10. Neer CS, Gratham SA, Shelton ML. Supracondylar fractures of adult femur. *JBJS.* 1967;49(4):591-613.
11. Yeap EJ, Deepak AS. Distal Femoral Locking Compression Plate Fixation in Distal Femoral Fractures: Early Results. *Malaysian Orthop J.* 2007;1(1):12-7.
12. Henderson CE, Kuhl LL, Fitzpatrick DC, Marsh JL. Locking plates for distal femur fractures: is there a problem with fracture healing? *J Orthop Trauma.* 2011;25(1):8-14.
13. Hoffmann MF, Jones CB, Sietsema DL, Tornetta P 3rd, Koenig SJ. Clinical outcomes of locked plating of distal femoral fractures in a retrospective cohort. *J Orthop Surg Res.* 2013;8:43.

Cite this article as: Bachu S, Ramulu L. A study of surgical management of distal femoral fractures in adults using locking compression plate. *Int J Res Orthop* 2017;3:253-8.