

Original Research Article

Randomised prospective comparative analysis of functional outcome of hemiarthroplasty with cemented bipolar and uncemented unipolar prosthesis

Hashmukh S. Varma, Sachin Upadhyay, Nuthan Jagadeesh*

Department of Orthopedics, NSCB Medical College, Jabalpur, Madhya Pradesh, India

Received: 12 March 2020

Revised: 31 March 2020

Accepted: 01 April 2020

***Correspondence:**

Dr. Nuthan Jagadeesh,

E-mail: nuthanjagadeesh@yahoo.com

Copyright: © the author(s), publisher and licensee Medip Academy. This is an open-access article distributed under the terms of the Creative Commons Attribution Non-Commercial License, which permits unrestricted non-commercial use, distribution, and reproduction in any medium, provided the original work is properly cited.

ABSTRACT

Background: Hemiarthroplasty (HA) has been considered as better treatment modality in elderly patients compared to internal fixation because of better outcome, early mobilization, associated with HA. However, there is inadequate evidence to support the choice between unipolar or bipolar HA. The aim of this study was to compare the outcome of uncemented unipolar with the cemented bipolar prosthesis in geriatric patients especially in an Indian setup.

Methods: Sixty five patients above 60 years of age and displaced fracture of the femoral neck were randomly allocated to treatment by either unipolar or bipolar HA, in the Department of Orthopaedics, between September 2014 and October 2016. Functional outcome was assessed and compared using Harris hip score and radiological parameters with X-ray with serial follow-up at 3, 6, 12 and 18 months.

Results: The two groups of patients with mean age of 68 ± 7 years in bipolar group and 68 ± 6 years in unipolar group did not differ in their pre-injury characteristics and perioperative parameters. The mean Harris hip score in cemented bipolar and uncemented unipolar groups was 86 ± 8.53 and 85.27 ± 10.09 , respectively ($p=0.687$). There were no differences in functional activities either group.

Conclusions: Based on the results of our study, there appears to be no statistical difference between the two groups, uncemented unipolar HA and cemented bipolar HA in terms of functional outcome and various complications discussed. Uncemented unipolar HA is cheap, less technically demanding, suitable in fragile old patients.

Keywords: Bipolar hemiarthroplasty, Unipolar hemiarthroplasty, Harris hip score, Neck of femur

INTRODUCTION

The fracture neck of femur even though can occur in any age, it mainly occurs in elderly population. Important factors to consider in choosing any treatment modality are intrinsic, namely age, general condition, type of fracture; and extrinsic, that is availability of facilities and socio-economic status of the patient, occupation. Non operative treatment has very limited indications in terminally ill non ambulatory patients. Surgical treatment commonly available are internal fixation and hemiarthroplasty (HA)

and total hip arthroplasty.¹ Though internal fixation is good modality of treatment in young patients, in elderly population hemiarthroplasty is better owing to early mobilization, less revision rate and lack of complications associated with internal fixation like non-union, osteonecrosis etc.²⁻⁵

There are two types of hemiarthroplasty unipolar and bipolar. The question that's most debatable is whether to use unipolar or bipolar prosthesis. Bipolar HA has said to have theoretical advantage of better mobility and less

acetabular wear and tear, better functional outcome and has disadvantage of risk of polyethylene wear that may contribute to mechanical loosening over time.⁵ Even with development of the bipolar endoprosthesis, the unipolar prosthesis remains one of the commonly used hip prosthesis in India. The Austin Moore prosthesis (AMP) produces excellent functional outcome. Though thigh pain and protrusio acetabuli have been associated with this device in younger patient but on older high risk patients with comorbidities, these may not be that significant. When the cost of treatment and potential complications of recent hip prosthesis are considered, it appears wise to limit the use of bipolar and total hip arthroplasties to patients who are most likely to benefit from them. In fact, many patients may not survive long enough after their hip fracture to justify procedures with higher risk and higher cost. And in the Indian scenario where squatting is important, it is imperative that AMP has its place where squatting is possible as compared to bipolar. A recent systematic review and meta- analysis of 10 RCTs including 1, 190 patients by Jia et al demonstrated that bipolar HA was associated with similar outcomes in hip function, hip pain, quality of life while with a higher cost compared with unipolar HA.⁶ Our study is a randomised prospective comparative analysis of functional outcome of hemiarthroplasty with cemented bipolar and uncemented unipolar prosthesis and also to look for various complications associated with hemiarthroplasty.

METHODS

This was prospective study conducted on 65 patients admitted with fracture neck of femur who fit into the inclusion criteria in the Department of Orthopaedics, NSCB Medical College, Jabalpur between September 2014 and October 2016. Patients included are elderly patients 60 years and above of either sex with fracture neck of femur, adults with intracapsular fracture neck of femur where the feasibility of osteosynthesis is negligible and, patients who are available for minimum follow up of 6 months. Patients excluded are one with pathological fracture neck of femur, one with severe comorbidities and thus are unfit for surgery, one with impaired cognitive function. Institutional ethical committee clearance taken for the study.

Patients from the inclusion criteria were subjected to history taking, through physical examination and later evaluated for any radiological (X-ray of pelvis with both hip and lateral views) evidence of fracture neck of femur. The cohort was randomized based on odd/even number. 65 patients were divided into two groups with odd numbers (group A) assigned to uncemented unipolar prosthesis and even number (group B) with cemented bipolar prosthesis.

The data thus obtained was compiled using Microsoft Excel sheet and transferred and analyzed using Graph pad prism version 8. Descriptive statistics was used summarize the data. The data was analyzed using proportion test, Chi-

Square test. Microsoft Word and Excel was used to generate graphs, tables etc.

Preoperative planning

Good quality radiographs to assess the extent, type of the fracture was taken. Selection of size of prosthesis assessed looking at the normal side. Patient was fully explained about the nature of the fracture, its etiology, the anaesthesia, the planned operation; its need, the nature and benefits, possible pre or intra or post-operative complications, blood transfusion, the possible postoperative limitations necessitating a modification his life style and occupation, and the study involved; in his own language. An informed, valid, explained, documented, signed and witnessed consent taken from all patients undergoing surgery. Sensitivity testing was done routinely for xylocaine and preoperative prophylactic antibiotic was started 24 hrs before surgery.

Approach used: Standard Moore's approach (Figure 1).

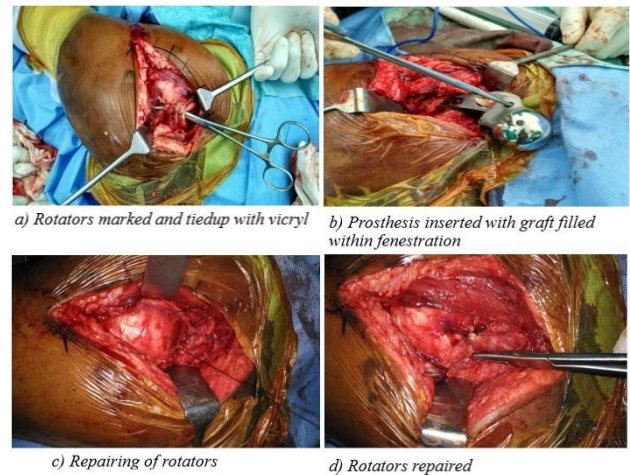


Figure 1 (a-d): Surgical technique used in hemiarthroplasty.

All the procedures were performed under spinal anesthesia. All operations were performed by the senior author or under his direction. The procedure was carried in the lateral decubitus position. Adductor tenotomy was done whenever necessary. Scrubbing, painting and draping of operative site was done. Standard Moore's approach was used. After skin incision, subcutaneous tissue was excised, deep fascia is cut. The gluteus maximus muscle was split, trochanteric bursa is excised. External rotator muscles are identified tied with vicryl suture are divided close to the inter-trochanteric ridge. A 'T' shaped incision is made over the posterior capsule of the hip. The femoral head was extracted using head extractor. Head size was measured using templates. The neck osteotomy was done using an osteotomy template of either unipolar or bipolar prosthesis, cut made using oscillating saw. An adequate amount of calcar just above the lesser trochanter was left as guided by the template. Entry point was

accessed using a canal finder. Serial broaching was done upto desired depth of the medullary canal. The graft from extracted head was inserted into the proximal fenestrations of the prosthesis and at calcar area. This is for the mechanical stability once it gets healed and thus making it a self-locking device. Graft at calcar area will help in maintaining the femoral offset and restoration abductor lever arm. The prosthesis was finally insert to its optimal position keeping 15 degree of ante-version. In case of bipolar prosthesis, neck length is choose wisely according to template or by serial trails, if the neck is left excessively long, reduction may be difficult and pressure on acetabular cartilage is increased, prostheses should be inserted so that the distance between the greater trochanter and center of the femoral head is restored, this will restore the length of the abductor mechanism and thereby help to prevent postoperative limp. Cementing was done with CMW-3 cement with standard setting time. The prosthesis was reduced. The stability was checked in full extension with external rotation to 45 degrees, flexion to 100 degrees, adduction to 20 degrees and internal rotation to 60 degrees. Special care is taken to repair capsule and tied up rotators. The gluteus maximus was repaired. The wound closed in layers over negative suction drain. All patients were given low molecular weight heparin preoperatively and for eight days postoperatively. Cloxacillin 2 gram was given preoperatively, followed by two additional doses during the first 24 hours.

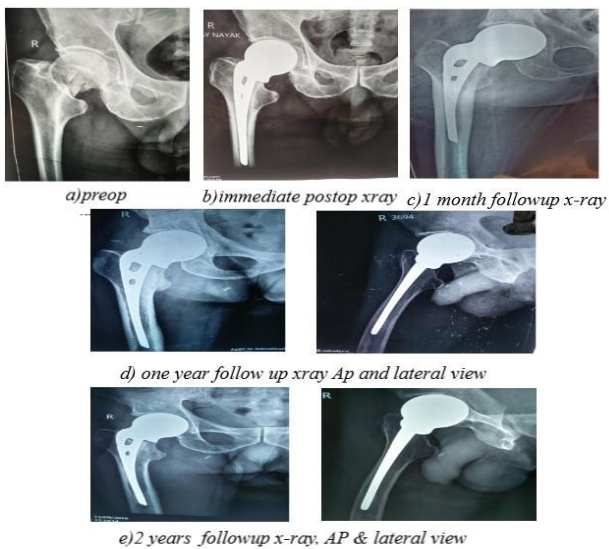

Figure 2 (a-e): 65 year old male with fracture neck of femur right under went unipolar hemiarthroplasty. Serial follow-up X-rays at various time intervals.

Post operative care

Patient advised to rest in supine position with both limbs slightly abducted with a pillow or a box is put transversely below ipsilateral knee joint. Patient is ambulated with knee mobilisation then partial weight bearing using standard walker with both limbs in abduction from 2nd post operative day. Postoperative physiotherapy is done i.e.

static quadriceps exercise, ankle and toe mobilization, pelvic lift exercises, abductor strengthening exercises is given. Postoperative HHS is assessed and patient is discharged with advice to follow up 6 weeks after surgery or earlier in case of a problem.

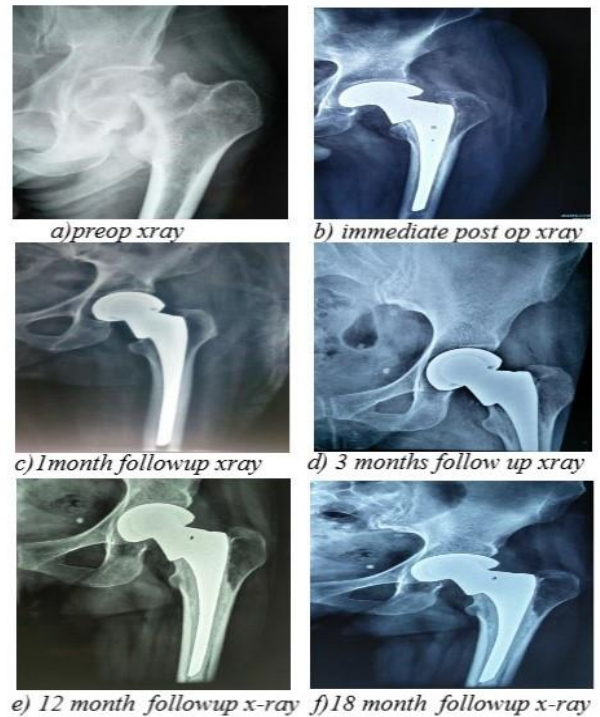

Figure 3 (a-f): 62 year old male with fracture neck of femur right under went cemented bipolar hemiarthroplasty.

Serial follow-up X-rays at various time intervals.

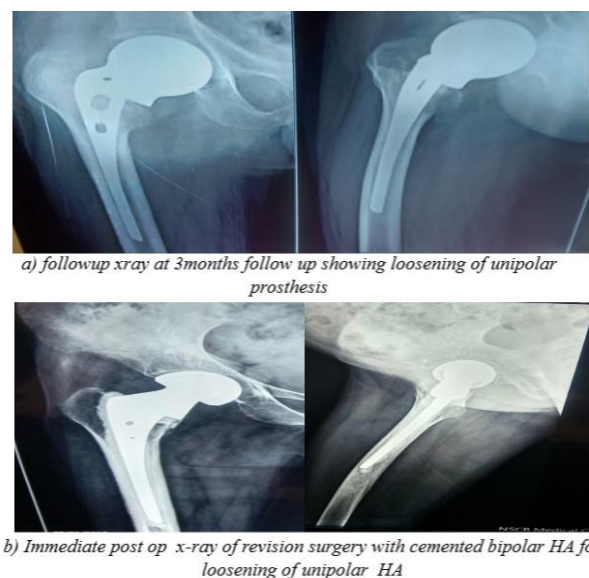

Figure 4 (a and b): 60 year old male with fracture neck of femur right under went uncemented unipolar hemiarthroplasty.

Serial X-rays showing loosening of unipolar prosthesis and subsequent revision with cemented bipolar hemiarthroplasty was done.

Follow up

Patients were advised to attend orthopaedic OPD for follow up at four weeks, three months, six months, one year and two years after surgery. Minimum follow up period of six months was required to be included. Clinical and functional improvement was assessed using Harris hip score (HHS). Pain was measured in terms of visual analog scale (VAS) pain score. Radiological parameters were assessed on X ray films (AP and lateral view). Complications were assessed with patient’s complaints, clinical examination, radiological and laboratory investigations.

RESULTS

In our randomised study comparison between 33 cases of cemented bipolar hemiarthroplasty and 32 cases of unipolar hemiarthroplasty for femoral neck fractures in elderly patients over a mean follow up period of 13.69±6.33 and 11.09±5.22 months and mean age of 68.01±6.0 and 68±7 years respectively has been shown.

In our study the intracapsular fracture of femoral neck were found to be equally distributed among males and females. But majority of patients to rural areas i.e. 21 out of 32 unipolar and 20 out of 33 in bipolar group. This is important as majority of population in India (rural-urban distribution: 68.84% and 31.16% census 2011) are from rural setup and thus our study is more suited for Indian scenario. About 83% had some or the other comorbidities like hypertension, diabetes, cardiac and abnormalities etc but most of patients belong to ASA score 2 or 3. About 86.2% of patients were admitted to hospital only 3days after injury, with 41.5% admitted between 3-10 days and 43.1% admitted between 10-30 days, this again can be attributed to most patients belonging to rural areas where sufficient facilities are not available to make diagnosis.

In our study, 93.8% of the fractures in our trail belonged to displaced fractures of Garden type III and IV. Depending on the anteroposterior radiographs available, we could group 4 patients (6%) into type II, 41 patients

(63.1%) into type III and 20 patients (30.8%) into Garden type IV. About 84.6 percent of our patients had fractures due to trivial fall on ground owing to osteoporosis in elderly.

In our trail, the type (subcapital or transcervical) or the displacement (Garden’s III and IV), mode of injury, duration between injury and admission are not taken as the criteria to choose the procedure for the management of fracture neck of the femur.

There were no differences in the intraoperative blood loss or need for blood transfusions on comparing the randomisation groups. Duration of surgery was lower in unipolar group compared bipolar group. This can be attributed to time taken for cementing. There was no abnormalites in immediate post operative period interms of distal neurovascular status, iotrogenic periprosthetic fracture, deep vein thrombosis, no mortality occurred in between operation and discharge. All the patients in both group were made to walk with a walker within 3 to 5 days of postoperative period.

There was no difference in functional outcome assesed with mean HHS and VAS pain score. Mean HHS was 85.2±10.09 among uncemented unipolar HA group and 86.00±8.52 cemented bipolar HA group. We also assesed mean HHS score considering the locality, sex and found no difference in HHS scores among rural or urban people (Figure 5, Table 2 and 3). Majority of the patients in both groups had excellent or good mean HHS score (Figure 5).

In our trail none of patients had dislocation, subsidence of implant, periprosthetic fracture, or acetabular erosion in either group (Table 4). One patient in unipolar group had deep implant infection. Patient was diabetic, unattended and was managed with debridement of wound with higher antibiotics. Though infection subsided patient continued to have poor HHS scores and VAS score. One Patient in unipolar had loosening of implant which required revision with cemented bipolar at 6 months follow up. There was no cement related complications amongst cemented bipolar group.

Table 1: Distribution and mean HSS according to locality of patient.

Locality	Distribution (%)	Mean HHS	Standard deviation	Minimum	Maximum
Rural	63	85.59	9.68	45	100
Urban	37	85.68	8.76	64	100

Table 2: Comparing functional outcome of patients undergoing uncemented unipolar HA and cemented bipolar HA using HSS based on sex.

	Unipolar		Bipolar					
	Mean HHS at 12 months	Standard deviation	Minimum	Maximum	Mean	Standard deviation	Minimum	Maximum
Male	94.75	2.8	88	97	94.81	2.08	93	97
Female	95.75	1.47	88	97	92.24	3.36	87	97

Table 3: Comparing functional outcome of uncemented unipolar HA and cemented bipolar HA using HHS in various time interval.

HHS	Unipolar				Bipolar				t test	P value
	Mean	Standard deviation	Min	Max	Mean	Standard deviation	Min	Max		
Preop	0	0	0	0	0.39	2.26	0	13	0.98	0.33
On discharge	72	7	45	83	74	6	62	83	1.43	0.16
1 month	81	7	54	87	83	4	74	87	1.32	0.19
3 months	86	6	62	93	88	5	78	93	1.39	0.17
6 months	90	6	68	97	92	3	87	97	1.78	0.06
12 months	94	3	87	97	95	2	93	97	0.86	0.39
18 months	96	1	93	97	95	2	93	97	1.25	0.23
24 months	98	2	97	100	-	-	-	-	-	-

Table 4: Comparing complications of uncemented unipolar HA and cemented bipolar HA.

Complications	Uncemented unipolar	Cemented bipolar	Total
Thigh pain	5	2	7
Infection	1	0	1
Loosening	1	0	1
Dislocation	0	0	0
Acetabular erosion	0	0	0
Subsidence	0	0	0

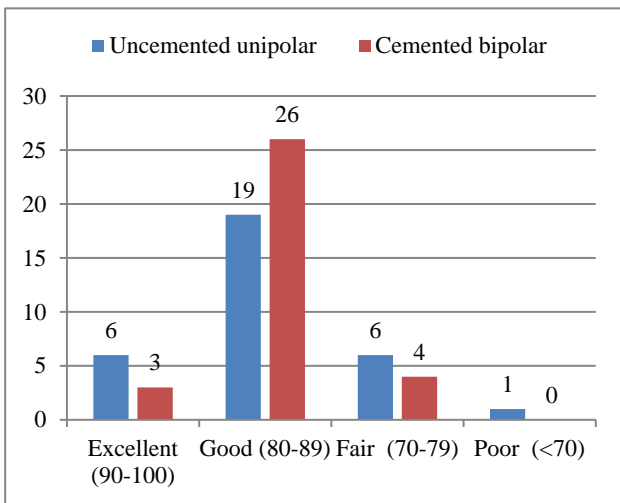


Figure 5: Comparison of functional outcome based on HHS.

Thigh pain was assessed as a separate entity, and was found in 5 patients among unipolar group when compared to 2 patients in cemented bipolar group but this was statistically insignificant with 'p' value of 0.214. Among 5 patients with thigh pain among unipolar group, 1 was patient who also had deep infection and 1 was patient who also had complication of loosening of implant.

There was one death in unipolar and two death among cemented bipolar group. All three patients completed minimum 6 months follow up before death and HHS before death was good (all between 80-89). So, the cause of death could be attributed to the comorbidities they had.

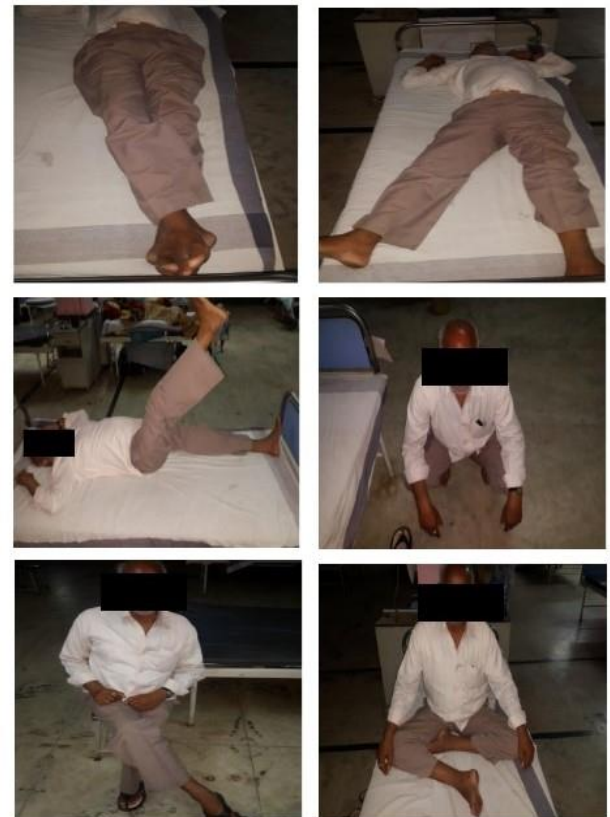

Figure 6: Clinical photographs of patient who underwent unipolar hemiarthroplasty performing various hip movements, squatting and sitting cross leg at 2 years follow-up.

DISCUSSION

In elderly patients with displaced femoral neck fracture, if HA is chosen, it is not clear if unipolar or bipolar ought to be picked. By and large, the outcomes in our study demonstrate that hemiarthroplasty performed with uncemented unipolar or cemented bipolar heads is safe and reliable method of treatment of femoral neck fracture in elderly with excellent HHS majority of patients.^{7,8}

The goal of this study was to compare functional outcome in uncemented unipolar with that of cemented bipolar hemiarthroplasty as treatment of femoral neck fracture in elderly in a randomized setting with short term follow-up. Consideration was taken to minimize the internal bias in the study. The groups that we analyzed were fundamentally the same at baseline, with equal distribution with respect to age, sex, type of fracture according to Garden's classification, locality. Here we stress on fact that majority of patients belonged to rural areas of central India i.e. 21 out of 32 in unipolar and 20 out of 33 in bipolar group. This is important as majority of general population in India (rural - urban distribution: 68.84% and 31.16% census 2011) are from rural setup and the distribution according to locality in our study is similar to distribution in general population. We also stress that patients coming into our department have a large coverage with patients from different parts of central India. Thus, our study is more representative of Indian scenario and can be generalized to general population. This distribution among rural and urban areas have not been given significance in any of the studies. The outcome was assessed with utilization of the HHS. Patients were randomly allotted either unipolar or bipolar group. Decision whether uncemented unipolar or cemented bipolar was influenced by Dorr classification of proximal femur and intraoperative finding of canal characteristics during rasping of canal, with Dorr's type A & B operated with uncemented unipolar group and Dorr's type C operated with bipolar group. There were no differences between two groups in terms of perioperative findings, except that duration of surgery was less in unipolar group which is attributed to non-cementing and it was statistically insignificant. All the patients followed a similar post-operative rehabilitation protocol that consisted of early knee mobilization and partial weight bearing on 2nd post operative day and full weight bearing by 6 weeks along with abductor strengthening exercises. The present study was a short term follow-up and relied on functional, clinical and radiological outcome.

Calder et al, randomized study comparing unipolar prosthesis and the bipolar Monk prosthesis in patients more than 80 years. In a 2-year follow-up, the main statistically significant difference they found was that patients with unipolar prostheses will probably come back to their preinjury functional state than patients with bipolar prostheses.⁷ Hedbeck et al Studied unipolar versus bipolar hip hemiarthroplasty: a prospective cohort study on 830 consecutive hips patients with femoral neck fractures. In

this study, the prosthetic design (uni-or bipolar) had no influence on the risk for reoperation or dislocation, nor had the age, gender or the surgeon's experience.⁵ Cornell et al. distributed a 48-patient series in which same femoral stem was utilized and just distinction between the prosthesis head outline. Patients with bipolar prostheses improved on walk tests and had better range of movements at 6 months; however, the patient-arranged hip scores did not vary at 6 months between the unipolar and bipolar groups, a finding which coincides with our study.⁸ Raia et al analyzed the adequacy of unipolar versus bipolar hemiarthroplasty in elderly patients with displaced femoral neck fractures in terms of quality of life and functional outcomes.⁹ They found no contrast between the groups when assessing the blood loss, length of hospital stay, death rate and number of dislocations, post-operative complications, or ambulatory status at 1 year in their 115 patients group. Kanto et al reported 175 cases of uni- and bipolar hemiarthroplasty with a modern cemented femoral component provides elderly patients with displaced femoral neck fractures with equal functional outcome and survivorship at medium- term follow-up.¹⁰ Jia et al studied 1190 patients were identified unipolar versus bipolar hemiarthroplasty for displaced femoral neck fractures: a systematic review and meta- analysis of randomized controlled trials.⁶ Total of 10 RCTs including 1, 190 patients were identified. They demonstrated that bipolar hemiarthroplasty was associated with similar outcomes in hip function, hip pain, quality of life while with a higher cost compared with UH.

In our outcomes, we did not have any distinctions in terms of functional outcome with no significant statistical difference in mean HHS, VAS pain score and also HHS at 6, 12 and 18 months. Baker et al reported acetabular erosion in 21 out of 32 patients treated with a unipolar HA after a mean follow-up of 39 months, giving an overall rate of acetabular erosion of 66%.¹¹ We followed the same criteria of grading followed by Baker, but found no cases of acetabular erosion either two groups in our follow up. Loosening of implant is one of complication seen due to improper prosthetic setting, reaming of canal with reamer of improper size, tissue reaction, improper selection of patient (Dorr type 3 having unipolar HA). In our study, one patient in unipolar group had loosening of the implant. This was mainly due to using of reamer of improper size, revision surgery with cemented bipolar was done in this patient as he had persistent pain. Dislocation following hemiarthroplasty was due to the disruption of the posterior stabilizers while performing the posterior approach, ultimately leading to failure and dislocation. Chan et al stated posterior approach is associated with higher dislocation rate.¹² Sikorski et al reported dislocation rates of 10% in the unipolar prosthesis.¹³ In our study, there were no incidence of dislocation of prosthesis in either group. This can attributed to special care taken in maintaining 15° anteversion during insertion of prosthesis and in repairing in capsule and rotators during operation. There was no incidence of subsidence of prosthesis or periprosthetic fracture in either group. Thigh pain was assessed separately in follow ups. Lunceford Jr et al listed

the following causes for pain: infection, improper prosthetic seating, metallic corrosion and tissue reaction, improper sized femoral head, contractures, periarticular ossification, toggle or acetabular wandering and redundant ligamentum teres.¹⁴ In our study, thigh pain was higher in unipolar group i.e. 5 patients compared to 2 in bipolar group but was statistically non-significant (p value 0.24). Out of 5 patients with thigh pain in unipolar group, 2 patients had other associated complication like loosening and infection. This substantiates the points given by Lunceford who said pain may not always be due to the fault of implant.¹⁴ One patient in unipolar group had deep implant infection. This patient was diabetic from old age home with no attenders to take care of him, and was managed with debridement of wound with higher antibiotics. Though infection subsided patient continued to have poor HHS scores and VAS score. There was one death in unipolar and two death among cemented bipolar group but this was statistically insignificant (p value 0.573). All three patients completed minimum 6 months follow up before death and HHS before death was good (all between 80 to 89). So, the cause of death could be attributed to the comorbidities they had. Limitations of this study was short term follow up, small sample size of 65 patients, comparing cemented prosthesis with that of uncemented one.

CONCLUSION

Based on the results of our study, there appears to be no statistical difference between the two groups, uncemented unipolar HA and cemented bipolar HA in terms of functional outcome and various complications discussed before. Uncemented unipolar hemiarthroplasty is cheap, less technically demanding, takes less operative time and is suitable in fragile, old patients. Moreover, patients may not be exposed to potential harmful effects associated with cement. In an Indian scenario, where majority of patients are from a rural setup and lower socioeconomic background, it is imperative that unipolar hemiarthroplasty should be considered as a better option in treating displaced fracture neck of femur in elderly population.

Funding: No funding sources

Conflict of interest: None declared

Ethical approval: The study was approved by the institutional ethics committee

REFERENCES

- Holmberg S, Kalen R, Thorngren KG. Treatment and outcome of femoral neck fractures: An analysis of 2418 patients admitted from their own homes. *Clin Orthop Relat Res.* 1987;218:42-52.
- Rogmark C, Carlsson Å, Johnell O, Sernbo I. A prospective randomized trial of internal fixation versus arthroplasty for displaced fractures of the neck of the femur: Functional outcome for 450 patients at two years. *J Bone Joint Surg Br.* 2002;84:183-8.
- Søreide O, Mølster A, Raugstad TS. Internal fixation versus primary prosthetic replacement in acute femoral neck fractures: A prospective, randomized clinical study. *Br J Surg.* 1979;66:56-60.
- Sikorski JM, Barrington R. Internal fixation versus hemiarthroplasty for the displaced subcapital fracture of the femur: A prospective randomized study. *J Bone Joint Surg Br.* 1981;63:357-61.
- Hedbeck CJ, Blomfeldt R, Lapidus G, Törnkvist H, Ponzer S, Tidermark J. Unipolar hemiarthroplasty versus bipolar hemiarthroplasty in the most elderly patients with displaced femoral neck fractures: a randomised, controlled trial. *Int Orthop.* 2011;35(11):1703-11.
- Jia Z, Ding F, Wu Y, Li W. Unipolar versus bipolar hemiarthroplasty for displaced femoral neck fractures: a systematic review and meta-analysis of randomized controlled trials. *J Orthop Surg Res.* 2015;10:8.
- Calder SJ, Anderson GH, Jagger C, Harper WM, Gregg PJ. Unipolar or bipolar prosthesis for displaced intracapsular hip fracture in octogenarians: a randomised prospective study. *J Bone Joint Surg Br.* 1996;78:391-4.
- Cornell CN, Levine D, O'Doherty J, Lyden J. Unipolar versus bipolar hemiarthroplasty for the treatment of femoral neck fractures in the elderly. *Clin Orthop Relat Res.* 1998;348:67-71.
- Raia FJ, Chapman CB, Herrera MF, Schweppe MW, Michelsen CB, Rosenwasser MP. Unipolar or bipolar hemiarthroplasty for femoral neck fractures in the elderly? *Clin Orthop Relat Res.* 2003;414:259-65.
- Kanto K, Sihvonen R, Eskelinen A, Laitinen M. Uni- and bipolar hemiarthroplasty with a modern cemented femoral component provides elderly patients with displaced femoral neck fractures with equal functional outcome and survivorship at medium-term follow-up. *Arch. Orthop. Trauma Surg.* 2014;134(9):1251-9.
- Baker RP, Squires B, Gargan MF, Bannister GC. Total hip arthroplasty and hemiarthroplasty in mobile, independent patients with a displaced intracapsular fracture of the femoral neck. A randomized, controlled trial. *J Bone Joint Surg Am.* 2006;88:2583-9.
- Chan RN, Hoskinson J. Thompson prosthesis for fractured neck of femur. A comparison of surgical approaches. *J Bone Joint Surg Br.* 1975;57:437-43.
- Sikorski JM, Barrington R. Internal fixation versus hemiarthroplasty for the displaced subcapital fracture of the femur: a prospective study. *J Bone Joint Surg Br.* 1981;63:357-61.
- Lunceford Jr EM. Use of Moore self-locking Vitallium prosthesis in acute fractures of the femoral neck. *J Bone Joint Surg Am.* 1965;47:832-41.

Cite this article as: Varma HS, Upadhyay S, Jagadeesh N. Randomised prospective comparative analysis of functional outcome of hemiarthroplasty with cemented bipolar and uncemented unipolar prosthesis. *Int J Res Orthop* 2020;6:455-61.