

Original Research Article

Soft tissue allograft for primary anterior cruciate ligament reconstruction

Rahul P., Suraj H. P., Satish Shervegar, Abhilash Palla*

Department of Orthopaedics, M. S. Ramaiah Hospitals, Bengaluru, Karnataka, India

Received: 20 April 2017

Accepted: 04 May 2017

***Correspondence:**

Dr. Abhilash Palla,

E-mail: pallaabhilash@gmail.com

Copyright: © the author(s), publisher and licensee Medip Academy. This is an open-access article distributed under the terms of the Creative Commons Attribution Non-Commercial License, which permits unrestricted non-commercial use, distribution, and reproduction in any medium, provided the original work is properly cited.

ABSTRACT

Background: Arthroscopic ACL reconstruction has become one of the most commonly performed arthroscopic surgeries. In spite of extensive research on available autograft options, controversy still persists regarding the ideal graft. Allograft tendons usage in orthopedic operations has increased because of its advantages. This study was conducted to assess the functional outcome in patients undergoing ACL reconstruction with soft tissue allografts.

Methods: 15 patients with Anterior Cruciate Ligament injury presenting from 2012-2014 who underwent Arthroscopic ACL reconstruction with soft tissue allograft were the subjects of this Prospective study. Assessment of the involved knee was performed to obtain subjective measures of the clinical outcomes of the ACL reconstruction. All patients were followed up at regular intervals of 3 weeks, 6 weeks, 12 weeks, 6 months and 2 years.

Results: At the final follow up, the patients had an average Lysholm knee score of 85.60, Tegner score of 7.24 and IKDC score of 85.28. Knee flexion of $>120^{\circ}$ was achieved in $>80\%$ of patients and minimal laxity in 60% patients but no functional disability in any of them. No graft failures were noted.

Conclusions: Contrary to the fear of graft failure and complications associated with allograft construct for primary ACL reconstruction, allografts yield the same clinical outcome as autografts with the advantages of reduced operative time, no donor site morbidity, preservation of native hamstring tendons, faster and comfortable rehabilitation. Allografts are a good alternative to autografts for primary ACL reconstruction.

Keywords: Anterior cruciate ligament reconstruction, Allografts, Lysholm score, Tegner score, IKDC score

INTRODUCTION

Arthroscopic anterior cruciate ligament (ACL) reconstruction has become one of the most commonly performed surgeries in orthopaedics. Greater participation in sporting and recreational activities by the general population continues to expose more individuals to the risk of ACL rupture. The evolution of ACL reconstructive surgery has been from open surgery to arthroscopy-assisted to current all-arthroscopic techniques. The science and technique of ACL reconstruction has expanded over the years. There are many options in the armamentarium of the surgeon treating these injuries regarding graft choice, fixation, and surgical technique.

An ideal graft should be easy to harvest with minimal donor site morbidity, have the strength of the native ACL, incorporate quickly and allow rigid fixation to enable early mobilization and rehabilitation.

Historically, patellar tendon autograft was considered to be the gold standard. However, associated problems of donor site morbidity has compelled many surgeons to use hamstring tendon autografts.^{1,2} Quadrupled hamstring autografts (semitendinosus and gracilis) have been shown to have the highest tensile strength and excellent clinical results. However, disadvantages include decreased knee flexion and hip extension strength, which can be detrimental to athletes who rely on knee flexion strength

beyond 90 degrees (e.g. sprinters, wrestlers, gymnasts, martial arts practitioners).³ Furthermore, hamstring strength has been shown to be protective of ACL reconstruction by way of the ACL-hamstring reflex arc. Harvesting the semitendinosus and gracilis tendons result in disruption of this arc and a decrease in the protective effect of the hamstrings on the ACL.⁴

Surgeons usually prefer autograft over allograft because of ready availability, decreased cost, and faster graft incorporation and to avoid the risk of disease transmission associated with the use of allograft.⁵

Allograft usage in orthopedic operations has increased significantly over the last 2 decades.⁶ The potential drawbacks of using autografts for ACL reconstruction has led to increased usage of allografts.^{7,8} However, allografts have their own drawbacks, such as disease transmission, slower incorporation, possible immunologic reaction, finite supply, tunnel expansion, inferior biomechanical strength, possibly increased failure rate and cost.⁹ Thus, they have their own unique risks and disadvantages that the surgeon and patient must consider as part of the informed consent.

Allografts for ligament reconstruction have been mainly used in cases of multi-ligament injury and revision ACL reconstruction. There are no studies till date among Indian population as per our knowledge regarding the use of allografts for primary ACL reconstruction.

The purpose of this study is to evaluate the clinical and subjective outcome of allografts in primary ACL reconstruction.

METHODS

Patient criteria

This Prospective study was conducted in a tertiary care hospital. 15 adult male patients, with isolated ACL tear established clinically and radiologically between 2012 and 2014 were included in the study.

The exclusion criteria were patients 1) with multi-ligament injuries 2) with previous ligament injuries to the primary or contralateral knee requiring reconstructive surgery (3) requiring a concurrent meniscal allograft, osteotomy or major cartilage restoration or resurfacing procedures (4) with ipsilateral or contralateral osteoarthritic knee.

Preoperatively, the available graft options, merits and demerits of allograft, source of the allograft and possible complications were thoroughly explained to the patients.

Written consent was obtained prior to surgery, which included the consent for procedure and consent for the use of allograft and for inclusion in the study. Thorough clinical examination helped rule out associated injuries.

Mode of injury was documented. The preoperative Tegner activity level, Lysholm knee and IKDC scores were documented.

Graft

Allografts were obtained from M S Ramaiah Tissue Bank. The same technique of harvest and preservation was followed for all the grafts (Figure 1). The grafts were non irradiated and fresh frozen.

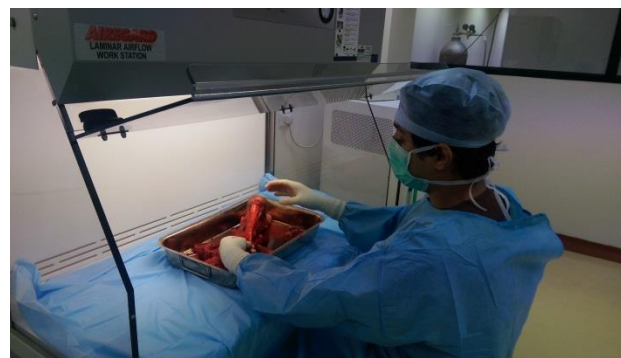


Figure 1: Tendoachillis allograft harvest.

Surgical technique

All the patients were operated by the same senior surgeon and his team.

The allograft was thawed for at least 30 mins following which the vacuum seal was opened and the tendon washed with 2liters of normal saline and 80mg of Gentamicin. Ends were whip stitched with a no. 2 non-absorbable Ethibond suture material and the graft size was measured (Figure 2).



Figure 2: Allograft whipstitched and measurement.

Under suitable anaesthesia, Diagnostic arthroscopy was performed. The remnants of ACL were shaved as required for better visualisation. The knee was flexed to

around 90°, tibial foot print was identified, ACL tibial guide was placed through the anteromedial portal and a tibial aperture entry point was made around 5-8mm medially along the line from the posterior margin of the anterior horn of lateral meniscus to medial tibial spine. Tibial tunnel equal to the size of the graft diameter was drilled over a guide pin. The femoral tunnel was drilled over a guide pin, 7-8 mm anterior to the posterior margin of the lateral femoral condyle at the 10 o'clock position for right knee and 2 o'clock position for left knee. Once the position of the femoral tunnel has been confirmed, tunnel equal to the graft diameter was drilled. An Ethibond loop of no.2 was passed through both tunnels to help the passage of graft construct. Adequate length of graft was passed into the femoral tunnel and titanium interference screw of appropriate thickness and length was placed outside-in along the outer femoral cortex followed by tibial fixation. The knee was examined for any signs of impingement and stability was confirmed (Figure 3). Total duration of surgery was noted in all cases.

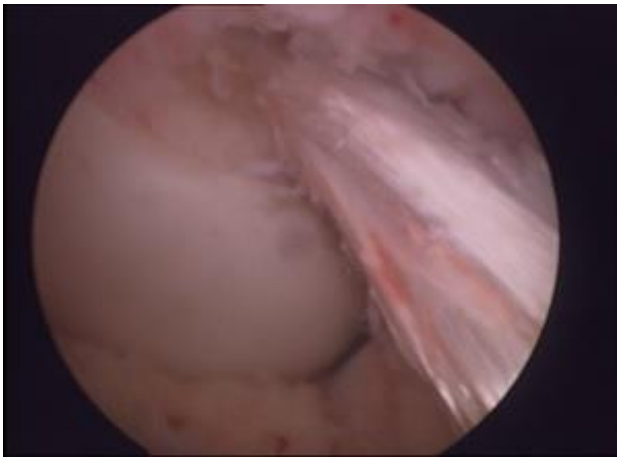


Figure 3: Arthroscopic view of reconstructed ACL.

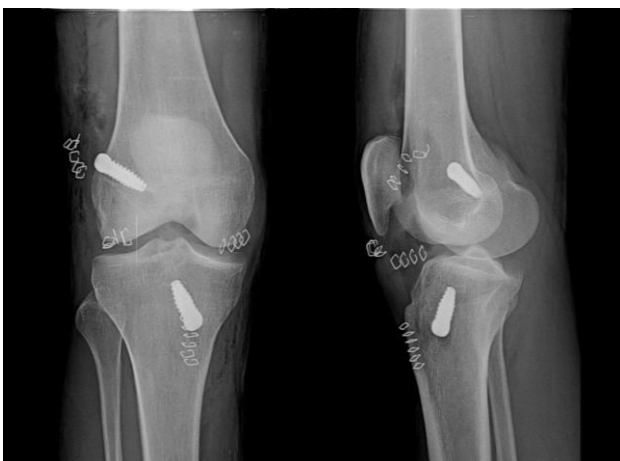

Figure 4: Postoperative X-ray.

Immediate postoperative X-rays were taken to assess the fixation parameters (Figure 4).

Postoperative management

Post-operative dressings were debulked on the second post-operative day and the wound was examined for any discharge, gaping, redness or any other signs of infection. Postoperative radiographs were obtained. Patients were started on immediate knee range of motion exercises, static and dynamic quadriceps and hamstring strengthening exercises. Knee flexion of at least 90° by the end of first week and 120° by the end of second week was aimed at. Patients were allowed walker assisted weight bearing as tolerated. Patients were followed up at regular intervals.

RESULTS

All 15 patients operated by allograft construct meeting the inclusion and exclusion criteria were serially followed up to 2 years. Examination findings, Lyshom score, Tegner activity score and IKDC score were documented at 3 weeks, 6 weeks, 12 weeks, 6 months and 2 years post operatively. The data thus recorded was analysed and conclusions were drawn.

Table 1: Age distribution.

Age	No. of patients
<20 years	0
21-30 years	11
31-40 years	3
>40 years	1
Mean age	28.66 ± 7.2

The principle findings of the study are as follows:

Age distribution of the patients is outlined (Table 1) and the mean age of patients was 28.66 years. Road traffic accidents were the commonest mode of injury in our study. Patients attended regular follow-ups as per the protocol and none were lost till final follow-up. All the patients had exclusive ACL injury with no meniscus or collateral ligaments damage. Anatomical single bundle reconstruction was performed in all patients. The average duration for the surgical procedure was 1 hour 17 minutes. In our study, 9 (60%) patients were right sided and 6 (40%) patients were left sided. We did not face any mishandling problems of the allograft from collecting it from the tissue bank till incorporation into the recipient.

We did not have any post-operative infections or graft rejections. Patients were comfortable without much pain; hence they were compliant for physiotherapy protocols from the immediate postoperative day. No cases of blowout fractures, failure of fixation or arthrofibrosis were noted. No disease transmission to the recipients through graft was noted.

At 2 years of follow-up, 80% (12 patients) of the patients had knee flexion range of >120°. Joint laxity was

significant where 60% of the operated knees were positive for grade 0 anterior drawer tests and Lachman's test. One patient had grade 1 Lachman laxity. In spite of this, none of the patients had any episodes of instability and had no functional disability in performing their daily activities. No patient needed a revision surgical procedure. We did not have any patients were from athletic or sports background and hence extreme range of motion or severe activity levels were not assessed. The patient activity level postoperatively was very much in comparison to the preoperative status (Table 2). The activity scores were tabulated (Table 3).

Table 2: Average preoperative scores.

Lysholm score	55.4
Tegner score	4.86
IKDC score	53.66

Table 3: Average postoperative scores.

Follow-up period	Lysholm score	Tegner score	IKDC
3 weeks	46.26	1.06	48.07
12 weeks	58.33	3.33	57.54
6 months	68	4.30	70.04
2 years	85.6	4.50	85.28

A significant improvement in the Lysholm score and IKDC subjective knee evaluation score postoperatively was observed when compared to preoperative status. Tegner activity score at the end of 2 years was comparable to the pre injury level.

DISCUSSION

Literature search reveals that ACL injury is most predominantly sports related.¹⁰ Increase in athletic activity in people to maintain adequate fitness levels is pushing more and more people into sports and thus is leading to an increase in sports related injuries.¹¹ However, in our study in the Indian scenario all the cases were because of road traffic accidents (two wheeler accidents).

Technological advancement has proved Arthroscopic ACL reconstruction to be the procedure of choice for treatment of ACL injuries. There has been a dilemma with regards to the best graft to be used. A gradual shift has been noted from the historically considered "gold standard" Bone patellar tendon autograft to Hamstring autograft which have shown comparable clinical results as BPTB grafts.

There has always been a look out for other graft choices which would overcome the problems associated with the Hamstring autograft (donor site morbidity, disruption of the ACL hamstring protective reflex arc) which has led

surgeons to consider using allograft constructs for ACL reconstruction.

The advantages of allografts include lack of donor-site morbidity, decreased incidence of postoperative knee stiffness and pain, preservation of knee extensor or flexor mechanisms, decreased operative time (no harvesting time), lower incidence of arthrofibrosis, and improved cosmetic appearance.

The limitations of allograft being concerns with slower incorporation rate, risk for disease transmission, cost factors, local bone resorption, graft rejection, limited availability, and compromised material properties due to sterilization and storage procedures.¹⁰

Our grafts (6 tendoachillis grafts, 6 tibialis posterior and 3 tibialis anterior) were harvested under strict aseptic precautions after proper donor screening and processed under same protocol and hence the graft processing bias was handled.

There are concerns regarding disease transmission with the use of allografts. Although Gamma irradiation is known for its bactericidal and virucidal properties, a meta-analysis has shown that even a small dose of about 2 Mrad can cause about 31% abnormal laxity in ligaments reconstructed with irradiated allografts, because of alteration in biomechanical properties which is significantly high when compared to non-irradiated grafts which is around 12%.^{12,13} Hence, all the grafts we used were maintained as fresh frozen but not irradiated. This procedure helps reduce antigenicity and disease transmission without affecting the graft strength.¹⁴

Allografts preserved by fresh frozen method were shown to cause little immune response.¹⁵⁻¹⁷ Hence its use is safe with respect to the rejection in the recipient. In our study, we did not encounter any graft rejections.

All the surgeries were performed by the same surgical team in the same operating room under similar conditions following the prefixed pre-operative protocol, procedure of reconstruction and the post-operative protocol. Thus the variability in the procedure performed was minimised.

Not much data is available on the differences in the duration of surgery among the studies. In our study, the mean duration of surgery was 1 hour 17 min.

Although it is currently accepted that the rate of post-operative infection is comparable in both autografts and allografts, some studies have shown that there is a significant increase in the rate of infection in allograft groups but is mainly attributed to at least one additional risk factor for infection (obesity, prior ipsilateral knee surgery or immunocompromised status) and some authors have suggested that infected allograft may be the nidus of

such events.^{18,19} Contrary to this historical popular belief, no patient in our allograft study group showed any signs of superficial or deep infection.

In our study, the average Lysholm score at 2 year follow-up period was 85.60 and IKDC score was 85.28 which was comparable to the other studies like Wang et al, whose mean Lysholm score was 90.5 and mean IKDC score was 89.4 at the end of 2 years for Patellar tendon allograft.²⁰ Kang et al reported mean IKDC score of 89.9 at the end of 3 year follow-up for single bundle patellar tendon allograft and 91.1 for double bundled tibialis anterior allograft.²¹

Grade I laxity of knee post allograft ACL reconstruction is a known phenomenon which averages around 76.7% for soft tissue allografts and should not be considered as graft failure unless the patient has concomitant functional

disability.^{20,21} Hence, our study with grade 0 laxity in 60% of subjects and grade 1 laxity in one subject is considered to be of no graft failures.

The possible causes of increased allograft clinical laxity were described as immunologic response by Schulte and Jackson, as freezing by Cryolife, as increased donor age by Kurzweil, as increased graft shelf time by Sterling, as subclinical infection by Carpenter and as radiation sterilization by Noyes, Gorschewsky.¹²

The results of our study with allografts are compared to certain other previous studies and tabulated (Table 4). We also compared our results with other studies where autografts were used and our results are similar to them (Table 5). Hence allografts are a very good alternative to autografts in ACL reconstruction.

Table 4: Comparison with allograft studies.

Study	Allograft	IKDC score	Lysholm score	Lachmann (<3 mm)
Fei Wang et al ²⁰	BPTB	89.4	90.5	57%
Martyn Snow(2010) ²²	TA	88	92	60%
Kang Sun et al ¹³	Hamstring		90	
Our study	TA,TP, Tendoachilles	85.28	85.6	60%

Table 5: Comparison with autograft studies.

Study	Autograft	IKDC score	Lysholm score	Lachmann (<3 mm)
Hussein et al ²³	Hamstring	90.2	90.9	52.9%
Yu Hua Jia ²⁴	Hamstring	87.8	85.2	
E. Witvrouw ²⁵	Hamstring		90.2	
Our study	TA, TP, Tendoachilles	85.28	85.6	60%

The strengths of the study being a prospective study, allografts obtained from our institution's cadaver lab, all the procedures related to surgery or the graft maintenance were performed by the same team of qualified personnel. Limited data is available in Indian scenario in this field, making our study one of its kinds.

The limitations of the study are smaller sample size and comparatively less follow-up period. The study would have been of more value if comparative analysis between the autograft and allograft use in the reconstruction of ACL was done and if multicentric analysis in different centres was performed.

CONCLUSION

Allograft ACL reconstruction with its various advantages makes it an excellent alternative to autografts for primary ACL reconstruction. Allografts have the potential to become the principle graft source for ligament reconstructions in the years to come, provided the technical complexity in procuring and processing is handled.

Funding: No funding sources

Conflict of interest: None declared

Ethical approval: The study was approved by the institutional ethics committee

REFERENCES

- Hospodar SJ, Miller MD. Controversies in ACL reconstruction: bone- patellar tendon- bone anterior cruciate ligament reconstruction remains the gold standard. Sports Med Arthrosc. 2009;17:242.
- Rue JP, Lewis PB, Parameswaran AD, Bach BR Jr. Single-bundle anterior cruciate ligament reconstruction: technique overview and comprehensive review of results. J Bone Joint Surg Am. 2008;90(Suppl 4):67-74.
- Edgar CM, Zimmer S, Kakar S. Prospective comparison of auto and allograft hamstring tendon constructs for ACL reconstruction. Clin Orthop Relat Res. 2008;466:2238-46.
- Biedert RM, Zwick EB. Ligament- muscle reflex arc after anterior cruciate ligament reconstruction: electromyographic evaluation. Arch Orthop trauma Surg. 1998;118:81-4.

5. Gulotta LV, Rodeo SA. Biology of autograft and allograft healing in anterior cruciate ligament reconstruction. *Clin Sports Med.* 2007;26:509-24.
6. Cohen SB, Sekiya JK. Allograft safety in anterior cruciate ligament reconstruction. *Clin Sports Med.* 2007;26:597-605.
7. Baer GS, Harner CD. Clinical outcomes of allograft versus autograft in anterior cruciate ligament reconstruction. *Clin Sports Med.* 2007;26:661-81.
8. Cohen SB, Sekiya JK. Allograft safety in anterior cruciate ligament reconstruction. *Clin Sports Med.* 2007;26:597-605.
9. Gulotta LV, Rodeo SA. Biology of autograft and allograft healing in anterior cruciate ligament reconstruction. *Clin Sports Med.* 2007;26:509-24.
10. Engelman GH, Carry PM, Hitt KG, Polousky JD, Vidal AF. Comparison of allograft versus autograft anterior cruciate ligament reconstruction graft survival in an active adolescent cohort. *The American journal of sports medicine.* 2014;42(10):2311-8.
11. Edgar CM, Zimmer S, Kakar S, Jones H, Schepsis AA. Prospective comparison of auto and allograft hamstring tendon constructs for ACL reconstruction. *Clinical orthopaedics and related research.* 2008;466(9):2238-46.
12. Prodromos CC, Joyce B, Shi K. A meta-analysis of stability of autografts compared to allografts after anterior cruciate ligament reconstruction. *Knee Surg Sports Traumatol Arthrosc.* 2007;15:851-6.
13. Sun K, Zhang J, Wang Y, Xia C, Zhang C, Yu T, Tian S. Arthroscopic reconstruction of the anterior cruciate ligament with hamstring tendon autograft and fresh-frozen allograft: a prospective, randomized controlled study. *Am J Sports Med.* 2011;39(7):1430-8.
14. Nikolaou PK, Seaber AV, Glisson RR, Ribbeck BM, Bassett III FH. Anterior cruciate ligament allograft transplantation: long-term function, histology, revascularization, and operative technique. *Am J Sports Med.* 1986;14(5):348-60.
15. Goertzen M, Dellmann A, Gruber J, Clahsen H, Bürrig KF. Anterior cruciate ligament allograft transplantation for intraarticular ligamentous reconstruction. *Arch Orthop Trauma Surg.* 1992;111:273-9.
16. Jackson DW, Grood ES, Arnoczky SP, Butler DL, Simon TM. Freeze dried anterior cruciate ligament allografts: Preliminary studies in a goat model. *Am J Sports Med.* 1987;15:295-303.
17. Fromm B, Schafer B, Parsch D, Kummer W. Reconstruction of the anterior cruciate ligament with a cryopreserved ACL allograft: A microangiographic and immunohistochemical study in rabbits. *Int Orthop.* 1996;20:378-82.
18. Crawford DC, Hallvik SE, Petering RC, Quilici SM, Black LO, Lavigne SA. Post-operative complications following primary ACL reconstruction using allogenic and autogenic soft tissue grafts: Increased relative morbidity risk is associated with increased graft diameter. *Knee.* 2013;20:520-5.
19. Labi N. Deadly transplants. *Time.* 2002;160(9):50-1.
20. Wang F, Kang HJ, Chen BC, Zhang YZ, Su YL. Primary ACL reconstruction: comparison of Achilles tendon allograft with tibial anatomical fixation and patellar tendon allograft with external aperture fixation. *European J Orthop Surg Traumatol.* 2011;21(5):333-9.
21. Kang HJ, Wang XJ, Wu CJ, Cao JH, Yu DH, Zhen ZM. Single-bundle modified patellar tendon versus double-bundle tibialis anterior allograft ACL reconstruction: a prospective randomized study. *Knee Surg, Sports Traumatol, Arthroscopy.* 2015;23(8):2244-9.
22. Snow M, Campbell G, Adlington J, Stanish WD. Two to five year results of primary ACL reconstruction using doubled tibialis anterior allograft. *Knee Surg, Sports Traumatol, Arthroscopy.* 2010;18(10):1374-8.
23. Hussein M, van Eck CF, Cretnik A, Dinevski D, Fu FH. Prospective randomized clinical evaluation of conventional single-bundle, anatomic single-bundle, and anatomic double-bundle anterior cruciate ligament reconstruction: 281 cases with 3-to 5-year follow-up. *Am J Sports Med.* 2012;40(3):512-20.
24. Jia YH, Sun PF. Comparison of clinical outcome of autograft and allograft reconstruction for anterior cruciate ligament tears. *Chinese Med J.* 2015;128(23):3163.
25. Witvrouw E, Bellemans J, Verdonk R, Cambier D, Coorevits P, Almqvist F. Patellar tendon vs. doubled semitendinosus and gracilis tendon for anterior cruciate ligament reconstruction. *Int Orthop.* 2001;25(5):308-11.

Cite this article as: Rahul P, Suraj HP, Shervegar S, Palla A. Soft tissue allograft for primary anterior cruciate ligament reconstruction. *Int J Res Orthop* 2017;3:718-23.