

## Original Research Article

# Short term outcome of primary un-cemented total hip arthroplasty in osteonecrosis of femoral head

Mohmad Nawaz Rather<sup>1</sup>, Wajahat Ahmad Mir<sup>1</sup>, Shahid Shabir Khan<sup>1\*</sup>,  
Naseer Ahmad Mir<sup>1</sup>, Nadeem Ali<sup>2</sup>

<sup>1</sup>Department of Orthopaedics, SKIMS, MC & H Srinagar, India

<sup>2</sup>Bone and joint hospital, Barzulla, Srinagar, India

**Received:** 01 April 2021

**Revised:** 21 April 2021

**Accepted:** 22 April 2021

**\*Correspondence:**

Shahid Shabir Khan,

E-mail: [Shahidshabirkhan@gmail.com](mailto:Shahidshabirkhan@gmail.com)

**Copyright:** © the author(s), publisher and licensee Medip Academy. This is an open-access article distributed under the terms of the Creative Commons Attribution Non-Commercial License, which permits unrestricted non-commercial use, distribution, and reproduction in any medium, provided the original work is properly cited.

### ABSTRACT

**Background:** Osteonecrosis of femoral head (ONFH) is characterised by cell death in the subchondral bone caused by abnormalities of blood flow to the femoral head. About 5% to 13% of arthroplasties are performed yearly for ONFH in United States. Ficat and Arlet classification is the commonest system used for grading of ONFH. Advanced stages 3 and 4 are best managed with total hip arthroplasty (THA). THA restores hip range of movement and allows early ambulation in ONFH.

**Methods:** After seeking approval from local institutional ethical committee 25 patients with stage 3 and stage 4 ONFH (Ficat and Arlet) were admitted from OPD of SKIMS MC and Hospital Bemina, Srinagar. The study was conducted from February 2018 to February 2020 in department of Orthopaedics SKIMS MC and Hospital Bemina, Srinagar. 25 patients with mean age of 50.64 years comprising of 13 females and 12 males with unilateral osteonecrosis of femoral head with collapsed head underwent uncemented total hip arthroplasty and were followed up to a minimum of 1 year post-operatively.

**Results:** Outcome was evaluated by comparing pre-operative and post-operative Harris hip scores. The average Harris hip scores improved from 65.87 in the pre-operative group to 96.54 at 1-year follow-up post-operatively. Marked improvement was noted in pain scores. No revisions were performed during the study. One patient developed superficial surgical site infection which healed with supervised dressings and oral antibiotics.

**Conclusions:** Uncemented THA has excellent short-term outcomes in advanced stages of ONFH. It provides mobile hip joint and pain free ambulation shortly after surgery.

**Keywords:** Osteonecrosis of femoral head, Total hip arthroplasty, Harris hip score

### INTRODUCTION

Osteonecrosis of femoral head (ONFH) is characterised by cell death in the subchondral bone caused by abnormalities of blood flow to the femoral head. Chandler called it 'The Coronary Disease of Hip'.<sup>1</sup> ONFH affects young adults in third to fourth decade of life.<sup>2</sup> About 5% to 13% of arthroplasties are performed yearly for ONFH in United States.<sup>3</sup> Disease usually affects males more than females. ONFH encompasses various radiographic stages grossly

divided into pre-Collapse and Collapsed head stages. Management of ONFH is defined by the stage of the disease. X-ray and MRI are used as the diagnostic tools. Groin pain, limp and support for ambulation are the common presentations. Ficat et al classification is the commonest system used for grading of ONFH.<sup>4</sup> Stage 1 and 2 are managed with head salvage. Advanced stages 3 and 4 are best managed with total hip arthroplasty (THA). Proximal femoral osteotomies delay the arthroplasty in young patients with less than 30% head involvement in the

weight bearing area.<sup>5</sup> Despite the advantages of bone stock preservation and deaying THA, results of head - resurfacing have been discouraging.<sup>6</sup> Although cemented THA was reported to have better outcome compared to uncemented THA, recent reports suggest improved results of uncemented THA in ONFH patients.<sup>7</sup> Uncemented THA has the advantages of less risk of infection, aseptic loosening and zero incidence of bone cement implantation syndrome.<sup>8</sup> This study was performed to evaluate short-term outcome of uncemented THA in unilateral ONFH.

**METHODS**

This prospective interventional study was conducted in SKIMS medical college hospital, Bemina Srinagar from February 2018 to February 2020. 25 patients meeting the inclusion criteria were admitted to SKIMS MC hospital. All the patients were operated after pre-operative workup by the same surgeon via the same approach (posterolateral hip approach) after getting approval from institutional ethical committee. The implant used was same in all patients. Fully hydroxyl-apatite coated stem and pinnacle shell with metal on polyethylene interface was used. Post-operative management included intra-venous antibiotics and thrombo-prophylaxis. Patients were ambulated in the immediate post-operative period with partial weight bearing with walker with progression to full weight bearing at 6 weeks<sup>9</sup>. Standard hip precautions were advised. Radiographs were taken in immediate post-operative period, 6 month and 1 year follow up. Follow up was done at 2 weeks, 3 months, 6 months and final follow up at 1 year. Harris hip scoring was done preoperatively and at final follow up.

**Inclusion criteria**

Age- above 20 years; sex- all sexes. Osteonecrosis head femur; FICAT ARLET stage 3 and 4; DORR A and B Femori; unilateral osteonecrosis.

**Exclusion criteria**

Age- below 20 years; FICAT ARLET stage 1 and 2, DORR C Femori. Any medical contraindication to surgery; fresh trauma to the affected side.

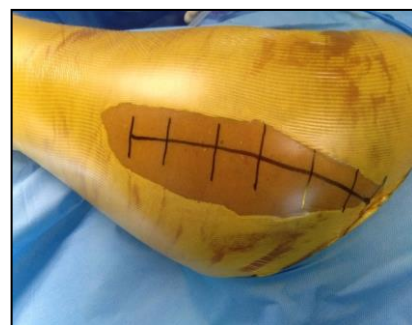**Stastical analysis**

Data was entered on microsoft excel software and analysis was done with SPSS version 20.0 software.

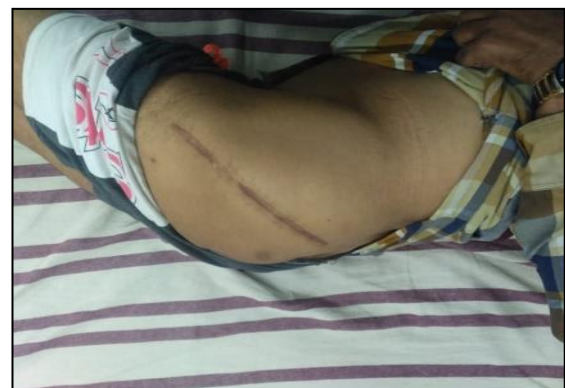**RESULTS**

The study patients were in the age group of 28 to 65 years with mean age of 50.64 years. 13 females and 12 males were studied. 16 patients had left hip involvement and 9 patients had right hip affected. 11 patients had post traumatic ONFH with 8 patients post neck femur fracture and 3 patients post acetabulum fracture with hip dislocation. 9 patients had idiopathic, 3 had steroid

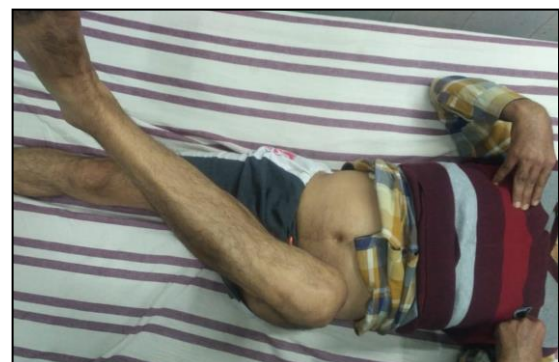induced, 1 with renal transplant and one patient with chronic alcohol intake. Limb length discrepancy (LLD) was found postoperatively in 13 patients. All the patients with LLD had less than 1.5 cm of discrepancy. 2 patients were complicated with superficial surgical site infection, 3 with anterior thigh pain and 1 with trendelenburg gait. Most common head size used was 36 mm in 14 patients, 32 mm in 9 patients and 28 in 2 patients. 21 patients had central stem configuration with varus in 4 patients. Acetabular inclination range from 40 to 50 degrees in all patients. Mean pre-op Harris Hip Score (HHS) improved from 65.875 to 96.52 post-operatively. Noted improvements occurred in pain score from 26 in the pre-op group to 43.04 in the post-op group. No dislocations were reported in our study and no cases of heterotopic ossification were reported.



**Figure 1: Draping and marking.**



**Figure 2: Incision scar at final follow up.**



**Figure 3: External rotation at final follow up.**

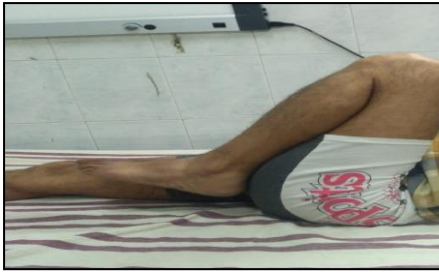

Figure 4: Flexion at final follow-up.

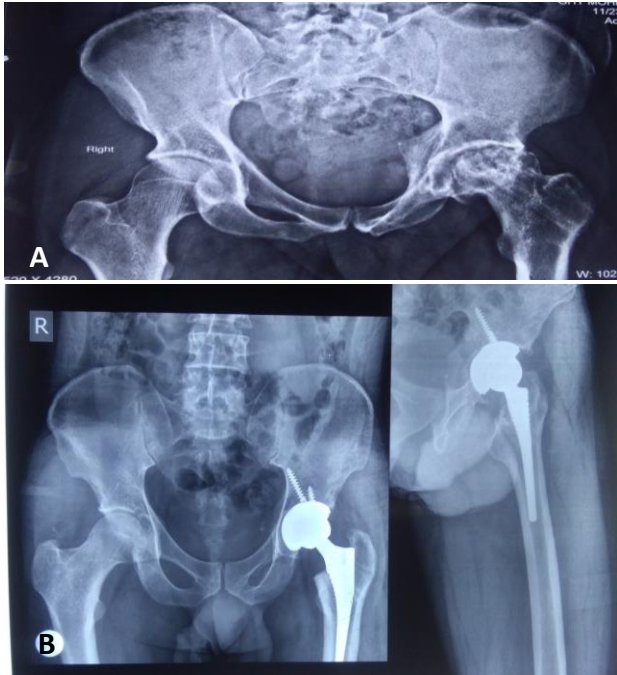


Figure 5 (A and B): Pre and post-op xrays, correct the post-op xrays as it is inverted.

Table 1: Epidemiology.

Epidemiology	
Mean age	50.64 years
Gender ratio	13:12 (female: male)
Side involvement	16:9 (right: left)
Causes of ONFH	
Post-Traumatic	44%
Idiopathic	36%
Steroids	12%
Renal transplant	4%
Alcoholism	4%

Table 2: Complications.

Complications	No. of patients	Percentage
SSI	2	8
Anterior thigh pain	3	12
Trendelenburg gait	1	4
Not applicable	16	76
<b>Total</b>	<b>25</b>	<b>100</b>

Table 3: Femoral stem configuration.

Configuration	No of patients	Percentage
Central	21	84
Varus	4	16
<b>Total</b>	<b>25</b>	<b>100</b>

Table 4: Acetabular inclination.

Inclination angle	No. of patients	Percentage
43	3	12
44	2	8
45	10	40
46	8	32
47	1	4
49	1	4
<b>Total</b>	<b>25</b>	<b>100</b>

Table 5: HHS and grading of HHS.

No. of patients	Mean pre-op HHS	Mean post-op HHS
<b>25</b>	<b>65.875</b>	<b>96.52</b>
Grade of HHS	No of patients in pre-op group	No of patients in post-op group
Poor	13	0
Fair	9	0
Good	3	1
Excellent	0	24
<b>Total</b>	<b>25</b>	<b>25</b>

**DISCUSSION**

The age group in our study ranged from 28 to 65 years with mean age of 50.64 years which points to delayed diagnosis and presentation to an Arthroplasty centre. The mean age of our study is comparable to other studies conducted on patients with avascular necrosis of the femoral head because AVN is primarily a disease of young adults.<sup>7,8,10,11</sup> Our study group comprised of 13 females (52%) and 12 males (48%). The gender ratio in our study correlates poorly with other studies which may be due to small sample size and more female patients with AVN presenting to hospital OPD during the study period. More than half of the arthroplasties were done on the right hip. The study group comprised of 64% involvement of right hip and 36% of the left hip joint. This is comparable to other studies.<sup>11,12</sup> Our study group comprised of both post-traumatic as well as non-traumatic AVN of femoral head. The study group of 25 patients include 36% idiopathic, 44% post-traumatic, 12% steroids, 4% alcoholism, and 4% other causes. The major etiology of AVN of the femoral head in our study is contributed by the idiopathic and post-traumatic group. Two patients reported with superficial surgical site infections which cleared upon repeated antiseptic dressings (ASD). None of the patients had deep infection or continuous discharge from the incision site. This was comparable to the study of El-etewy and was

slightly higher than other studies.<sup>11,14,15</sup> In our study three (12%) patients presented with thigh pain, two of which had varus configuration of femoral stem. This correlates closely with the study of Shah et al.<sup>11</sup> Lewinnek et al used a pelvic co-ordinate system with anterior pelvic plane in order to define the so called “safe zone”.<sup>16</sup> They suggested a 40 average acetabular inclination angle. Hirakawa et al suggested an inclination angle of less than 40 is associated with better long-term results as compared to an angle of 45 or above.<sup>17</sup> The mean acetabular inclination angle in our study was 45.24 degrees ranging from 43 to 49 degrees which is comparable to other studies.<sup>8,15,18</sup> Femoral stem was placed in central position in 84% of the patients, 16% had slightly varus position of the femoral stem at final follow-up. None of the patients had valgus configuration of the femoral stem. This correlates well with other studies.<sup>8,15</sup> The average Harris hip score (HHS) improved from 65.875 in the pre-op group to 96.52 at the final follow-up in post-op group. The improvement was grossly seen in the pain scores which improved from a mean score of 26 in pre-op group to 43.04 in the post-op period at final follow up. The improvement in HHS was comparable to other studies.<sup>12,14,15,18</sup> The grading of outcome based on the improvement in HHS showed 96% graded as excellent while 4% were graded as good. The grading of outcome in our study was in line with the studies.<sup>12,18-20</sup> In our study there were no dislocations with the posterolateral approach and posterior soft tissue repair. Kim et al reported three dislocations in his study which were attributed to the use of 22 mm head and habitual squatting on floor.<sup>8</sup> None of the studied patients had any evidence of heterotopic ossification at final follow-up.

## CONCLUSION

Avascular necrosis of the hip is the disease of young adults. Advanced stages characterized by flattening of articular surface of the femoral head with secondary arthritis are responsible for the limp and loss of range of motion of hip joint. Total hip arthroplasty is the only treatment that relieves pain and restores mobility of the hip joint in advanced stages of AVN. Our study used uncemented fully hydroxyapatite coated femoral stem (corail) with porous coated acetabular shell with metal on polyethylene interface. Our study despite some complications showed favourable short-term results in advanced stages of AVN of head of femur.

## ACKNOWLEDGEMENTS

*Funding: No funding sources*

*Conflict of interest: None declared*

*Ethical approval: The study was approved by the institutional ethics committee*

## REFERENCES

1. Chandler FA. Coronary disease of the hip. *J Int Coll Surg.* 1948;11(1):34-6.

2. Mankin HJ. Nontraumatic necrosis of bone (osteonecrosis). *N Engl J Med.* 1992;326(22):1473-9.
3. Steinberg ME, Hayken GD, Steinberg DR. A quantitative system for staging avascular necrosis. *J Bone Joint Surg Br.* 1995;77(1):34-41.
4. Ficat RP. Treatment of bone ischemia and necrosis. In: Hungerford DS, eds. *Ischemia and necrosis of bone.* Baltimore: Williams & Wilkins; 1980: 171.
5. Mont MA. Corrective osteotomy for osteonecrosis of femoral head:the results of long term follow-up. *J Bone Joint Surg.* 1996;78:1032-8.
6. Pyda M, Koczy B, Widuchowski W, Widuchowska M, Stołtny T, Mielnik M, et al. Hip resurfacing arthroplasty in treatment of avascular necrosis of the femoral head. *Med Sci Monit.* 2015;21:304-9.
7. Saito S, Saito M, Nishina T, Ohzono K, Ono K. Long-term results of total hip arthroplasty for osteonecrosis of the femoral head. A comparison with osteoarthritis. *Clin Orthop Relat Res.* 1989;(244):198-207.
8. Kim YH, Kim JS, Park JW, Joo JH. Contemporary total hip arthroplasty with and without cement in patients with osteonecrosis of the femoral head: a concise follow-up, at an average of seventeen years, of a previous report. *J Bone Joint Surg Am.* 2011;93(19):1806-10.
9. Andersson L, Wesslau A, Bodén H, Dalén N. Immediate or late weight bearing after uncemented total hip arthroplasty: a study of functional recovery. *J Arthroplasty.* 2001;16(8):1063-5.
10. Ancelin D, Reina N, Cavaignac E, Delclaux S, Chiron P. Total hip arthroplasty survival in femoral head avascular necrosis versus primary hip osteoarthritis: Case-control study with a mean 10-year follow-up after anatomical cementless metal-on-metal 28-mm replacement. *Orthop Traumatol Surg Res.* 2016;102(8):1029-34.
11. Shah N, Singh AK, Sharma A, Pawar E, Nadwi ST, Shet V. Preoperative assessment and postoperative outcome of total hip replacement in adults with AVN. *Int J Orthop Sci.* 2017;3(3):986-91.
12. Reddy MRS, Shivakumar MS, Phadet P. Study of clinical and functional outcome of total hip replacement in avascular necrosis of femoral head *International J Orthop Sci* 2018;4(1):252-8.
13. Ortiguera CJ, Pulliam IT, Cabanela ME. Total hip arthroplasty for osteonecrosis: matched-pair analysis of 188 hips with long-term follow-up. *J Arthroplasty.* 1999;14(1):21-8.
14. Rahangdale A, Raza HKT, Maravi LS, Sirsikar A. A prospective study of early complications of uncemented total hip arthroplasty for avascular necrosis of femoral head.
15. El ESS, Megahed RM. Cementless total hip arthroplasty in post-traumatic avascular necrosis of the femoral head in young adults *Egypt Orthop J.* 2013;48:282-8.
16. Lewinnek GE, Lewis JL, Tarr R, Compere CL, Zimmerman JR. Dislocations after total hip-

- replacement arthroplasties. *J Bone Joint Surg Am.* 1978;60(2):217-20.
17. Hirakawa K, Mitsugi N, Koshino T, Saito T, Hirasawa Y, Kubo T. Effect of acetabular cup position and orientation in cemented total hip arthroplasty. *Clin Orthop Relat Res.* 2001;(388):135-42.
  18. Brinker MR, Rosenberg AG, Kull L, Galante JO. Primary total hip arthroplasty using noncemented porous-coated femoral components in patients with osteonecrosis of the femoral head. *J Arthroplasty.* 1994;9(5):457-68.
  19. Mont MA, Seyler TM, Plate JF, Delanois RE, Parvizi J. Uncemented total hip arthroplasty in young adults with osteonecrosis of the femoral head: a comparative study. *J Bone Joint Surg Am.* 2006;88(3):104-9.
  20. Sivakanthan A, Sharath KR, Kohli R. Uncemented total hip replacement using hydroxyapatite coated stem in vascular necrosis of femur head. *Internat J Sci Res.* 2016;5(5):880-2.

**Cite this article as:** Rather MN, Mir WA, Khan SS, Mir NA, Ali N. Short term outcome of primary uncemented total hip arthroplasty in osteonecrosis of femoral head. *Int J Res Orthop* 2021;7:513-7.