

Original Research Article

Modified dome shaped proximal tibial osteotomy for treatment of infantile tibia vara

Mohammed A. A. Geith*, Ahmed M. El. Naggar

Department of orthopedic surgery, Faculty of human Medicine, Zagazig University, Egypt

Received: 27 September 2016

Accepted: 04 November 2016

***Correspondence:**

Dr. Mohammed A. A. Geith,
E-mail: yousufmmkh@gmail.com

Copyright: © the author(s), publisher and licensee Medip Academy. This is an open-access article distributed under the terms of the Creative Commons Attribution Non-Commercial License, which permits unrestricted non-commercial use, distribution, and reproduction in any medium, provided the original work is properly cited.

ABSTRACT

Background: Tibial deformity in childhood is not always one plane deformity, but often combines torsional and angular malalignment.

Methods: In this prospective study, dome shaped osteotomy was performed in 36 tibiae in 24 patients. The osteotomy was held with K-wires and a plaster cast. The mean age at surgery was 5.5 years and the mean follow-up time was 30 months, range (24-42) months.

Results: All osteotomies united and no compartment syndrome occurred. Postoperatively, one leg (2.7%) had temporary weakness of external hallucis longus muscle. Thirty five of thirty six legs had good clinical and radiological correction of alignment. Recurrent deformity was seen in one leg.

Conclusions: Dome shaped osteotomy of the tibia is a simple, safe and effective method for correction of uni-planar varus deformity. For bi-planar deformities in childhood with infantile tibia vara we may need to step cut the lateral cortex to allow good bone contact to help in union with minimum morbidity.

Keywords: Tibia, Vara, Dome, Osteotomy, Infantile

INTRODUCTION

Most tibial deformities of childhood correct spontaneously with growth but some do not. It is relatively rare to have a deformity occur in only one plane. Tibia vara, rarely if never produces simple varus deformity of the tibia but usually involves internal tibial torsion and occasionally recurvatum deformity of the upper tibia. Tibia vara is classified as infantile when the onset occurs before 5 years of age and involvement is bilateral in 80% of patients. Late onset tibia vara considered when onset begins after the age of 6 years.¹ The surgical correction of persisting, significant deformity can be achieved by a variety of methods ranging from manipulation of physal growth by temporary physal stapling, or hemiepiphysiodesis to many types of valgus osteotomies such as the incomplete lateral closing wedge osteotomy, an

oblique tibial osteotomy, and the intra-epiphyseal, or trans-epiphyseal tibial osteotomy.²⁻⁶

It was felt that a suitable osteotomy should be near the center of rotation of angulation (CORA) with little translation, primarily in cancellous bone to allow rapid healing, and safe the epiphyseal plate and tibial length. In addition to these, the osteotomy site should be stable without the use of internal fixation devices to be able to change the amount of correction obtained on table during postoperative period. To fulfill these requirements and at the same time provide 3-plane correction of the deformity dome shaped tibial osteotomy has been described for realignment of the knee by many authors. Ponseti et al discussed a bilateral dome-shaped osteotomy of the proximal tibia to correct a varus deformity of the knees.⁷ Paley et al modified this concept by describing a focal dome osteotomy through the CORA to allow for

deformity correction with minimum translation as in Figure 1.^{8,9}

In this prospective study we assess the dome shaped osteotomy in the proximal tibia for correction of severe varus tibial deformity due to infantile tibia vara with step cut of the lateral cortex to get contact of the bone after derotation to correct the combined tibial torsion.

METHODS

Between January 2009 and June 2013, 36 tibiae in 24 children underwent a dome shaped osteotomy for correction of torsional and angular deformity. The indication for surgery in all cases was significant radiological and clinical deformity. In all limbs the primary deformity was varus and internal tibial torsion. The mean age at the time of operation was 5.5 years (range 3.5–6.75 years) and the mean follow-up was 30

months (range 24–42 months) as given in Table 1. Tibial torsion was measured clinically, preoperatively and postoperatively, by means of the thigh–foot angle (TFA) and the foot progression angle (FPA) as described by Staheli et al.¹⁰ Preoperative assessment also included measurement of the metaphyseal diaphyseal angle (MDA).¹¹ The mechanical axis should normally bisect the knee. Axes that lie within the central half of the knee (medial and lateral zones 1) are physiologically normal. Axes that pass through zones 2 and 3 are pathological. The CORA was identified for all limbs. All measurements were made from appropriately positioned, standing long-leg radiographs and the point where the mechanical axis crossed the knee joint was noted as shown in Figure 2.⁹ Postoperatively, similar radiographic measurements were made at 6 and 12 months. Subsequent radiographic assessments were made only if there was a clinical indication. All patients were followed up clinically for a minimum of 24 months until their clinical state was stable.

Table 1: Tibia vara: all patients' data.

	Sex		Etiology		Limb affected		
	Male	Female	Tibia vara	Old rickets	Right	Left	Bilateral
Patient number	22	14	24	12	6	8	11
Mean age at surgery	Mean follow up period						
5.5 years (range: 3.5-6.75)	30 months (range: 24-42)						

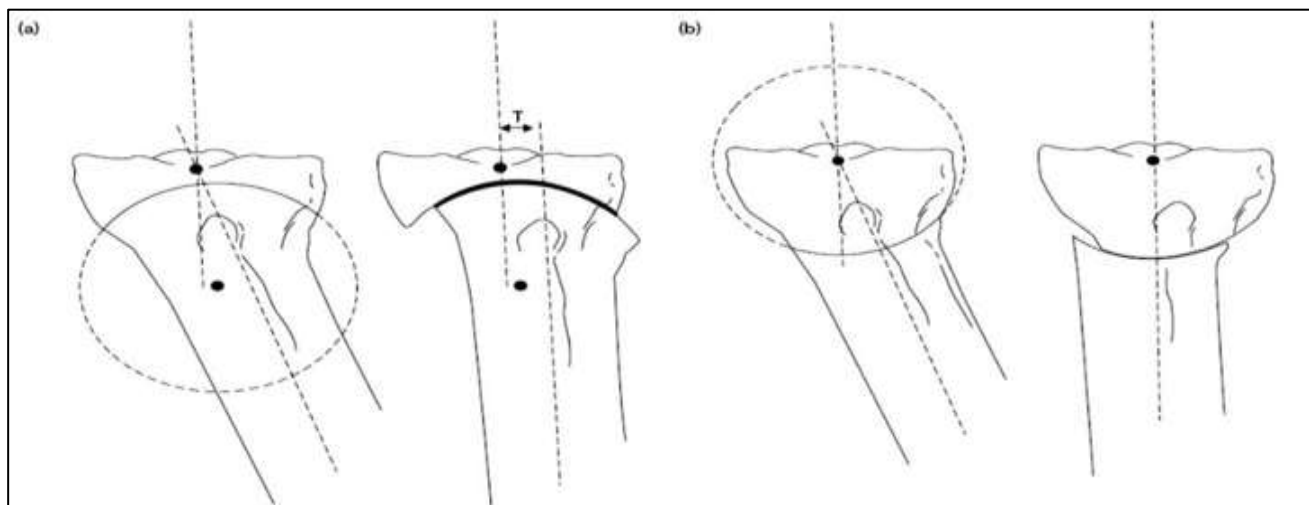


Figure 1: a) Standard Macquet type dome osteotomy for tibial deformity; b) Focal dome osteotomy of the tibia demonstrating minimal translation following correction of deformity (T): Amount of translation that occurs following displacement.

Operative technique

Under a general anesthesia, the child lay supine on a radiolucent operating table. Both limbs were prepared and draped separately. A high thigh tourniquet was used on the affected limb. A sub-periosteal excision of 1 cm of fibula was performed through a lateral longitudinal incision at the junction of the middle and distal thirds of the shaft: in the so-called 'safe zone' to avoid damage to branches of the peroneal nerve.^{12,13}

The tibial approach was via a longitudinal incision placed just lateral to the tibial crest and centered on the site of the proposed osteotomy. In the proximal tibia this was at or just below the tibial tubercle. A sub-periosteal exposure of the tibia was performed and the level confirmed with the image intensifier. A dome cut was outlined on the tibial surface: the apex of the osteotomy site below the tibial tuberosity was marked with a drill hole (2.5 mm or 3.5 mm depending on the size of the bone) and further medial and lateral drill holes were

placed in a semicircular distribution so that the convexity of the distal fragment faced the adjacent joint as shown in Figure 3. The drill holes were then connected with a small osteotome to complete a dome osteotomy. Care was taken to ensure that the lateral and medial corners were completed. Once the osteotomy was freely mobile, the major varus deformity was corrected and then the distal tibia was rotated to achieve the necessary torsional correction. After rotation correction the lateral cortices found not in contact, so a step osteotomy was done to give bone contact to add stability and help union.

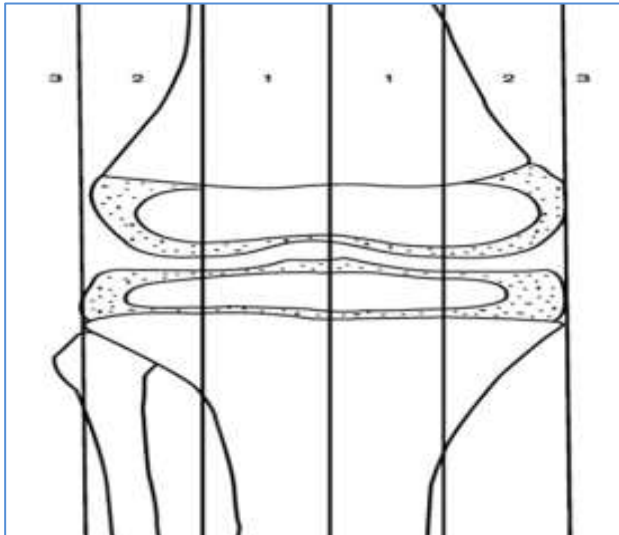


Figure 2: The mechanical axis should normally bisect the knee: axes that lie within the central half of the knee in zone 1: (medial or lateral) is physiologically normal; axes that pass through zone 2 or 3 are pathological.

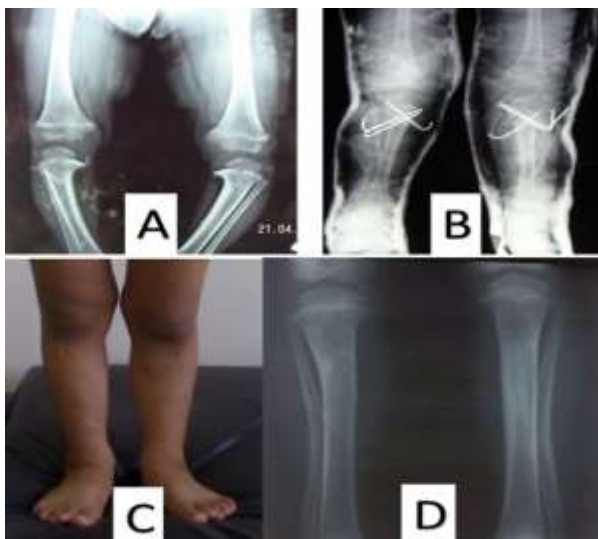

Figure 3: Operative technique A) preoperative x-ray of left leg in 4.5 years female, B) exposure of proximal tibia and pre-drilling for osteotomy; C & D) percutaneous K-wires for fixation; E) postoperative X-ray in cast.

Intra-operative corrections of the deformity was assessed clinically and radio-graphically using a diathermy cord passing from the center of the hip to the center of the ankle joint to identify the mechanical and anatomical axes. The osteotomy was stabilized with crossed 1.6 or 2 mm Kirschner wires inserted percutaneously. During wound closure, care was taken to preserve the periosteum and the soft tissues. All wounds were sutured using an absorbable subcuticular stitch. An above-knee plaster cast was applied. At 2 weeks, the plaster cast was changed under general anesthesia and the final position of the osteotomy adjusted, in three legs (8.2%), according to the mal-alignment detected on the follow up radiographs, and the K-wires were loose in one osteotomy, stable in two, so, K-wires were resited under image intensifier. The K-wires were removed at 6 weeks without a general anesthetic. The plaster cast was removed when the osteotomy was united clinically and radio-graphically. The total time in cast varied with the age of the patient. Full weight bearing was allowed at 6 weeks. Physiotherapy was commenced following cast removal.

RESULTS

Two weeks postoperative during change of plaster, two limbs showed some loss of angular correction and K-wires were extracted and resited percutaneously after manipulation under anesthesia with application of a valgus force to correct the residual deformity. The total time in plaster varied with the age of the patient. All osteotomies united within time ranged from 2 to 4 months. At a mean time of 30-months of follow-up, all patients had a good clinical and radiological correction of deformity with improvement of preoperative symptoms as given in Figure 4 and 5.

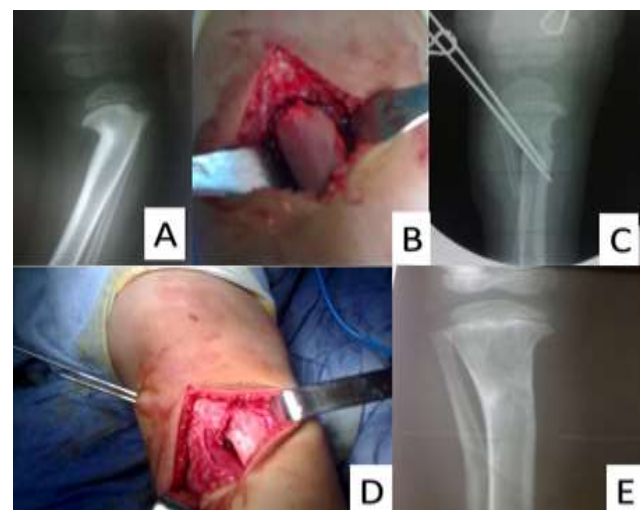

Figure 4: Female patient 3.5 years old with bilateral tibia vara: A) X-ray preoperative deformity; B) postoperative plain X-ray; C) photo of the patient 30 months after osteotomy with corrected deformity; D) X-ray 1 year postoperatively.

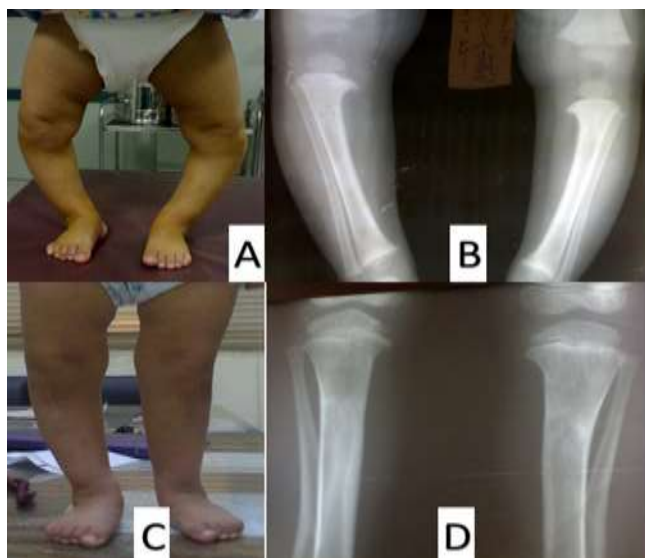

Figure 5: Female patient 3.5 years old with bilateral genu varum due to infantile tibia vara. A&B: preoperative clinical and X-ray appearance; C) postoperative photo at the end of follow up; D) 1 year postoperative X-ray with full correction in left and residual 15 degrees varus in right side.

In one case there were under-correction of deformity by (15 degrees varus) but, it was accepted by parents of the girl, so reoperation was not needed.

Radiographically, the angular correction was from a mean of 20 degrees preoperative to a mean of 2 degrees of varus angulation postoperative. TFA was corrected from a mean of 16 degrees of in-toeing preoperatively to a mean neutral position at follow-up.

In all cases the postoperative foot progression angle (FPA) was within 4 degrees of neutral and hence for each patient was within normal limits. The mechanical axis was corrected from passing outside the middle half of the knee joint (outside zones 1 in) as in Figure 2 in all cases preoperatively, to passing through the central zones 1 of the joint in all but one limb postoperatively as in Table 2 and 3.

Neurological symptoms occurred in one leg of 24 (4.2%) as weakness of extensor hallucis longus muscle (EHL) noted postoperatively and at 6-month follow-up. By 12 months strength in EHL was returned to normal. All patients were satisfied by the appearance and length of the scars at final follow-up for tibial and fibular scars.

Table 2: Different measurements of the deformity (pre and postoperative).

	Preoperative	Postoperative
Varus angular deformity (degrees)	Mean 19 degrees (range from 18-26° varus).	Mean 2 degrees (range from 5 degrees valgus to 15 degrees varus).
Thigh foot angle (FTA)	Mean 15 (8 to 20) degrees in-toeing.	Mean 2 degrees extoeing (from 5 degrees extoeing to 3 degrees in-toeing).
Metaphyseal diaphyseal angle (MDA)	Mean 18 (12- 22) degrees.	Mean 3 (0-6) degrees.

Table 3: The mechanical axes zone in the knee pre and postoperative.

Position of mechanical axis					
Side	Medial		Central	Lateral	
Zone	Zone 3	Zone 2	Zone 1	Zone 2	Zone 3
Preoperative	12 legs	24 legs	0	0	0
Postoperative	0	2 legs	36	0	0

DISCUSSION

The best way to obtain surgical correction of tibial deformity should be reproducible and safe, providing reliable correction with minimum morbidity. The surgical procedure carried out close to the CORA in the metaphyseal region of the bone can promote rapid union and prompt remodeling with minimal translation or shaft deformity. Dome shaped tibial osteotomy corrects accurately both the angular and rotational malalignment that occurs in patients with moderate to severe degrees of tibial deformity whilst maintaining bone length. Good bony apposition occurred, and in this study, the added step osteotomy of lateral cortex after rotation of the

distal fragment gave good bone apposition. The limited internal fixation with crossed Kirschner wires provided satisfactory control of the osteotomy position in all cases except one (2.7%), thus avoiding the need for further surgery that occurs for extraction in plate fixation techniques.

Miller et al used a similar osteotomy for the treatment of adolescent tibia vara but stabilized the osteotomy with an external fixator.¹⁴ All their patients were obese and the mean age was higher than in this study. We believe that in the majority of young patients undergoing a dome osteotomy an external fixator can be avoided.

Proximal tibial osteotomies in young patients have been associated with some major problems: failure to achieve desired postoperative alignment, and an incidence of neurovascular complications that many would consider unacceptable.¹⁵⁻¹⁸ Several potential causes of neurovascular problems have been highlighted. Peroneal nerve palsy may be caused by traction and the anterior compartment syndrome could be related to anterior tibial artery trauma. Steel et al reported extensor hallucis longus weakness due to anterior compartment syndrome in 29% of their patients.¹⁹ Schrock reported peroneal nerve palsy in 10% of children under going tibial derotation osteotomies due to anterior compartment syndrome.²⁰ Rab advocated routine fasciotomy of the anterior compartment to reduce the risk of this complications.¹⁷

In our work, careful attention to surgical detail with gentle soft tissue dissection, pre-drilling of the tibia and then completion of the osteotomy with an osteotome to avoid vascular complications. In addition, the fibular osteotomy decompressed all three compartments of the lower leg, thus adding to the safety of the procedure. The level of the fibular osteotomy is important. Both Elgafy et al and Kirgis and Albrecht identified a 'danger zone' between 6 and 13 cm distal to the head of the fibula where division of the fibula risks damage to the nerve to extensor hallucis longus muscle which has a close relationship to the fibular periosteum at this site.^{12,13} Our one case of temporary EHL weakness was associated with an incorrectly sited fibula osteotomy. We believe that direct damage to the nerve to EHL is a more likely explanation for postoperative weakness than an anterior compartment syndrome.

Although compartment syndromes have been reported not infrequently in the old literature, recent studies including ours have seen no such complications.^{14,19,21} However, Mueller and Farley recently reported a case of compartment syndrome affecting both superficial and deep posterior compartments and special care should be given to immediate postoperative period.²²

Multiple level deformities were uncommon in our patients. One patient had significant distal deformity despite successful proximal tibial osteotomy. The deformity was due to old rickets, and was accepted by parents, so no further osteotomy was needed. Nadeem et al reported in their series high % of patients had multiple level deformities and several patients may require distal femoral procedures in the future.⁹ Payman et al identified a significantly increased risk of major complications such as recurrence/reoperation in patients with a co-morbidity.²¹ In our study all patients but one were corrected by single level osteotomy in proximal tibia. No patients needed re-operation. In Nadeem et al work they have been practicing simultaneous two (and occasionally three) level osteotomies using this technique at distal femur, and proximal and distal tibia in

cases in which each individual deformity was severe enough to warrant treatment.⁹

CONCLUSION

Dome shaped osteotomy of the tibia is a simple, safe and effective method for correction of uniplanar or biplanar deformities in childhood with infantile tibia vara with minimum morbidity. The added step cut of the lateral cortex added stability to the osteotomy by giving good bone contact after derotation to correct the internal torsion deformity.

Funding: No funding sources

Conflict of interest: None declared

Ethical approval: The study was approved by the institutional ethics committee

REFERENCES

1. Brooks CW, Gross HR. Genu varum in children: diagnosis and treatment. *J Am Acad Orthop Surg.* 1995;3:326-35.
2. Mielke CH, Stevens PM. Hemi-epiphyseal stapling for knee deformities in children younger than 10 years; a preliminary report. *J Pediatr Orthop.* 1996;16:423-9.
3. Wagner H. The displacement osteotomy as a correction principle, in Hierholzer G, Muller KH (editors): *corrective osteotomies of the lower extremity after trauma.* Berlin: Springer; 1985: 141-150.
4. Laurencin CT, Ferriter PJ, Millis MB. Oblique proximal tibial osteotomy for the correction of tibia vara in the young. *Clin Orthop.* 1996;327:218-24.
5. Zayer M. Hemi-condylar tibial osteotomy in Blount's disease, a report of 2 cases. *Acta Orthop Scand.* 1992;63:350-2.
6. Sasaki T. Trans-epiphyseal plate osteotomy for severe tibia vara in children; follow up of 4 cases. *J Pediatr Orthop.* 1986;6:61-5.
7. Ponseti I, Tapia J, Stearin G. Vitamin D resistant rickets. *J Bone Joint Surg.* 1964;46:935.
8. Paley D, Herzenberg JE, Tetsworth K, McKie J, Bhav A: Deformity planning for frontal plane corrective osteotomies. *Orthop Clin North Am.* 1992;25:425-65.
9. Nadeem RD, Thomas JQ, Deborah ME. Focal dome osteotomy for the correction of tibial deformity in children. *J of Pediatr Orthop B.* 2005;14:340-6.
10. Staheli LT, Corbett M, Wyss C, King H. Lower extremity rotational problems in children. *J Bone Joint Surg (Am).* 1985;67:39-47.
11. Levine AM, Drennan JC. Physiological bowing and tibia vara. *J Bone Joint Surg (Am).* 1982;64:1158-63.
12. Elgafy H, Ebraheim NA, Shaheen PE, Yeating RA. Extensor hallucis longus innervations an anatomic study. *Clin Orthop.* 2002;398:245-51.

13. Kirgis A, Albrecht S. Palsy of peroneal nerve after proximal tibia osteotomy: an anatomical study. *J Bone Joint Surg (Am)*. 1992;74:1180-5.
14. Miller S, Radomisli T, Ulin R. Inverted arcuate osteotomy and external fixation for adolescent tibia vara. *J Pediatr Orthop*. 2000;20:450-4.
15. Henderson RC, Kemp GJ, Greene WB. Adolescent tibia vara: alternative for operative treatment. *J Bone Joint Surg (Am)*. 1992;74:342-50.
16. Thompson GH, Carter GR. Late onset tibia vara (Blount disease): Current concepts. *Clin Orthop*. 1990;255:24-35.
17. Rab GT. Oblique tibial osteotomy for Blount's disease (tibia vara). *J Pediatr Orthop*. 1988;8:715-20.
18. Slawski DP, Schoenecker PL, and Rich MM: Peroneal nerve injury as a complication of pediatric tibial osteotomies: A review of 255 osteotomies. *J Pediatr Orthop* 1994;14:166-72.
19. Steel HH, Sandrow RE, Sullivan PD. Complications of tibial osteotomy in children with genu varum and genu valgum. Evidence that neurological change due to ischemia. *J Bone Joint Surg (Am)*. 1971;53:1629-35.
20. Schrock RD. Peroneal nerve palsy following derotation osteotomies for tibial torsion. *Clin Orthop*. 1969;62:172-7.
21. Pamyran KR, Patenal V, Borden P, Green T, Otsuka NY. Complications of tibial osteotomies in children with co-morbidities. *J Pediatr Orthop*. 2002;22:642-4.
22. Mueller KL, Farley FA. Superficial and deep posterior compartment syndrome following high tibial osteotomy for tibia vara in a child. *Orthopaedics*. 2003;26(5):513-4.

Cite this article as: Geith MAA, Naggar AME. Modified dome shaped proximal tibial osteotomy for treatment of infantile tibia vara. *Int J Res Orthop* 2016;2:394-9.