

Original Research Article

Comparative evaluation of functional outcome of discectomy versus discectomy with posterior lumbar interbody fusion for treatment of lumbar disc herniation

Mubarak Basha Imam Saheb¹, Maheswaran Karattipalayam Saravanan^{2*},
Joney Mandice³, Vijay Krishnan Arcot Subramaniyan⁴

Department of Orthopaedics and Traumatology, ¹ESIC Medical College and PGIMSR, KK Nagar, Chennai, ²Govt. Kanyakumari Medical College, Asaripallam, Kanyakumari, Tamil Nadu, India

³Institute of Orthopaedics and Traumatology, Govt. Coimbatore Medical College, Coimbatore, Tamil Nadu, India

⁴Assistant surgeon, Mettupalayam Government Hospital, Tamil Nadu, India

Received: 12 December 2018

Revised: 10 April 2019

Accepted: 11 April 2019

*Correspondence:

Dr. Maheswaran karattipalayam Saravanan,
E-mail: maheshorth@gmail.com

Copyright: © the author(s), publisher and licensee Medip Academy. This is an open-access article distributed under the terms of the Creative Commons Attribution Non-Commercial License, which permits unrestricted non-commercial use, distribution, and reproduction in any medium, provided the original work is properly cited.

ABSTRACT

Background: Lumbar disc herniation is the most common cause of low back pain and significant disability with economic impact too. Management of disc herniation is challenging, often confusing when surgical treatment is considered, because of frequent failures after surgery in many patients to relieve symptoms.

Methods: Our study was a prospective study conducted in Department of Orthopaedics, Coimbatore medical college. Thirty six patients operated for intervertebral disc herniation of lumbar spine from March 2015 to February 2017 were included in the study.

Results: VAS score was not significant between two groups, at one month, but at 6 months, PLIF group had better VAS score and was statistically significant. ODI scores showed a similar pattern.

Conclusions: Discectomy for symptomatic lumbar disc herniation is still the procedure of choice but with any subtle instability, then it should be combined with stabilisation like posterior lumbar interbody fusion.

Keywords: Lumbar disc herniation, PLIF, Discectomy

INTRODUCTION

Low back pain is the commonest cause of chronic pain, disability and absence from work among middle aged south Indian population, especially obese and females. Out of these patients, lumbar disc herniation is a common cause.^{1,2} Management of disc herniation is a challenge to orthopaedic surgeon because of confusions regarding conservative versus surgical treatment and may even be frustrating when surgery fails to relieve symptoms. We know that failed back syndromes happen more frequently

after discectomy than other spinal surgeries. To summarise, lumbar disc disease may be called as unsolved spinal disorder.

Discectomy is an accepted comprehensive treatment, can give excellent results in majority of patients with symptomatic relief and early satisfactory results.³⁻⁵ However the long term results of discectomy would become less predictable with satisfactory outcome in 40 to 80 percent of patients only.⁶

The concept of posterior lumbar interbody fusion has gained importance in this context and the development of key principles and techniques goes to Cloward⁷ (PLIF). With PLIF, the maximum load sharing anterior column anatomy is restored.

The objective of this study is to evaluate and compare the functional outcome of surgical treatment of lumbar disc herniation by two methods; discectomy alone and discectomy with posterior lumbar interbody fusion (PLIF).

METHODS

Our study was a prospective study conducted in Department of Orthopaedics, Coimbatore Medical College Hospital, Coimbatore. Thirty six patients were operated for intervertebral disc herniation of lumbar spine from March 2015 to February 2017, included in the study.

Inclusion criteria

Inclusion criteria were lumbar disc prolapse with sciatica not relieved by conservative treatment for atleast six weeks, with MRI evidence of disc herniation; age 30 to 65 years, both male and females; progressive or new neurological deficit or cauda equine syndrome during conservative management.

Exclusion criteria

Exclusion criteria were congenital deformities of spine; malignancy (Primary or metastases in spine); infection; associated high grade spondylolisthesis; spinal canal stenosis, not caused by disc herniation.

Preoperative evaluation

After routine physical examination for confirmation of physical and neurological signs, radiographs of lumbosacral spine which includes anteroposterior, flexion and extension stress lateral views and MRI scan were done as standard protocol. After treating pre-existing comorbidities and optimisation of patient, patients were posted for elective surgery.

Surgical technique

Under general anaesthesia, standard procedures followed for conventional discectomy or discectomy with posterior lumbar interbody fusion, as the case may be.

In six patients, bone graft alone harvested from posterior iliac crest along with bone chips from excised lamina and spinous process was used.

In 10 cases, titanium cages filled with autologous cancellous bone grafts were used.

Postoperative protocol

In the discectomy group, patients were mobilised from bed to chair on same day and are allowed to walk from first postoperative day. Lifting weights and other strenuous activities were restricted for upto three weeks.

In the PLIF group, patients mobilised on postoperative day 1, as tolerated and were made to ambulate with lumbosacral corset within a week.

All patients were followed up regularly at 3 weeks, 2 months, 6 months and 1 year that includes clinical assessment (VAS score, ODI score) and X rays.

The fusion is assessed using Brantigan steffe classification.

Follow up assessment

6 months and one year function and pain assessment done by visual analogue score and Oswestry disability index (ODI) and radiological assessment of fusion using bone fusion classification by Brantigan and Steffe.

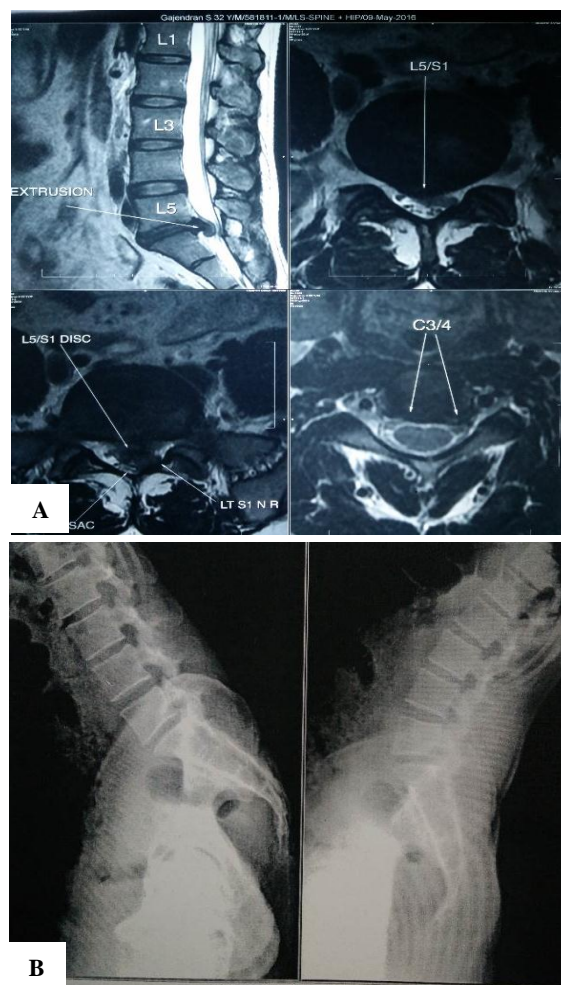


Figure 1: Discectomy: (A) Preoperative MRI image, (B) post operative X ray.

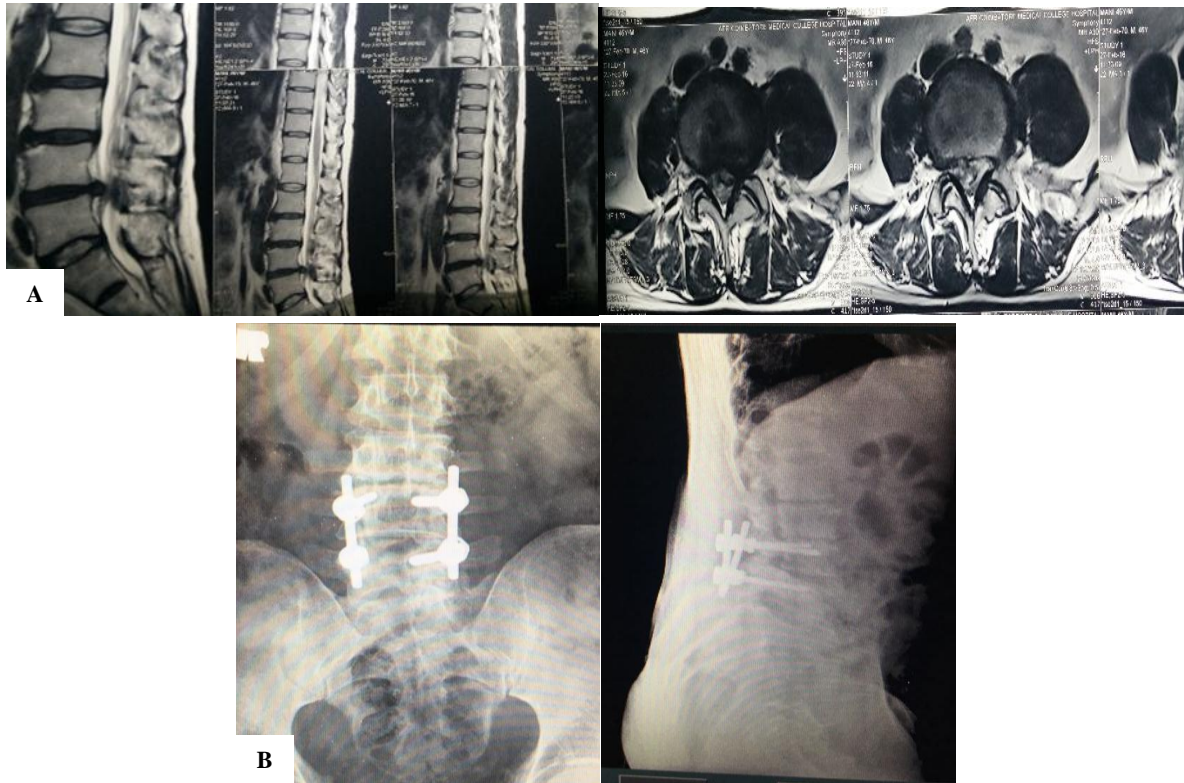


Figure 2: PLIF with bone graft only. (A) Preop, (B) Postop.

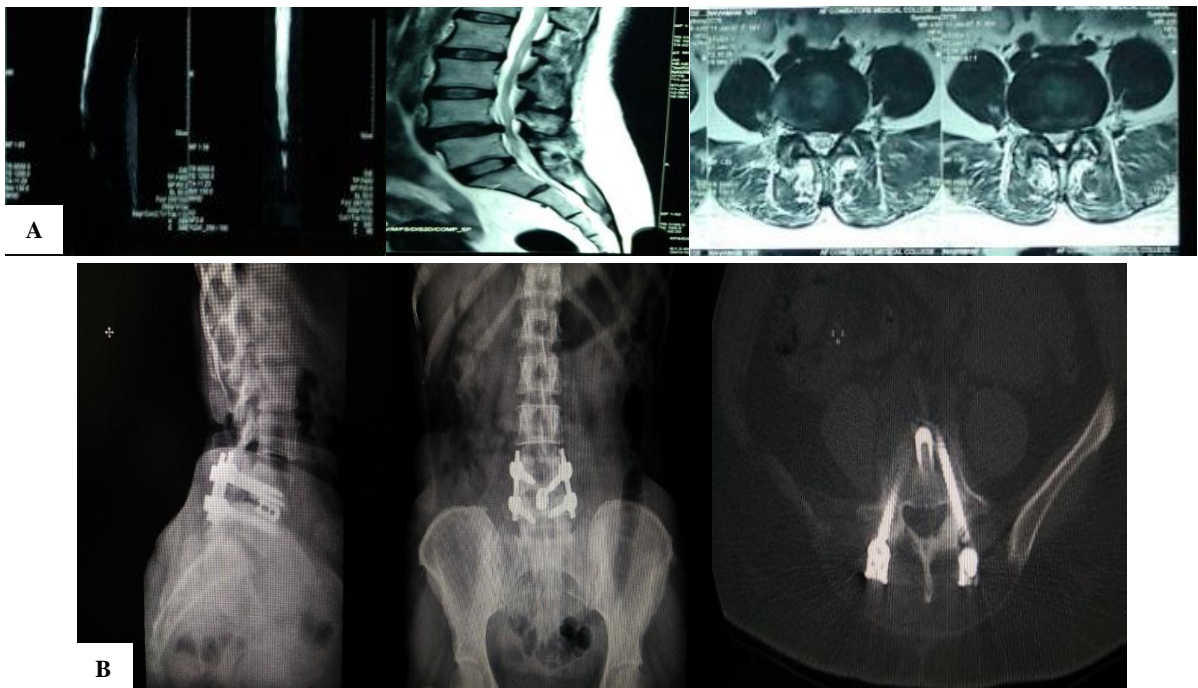


Figure 3: Discectomy with PLIF with titanium cage. (A) Pre operative MRI, (B) post operative X ray.

RESULTS

Demographics of the study are illustrated in Figure 4, 5 and Table 1. Among the thirty six patients in our study 16 patients (44%) underwent discectomy and 20 patients

(56%) underwent discectomy with fusion (Table 1). Among the 16 patients in the PLIF group, Brantigan grade 3 union were present in 12 cases, grade 2 union were attained in 4 patients in whom only bone grafting was done.

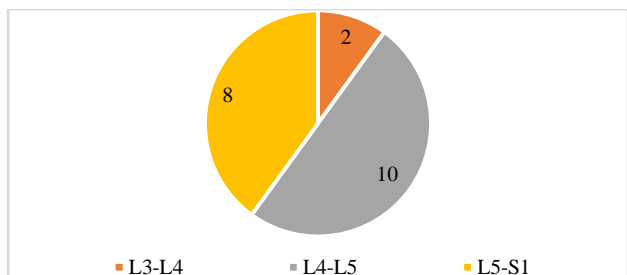


Figure 4: Chart depicting Lumbar levels and percentage.

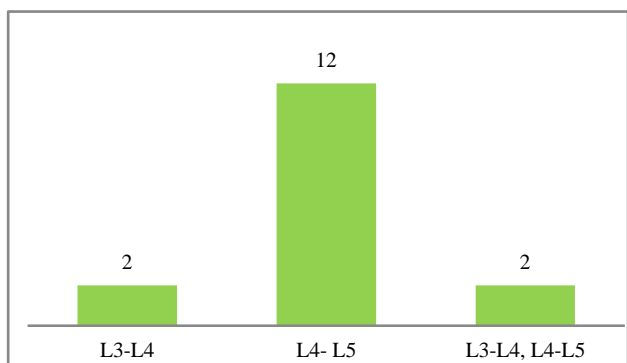


Figure 5: Segments involved in proportion.

Table 1: Various treatment groups.

Treatment group	No. of patients	Percentage (%)
Discectomy with posterior lumbar interbody fusion	16	44
Discectomy	20	56
Total	36	100

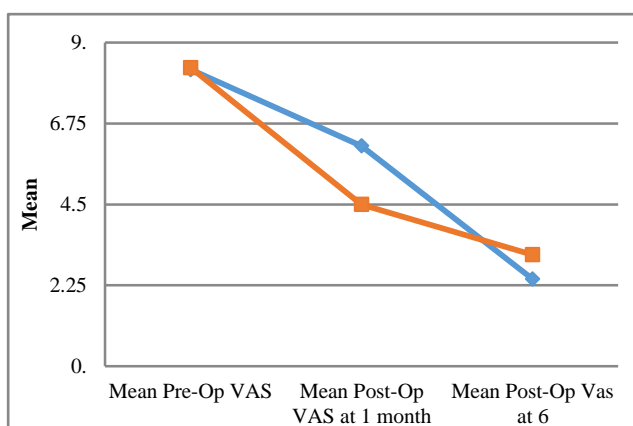


Figure 6: VAS score prior and after surgery.

VAS scores was not significant between two groups at one month, but at 6 months follow up, it was observed that PLIF group had a better VAS score. The mean difference in the VAS prior and after surgery is more in PLIF group and found to be statistically significant (Figure 6). The mean difference in ODI was more for

PLIF group compared with the discectomy group and is found to be statistically significant with a $p=0.048$ (Figure 7). The long term visual analogue scale and ODI is better in patients who underwent PLIF surgery.

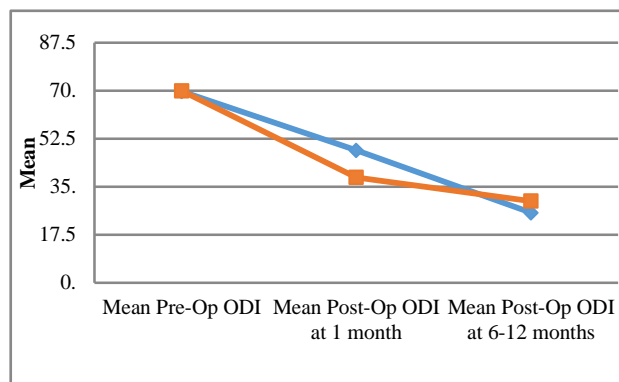


Figure 7: ODI Score before and after surgery.

Complications

Four patients had superficial infections in the discectomy group and two for PLIF group. Standard protocol for early post op infection was followed and the infection subsided.

Dural tear occurred in 4 patients. Three for discectomy and 1 for the PLIF group. We did not have any new neurological deficit after surgery in any patient.

DISCUSSION

Lumbar disc herniation is the most common cause of low back pain and significant disability including absence from work among middle aged south Indian population especially obese patients and females. Of these patients with low back ache, disc herniation is a common cause.^{1,2} Management of disc herniation is challenging, often confusing especially when it comes to decision making on surgical treatment and may even be frustrating for surgeon when surgical management fail to relieve the symptoms

Discectomy is time tested and widely accepted surgical treatment when conservative management fails or when complications (Eg: cauda equina syndrome/ peripheral neurological deficits) develops.³ However the long term results of discectomy would become less predictable with satisfactory outcome in 40 to 80 percent of patients only. Recurrent low back pain after surgery is referred to as failed back syndrome is common in patients who underwent discectomy than other spinal procedures.⁸

The concept of fusion was evolved to address this relapse of low back pain which could be due to multiple factors. Modic changes is another independent cause of discogenic low back pain.^{9,10} It is of three types, inflammatory, fibrosis and sclerosis based on MRI.

To address the complications and failures, posterior and transforaminal lumbar interbody fusion techniques emerged.¹¹⁻¹⁴

In our study we have used only single cage instead of conventional dual cages. Zhang et al aimed to study how cage placement affects bone remodelling after PLIF surgery.¹⁵ They found that the single cage model demonstrated superior bone development in the bone graft when placed under a constant 400 N axial compressive load. The results showed that in the initial state prior to any bone remodelling, cage stress, cage subsidence and cage dislodgement in the single cage model were all greater than in the coupled cage model. But after the bone remodelling there weren't any difference. They concluded that based on the long-term results, instrumented PLIF with a single cage could also be encouraged in clinical practice

Among the 36 patients included in our study 16 (44%) patients underwent discectomy with posterior lumbar interbody fusion and 20 (56%) patients underwent discectomy alone. The L4-L5 segment is the commonly involved segment in the study. There is no difference in the VAS score at 1 month but significantly better VAS scores for PLIF group at 6 months follow up.

The long term VAS and ODI were better in patients who underwent PLIF procedure.

CONCLUSION

Posterior lumbar interbody fusion with either bone graft alone or with bone graft and titanium cage provides good results in patients who have lumbar disc herniation. The functional outcome was better in the group where interbody cage along with bone graft is used in posterior lumbar interbody fusion. But it requires a longer duration of follow up to find the superiority of the graft material used. The pitfalls in our study were non randomized assignment of the patient into group suggesting that the choice of surgery might have been biased by the surgeon or the patient's preference.

Funding: No funding sources

Conflict of interest: None declared

Ethical approval: Not required

REFERENCES

1. Atlas SJ, Keller RB, Chang Y, Deyo RA, Singer DE. Surgical and non surgical management of sciatic secondary to lumbar disc herniation. Spine. 2001;26:1179-87.
2. DePalma AF, Rothman RH. Surgery of lumbar spine. Clin Orthop. 1969;63:162-70.
3. Tay ECK, Chach PB: midline prolapse of lumbar intervertebral disc with compression of cauda equine. J Bone Joint Surg Br. 1979;61:43-6.
4. Hanley EN Jr, Shapiro DE. The development of low-back pain after excision of a lumbar disc. J Bone Joint Surg Am. 1989;71:719-21.
5. Toyone T, Tanaka T, Kato D, Kaneyama R. Low-back pain following surgery for lumbar disc herniation. A prospective study. J Bone Joint Surg Am. 2004;86:893-6.
6. Satoh I, Yonenobu K, Hosono N, Ohwada T, Fuji T, Yoshikawa H. Indication of posterior lumbar interbody fusion for lumbar disc herniation. J Spinal Disord Tech. 2006;19:104-8.
7. Cloward RB. The treatment of ruptured intervertebral discs by vertebral body fusion: Indications, operative technique, after care. J Neurosurg. 1953;10:154-68.
8. Parker SL, Mendenhall SK, Godil SS, Sivasubramanian P, Cahill K, Ziewacz J, et al. Incidence of low back pain after lumbar discectomy for herniated disc and its effect on patient-reported outcomes. Clin Orthop Relat Res. 2015;473(6):1988-99.
9. Maatta JH, Wadge S, MacGregor A, Karppinen J, Williams FM. vertebral endplate (modic) change is an independent risk factor for episodes of severe and disabling Low back pain. Spine. 2015;40(15):1187-93.
10. Cao P, Chen Z, Zheng Y, Wang Y, Jiang L, Yang Y, et al. Comparison of simple discectomy and instrumented posterior lumbar interbody fusion for treatment of lumbar disc herniation combined with Modic endplate changes. Chin Med J (Engl). 2014;127(15):2789-94.
11. DiPaola CP, Molinari RW Posterior lumbar interbody fusion. J Am Acad Orthop Surg. 2008;16(3):130-9.
12. Agazzi, S., Reverdin, A., May, D. Posterior lumbar interbody fusion with cages: an independent review of 71 cases. J Neurosurg. 1999;91:186-92.
13. Wang JC, Dailey AT, Mummaneni PV, Ghogawala Z, Resnick DK, Watters WC 3rd, et al. Guideline update for the performance of fusion procedures for degenerative disease of the lumbar spine. Part 8: lumbar fusion for disc herniation and radiculopathy J Neurosurg Spine. 2014;21:48-53.
14. Fischer CR. Posterior Lumbar Fusion: Choice of Approach and Adjunct Techniques. J Am Acad Orthop Surg. 2014;22(8):503-11.
15. Zhang M, Pu F, Xu L, Zhang L, Yao J, Li D, et al. Long-term effects of placing one or two cages in instrumented posterior lumbar interbody fusion Int Orthop (SICOT). 2016;40:1239.

Cite this article as: Imam Saheb MB, Saravanan MK, Mandice J, Subramaniyan VKA. Comparative evaluation of functional outcome of discectomy versus discectomy with posterior lumbar interbody fusion for treatment of lumbar disc herniation. Int J Res Orthop 2019;5:651-5.