

## Original Research Article

# Role of PFN in ipsilateral fracture neck and shaft femur: a single solution to double fracture

Anshul Dahuja<sup>1</sup>, Shiraz Bhatt<sup>2\*</sup>, Kapil Bansal<sup>1</sup>, Rashmeet Kaur<sup>3</sup>, Radhe Shayam<sup>1</sup>

Department of Orthopaedics, <sup>1</sup>GGS Medical College and Hospital, Faridkot, <sup>2</sup>Adesh Institute of Medical Sciences and Research, Bathinda, Punjab, India

<sup>3</sup>Department of Radiodiagnosis, GGS Medical College and Hospital, Faridkot, Punjab, India

**Received:** 20 March 2018

**Revised:** 08 April 2018

**Accepted:** 09 April 2018

### \*Correspondence:

Dr. Shiraz Bhatt,

E-mail: shirazbhatt@gmail.com

**Copyright:** © the author(s), publisher and licensee Medip Academy. This is an open-access article distributed under the terms of the Creative Commons Attribution Non-Commercial License, which permits unrestricted non-commercial use, distribution, and reproduction in any medium, provided the original work is properly cited.

## ABSTRACT

**Background:** Ipsilateral, concomitant femoral neck and shaft fracture is a rare fracture pattern that presents a diagnostic and treatment challenge. A variety of management modalities have been tried to treat this complex fracture pattern ranging from conservative approach to recently introduced proximal femoral nails (PFN).

**Methods:** We analysed the retrospective data of 25 consecutive patients who had sustained a high energy trauma who had concomitant ipsilateral fractures of the femoral shaft associated with proximal femur fractures treated with PFN between January 2010 and January 2017.

**Results:** Average follow up period was 1.2 years. All ipsilateral neck and shaft fractures were united with proximal femur nail (PFN). Neck fracture union averaged 4.3 months (range, 3–6 months). Shaft fracture union averaged 5.4 months (range, 4–7 months). Eighteen patients (70%) had a good functional result, five patients (21%) had fair result and in two patients the result (9%) was poor.

**Conclusions:** We observed although technically demanding, the reconstruction nail is an acceptable, cost effective and minimal invasive alternative for the management of concomitant ipsilateral fractures of the femoral neck and shaft, with a good functional outcome and fewer complications.

**Keywords:** Ipsilateral, Proximal femoral nail

## INTRODUCTION

Ipsilateral fractures of the proximal femur and femoral shaft are rare injuries followed by high velocity trauma. The existing literature documents an incidence ranging from 5 to 6%.<sup>1</sup> In 19-31% of the cases the proximal femur fracture is often neglected, as the femoral fracture takes the priority.<sup>2,3</sup> The majority of the injuries were the result of a motor vehicle accident, fall from height and industrial accidents. Trauma force found to cause buckling of the shaft and shearing the neck of femur. Hence hip fractures are non-displaced or minimally displaced and shaft fractures are severely comminuted.

Therefore, hip fractures are easily missed and shaft fractures bear significant healing problems.<sup>4,5</sup>

Many preferences for treatment have been described in the literature; no method has been proven to be exclusively more effective than the others.<sup>5</sup> These techniques include simultaneous use of two implants like transcervical screwing and shaft plating, intramedullary fixation with additional transcervical fixation, retrograde intramedullary nailing with femoral neck-lag screws, and now shifting the trend to single implant like reconstruction nailing.<sup>6-12</sup> Recently, second-generation intramedullary locking nails have been used in the

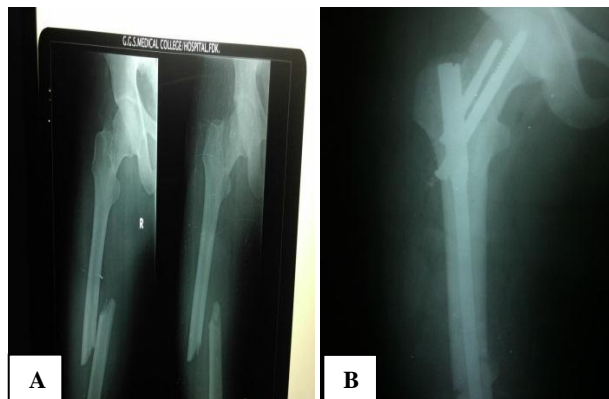
treatment of this complicated fracture pattern, providing fixation of both fractures with a single implant.

We analyzed functional outcome with a single procedure of proximal femoral nail (PFN) in concomitant ipsilateral fractures of proximal femur and shaft of femur.

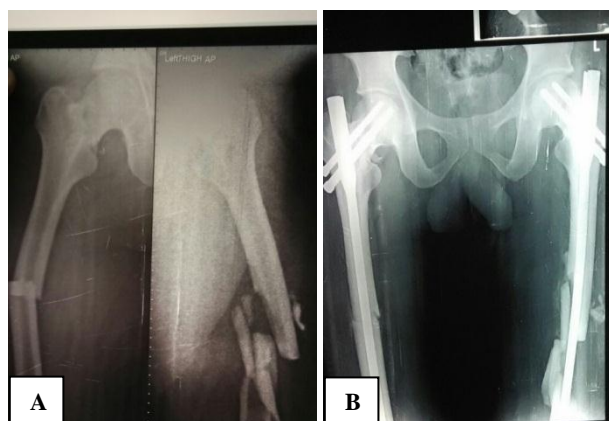
## METHODS

We conducted a retrospective study of twenty-five patients with an ipsilateral femoral neck and shaft fractures, who were treated with PFN from January 2010-January 2017 with ethical board approval. This included 22 males and three females with average age of 35 years (range 25-60 years). Twenty patients had high velocity road traffic accident, among these twelve patients were injured in automobile accident, eight were involved in two wheeler accidents, three had fall from height and two had iatrogenic femur neck fracture during antegrade nailing for femoral shaft fracture. All the patients had digital radiographs of the pelvis including both hips, thigh including knee and hip joint. Both orthopaedic and non orthopaedic associated injuries were documented. Five patients had significant associated injuries. Two patients had head injury, two patients had intra-abdominal injuries and one patient had pulmonary contusions. Six patients sustained fractures of other extremities, which included two had contralateral fracture shaft of femur, two had fractures tibia, one had fracture humerus and two had fracture forearm bones. One patient had fracture of bilateral neck femur and bilateral shaft femur. Hip fractures were classified into two main groups, neck and peritrochanter. They were further classified into Garden (neck fractures) and Boyd and Griffin (trochanter). The femoral shaft fractures were also classified with Winquist classification of comminution, site and also into open or closed fractures.<sup>13</sup> Femoral neck fractures were classified according to Garden's classification, five were grade I, ten were grade II and three were grade III. Intertrochanteric fractures were classified by Boyd & Griffin's criteria, three were type I, two were type II, and two were type III. There were six fractures of shaft of femur in proximal third, fifteen fractures in mid third, and four fractures in distal third. Once the patient's general condition stabilized, they were treated with long proximal femoral nail (PFN) as shown in Figure 1. We had one patient with bilateral neck femur and shaft femur fracture operated with PFN as shown in Figure 2. All patients were followed up for a period of six months to two years with a follow up protocol of 3 months, 6 months, 1 year, 1.5 and 2 years. Average follow up period was 1.2 years. After the operation, patients were allowed to ambulate with partial weight bearing as early as possible. Quadriceps strengthening and knee-motion exercise were encouraged. Patients were followed-up in the outpatient department at 4-6 weeks interval to assess the clinical and radiographical fracture healing processes. Protected weight bearing was advised until bony union. Radiographical union was defined as healing trabeculae across the fracture site or solid callus

with cortical density connecting both fracture fragments. Nonunion was defined as a fracture site which remained un-healed one year after treatment or a fracture which required a second surgery to achieve union.<sup>4,14</sup> Functional results were assessed according to the Friedman and Wyman classification.<sup>7</sup>



**Figure 1 (A and B): Ipsilateral neck and shaft femur operated with PFN.**



**Figure 2 (A and B): Bilateral neck and shaft femur operated with PFN.**

## RESULTS

All ipsilateral neck and shaft fractures were united with proximal femoral nail (PFN). Neck fracture union averaged 4.3 months (range, 3-6 months). Shaft fracture union averaged 5.4 months (range, 4-7 months). No patient had avascular necrosis of the femoral head. There were two femoral shortening due to comminution. Delayed union was recorded in five femoral shaft fracture. One patient had superficial wound infection (grade II open shaft fracture) that was controlled by local care and proper antibiotics. No cases of deep venous thrombosis or fat embolism were recorded. No hardware failure of any component of the nail was noted. Technical errors resulted in varus hip in one case due to the lateral portal of the nail. In two cases distraction at fracture neck femur side and two cases with comminuted intertrochanteric fractures and two patients with fracture shaft of femur

where delayed union seen. Both the femoral neck and intertrochanteric fractures were united within six months from date of injury without any further intervention. Non-union was observed in two patients with fracture shaft of femur due to comminution and distraction at fracture site, which required bone grafting to heal and fracture healed on follow up. One patient had early weight bearing which resulted in varus angulation and inferolateral comminution of neck. Two patients with type III intertrochanteric fractures went into varus malunion due to opening up of fractures line laterally, while inserting

the nail and hip abductors pulled up proximal fragment. Twelve patients had full range of motion at hip joint, five patients had 0-110 degrees ROM and six had ROM of 0-100 degrees. Only two patients had ROM less than 100 degrees. None of the patients had fixed flexion deformity at hip. Results (Table 2) were evaluated based on the criteria adopted by Friedman and Wyman classification.<sup>7</sup> Eighteen patients (70%) had a good functional result, five patients (21%) had fair result and in two patients the result (9%) was poor.

**Table 1: Demographic details along with radiographically union duration.**

S. No.	Demographic details	Values
1.	Total number of cases	25
2.	Male:female	22:3
3.	Pauwels grade (neck fracture) I/II/III	4/7/5
4.	Boyd Griffin I/II/III/IV	2/2/5/0
5.	Average age	35.5 yrs
6.	Average time to union	
	a) Neck	4.3
	b) Shaft femur	5.4
7.	Average total follow up	1.2 yrs
8.	Complications	5
9.	Any revision surgery	3

**Table 2: Friedman Wyman’s functional assessment system.**

Result	Impaired daily living activities	Pain	Loss of ROM in hip and knee	Number of cases
<b>Good</b>	No	No	Less than 20%	18
<b>Fair</b>	Mild	Mild to moderate	20-50%	5
<b>Poor</b>	moderate	Severe	More than 50%	2

## DISCUSSION

Ipsilateral femoral neck and shaft fractures pose a diagnostic and treatment dilemma.

Stabilization of this complex fracture is a controversial issue. The spectrum has shifted from conservative management to operative treatment and the lack of consensus about best modality of fixation has led to evolution of various techniques and numerous implants over a period of time. Several techniques have been described; no ideal method of fracture fixation is found in the literature.<sup>2,15-17</sup> A meta-analysis related to 722 cases from 65 published studies found no superiority of an implant over the other. Alho reported that second-generation nails (reconstruction nails) generated outcomes comparable to those of first-generation locked nails with separate hip screws; these two kinds of fixations assured better results than other traditional fixation methods.<sup>15</sup> On the contrary Wiss et al reported less satisfactory results with closed reamed antegrade intramedullary nailing with supplemental screw fixation of the femoral neck and shaft fractures because of a high rate (18%) of symptomatic varus nonunion of the femoral

neck fracture.<sup>9</sup> The Y-nail, Ender’s pins, and the Ziekol nail usually distract the femoral neck fracture.<sup>5</sup> Another study used partially threaded cancellous screws with interlocking nail system and fetched satisfactory results.<sup>16</sup>

Good results have been reported using second-generation reconstruction nails.<sup>7,8,15</sup> Biomechanical studies of cadaveric femurs demonstrate that the load bearing strength of the reconstruction nail fixation of the neck fracture is superior than that achieved by cancellous screw fixation alone.<sup>21</sup> The disadvantage of the primary procedure is that it is a technically demanding operation, and requires good experienced surgeon for accurate placement of the proximal screws in the head and neck specially when there is displaced neck fracture. Many surgeons place temporary Kirschner wires in the femoral neck.<sup>7,15</sup> The use of provisional Kirschner-wire fixation of the neck fracture proved effective in our series.

A couple of studies faced several technical hurdles due to the straightness of the nail relative to the curved femoral canal.<sup>17,18</sup> In the current study also, the lateral portal led to a varus hip in one case. The distal tip of the nail violated the anterior cortex of the distal femur; the distal

femur was not aligned properly during insertion, and eventually, there was 15° valgus.

The most unwanted and long term complications are non union and avascular necrosis which have been discussed in several studies. Most of the studies didn't encounter non union of neck femur fracture with reconstruction nail but varied percentage of non union or delayed union of shaft femur fracture.<sup>19-21</sup>

Jain et al reported one case each of nonunion of the neck fracture, avascular necrosis of the femoral head, and femoral shaft fracture united in varus. There were four cases of nonunion and six cases of delayed union of the femoral shaft fracture. The mean time for union of the femoral neck fracture and shaft femur fracture was 15 weeks and 22 weeks respectively.

In our study Neck fractures healed within an average of 4.3 months (range, 3–6 months), and shaft fractures healed within an average of 5.4 months (range, 4–7 months). All patients had a good functional outcome and had complete fracture union. One of the fractures healed in mild varus radiologically, which was probably due to a technical error of nail entry being to lateral. None of the patients in our study had nonunion of fracture or features suggestive of avascular necrosis of head of femur. None of our cases had implant failure. Our results are comparable with other recent studies using the Russell-Taylor reconstruction nail for the treatment of ipsilateral hip and shaft fractures.

As per the author observation in this study and from the past literature, fracture shaft femur takes attention at first sight but intraoperative we are more concerned and focus on neck femur reduction and shaft femur fracture compression receives least priority, which could be one of the reason for delayed and non union of shaft femur fractures more than non union of neck femur fractures in this particular fracture scenario.

After scratching the world literature, Casey and Chapman reported a rate of 4% avascular necrosis of the femoral head after these fractures.<sup>3</sup> Wiss and co-workers reported a 6% and Swiontkowski et al reported 22% incidence osteonecrosis.<sup>2,9</sup> Though numerous authors report a union rate of 100% for both fracture, nonunion of the femoral neck and shaft remains a potential complication. Alho postulated that the incidence of osteonecrosis in ipsilateral femoral neck shaft fractures is less than that in simple femoral neck fracture and this low rate may be attributed to energy dissipation.<sup>15</sup> At a mean follow-up of 26 months, no case of avascular necrosis was reported in our study; signs and symptoms of osteonecrosis, however, develop in young adult patients, in particular more than 3 years after injury.<sup>4</sup> Many authors favour Wolinsky and colleagues that fixation of the femoral neck should take precedence over fixation of the femoral shaft.<sup>1,4,20</sup> This decreases the risk of further disrupting the

blood supply to the femoral head, leading to a decrease in the incidence of avascular necrosis.

Mechanism of injury is that of a force applied to a flexed, abducted femur with the knee flexed (motorcycle injury), so few patients also have knee injuries and most common mode of transport in our region is a two wheeler favoring the mechanism and type of similar fracture pattern with multisystem injury.<sup>3,16,22,23</sup>

Adequate knee examination is important as is the evaluation of the knee stability after femoral fixation; knee injury is frequently overlooked, resulting in residual disability and less than optimal results. Antegrade nailing is preferred, as opposed to retrograde nailing, which may risk further damage to an already traumatized knee.<sup>8</sup>

In our series, we registered 2 patients (20%) with bad results probably because of associated knee injuries and 8 (80%) with good and average results. These functional results were similar with those of literature because the function appeared to be good in 63%–93% of cases.<sup>9,10</sup> Douša et al reported good results of ipsilateral fractures of the proximal femur and the femoral shaft treated by the long PFN.<sup>24</sup> They found results do not differ from those reported by other authors. Our results goes parallel with those of Pavleka et al who observed 63.9% good, 30.6% fair, and 5.5% poor results.<sup>25</sup>

Many studies documented that the results of functional assessment are principally qualitative and the use of valid tools is scarce.<sup>9,10,26</sup>

### **Limitations**

Besides, the rarity of this injury makes it difficult to analyze and most of studies are retrospective with small sample size (inferior to 40 cases). No further studies such as bone scan, tomography, computed tomography or magnetic resonance imaging were used to assess the viability of the femoral head. These studies are insufficient to confirm the difference in functional outcomes between one-implant group and two-implant group. A randomized prospective study is further needed with a longer follow up.

### **CONCLUSION**

We observed although technically demanding, the reconstruction nail is an acceptable, cost effective and minimal invasive alternative for the management of concomitant ipsilateral fractures of the femoral neck and shaft, with a good functional outcome and fewer complications.

*Funding: No funding sources*

*Conflict of interest: None declared*

*Ethical approval: The study was approved by the institutional ethics committee*

## REFERENCES

1. Wolinsky PR, Johnson KD. Ipsilateral femoral neck and shaft fractures. *Clin Orthop*. 1995;318:81-90.
2. Swiontowski M, Hansen S, Kellam J. Ipsilateral fractures of the femoral neck and shaft- a treatment protocol. *J Bone Joint Surg Am*. 1984;66:260-8.
3. Casey MJ, Chapman MW. Ipsilateral concomitant fractures of the hip and femoral shaft. *J Bone Joint Surg Am*. 1979;61:503-9.
4. Bennett FS, Zinar DM, Kilgus DJ. Ipsilateral hip and femoral shaft fractures. *Clin Orthop*. 1993;296:168-77.
5. Gadegone WM, Salphale YS. Proximal femoral nail-an analysis of 100 cases of proximal femoral fractures with an average followup of 1 year. *Int Orthop*. 2007;31:403-8.
6. Swiontkowski M F. Ipsilateral femoral shaft and hip fractures. *Orthop Clin North Am*. 1987;18(I):73-84.
7. Friedman RJ, Wyman ET Jr. Ipsilateral hip and femoral shaft fractures. *Clin Orthop*. 1986;208:188-94.
8. Zettas JP, Zettas P. Ipsilateral fractures of the femoral neck and shaft. *Clin Orthop*. 1981;160:63-73.
9. Wiss DA, Sima W, Brien WW. Ipsilateral fractures of the femoral neck and shaft. *J Orthop Trauma*. 1992;6:159-66.
10. Gadegone WM, Salphale YS. Proximal femoral nail-an analysis of 100 cases of proximal femoral fractures with an average follow up of 1 year. *Int Orthop*. 2007;31:403-8.
11. Barquet A, Fernandez A, Leon H. Simultaneous ipsilateral trochanteric and femoral shaft fracture. *Acta Orthop Scand*. 1985;56:36-9.
12. Russell TA. Ipsilateral femoral neck and shaft fractures. *Clin Orthop Relat Res*. 1986;208:188-94.
13. Winquist RA, Hansen ST, Clawson DK. Closed intramedullary nailing of femoral fractures. A report of five hundred and twenty cases. *J Bone Joint Surg (Am)*. 1984;66:529-39.
14. Boulton CL, Pollak AN. Special topic: ipsilateral femoral neck and shaft fractures- does evidence give us the answer? *Injury*. 2015;46:478-83.
15. Alho A. Concurrent ipsilateral fractures of the hip and femoral shaft. A meta-analysis of 659 cases. *Acta Orthop Scand*. 1996;67:19-28.
16. Bucholz RN, Rathjen K. Concomitant Ipsilateral fractures of the hip and femur treated with interlocking nails. *Orthopaedics*. 1985;8:1402-6
17. Gibbons CL, Gregg-Smith SJ, Carrell TW, Murray DW, Simpson AH. Use of the Russell-Taylor reconstruction nail in femoral shaft fractures. *Injury*. 1995;26:389-92.
18. Bose WJ, Corces A, Anderson LD. A preliminary experience with the Russel Taylor reconstruction nail for complex femoral fractures. *J Trauma*. 1992;32:71-6.
19. Randelli P, Landi S, Fanton F, Hoover GK, Morandi M. Treatment of ipsilateral femoral neck and shaft fractures with the Russell-Taylor reconstructive nail. *Orthopedics*. 1999;22:673-6.
20. Hossam EM, Adel MH, Emad EY. Ipsilateral fracture of the femoral neck and shaft, treatment by reconstruction interlocking nail. *Arch Orthop Trauma Surg*. 2001;121:71-4.
21. Jain P, Maini L, Mishra P, Upadhyay A, Agarwal A. Cephalomedullary interlocked nail for ipsilateral hip and femoral shaft fractures. *Injury*. 2004;35:1031-8.
22. Oh CW, Oh JK, Park BC, Jeon IH, Kyung HS, Kim SY, et al. Retrograde nailing with subsequent screw fixation for ipsilateral femoral shaft and neck fractures. *Arch Orthop Trauma Surg*. 2006;126:448-53.
23. Abalo A, Dossim A, OuroBangna AF, Tomta K, Assiobo A, Walla A. Dynamic hip screw and compression plate fixation of ipsilateral femoral neck and shaft fractures. *J Orthop Surg*. 2008;16:35
24. Douša P, Bartoníek J, Pavelka T, Lunáček L. Ipsilateral fractures of the proximal femur and the femoral shaft. *Acta Chir Orthop Traumatol Cech*. 2010;77:378-88.
25. Pavleka T, Lihart M, Matejka J, Vyskocil V. Osteosynthesis of ipsilateral hip and femoral shaft fracture with a long PFN. *Zentralbl Chir*. 2005;130:148-52.
26. Chen CH, Chen TB, Cheng YM, Chang JK, Lin SY, Hung SH. Ipsilateral fractures of the femoral neck and shaft. *Injury*. 2000;31:719-22.

**Cite this article as:** Dahuja A, Bhatti S, Bansal K, Kaur R, Shayam R. Role of PFN in ipsilateral fracture neck and shaft femur: a single solution to double fracture. *Int J Res Orthop* 2018;4:384-8.