

## Original Research Article

# Functional outcome evaluation of distal humerus fracture fixation

Boddu Sunil, Sandeep Krishna Avulapati\*, Suraj Kumar Choudhary, Susmitha Koneru

Department of Orthopedics, Balaji Institute of Surgery, Research and Rehabilitation for Disabled (BIRRD), Sri Padmavathi Medical College for Women, SVIMS, Tirupati, Andhra Pradesh, India

**Received:** 10 February 2020

**Revised:** 26 February 2020

**Accepted:** 27 February 2020

### \*Correspondence:

Dr. Sandeep Krishna Avulapati,  
E-mail: [sundeepavulapati@gmail.com](mailto:sundeepavulapati@gmail.com)

**Copyright:** © the author(s), publisher and licensee Medip Academy. This is an open-access article distributed under the terms of the Creative Commons Attribution Non-Commercial License, which permits unrestricted non-commercial use, distribution, and reproduction in any medium, provided the original work is properly cited.

### ABSTRACT

**Background:** Distal humerus fracture are complex, difficult to reduce and fix, cumbersome post-operative mobilization, and yet functional outcome is doubtful. Though various treatment modalities available for past many decades ranging from conservative management, K wire fixation to plate and screws, but still treatment remains difficult. The objective of the study was to assess functional outcome of operative fixation of distal humerus with locking plate and screws.

**Methods:** Prospective study was done in during November 2015 to June 2016 in Vydehi Institute of Medical Sciences and Research Centre, Bengaluru. Patients with distal humerus fractures who were admitted into hospital for operative treatment after fulfilling inclusion and exclusion criteria were included into study. They were followed up to 6 months post-operatively. Functional outcome evaluation was done with Mayo's elbow performance score.

**Results:** 30 patients were included into study with full data. We had excellent, good, fair and poor outcome in 17, 8, 3, 2 patients respectively. Except for infection in one, elbow stiffness in two and non-union in two patients, we had no other complications.

**Conclusions:** Management of distal humerus fractures with preoperative evaluation, pre-operative planning, use of locking plate and screws, early mobilization can result in good functional outcome.

**Keywords:** Distal humerus fractures, Locking plates and screws, Mayo's elbow performance score, Non union

### INTRODUCTION

Though uncommon, 2-6% of all fractures, distal humerus fractures account for 30% of all elbow fractures.<sup>1</sup> Elderly person fall, sports injuries, road traffic accidents are common causes of distal humerus fractures. Classification of these fractures not only differentiates, but also guides them towards standardized treatment protocols. A.O Muller classification is widely accepted in the literature for its description, reproducibility and treatment directed to that particular type of fracture. Difficulty in achieving the goal of good fracture reduction and fixation are due to complex joint anatomy, forces acting across elbow, osteoporosis and decreased primary stability. This can result in 35% complications and poor results.

Non operative treatment traditionally results in doubtful functional outcome with limitation of elbow range of movements.<sup>2</sup> Ideal implant should provide adequate stability under physiological loads and the bone implant interface should not be alternated under cyclic stress.<sup>1</sup> It should be easily applicable, contourable with anatomical variations of the distal humerus.

Fracture fixations by K wires and distal one third semi tubular plate have resulted in a high percentage of implant failures, in presence of metaphyseal communitation. In osteoporotic bone and in very distal fractures, screw placement becomes difficult because of limited space

available, which makes stable anchorage of each screw crucial.

In this preview we made an attempt to evaluate the results of surgical management of fractures of distal end humerus using distal humeral locking plates.

The objective of the study was to assess reduction, stability of fixation of distal humerus fractures with plate, screws and to assess maintenance of reduction, and range of movements post-operatively.

**METHODS**

A prospective study was carried out in department of orthopedics, Vydehi Institute of Medical Sciences and Research Centre, Bengaluru, from January, 2015 to June 2016. All the patients with distal end humerus were included into the study after fulfilling inclusion and exclusion criteria.

**Inclusion criteria**

Patients between 18-65 years of age group, patients with consent for surgery, all patients with closed fractures, open fractures with gustilo anderson classification type I and II, patients who had given consent for surgery, were included.

**Exclusion criteria**

Any other patients with age less than 18 years and greater than 65 years. Any other fractures other than distal end humerus fractures. Patients with cardiovascular diseases, open fractures with Gustilo Anderson classification type III were excluded.

Routine haematological and radiological investigation were carried out. Fitness for surgery from respective departments were sought in terms of risk. Pre-operative evaluation of X-rays, pre-operative planning of surgery (regarding surgical steps and choice of implants) were done. Surgery was performed under brachial block for good per, post-operative pain relief. Tourniquet applied, patient was positioned lateral decubitus position with affected side up, shoulder at 90° abduction and flexion of elbow at 90° over bolsters. Posterior approach, with olecranon osteotomy for better visualization of fracture, and better implantation of humerus.

Patients were followed up to 6 months post-operatively. Functional evaluation was done with Mayo’s elbow performance score.

**Statistics**

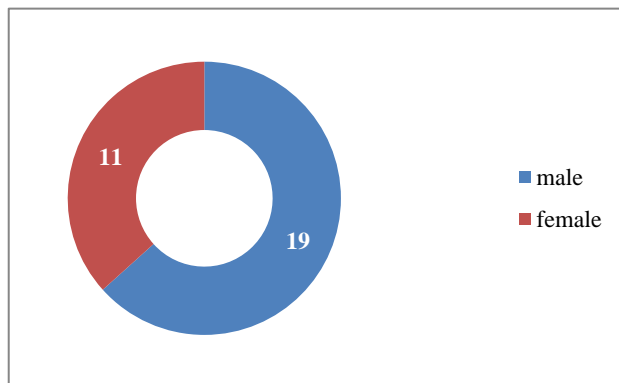
Simple average and standard deviation was used in this study.

**RESULTS**

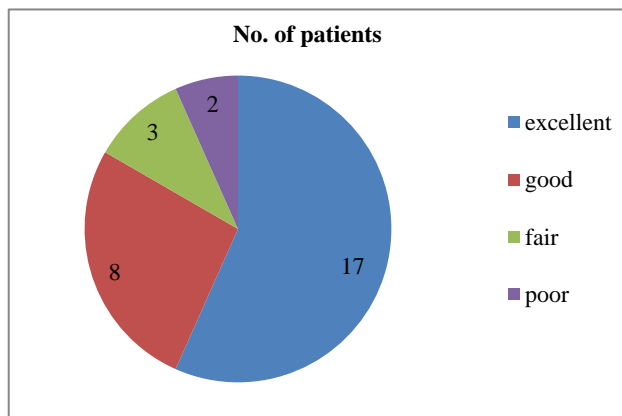
30 patients were included into the study with complete data available. Average age of patients in our study was 37.5 (SD±14) years. 50% of patients were in the age group of 18-35 years. There were 19 males and 11 females in the study. 13 patients with right side, and 17 with left side involvement.

**Table 1: Complication occurred in study and no of patients presenting with them.**

Complications encountered in the study	No. of patients
Non union	2
Non union with bone grafting	1
Non union with revision surgery due to implant failure	1
Infection (superficial)	1
Elbow stiffness which recovered with physiotherapy	2



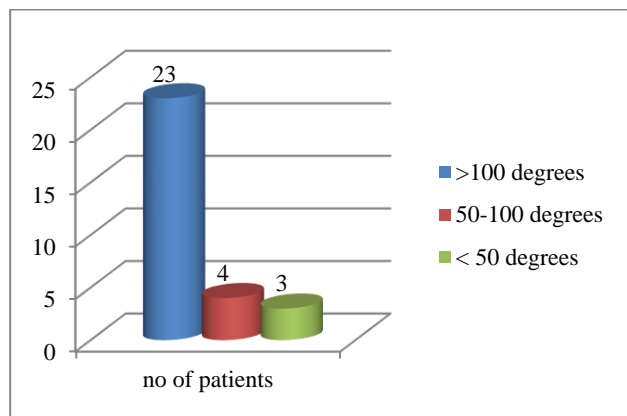
**Figure 1: No. of patient in the study.**



**Figure 2: Mayo elbow performance score in terms of excellent, good, fair, poor in study population.**

No patients with bilateral involvement were recorded into the study. Mode of injury with road traffic accident was 16, while remaining had history of fall. 93% (28) patients had full union with 24 weeks of study, which remaining two patients who had reported non-union required bone

grafting(one) and revision surgery (other one, due to implant failure). We had infection in one patient, elbow stiffness reported in two patients. Overall 25 patients had no complications reported during the period of the study. 77% (23) patients had range of motions greater than 100°, while 13% (4) patients 50°-100°. Remaining 3 (10%) of patients had range of motion less than 50°.



**Figure 3: No. of patient with range of motion.**

Stable fixation was found in 28 patients, while remaining 2 had moderately unstable fixation. Post-operative pain 15 days after surgery which represents early mobilization and better return to activities of daily living was better in our study. We had 22 patients with no pain after 15 days post-operatively. 20% of patients had mild pain which two had moderate pain. None reported severe pain. 83% of patients had excellent and good scores in mayo elbow grading. We had 2 patients with poor score i.e., less has 59. Average mayo elbow grading score in our study was 83.83 (SD±13.98).

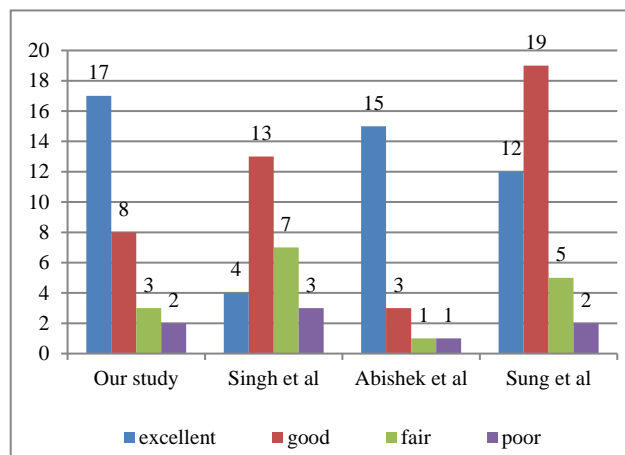
**DISCUSSION**

Distal humerus fractures being complex were treated conservatively, long back. Now a days, early surgical intervention, anatomical reduction, stable internal fixation, locking plates, early physiotherapy and mobilization have resulted in good functional out come in these cases.

Average age of patients in our study was 37.5 years which is comparable with other studies 36 years by Mishra et al, 37.5 years by Singh et al, and 38.4 by Gupta et al years.<sup>3-5</sup> We found male population affected more in our study, i.e., active working population. This is in consistence with other studies like 66.7% by Atalar et al and 60% by Lakhey et al.<sup>6,7</sup> Mode of injury in our study was road traffic accident which differs from other studies like fall in Li et al and Muzaffar et al studies.<sup>8,9</sup>

Time of union was found to be higher in our studies i.e., 24 weeks which is high on comparison with other studies 10-16 weeks by Singh et al and Muzaffar et al.<sup>4,9</sup> The reason might be due to urban population, road traffic accident, complexity of fracture patterns, and longer

operation time in our study when compared to probable rural population and history of fall in other studies.



**Figure 3: Various studies showing comparison of MEPS.**

In our study we had one patient, presented with superficial infection, subsided with regular dressings. In two patients we had elbow stiffness which improved with physiotherapy and mobilization exercises. Nonunion occurred in two patients, where one was treated with bone grafting which united later. Other patient had nonunion with implant failure which required revision surgery. These finding were consistent with other studies. We had no ulnar neuropraxia, and heterotrophic ossification complication which were reported in other studies by Mishra et al, Singh et al, Kaiser et al.<sup>3-10</sup>

Functional evaluation was done with mayo elbow performance score in our study. Results were excellent and good in 83% of patients, fair (10%) and poor (7%). These results were different when compared to Singh et al where excellent and good were 62.9%, fair (26%), and poor (11.1%).<sup>4</sup> The results were same and consistent with Mishra et al, Jung et al with excellent and good 90% and 81.6%, fair (5%, 13.2%) and poor (5%, 5.3%) respectively.<sup>3,11</sup>

**CONCLUSION**

Distal humerus fractures are complicated and difficult to treat and manage. From our study for better management of these fracture we infer: careful pre-operative evaluation and planning, early operative intervention with pre-contoured distal humerus plates for anatomical reduction and stable fixation, followed by early mobilization. Early mobilization in turn provides good functional outcome and decreases elbow stiffness.

*Funding: No funding sources*  
*Conflict of interest: None declared*  
*Ethical approval: The study was approved by the institutional ethics committee*

## REFERENCES

1. Korner J, Lill H, Muller LP, Rommens PM, Schneider E, Linke B. The LCP-concept in the operative treatment of distal humerus fractures-biological, biomechanical and surgical aspects. *Int J Care Injured.* 2003;34(2):20-30.
2. Soon JL, Chan BK, Low CO. Surgical fixation of intra-articular fractures of the distal humerus in adults. *Int J Care Injured.* 2004;35(1):1383.
3. Mishra A, Singh V, Chaurasia A, PK. Lakhtakia operative management of intraarticular distal humeral fractures with locking plates. *J Evolution Med Dent Sci.* 2015;4(94):15923-6.
4. Singh V, Uikey S, Ganvir A, Ds M, Gaur S. Outcome analysis of intercondylar humerus fractures treated by locking compression plates. *Int J Med Res Rev.* 2016;4(3):414-9.
5. Gupta RK, Gupta V, Marak DR. Locking plates in distal humerus fractures: study of 43 patients. *Chin J Traumatol.* 2013;16(4):207-11.
6. Atalar AC, Demirhan M, Salduz A, Kilicoglu O, Seyahi A. Functional results of the parallel-plate technique for complex distal humerus fractures. *Acta Orthop Traumatol Turc.* 2009;43(1):21-7.
7. Lakhey S, Sharma S, Pradhan RL, Pandey BK, Manandhar RR, Rijal KP. Osteosynthesis of intercondylar humerus fracture using Bryan and Morrey approach. *J Nepal Med Assoc.* 2010;49(2):129-32.
8. Li SH, Li ZH, Cai ZD, Zhu YC, Shi YZ, Liou J et al. Bilateral plate fixation for type C distal humerus fractures: experience at a single institution. *Int Orthop.* 2011;35(3):433-8.
9. Muzaffar N, Bhat K, Ahmad R, Wani R, Dar M. Functional results after osteosynthesis of distal humeral fractures with pre-contoured LCP system. *Ortop Traumatol Rehabil.* 2014;16(4):381-5.
10. Kaiser T, Brunner A, Hohendorff B, Ulmar B, Babst R. Treatment of supra-and intra-articular fractures of the distal humerus with the LCP Distal Humerus Plate: a 2-year follow-up. *J Shoulder Elb Surg.* 2011;20(2):206-12.
11. Jung SW, Kang SH, Jeong M, Lim HS. Triangular fixation technique for bicolmn restoration in treatment of distal humerus intercondylar fracture. *Clin Orthop Surg.* 2016;8(1):9-18.

**Cite this article as:** Sunil B, Avulapati SK, Chaudhary SK, Koneru S. Functional outcome evaluation of distal humerus fracture fixation. *Int J Res Orthop* 2020;6:467-70.