

Original Research Article

Cross leg flaps: are they relevant in the present era?

Mahadevan K., Charan J. C.*, Sridevi S.

Department of Plastic, Reconstructive and Facio-Maxillary Surgery, Madras Medical College, Chennai, Tamil Nadu, India

Received: 08 May 2017

Revised: 20 May 2017

Accepted: 23 May 2017

***Correspondence:**

Dr. Charan J. C.,

E-mail: charanjcc@gmail.com

Copyright: © the author(s), publisher and licensee Medip Academy. This is an open-access article distributed under the terms of the Creative Commons Attribution Non-Commercial License, which permits unrestricted non-commercial use, distribution, and reproduction in any medium, provided the original work is properly cited.

ABSTRACT

Background: Injuries of lower limb due to road traffic accidents are challenging to reconstruct due to paucity of tissues and damage to vasculature. Recurrent trophic ulcers are also difficult to reconstruct due to stigmata of previous surgeries. When local and regional flaps are not available, free flaps become the best option. The success of free flap depends on the presence of healthy recipient vessels and microsurgical expertise. In cases where the free flaps have failed or when there is no available soft tissue for local flaps, cross leg flaps are a method of resurfacing and salvaging the limb.

Methods: This Study was done from January 2013 to January 2016 in Rajiv Gandhi Government General Hospital, Chennai. 20 patients were included in the study and the flaps used were conventional cross leg and cross leg reverse superficial sural artery flap.

Results: All flaps survived. There was one case of wound dehiscence managed by re-insetting, two cases with marginal necrosis which were managed conservatively. One case of partial loss which was managed by STSG and one case of sinus formation due to tuberculosis managed with ATT. Remaining flaps had no complications.

Conclusions: Cross leg flaps are still relevant in the present era of microsurgery. They can be the primary choice of reconstruction or as a workhorse when free flaps have failed or other loco regional flaps are already exhausted. Immobilisation and two stage reconstruction are few disadvantages which when weighed against limb salvage are acceptable.

Keywords: Cross leg flap, Lower limb trauma, trophic ulcer, Limb salvage

INTRODUCTION

Lower limb defects are one of the major areas where the expertise of the plastic surgeon is utilized. The major cause of lower limb defects in India is road traffic accidents. These injuries are usually Gustilo Anderson Type III B and III C. The reconstruction in these cases is a challenging for plastic surgeons due to paucity of the available tissues and damage to the blood vessels. Another challenging defect for reconstruction are ulcers secondary to various pathologies. The problem with trophic ulcers is that they are recurrent and recalcitrant.

Recurrent trophic ulcers are difficult to reconstruct due to stigmata of previous surgeries. Principles of reconstruction ladder advocate using local and regional tissues first. However, local and regional flaps may not be available in all cases, and adequate fresh tissue can only be obtained with microsurgical procedures. The success of free flap operations depends on the presence of healthy recipient vessels and microsurgical expertise. In cases where the free flaps have failed or when there is no available soft tissue for local flaps, cross leg flaps are a method of resurfacing and salvaging the limb. In this study we have analysed the efficacy of cross leg flaps and

donor site morbidity in cases where local, regional or free flaps could not be used.

METHODS

Number of patients: 20

Study period: January 2013 – January 2016

Place of the study: Rajiv Gandhi Government General Hospital, Chennai

Inclusion criteria

Damaged surrounding tissue for local fasciocutaneous flaps; damaged ipsilateral blood vessels, varicose veins; defects where ipsilateral flaps could not reach.

Exclusion criteria

Patients with age >40 years, psychiatric illness and epileptic patients.

Preoperative preparation

All patients were subjected to orthopedic opinions, fractures stabilized and wound swab taken for culture and sensitivity. Pre-operative counseling of patients regarding positioning of the limb, period of immobilization required and morbidity of the donor site was given. We used medially based flaps perfused by posterior tibial artery perforators or reverse superficial sural artery flap from the contralateral limb depending on the site and requirement of the defect and donor site availability. The inferior limit of the flaps was kept at about 8cm from the medial malleolus. The upper limit of the flap was kept 8 cms from the knee joint line because positioning was difficult beyond that limit. The length of the flap depended on the dimension of the defect, with the maximum length of 19 cm. The largest dimensions were obtained when flap was placed over the middle third of leg.

Surgical technique

Surgery was performed under either spinal or epidural anesthesia under tourniquet control. Wound debridement was done till healthy margins. The dimensions of the wound were noted and planning in reverse done. The incision was made. Fascia identified, tagged to the dermal component of the flap and subfascial dissection done. When medially based flap crossed posterior midline, segment of sural nerve and short saphenous vein were included in the flap as the flap was raised subfascially. The reach of the flap was checked by bringing the donor limb to the recipient limb and placing it in comfortable position without any stretch or kinking in the flap. The donor area covered using split thickness skin grafts. In all cases, more than 60% of flap inset was given. The limbs were placed in position using ex-fix in most cases and

plaster of paris in remaining cases. The fixation was achieved by few layers of a plaster of paris bandage in the form of figure of eight around two light smooth wooden pieces of appropriate diameter and size. These were kept with adequate cotton padding across the ankle and knee.

Flap division done after three weeks. The bridge segment was either utilized to resurface rest of the recipient area or returned to the donor site. Passive mobilization of the joints of the both lower limbs was done. Active and passive movements of the limbs were encouraged postoperatively.

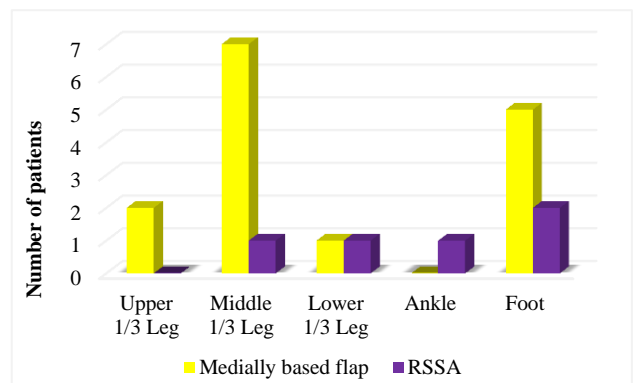


Figure 1: Type of flap used according to site of defect.

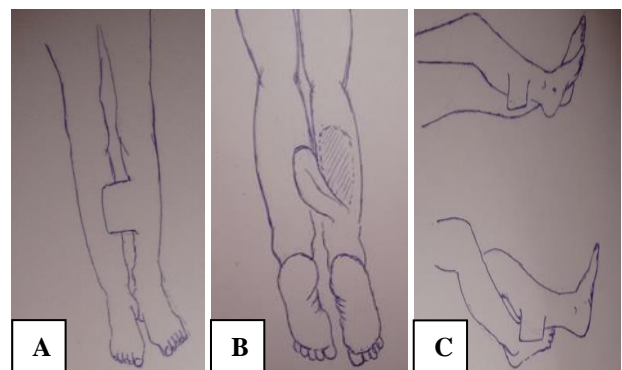


Figure 2 (A, B, C): Line diagram showing positioning of the lower limbs for cross leg flap.

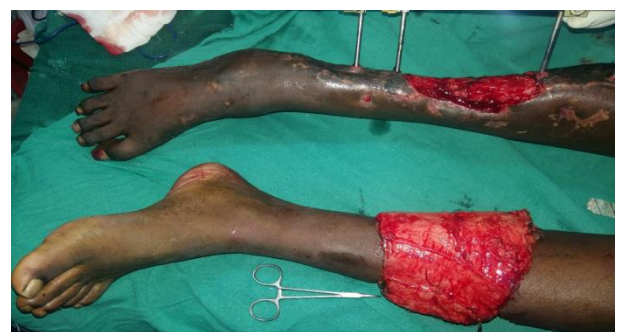

Figure 3a: Post traumatic soft tissue defect upper and mid 1/3 right leg, wound debridement done, medially based cross leg flap elevated.

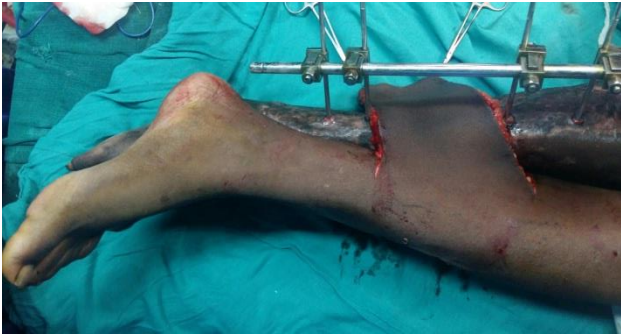

Figure 3b: Limbs placed in the position for inset.

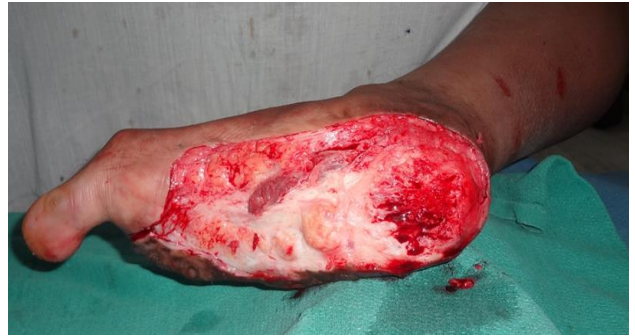

Figure 4b: After excision of the unstable scar.

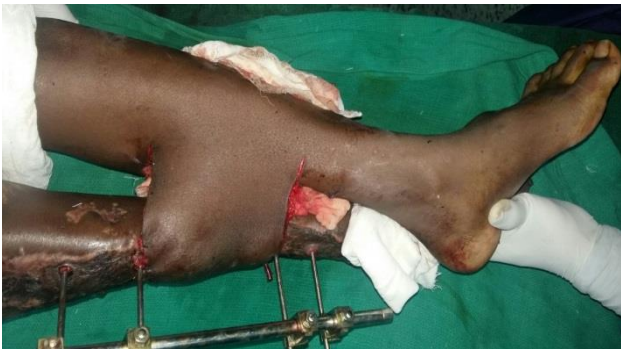

Figure 3c: After flap inset.

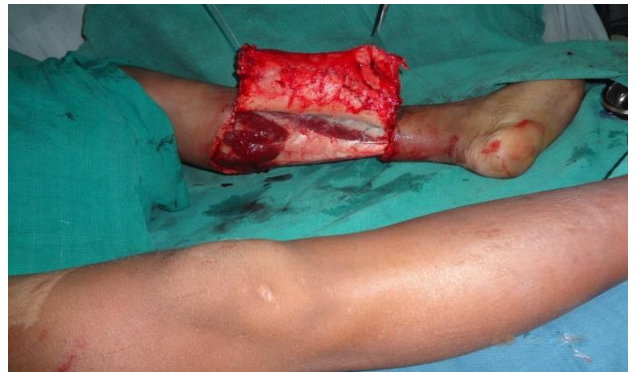

Figure 4c: Medially based cross leg flap elevated beyond the posterior midline.

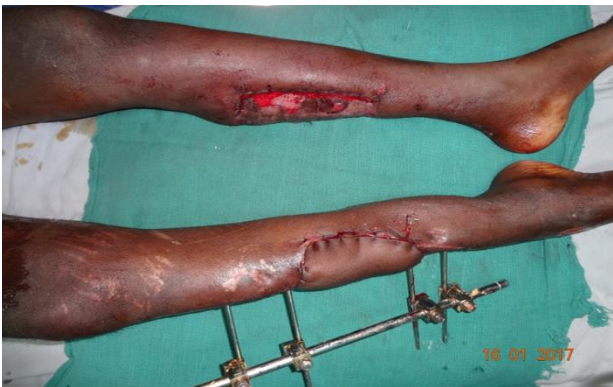

Figure 3d: After flap division and inset, POD-21.

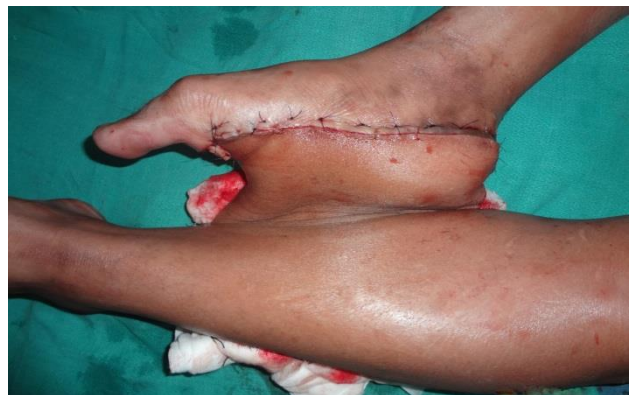

Figure 4d: After flap inset.

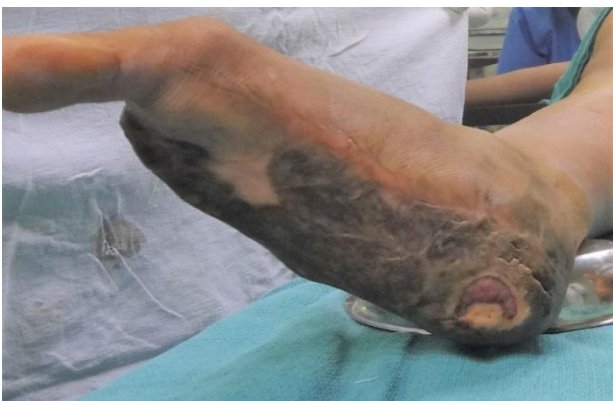

Figure 4a: 30/M post traumatic post-surgical unstable scar right sole of foot.

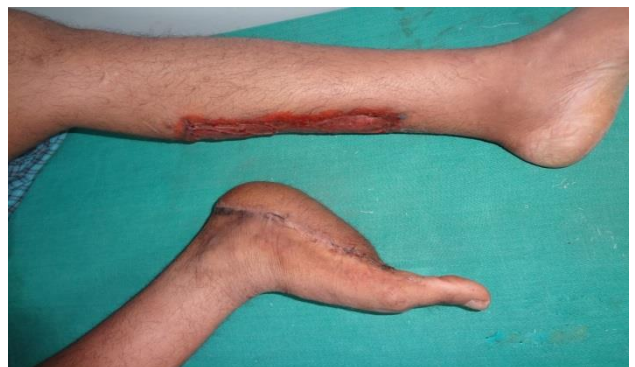

Figure 4e: After flap division, donor site healed well.

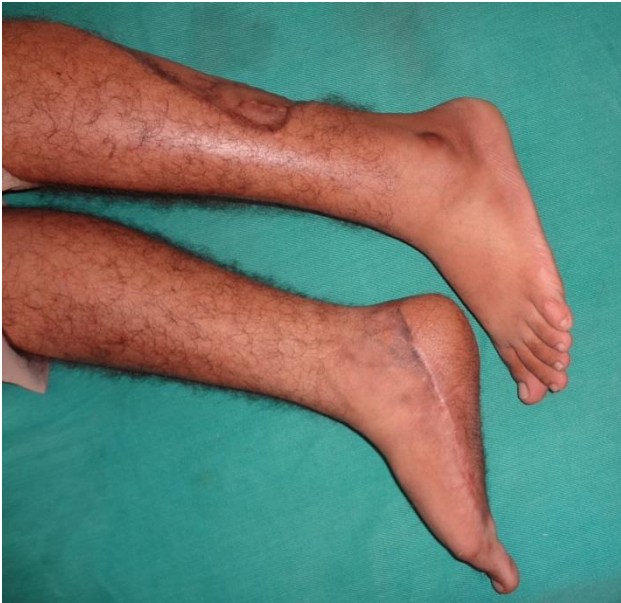

Figure 4f: 3 months post-operative period showing well healed flap.

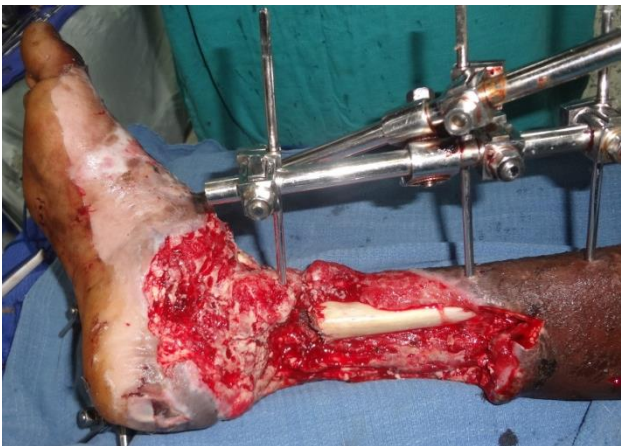

Figure 5a: Post traumatic composite defect lower 1/3 right leg.

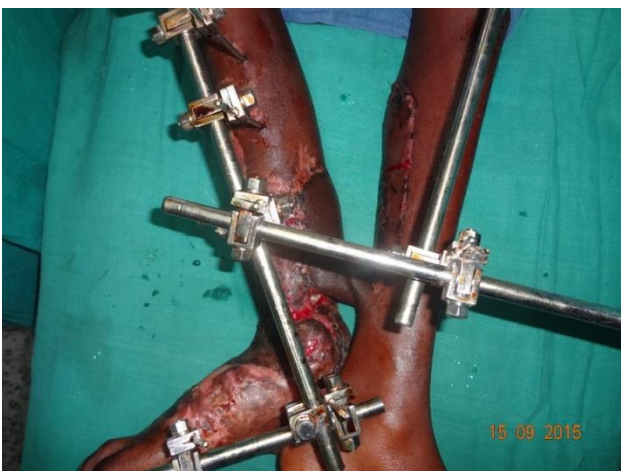

Figure 5b: Reverse superficial sural artery flap from left leg for covering the exposed tibia.

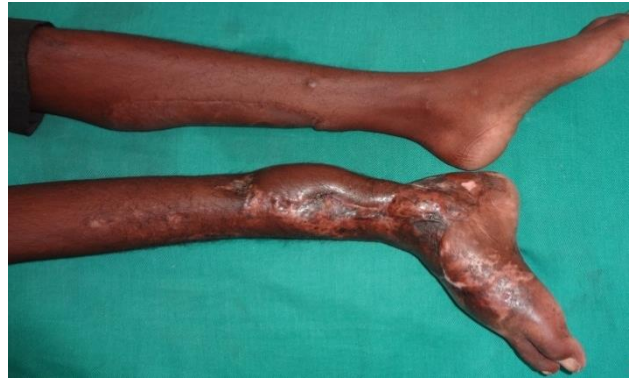

Figure 5c: After flap division.

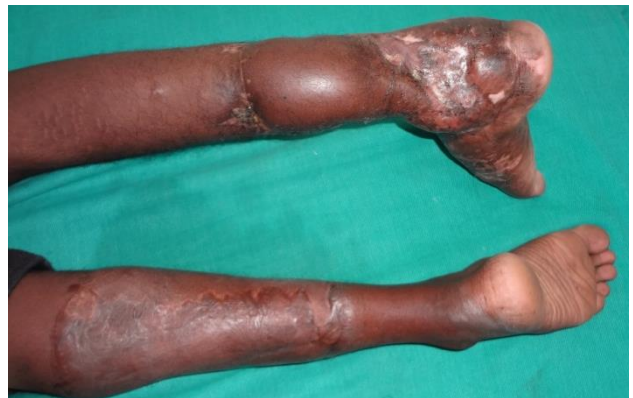

Figure 5d: 1 year follow up showing well healed flap and donor site.

Table 1: Distribution of etiology according to age.

S. No.	Age group (years)	Trauma	Trophic ulcer	Other
1	1-10	0	0	1
2	11-20	1	0	0
3	21-30	9	0	1
4	31-40	5	2	1

Table 2: Average size of the flap according to the defect.

S. No.	Site of defect	Medially based flap (cm)	RSSA (cm)
1	Upper 1/3 leg	13×14.5	0
2	Middle 1/3 leg	9.8×11.4	11×16
3	Lower 1/3 leg	11×9	15×9
4	Ankle	0	16×13
5	Foot	11.2×9.2	7×11.5

RESULTS

All flaps survived. Complications were noted in 5 of the flaps. Two of them were RSSA flap and three were medially based flap. Marginal necrosis of distal end of the flap was noted in two patients who were managed with bedside debridement, antibiotics and dressings. One

patient had dehiscence of the suture line at the inset which was managed by re-insetting the flap. One patient had a partial flap loss which was managed by a split skin graft. One patient had a persistent sinus which was found to be tuberculous in etiology and managed with anti-tuberculous therapy and the sinus healed well. The complication rate was more with RSSA flap than with medially based flap in our study. The mean age of the patients was 27.5 years youngest being 5 years and oldest 39 years. The most common etiology of defect was trauma. Most commonly affected age group of patients in our study was between 21-30 years. The average size of the defect was 108.3 cm² with the maximum size of the defect 300 cm². The average size of the flaps used 129.5 cm² with the largest measuring 336 cm². Largest size of the medially based flap was 336 cm² and RSSA was 208 cm² in our study. The Medially based flap was used in 15 patients and the reverse superficial sural artery flap used in 5 patients. The most common site of defect was middle 1/3 of the leg in 8 patients, proximal 1/3 of the leg in 2, distal 1/3rd of the leg in 2 patients, ankle and foot defects in 8 patients. All the patients in the study were male. The mean follow up period was 15 months with the maximum follow up 24 months. In 9 patients there was hypoesthesia in the sural nerve distribution of the donor. Among these 9 patients, in 5 of them reverse superficial sural artery flap was used and in 4 patients medially based flap including the sural nerve was used.

DISCUSSION

Cross leg flap was introduced in 1854 by Hamilton. Stark standardised the procedure in 1950 and summarised its usefulness for lower extremities trauma.¹ Since the advent of free flap in 1970, it has become gold standard for reconstruction of soft tissue defects in lower limb. However, cross leg flap still remains the simple and effective alternative for free flap reconstruction.

In cases where microvascular reconstruction cannot be done, as in axial vessel damage, vessel thrombosis and microangiopathy, other alternative methods of perfusion like prefabrication and use of "carrier vessels" from contralateral uninjured leg have been advocated.²⁻⁵ But in these techniques, multiple stages are needed thus nullifying the advantage of single stage reconstruction in free flap.

Post traumatic soft tissue defects in the lower limbs are a challenge for the reconstructing surgeon owing to the paucity of local and regional tissues and associated vessel injuries. In those scenarios, microvascular reconstruction is precluded as an option due to non-availability of recipient anastomotic vessel. Cross leg flap is a suitable alternative in defects where microvascular reconstruction is not possible. Trophic ulcers secondary to various pathologies are best reconstructed with free flap. The problem with trophic ulcers is that they are recurrent and recalcitrant. When there is failure of free flap and local or regional flaps are not possible due to previous surgery,

scars or unilateral neurovascular disease, cross leg flaps are the lifeboat option for coverage of the defect.

Wells et al reported that Type IIIB tibial fractures carried a significantly higher risk of free-flap failure than the other types of fracture, and stable, long-term coverage of the free flaps was achieved only in 78% of patients.⁷ For free flap coverage in lower limb, Serafin et al reported the average time in the hospital as 36.2 days and average operating time as 8 hours.⁸ Morris et al reported 94% success rate with conventional cross-leg flap, and by incorporating the fascia, the success rate approaches nearly 100%.⁹ In our study, we had 100% success of the flaps. All the patients underwent cross leg flap because free flap was not an option because of extensive soft tissue injury with injury to lower limb vasculature. In two cases of trophic ulcer we used RSSA cross leg flap and a medially based cross leg as the local flaps could not cover the entire defect. The biggest flap harvested by us was 336 cm² for coverage of a defect of 300 cm² which is larger than previously reported studies.¹⁰ We had a mean operating time of 2½ hours and mean hospital stay of 27 days which is acceptable and consistent with other studies.⁶ Mean healing time was 32 days.

CONCLUSION

In coverage of lower limb defects there are plethora of options available but in severely injured limb or recalcitrant trophic ulcers these options dwindle significantly. While free flaps are used regularly there are conditions where they might be contraindicated. Cross leg flaps are relevant in the present era of microsurgery when free flaps have failed and loco regional flaps are already exhausted. These flaps are still a viable tool in the armamentarium of flaps for a plastic surgeon. Immobilisation, two-stage reconstruction and donor limb hypoaesthesia being disadvantages, but considering the advantage of limb salvage when other options are excluded, cross leg flaps are still a vital option even in centres with microsurgical expertise.

Funding: No funding sources

Conflict of interest: None declared

Ethical approval: Not required

REFERENCES

1. Stark RB. The cross leg flap procedure. *Plastic Reconstr Surg.* 1952;9:173-204.
2. Devansh S. Prefabricated recipient vascular pedicle for free composite-tissue transfer in the chronic stage of severe leg trauma. *Plast Reconstr Surg.* 1995;96:392-9.
3. Yamada A, Harii K, Ueda K, Asota H, Tanaka H. Versatility of a cross leg free rectus abdominis flap for leg reconstruction under difficult and unfavorable conditions. *Plast Reconstr Surg.* 1995;95:1253-7.

4. Lai CS, Lin SD, Chou CK, Cheng YM. Use of a cross-leg free muscle flap to reconstruct an extensive burn wound involving a lower extremity. *Burns* 1991;17:510-3.
5. Chen H, El-Gammal TA, Wei F, Chen H, Noordhoff MS, Tang Y. Cross-leg free flaps for difficult cases of leg defects: Indications, pitfalls, and long-term results. *Trauma*. 1997;43:486-91.
6. Agarwal P, Raza HKT. Cross-leg flap: Its role in limb salvage. *Indian J Orthop*. 2008;42(4):439-43.
7. Wells MD, Bowen CV, Manktelow RT, Graham J, Boyd JB. Lower extremity free flaps: A review. *Can J Surg*. 1996;39:233-9.
8. Serafin D, Georgiade N, Smith DH. Comparison of free flaps with pedicled flaps for coverage of defects of the leg or foot. *Plast Reconstr Surg*. 1977;59:492-9.
9. Morris AM, Buchan AC. The place of the cross-leg flap in reconstructive surgery of the lower leg and foot: A review of 165 cases. *Br J Plast Surg*. 1978;31:138-42.
10. Bhattacharya V, Reddy GR. Distal perforator based cross leg flaps for leg and foot defects. *Indian J Plast Surg*. 2005;38:18-21.

Cite this article as: Mahadevan K, Charan JC, Sridevi S. Cross leg flaps: are they relevant in the present era? *Int J Res Orthop* 2017;3:738-43.