

## Case Report

# Open reduction of carpometacarpal fracture dislocations: a case report

Surya Vijay Singh\*, Gyanendra Puri, Rajesh K. Chopra, Nivendiran Kuppasamy,  
Pritam Samanta, Lakshay Goel

Department of Orthopedics, Central Institute of Orthopedics, V.M.M.C. and Safdarjung Hospital, New Delhi, India

**Received:** 13 September 2019

**Revised:** 07 December 2019

**Accepted:** 09 December 2019

**\*Correspondence:**

Dr. Surya Vijay Singh,

E-mail: [suryavijaysingh89@gmail.com](mailto:suryavijaysingh89@gmail.com)

**Copyright:** © the author(s), publisher and licensee Medip Academy. This is an open-access article distributed under the terms of the Creative Commons Attribution Non-Commercial License, which permits unrestricted non-commercial use, distribution, and reproduction in any medium, provided the original work is properly cited.

### ABSTRACT

Dislocations of the carpometacarpal (CMC) joints are uncommon injuries. Up to 70% of carpometacarpal dislocations are missed or misdiagnosed. Post traumatic dislocation of carpal and CMC joint results most commonly due to high energy trauma. A 24 year old male with right hand dominant presented 5 days after in emergency room with alleged history of fall from 4 feet height on right hand with wrist in extension. On clinical examination revealed marked swelling over dorsum of right hand with wound over volar aspect of hand. There was minimal movement of fingers due to pain. There was no finger paresthesia. CRT was normal. Radiography revealed a volar dislocation of 2nd to 5th CMC joint with intra-articular fracture of base of proximal phalanx of the thumb. He was treated by open reduction and percutaneous fixation using Kirschner wires. The functional results were excellent at 6 months of follow-up.

**Keywords:** Carpometacarpal joints, Dislocation, High energy trauma, Bone, Fracture

### INTRODUCTION

Dislocations of the carpometacarpal (CMC) joints are uncommon injuries. They represent less than 1% of all injuries to the hand and wrist regions.<sup>1</sup> Up to 70% of carpometacarpal dislocations are missed or misdiagnosed. Post traumatic dislocation of carpal and CMC joint results most commonly due to high energy trauma.

The carpometacarpal joints (CMCJs) II-V are saddle joints and stabilized by the weaker volar and the stronger dorsal ligaments, transverse metacarpal ligaments, the extrinsic flexor and extensor tendons, and the intrinsic muscles of the hand. The feature is that the stability of these joints decreases from radial to ulnarwards.

The CMCJs II and III in which the dynamic compressive stability is enhanced by the insertion of the flexor carpi radialis and extensor carpi radialis longus/brevis at the bases of the 2nd and 3rd metacarpal bone allow a

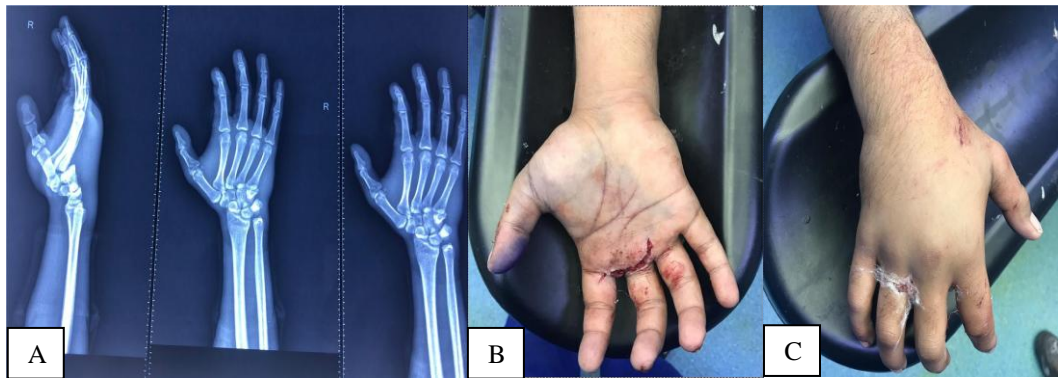
movement of 1° to 3° only whereas the CMCJs V 15° to 20° respectively, and the CMCJ III in which the metacarpal articulates with the capitate bone is the strongest joint that is to be considered as the “key stone” due to its more proximal location than the other joints and its initial injury seems to be a predisposition of dislocation injuries at the other CMCJs. Thus, the frequency of dislocation injuries increases from radial- to ulnarwards.<sup>1</sup>

### CASE REPORT

A 24 year old male with right hand dominant presented 5 days after in emergency room with alleged history of fall from 4 feet height on right hand with wrist in extension. He complained of development of immediate painful swelling in dominant right wrist and painful active movement of the index to small fingers associated with wound over volar aspect of hand (Figure 1).

On examination, there was marked swelling over dorsum of right hand with wound over volar aspect of hand. There was minimal movement of fingers due to pain. There was no finger paraesthesia. CRT was normal.

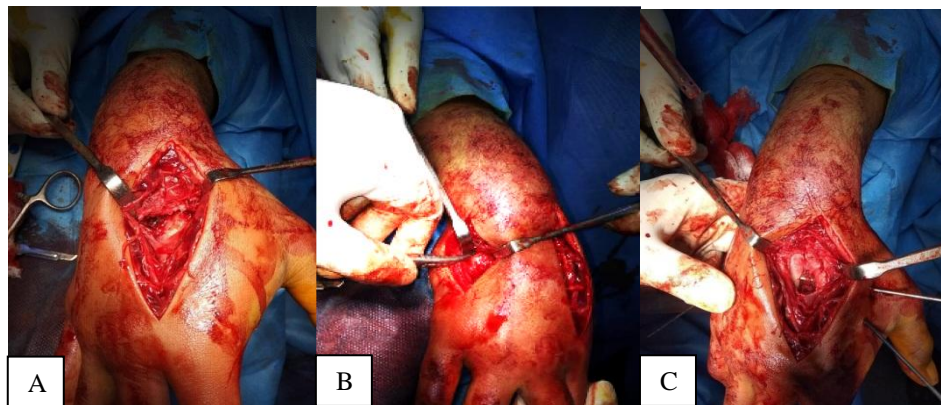
Radiography revealed a volar dislocation of 2nd to 5th CMC joint with intra-articular fracture of base of proximal phalanx of the thumb (Figure 1).



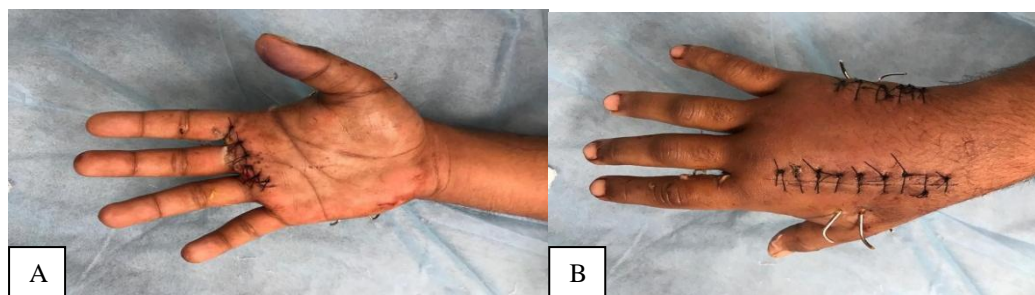
**Figure 1: (A) Pre-operative anterior posterior and lateral view of patient's hand, (B and C) pre-operative clinical examination of wound over palmar aspect and gross swelling over dorsal aspect of hand.**

Initially He underwent manipulation and closed reduction of carpometacarpal dislocation but couldn't be reduced as five days old injury and pain. Then he underwent surgery on the same day open reduction and pinning (ORP) with 2 dorsal incision were given between 2nd and 3rd, and 4th and 5th metacarpal (Figure 2). Intraoperative, there was soft tissue interposition into CMC joint 2nd to 5th as cause for failed closed reduction and volar dislocation of 2nd to 5th carpometacarpal joint found, with disruption of volar and dorsal ligamentous and capsular structures.

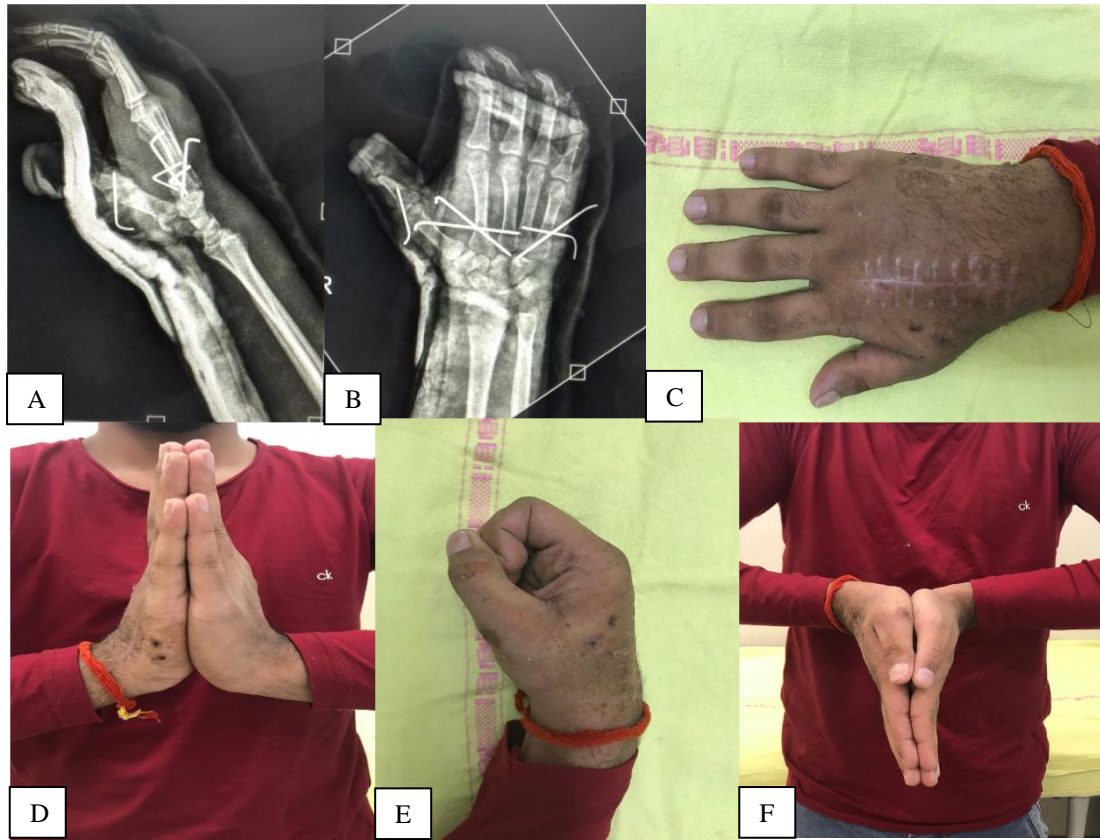Then surgical stabilization of CMC joints done by 2 cross k-wire for 2nd, 3rd CMC joint with carpal and 2 cross k-wire for 4th, 5th CMC joint with carpal after removal of intra-articular soft tissue. And 1 k wire for intra-articular fracture of 1st proximal phalanx. The wound over volar aspect of hand was debrided and sutured (Figure 3). Post-operative patient was applied cockup slab with thumb spica and was kept in ward for IV antibiotics. Patient was discharged on oral antibiotics and suture removal was done on 14th day (Figure 4).



**Figure 2: (A and B) Intra operatively shows dislocation of CMC joints 2<sup>nd</sup> to 5<sup>th</sup> with interposed soft tissue, (C) shows cross K-WIRE pinning after open reduction.**



**Figure 3: (A and B) Post-operative hand of the patient with K-wire in situ.**



**Figure 4: (A and B) Post-operative anterior posterior and lateral view of hand with K wire in situ, (C-F) post-operative clinical pictures of hand of the patient with full pain free range of motion.**

After 6 weeks of follow up removal of K-wired and slab done, and range of motion of wrist assessed. Patient advised physiotherapy and good range of motion with good grip strength achieved.

## DISCUSSION

Carpometacarpal joints (CMCJs) are saddle joints that are stabilised by volar and dorsal ligaments, transverse metacarpal ligaments, long flexor and extensor tendons, and intrinsic muscles of hand. Dorsal ligaments are stronger than volar ligaments. Furthermore, ulnar sided CMC joints are more mobile than radial CMC joints.<sup>2</sup>

The articulation of the third metacarpal with the capitate is located more proximal than the carpal articulations of the other metacarpals; this produces called keystone relationship with the other meta-carpal joints. This is one of the factors accounting for the increased incidence of dislocation of the fourth and fifth carpometacarpal joints as compared with dislocation of the second and third carpometacarpal joints.

High velocity injury is the most common mechanism of injury for CMC dislocation.<sup>3,4</sup>

Dislocations of CMC joints can occur either by a direct force on the bases of metacarpals or by an indi-rect force

transmitted via the metacarpal shafts. Whether a volar or dorsal dislocation occurs is determined by the direction of force.<sup>5</sup> Review of literature shows the fourth and fifth CMC joints are most commonly injured and are usually displaced dorsally.<sup>6</sup> In our patient, the most likely mechanism of injury would appear to be fall on the dorsum of hand with direct force applied to the bases of metacarpals.

Fracture-dislocation of CMC joints is often not recognized early because of swelling. Henderson et al reviewed 21 patients who suffered CMC dislocation and found that diagnosis was missed in 15 cases when they first presented at an accident and emergency department.<sup>7</sup>

When injury is seen early, closed reduction is easy, in case of close reduction, there is a higher risk of redislocation of CMC joint, as compared to open reduction.<sup>8</sup> Open reduction and internal fixation is the recommended treatment for CMC joint dislocation.<sup>8,9</sup> Kirschner wire fixation is usually necessary to prevent redislocation. Closed reduction may fail because of massive edema, interposed fracture fragments and interposed ligaments. Open reduction and pinning are useful in patients in whom closed reduction is unsuccessful. This technique is preferred over closed reduction and percutaneous pinning because better reduction is obtained and transfixing of tendons is avoided.<sup>4</sup> In our case, after the closed reduction failed, we

successfully treated the patient by open reduction and pinning of CMC joints.

In every case, the base of third metacarpal was fixed initially, as it is key in cases of multiple CMC joint fracture dislocations.<sup>10</sup>

Physiotherapy of hand and wrist joint is required after 6 weeks of immobilisation to avoid postoperative stiffness.<sup>11</sup>

## CONCLUSION

Carpometacarpal (CMC) joint fracture dislocation from second to fifth finger is an extremely rare injury that needs thorough clinical examination and radiological assessment. Missed diagnoses are frequently reported. Hence, CMC joint fracture dislocation should be considered on careful examination of the hand injury, in addition to true lateral X-ray of wrist and hand. Early open reduction and internal fixation is required for excellent functional results of the hand injury.

*Funding: No funding sources*

*Conflict of interest: None declared*

*Ethical approval: Not required*

## REFERENCES

1. Hartwig RH, Louis DS. Multiple carpometacarpal dislocations: a review of four cases. J Bone Joint Surg Am. 1979;61(6A):906-8.
2. El-Shennawy M, Nakamura K, Patterson RM, Viegas SF. Three-dimensional kinematic analysis of the second through fifth carpometacarpal joints. J Hand Surg Am. 2001;26(6):1030-5.
3. de Beer JD, Maloon S, Anderson P, Jones G, Singer M. Multiple carpo-metacarpal dislocations. J Hand Surg Br. 1989;14(1):105-8.
4. Breiting V. Simultaneous dislocations of the bases of the four ulnar metacarpals upon the last row of carpals. Hand. 1983;15(3):287-9.
5. Weiland AJ, Lister GD, Villareal-Rios A. Volar fracture dislocations of the second and third carpometacarpal joints associated with acute carpal tunnel syndrome. J Trauma. 1976;16(8):672-5.
6. Lawlis JF, Gunther SF. Carpometacarpal dislocations. Long-term follow-up]. J Bone Joint Surgery Am. 1991;73(1):52-9.
7. Henderson JJ, Arafa MA. Carpometacarpal dislocations. An easily missed diagnosis. J Bone Joint Surgery Br. 1987;69(2):212-4.
8. Sharma AK, John JT. Unusual case of carpometacarpal dislocation of all the four fingers of ulnar side of hand. Med J Armed Forces India. 2005;61(2):188-9.
9. Jilani LZ, Abbas M, Goel S, Akhtar MN. Multiple volar dislocations of the carpometacarpal joints with an associated fracture of the first metacarpal base. Chin J Traumatol. 2014;17(1):38-40.
10. Pundkare GT, Patil AM. Carpometacarpal joints fracture dislocation of second to fifth finger. Clinics Orthopedic Surg. 2015;7:430-5.
11. Bell T, Chinchalkar SJ, Faber K. Postoperative management of carpometacarpal joint fracture dislocation of the hand: a case report. Can J Plast Surg. 2010;18(3):e37-40.

**Cite this article as:** Singh SV, Puri G, Chopra RK, Kuppusamy N, Samanta P, Goel L. Open reduction of carpometacarpal fracture dislocations: a case report. Int J Res Orthop 2020;6:209-12.