

Original Research Article

Functional results of shoulders Neer's prosthesis for four part fracture dislocation of shoulder

Ansari Muqtadeer Abdul Aziz, Pratik Rathod*, Altamash Patel

Department of Orthopaedics, Government Medical College and Hospital, Aurangabad, Maharashtra, India

Received: 01 February 2021

Revised: 01 March 2021

Accepted: 02 March 2021

***Correspondence:**

Dr. Pratik Rathod,

E-mail: Rathodpratik56@gmail.com

Copyright: © the author(s), publisher and licensee Medip Academy. This is an open-access article distributed under the terms of the Creative Commons Attribution Non-Commercial License, which permits unrestricted non-commercial use, distribution, and reproduction in any medium, provided the original work is properly cited.

ABSTRACT

Background: Objective was to study the clinical and functional outcome of shoulder hemi-arthroplasty using Neer's prosthesis in four part fracture dislocation of shoulder.

Methods: The study was conducted on patients who underwent shoulder hemi-arthroplasty using Neer's prosthesis for four part fracture dislocation of shoulder in Department of Orthopaedics, GMCH Aurangabad from January 2020 to January 2021. The patients were assessed clinically and functionally using Shoulder range of motion, Visual Analog Scale (VAS), American Society of shoulder and elbow (ASES) score and Constant-Murley score and radiological assessment at 3, 6 and 12 months.

Results: At one year follow up of 30 patients, no loosening or dislocation of prosthesis was detected, and mean forward elevation of 129.33° (90° - 150°), mean external rotation of 26.7° (18° - 34°), mean internal rotation of 47.86° (33°-58°), the mean ASES score of 79.46 (range 68-88), the mean VAS score of 1.5 (range 1-3) and mean Constant-Murley score of 82.9 (range 72-94) were achieved. 1 patient developed axillary nerve injury which recovered 6 weeks after surgery and 1 diabetic patient developed superficial infection which healed with antibiotics.

Conclusions: Hemiarthroplasty with Neer's prosthesis can be utilized in four part fracture dislocations of humerus with poor bone stock risking avascular necrosis of head and screw cut out with satisfactory outcome.

Keywords: Clinical and functional outcome, Four part fracture dislocation humerus, Neer's prosthesis, Proximal humerus, Shoulder hemiarthroplasty

INTRODUCTION

In the elderly, Proximal humerus fractures are the third most common osteoporotic fractures after hip and distal radius fractures.^{1,2} Proximal humerus fractures though can be treated conservatively, hemiarthroplasty has been recently adopted as the gold standard for neer's four part fracture dislocations of humerus.^{3,4} Four part fracture dislocation of proximal humerus affect vascularity of humeral head. Even after internal fixation, the probability of humeral head necrosis can reach upto 35%.⁵ The goal of surgical treatment is to provide a stable, mobile, painfree shoulder in comminuted humeral head fractures where

head cannot be salvaged. Surgical options include different fixation techniques (percutaneous pinning, intramedullary nailing, plating) as well as shoulder arthroplasty.⁶ The choice of procedure should be made considering several local(fracture pattern, quality of bone, status of rotator cuff) and general (comorbidities, functional demands, compliance to treatment) factors. Unfortunately, insufficient straightforward recommendations and significant variation in clinical practice among orthopaedic surgeons indicates a lack of consensus regarding optimal treatment of these fractures.^{7,8} Internal fixation may fail because sometimes comminuted fracture cannot be reduced and fixed. Humeral head excision or arthrodesis

in treatment of fracture dislocations of proximal humerus fractures resulted in disappointing outcomes which led Charles Neer (1917 - 2011) to articular replacement as a better solution for achieving pain relief and improved shoulder function. In 1955, he published results which were achieved in a series of twelve patients using a monobloc Vitallium prosthesis: at an average follow up of 10 months, eleven patients were free from pain, while range of motion (ROM) was poor in only two patients.⁹

In the present study, retrospective analysis of mentioned patients was done with the aim to assess short term effect of shoulder hemi arthroplasty for four part fracture dislocations of humerus., to discuss the operative precautions and complications in hemi arthroplasty; and to analyze the prevention of complications.

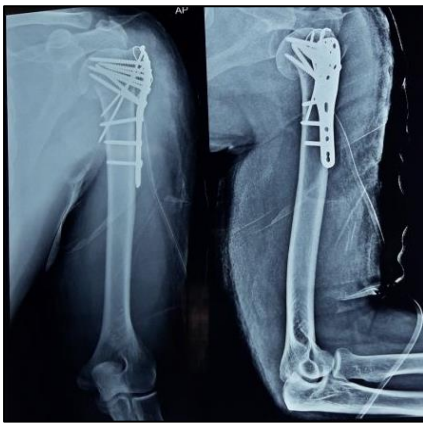

Figure 1: Failure of plate osteosynthesis in proximal humerus fractures.

METHODS

This was a prospective study done under the guidelines of ethical committee of the institution. This study was conducted in Government medical college and hospital, Aurangabad from January 2020 to January 2021.

Inclusion criteria

Comminuted four part fracture with humeral head as a separate fragment, elderly age patients, patients having osteoporotic fractures, lesser tuberosity and greater tuberosity as separate fragments were included in the study.

Exclusion criteria

Compound shoulder fractures, pre-existing rotator cuff arthropathy, neuropathy causing wasting of left shoulder muscles (eg Brachial plexus palsy) and local skin infection were excluded from the study.

All patients admitted in Government medical college, Aurangabad with 4 part fracture dislocation of humerus were evaluated for 12 months post hemi-arthroplasty of

shoulder. Clinical and functional evaluation was done using forward elevation, internal rotation, external rotation, VAS score 10, American society of shoulder and elbow score 11 and Constant-Murley score.^{12, 13} Routine radiographs included Anteroposterior and axillary lateral position of injury shoulder. Computed tomography scans helped gain insights into the fracture and Magnetic resonance imaging was done to assess degree of rotator cuff damage.

Surgical procedure

The night before surgery, the surgical site was cleaned with betadine and covered with a sterile pad and bandaged. Intravenous antibiotic (third generation cephalosporins) was administered once the night before (12 hours prior to surgery) and the second dose 30 minutes prior to incision. Skin hair over the surgical site were removed 10 minutes before surgery. Under general anesthesia, patient was positioned in beach chair position, the arm and shoulder were prepared and draped and the arm being operated was hanging over the edge.

A deltopectoral approach was used without detaching the anterior deltoid and upper third of pectoralis major. After releasing the clavipectoral fascia, the long head of biceps was identified which was the landmark in identifying the tuberosities. The greater and lesser tuberosities were identified and the interval between supraspinatus tendon and subscapularis tendon was opened and the insertions of rotator cuff were tagged with 5-0 ethibond non absorbable sutures.

The greater and lesser tuberosities were pulled separately to expose the humeral head which was taken out without detaching the subscapularis tendon. Canal of humerus shaft was prepared and a trial stem was inserted to determine height and version (approximately 300). The tuberosities were reduced and the position and height of prosthesis was checked using image intensifier size prosthesis. The stability and tightness of the prosthesis was checked and found satisfactory. Tuberosities were sutured to one another and were then reduced around the neck of the stem with 5-0 ethibond non-absorbable sutures and cancellous bone graft was inserted around the tuberosities to facilitate healing. Closure was done in layers over a drain.

Post-operative protocol-Intravenous third generation cephalosporins were given for 24 hours post operatively and oral antibiotics were given for further 3 days. Drain was removed after 48 hours. The shoulder was kept in a shoulder immobilizer. Initial shoulder pendulum exercised and active elbow, wrist and finger movements were started on first day post operatively. Suture removal was done at two weeks. Passive function exercises were started for the first 3 weeks followed by active assisted motion of the shoulder for next 3 weeks and active exercises were initiated at 6 weeks. Ethical approval for conducting the

study was taken from the Ethical Committee of the local institution.

Statistical analysis

The data of patients who fulfilled the inclusion criteria were tabulated in electronic spreadsheet (Microsoft Excel 2010) and data was analyzed using SPSS 24.0.

RESULTS

Majority of patients (40%) belonged to 71-80 years of age, followed by those belonging to more than 80 years (26.66%) (Table 1).

Table 1: Age of patients.

Age range (years)	No. of patients	Percentage
51-60	4	13.33
61-70	6	20
71-80	12	40
>80	8	26.66
Total	30	100

Table 2: Gender of patients.

Gender	No. of patients	Percentage
Males	13	43.33
Females	17	56.66
Total	30	100

Females formed majority of the study population with 56.66% (Table 2).

Table 3: Various result parameters.

Parameter	Range	Mean±SD
Age (years)	53-89	72.83±9.87
Forward flexion (degrees)	90-150	129.33±16.59
Internal rotation (degrees)	32-58	47.86±7.96
External rotation (degrees)	18-34	26.7±4.05
ASES (out of 100)	68-88	79.46±5.84
VAS (out of 10)	01-3	1.5±0.68
Constant-Murley score (out of 100)	72-94	82.9±6.71

Patients were clinically and functionally evaluated using Shoulder joint range of motion, American Society of elbow and shoulder (ASES) score(out of 100), Visual Analogue score(VAS) (out of 10), Constant-Murley score(out of 100) and imaging examination.

The mean age was 72.83 years (range 53-89 years), the mean forward flexion was 129.33° (range 90°-150°), the mean internal rotation was 47.86° (range 32-58), the mean external rotation was 26.70 (range 180-340), the mean ASES score was 79.46 (range 68-88), the mean VAS was

1.5 (range 1-3) and the mean Constant-Murley score was 82.9 (range 72-94) (Table 3).

Complications

At follow up, no other complications like infection, stress fracture, displacement of tuberosities was observed. One patient developed axillary nerve injury with parasthesia on the lateral border of shoulder on first day post operatively which recovered completely at 6 weeks with neurotropic drugs and physiotherapy and one diabetic patient with poor compliance to oral hypoglycemic drugs developed superficial skin infection which healed completely with oral antibiotics and dressing.

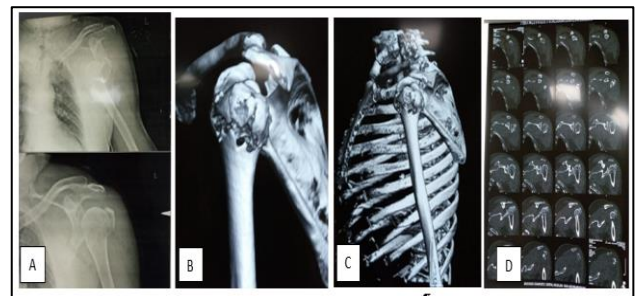


Figure 2: Pre-operative image showing four part fracture dislocation of proximal humerus.

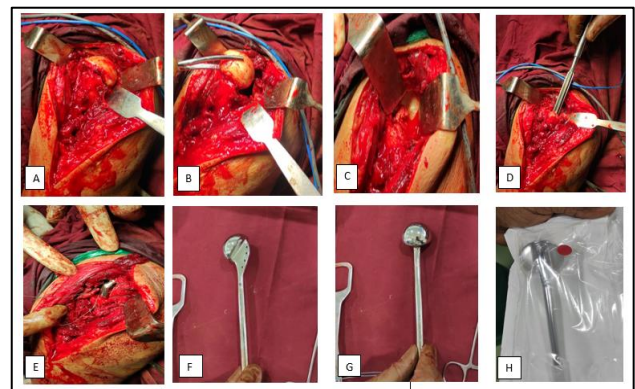


Figure 3: Intraoperative images showing exposure, head extraction, reduction of tuberosities over the implant and implant images.

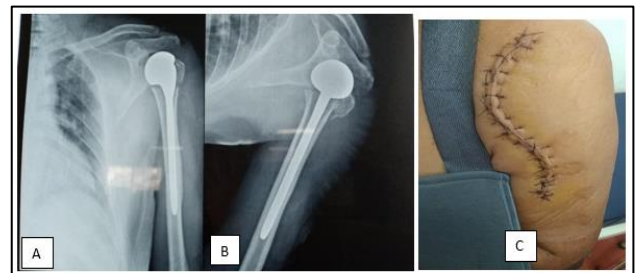


Figure 4: Post-operative x-rays of the above patient and surgical site after 10 days is healthy and healing.

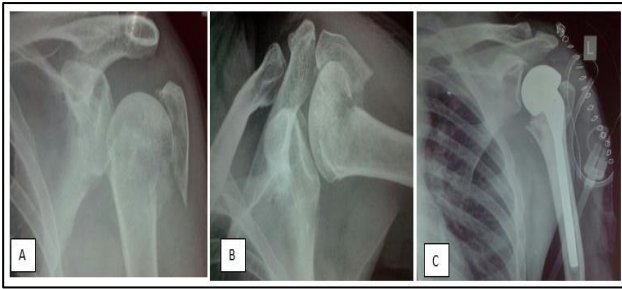


Figure 5: Another case with four part fracture of proximal humerus and the post-operative image showing good version and position of the implant.

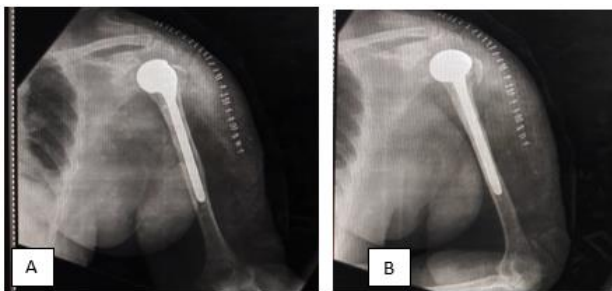


Figure 6: Another case with four part fracture dislocation of humerus after hemiarthroplasty with Neer's prosthesis.

DISCUSSION

The management of four part fracture dislocation of proximal humerus patients with plate osteosynthesis provides good initial reduction but with a risk of secondary loosening in osteoporotic bones or of humeral head necrosis leading to catastrophic functional impairment and reintervention especially when the humeral head is small and as a separate fragment.¹⁴⁻¹⁷ A thorough knowledge of anatomy of shoulder is necessary for patient selection and to offer optimal outcome after the hemiarthroplasty. Elderly patients with displaced fractures and poor bone quality are the primary candidates for Neer's hemiarthroplasty of shoulder.¹⁸⁻²⁰ The mean age in our series was 72.83 years. Tian et al found the mean age to be 71.9 years.¹⁷ Shah et al found the mean age to be 72.2 years.¹⁹ Kontakis et al found the mean age to be 67.7 years.²²

The mean forward elevation in our study was 129.33°. Tian et al found the mean forward elevation to be 132.5°. ¹⁷ Shah et al found the mean forward elevation to be 85.1°. ¹⁹ Mighell et al found the mean forward elevation to be 128°. ¹⁸ Pascal et al found the mean forward elevation to be 135°. ²⁰ Goldman et al found the mean forward elevation to be 107°. ²³ Kontakis et al found the mean forward elevation to be 105.7°. ²²

The mean internal rotation in our study was 47.86°. Tian et al found the mean internal rotation to be 47.1°. ¹⁷ Mighell et al found the mean internal rotation to be till L2 vertebrae. ¹⁸ Pascal et al found the mean internal rotation to

be till L5 vertebral level. ²⁰ Goldman et al found the mean internal rotation to be at L2 vertebral level. ²³

The mean external rotation in our study was 27.7°. Tian et al found the mean external rotation to be 29.5°. ¹⁷ Mighell et al found the mean external rotation to be 43°. ¹⁸ Pascal et al found the mean internal rotation to be 24°. ²⁰ Goldman et al found the mean internal rotation to be 31°. ²³ The mean ASES in our study was 79.46. Tian et al found the mean ASES to be 88.8. ¹⁷ Shah et al found the ASES to be 67.1. ¹⁹ Mighell et al found the mean ASES to be 76.6. ¹⁸ The mean VAS score in our study was 1.5. Xu tian et al found the mean VAS score to be 0.8. ¹⁷ The mean Constant Murley score in our study was 82.9. Tian et al found the mean Constant Murley score to be 89.1. ¹⁷ Pascal et al found the mean Constant Murley score to be 64.2° Anjum et al found the mean Constant score to be 47.5. ²¹ Kontakis et al found the mean Constant Murley score to be 56.63. ²² Hartog et al found the mean Constant Murley score to be 66.5. ²⁴

In our study, one patient developed axillary nerve injury and one patient developed superficial skin infection. Mighell et al reported the most common complication in their study to be malunion of greater tuberosity. ¹⁸ Kontakis et al reported superficial infection in 1.58% and deep infection in 0.64% of their cases. ²² Hemi-arthroplasty with Neer's prosthesis for such badly comminuted fractures gives excellent functional and clinical outcome which enables the patient to carry out activities of daily living. Patient's who underwent this surgery showed excellent post-operative function and satisfaction. Earlier surgical intervention in these fractures with shoulder hemiarthroplasty minimizes complications and maximizes function in these patients who are able to carry out activities of daily living without pain or discomfort. Neer's prosthesis showed excellent outcomes which was demonstrated in good Constant-murley, Visual Analog Scale, American society of elbow and shoulder score and Good functional range of motion of shoulder.

CONCLUSION

A patient presenting with four part fracture dislocation of proximal humerus is not going to recover his or her pre trauma shoulder, especially when elderly. The choice of treatment is therefore an option which most reliably and predictably restores a range of useful mobility which improves patient's everyday comfort as rapidly as possible and gives the patient a painfree, stable, functionally mobile shoulder. We intend to help the poor and needy rural population coming to tertiary government setup giving maximum benefit to these patients. This a short term study conducted during the COVID pandemic when surgical patients had drastically reduced and needs a long term study.

Funding: No funding sources

Conflict of interest: None declared

Ethical approval: The study was approved by the institutional ethics committee

REFERENCES

1. Yang GY, Xiang M, Chen H, Hu XC. Short-term clinical outcome of proximal humeral fractures using Multiloc proximal humeral nail. *Chin J Orthop.* 2016;36:103-12.
2. Passaretti D, Candela V, Sessa P, Gumina S. Epidemiology of proximal humeral fractures: a detailed survey of 711 patients in a metropolitan area. *J Shoulder Elbow Surg.* 2017;26:2117-24.
3. Neer CS. Displaced proximal humeral fractures. II. Treatment of three-part and four-part displacement. *J Bone Joint Surg Am.* 1970;52:1090-103.
4. Rangan A, Handoll H, Brealey S. Surgical vs nonsurgical treatment of adults with displaced fractures of the proximal humerus: the proffer randomized clinical trial. *JAMA.* 2015;313:1037-47.
5. Yüksel HY, Yılmaz S, Akşahin E. The results of nonoperative treatment for three- and four-part fractures of the proximal humerus in low-demand patients. *J Orthop Trauma.* 2011;25:588-95.
6. Rosa MA, Maccauro G, Nizegorodcew T. Percutaneous elastic fixation of proximal humeral fractures: operative indications, techniques, results and complications. *J Orthop Traumatol.* 2002;2:157-64.
7. Murray IR, Amin AK, White TO, Robinson CM. Proximal humeral fractures: current concepts in classification, treatment and outcomes. *J Bone Joint Surg Br.* 2011;93:1-11.
8. Piccioli A, Maccauro G, Rossi B. Surgical treatment of pathologic fractures of humerus. *Injury.* 2010;41:1112-6.
9. Neer CS. Articular replacement for the humeral head. *J Bone Joint Surg Am.* 1955;37:215-28.
10. Hjerstad MJ, Fayers PM, Haugen DF, Caraceni A, Hanks GW, Loge JH. Studies comparing numerical rating scales, verbal rating scales, and visual analogue scales for assessment of pain intensity in adults: a systematic literature review. *J Pain Symptom Manage.* 2011;41(6):1073-93.
11. Conboy VB, Morris RW, Kiss J, Carr AJ. An evaluation of the Constant-Murley shoulder assessment. *J Bone Joint Surg Br.* 1996;78(2):229-32.
12. Constant CR, Murley AH. A clinical method of functional assessment of the shoulder. *Clin Orthop Relat Res.* 1987:160-4.
13. King GJ, Richards RR, Zuckerman JD, Blasler R, Dillman C, Friedman RJ. A standardized method for assessment of elbow function. Research Committee, American Shoulder and Elbow Surgeons. *J Shoulder Elbow Surg.* 1999;8(4):351-4.
14. Paavolainen P, Bjorkenheim JM, Slati P, Pauku P. Operative treatment of severe proximal humeral fractures. *Acta Orthop Scand.* 1983;54:374-9.
15. Hessmann M, Baumgaertel F, Gehling H, Klingelhoefffer I, Gotzen H. Plate fixation of proximal humeral fractures with indirect reduction: surgical technique and results utilizing three shoulder scores. *Injury.* 1990;30:453-62.
16. Adedapo AO, Ikpeme JO. The results of internal fixation of three and four part proximal humeral fractures with the Polarus nail. *Injury.* 2001;32:115-21.
17. Kralinger F, Schwaiger R, Wambacher M, Farrell E, Chiari W, Lajtai G. Outcome after primary hemiarthroplasty for fracture of the head of the humerus A retrospective multicentre study of 167 patients. *J Bone Joint Surg.* 2004;86:217-9.
18. Bigliani LU. Fractures of the proximal humerus. In: Rockwood CA, Matsen FA, editors. *The shoulder.* Philadelphia: W.B. Saunders. 1990:278-334.
19. Bigliani LU, McClusky GN. Prosthetic replacement in acute fractures of the proximal humerus. *Semin Arthroplasty.* 1990;1:129-37.
20. Compito CA, Self EB, Bigliani LU. Arthroplasty in acute shoulder trauma. *Coordination.* 1994;307:27-36.
21. Tian X, Xiang M, Wang G, Zhang B, Liu J, Pan C, et al. Treatment of complex proximal humeral fractures in the elderly with reverse shoulder arthroplasty. *Orthop Surg.* 2020;12:1372-9.
22. Mighell MA, Kolm GP, Collinge CA, Frankle MA. Outcomes of hemiarthroplasty for fractures of the proximal humerus. *J Shoulder Elbow Surg.* 2003;12(6):569-77.
23. Shah N, Iqbal HJ, Brookes-Fazakerley S, Sinopidis C. Shoulder hemiarthroplasty for the treatment of three and four part fractures of the proximal humerus using Comprehensive® Fracture stem. *Int Orthop.* 2011;35(6):861-7.
24. Boileau P, Alta TD, Decroocq L, Sirveaux F, Clavert P. Reverse shoulder arthroplasty for acute fractures in the elderly: is it worth reattaching the tuberosities? *J Shoulder Elbow Surg.* 2019;28(3):437-44.
25. Anjum SN, Butt MS. Treatment of comminuted proximal humerus fractures with shoulder hemiarthroplasty in elderly patients. *Acta Orthop Belg.* 2005;71(4):388-95.
26. Kontakis G, Koutras C, Tosounidis T, Giannoudis P. Early management of proximal humeral fractures with hemiarthroplasty: a systematic review. *J Bone Joint Surg Br.* 2008;90(11):1407-13.
27. Goldman RT, Koval KJ, Cuomo F, Gallagher MA, Zuckerman JD. Functional outcome after humeral head replacement for acute three- and four-part proximal humeral fractures. *J Shoulder Elbow Surg.* 1995;4:81-86.
28. Hartog D, Haan J, Schep NW, Tuinebreijer WE. Primary shoulder arthroplasty versus conservative treatment for comminuted proximal humeral fractures: a systematic literature review. *Open Orthop J.* 2010;4:87-92.

Cite this article as: Aziz AMA, Rathod P, Patel A. Functional results of shoulder Neer's prosthesis for four part fracture dislocation of shoulder. *Int J Res Orthop* 2021;7:456-60.