

Original Research Article

Salvage of infected proximal tibial tumour prosthesis using vacuum assisted closure in seven patients

Navin Balasubramanian^{1*}, Sindhuja P.²

¹Department of Orthopaedics, ²Department of Pathology, Saveetha Medical College, India

Received: 14 January 2017

Revised: 26 January 2017

Accepted: 31 January 2017

*Correspondence:

Dr. Navin Balasubramanian,

E-mail: drnavin_ortho@yahoo.co.in

Copyright: © the author(s), publisher and licensee Medip Academy. This is an open-access article distributed under the terms of the Creative Commons Attribution Non-Commercial License, which permits unrestricted non-commercial use, distribution, and reproduction in any medium, provided the original work is properly cited.

ABSTRACT

Background: Proximal tibia is the second most common site for both benign and malignant bone tumours. The treatment protocols of such tumours have seen a paradigm shift from amputation towards limb salvage. Limb salvage has been possible with resection and reconstruction using custom modular prosthesis but the risk of tumour recurrence and infection still looms large.

Methods: Here we present our series of seven patients with infected proximal tibial tumour prosthesis which were salvaged using vacuum assisted closure (VAC) dressing. The indications for surgery were recurrent giant cell tumour (4 cases), chondrosarcoma (2 cases) and osteosarcoma (one patient). The prosthesis used was the limb preservation system (LPS) [Depuy-Synthes, US]. There were 6 males (M:F 6:1) with average age of 34.23 years. The predominant organism cultured was *Staph aureus*. We proceeded with radical wound debridement and VAC dressing with continuous negative pressure drainage for an average of 18 days (range 12-24 days). The patients then underwent secondary suturing and delayed suture removal (18-21 days).

Results: All 7 patients were well at 8 months follow-up with no recurrent or persistent infection with good functional outcome. The average knee society score (KSS) was 73 (good).

Conclusions: We conclude that with early thorough radical debridement and with select bacteriological culture profile, VAC is a valuable tool in the salvage of infected tumour prosthesis. This may reduce the need for amputations of such infected limbs by a significant margin while still retaining good functional outcome.

Keywords: Custom modular prosthesis, Limb preservation system, Vacuum assisted closure dressing, Knee society

INTRODUCTION

The incidence of bone tumours is increasing in Indian population. This is in effect due to more public awareness and screening camps being conducted. The proximal tibia is the second most common site of both benign and malignant bone tumours (second to distal femur).¹⁻³ The commonest benign tumour in proximal tibia is giant cell tumour and commonest malignant tumour is osteosarcoma. The treatment of such tumours has changed drastically from limb ablation (above knee amputation) to limb salvage (wide resection and endo-prosthetic reconstruction using custom modular

prosthesis±neo-adjuvant chemotherapy). Limb salvage has significantly reduced the morbidity and mortality associated with such diseases and alleviates to a certain extent, the social stigma often associated with amputations. The design and metallurgy of these prosthesis is also improving providing better bone ingrowth with native bone, better long term survival rates, options for re-attachment of the patellar tendon and providing a constrained design thus re-creating a near normal biomechanics for the knee joint and ensuring stability.

Although the cure rates have dramatically increased with multidisciplinary team approach and good margin clearance during surgery, the resection of extensive bone and soft tissues also compromises the vascularity of the field resulting in flap necrosis with infection.^{1,2,5} The limb survival rates decline progressively with each failed debridement procedure and the inevitable end result is an amputation at appropriate level.^{4,5} This results in severe financial and mental stress to the patients. The use of vacuum assisted closure (VAC) dressing has been practised in treating open wounds, pressure sores and nonhealing ulcers.^{1,19,20} It creates an anerobic medium within the field to prevent the multiplication of bacterial colonies in the wound and thereby killing the bacteria.

METHODS

We present our series of seven patients between June 2012 to November 2015 at a tertiary referral centre with secondary infection following wide resection and reconstruction using custom prosthesis of the proximal tibia. There were 6 males and one female. The average age was 34.23 years (range 26-39 years). The most common indications for resection and reconstruction with tumour prosthesis were recurrent giant cell tumour (4 cases), chondrosarcoma (2 cases) and osteosarcoma (one patient). One patient with chondrosarcoma underwent surgery with curettage and bone cementation supplemented with plate and screws as given in Figure 1 for a diagnosis of giant cell tumour which later was shown to be a primary chondrosarcoma (since both often show similar pathologic findings on closed biopsy). All other patients underwent primary wide resection and reconstruction using custom prosthesis. We used the Depuy LPS™ [Depuy-Synthes] proximal tibia custom modular prosthesis. The surgery was performed by a team of orthopaedic surgeon, surgical oncologist and anaesthetist and medical oncologist opinion was sought in all of them regarding neo-adjuvant chemotherapy. All seven patients presented with delayed wound infection at an average of 10.6 weeks (8-16 weeks). Wound culture was done in all of them with a bacteriological profile of *Staphylococcus aureus* in 4 patients, *Streptococcus pyogenes* in 2 and *Staph epidermidis* in one patient. The sensitivity pattern and dosage (MIC –minimal inhibitory concentration) was also calculated and appropriate antibiotics were started for 6 weeks (4 weeks I.V. and 2 weeks oral). All patients underwent radical wound debridement as shown in Figure 2, thorough wound lavage with 10 litres normal saline and VAC dressing application as given in Figure 3. Culture and sensitivity from the collected fluid in the drain was done every 4 days when the container was changed. Two serial negative cultures and a drain of less than 50 ml per day were taken as a threshold for secondary suturing. The secondary suturing as in Figure 4 was done with the assistance of a plastic surgeon and standard post-operative wound care was followed. All patients had a long leg knee brace for 4 weeks. However suture removal

was delayed till 18-21 days. Antibiotics were continued for a period of 6 weeks.

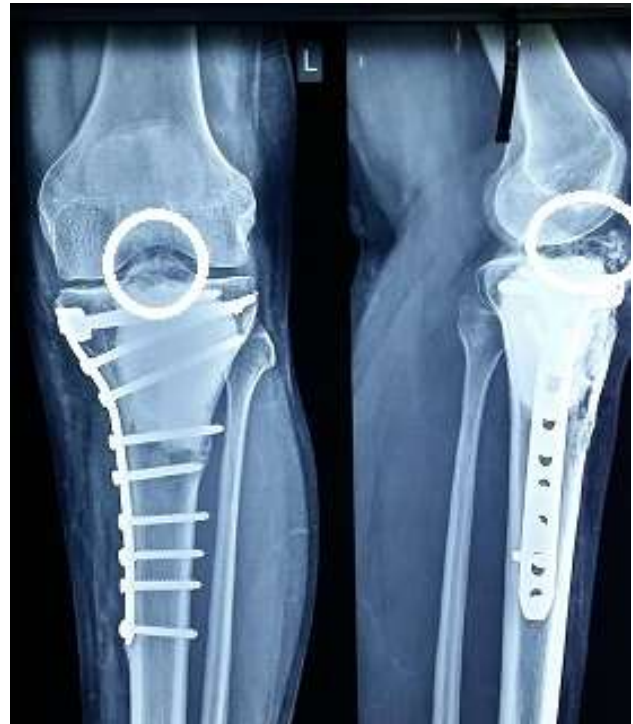

Figure 1: Preoperative X-ray showing recurrence of chondrosarcoma (encircled).

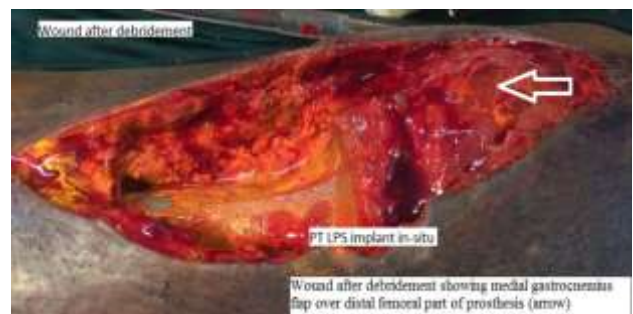

Figure 2: Post-debridement with arrow showing medial gastrocnemius muscle flap.

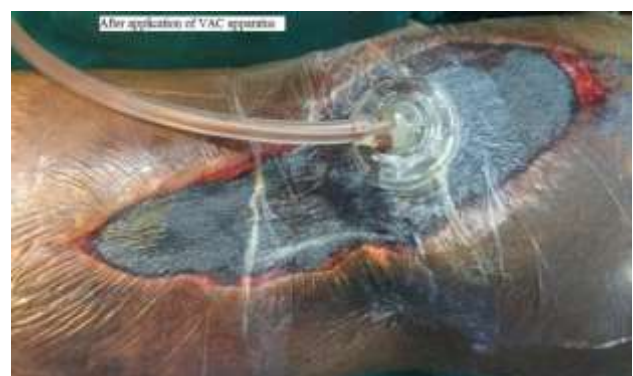


Figure 3: Following VAC dressing application.

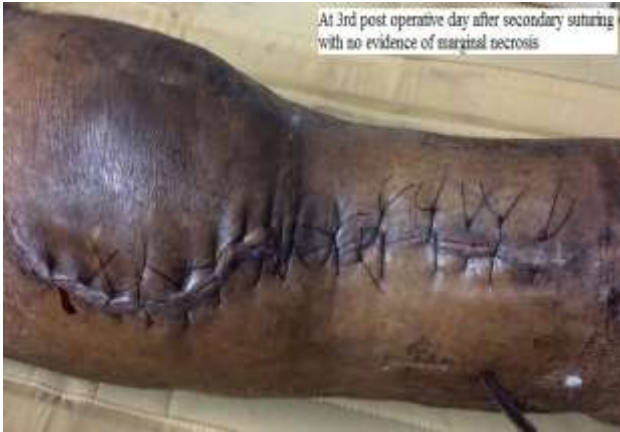

Figure 4: Following secondary suturing.

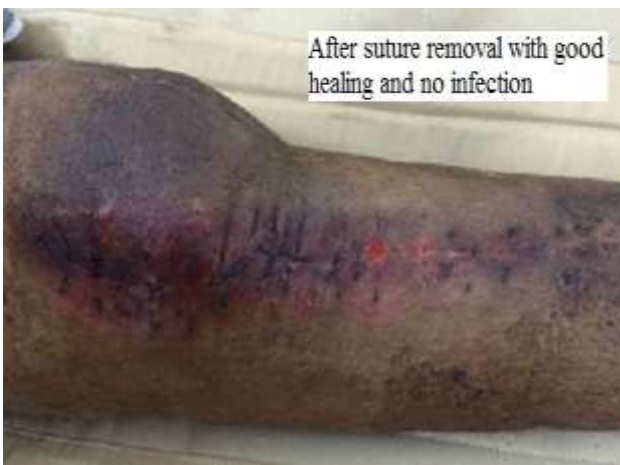

Figure 5: Following delayed suture removal.

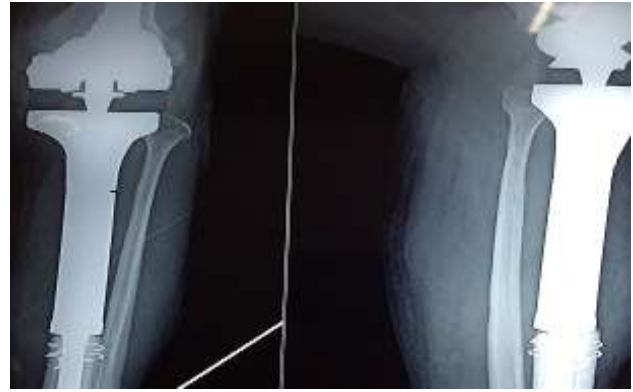

Figure 6: Follow-up at 8 months with no evidence of recurrence and good position of implant.

RESULTS

At a minimum follow-up of 8 months, all 7 patients were well with no infection. However due to debridement, a part of the patellar tendon was removed in all of them thus limiting knee extension. They had an extensor lag of 20 degrees. After 4 weeks, patients were made to mobilise with a hinged knee brace allowing 20-70 degrees knee flexion. The patients were assessed using knee society score (KSS) and they had an average score of 73 (good result). Better scores would have been anticipated with a better knee extension. There was no evidence of implant loosening, instability or tumour recurrence. All patients were satisfied with the result considering the other possible outcome would have been amputation and were comfortable using a hinged knee brace for an extended period of time.

Table 1: Patient demographic data with functional outcome.

S.No/Sex	Diagnosis	Bacteriological profile	Knee flexion at one year	Knee score at one year
1. Male	Recurrent GCT	<i>Staph. aureus</i>	72	75
2. Male	Recurrent Chondrosarcoma	<i>Staph. epidemidis</i>	71	71
3. Female	Recurrent GCT	<i>Staph. epidemidis</i>	66	73
4. Male	Recurrent GCT	<i>Staph. epidemidis</i>	71	77
5. Male	Osteosarcoma	<i>Staph. aureus</i>	70	69
6. Male	Recurrent GCT	<i>Staph. epidemidis</i>	68	73
7. Male	Chondrosarcoma	<i>Staph.</i>	72	73

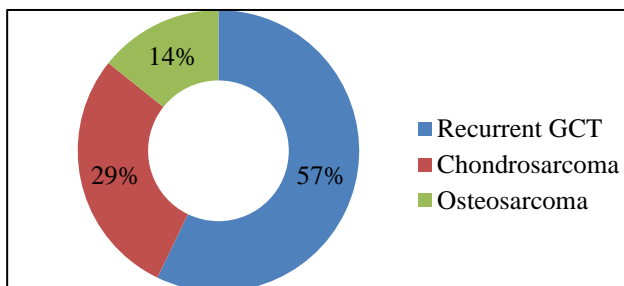


Figure 7: Chart showing patient data classification.

DISCUSSION

The results of our study on the use of VAC dressing are promising due to the fact that all our patients presented early with clinical symptoms of fever and localised warmth. Also our bacteriological profile showed that with aerobic bacteria, VAC is advantageous because the anaerobic environment created by VAC sounds the deathknell to these bacteria and reduces the bacterial load for the antibiotics to work thereafter. More importantly, due to the continuous negative pressure in the surgical

field, the formation of biofilm is significantly prevented allowing better penetrance of the antibiotics.

Wafa et al showed that silver coated prosthesis were more resistant to infections than non-silver coated designs although 30% of silver coated implants still had persistent periprosthetic infection.⁶ We used titanium implants in our study and though we did not use silver coated implants, we still had a 100 % success with our VAC method.

Rocco et al showed the use of VAC in closure of complex chest wall defects following resection of tumours in 32 high risk cases with extensive defects.⁷ The mean time to closure of defects was 14 months due to complexity of structures involved. The situation is however much simpler in proximal tibia with skin cover being the only challenge.

Jeys , Harges, and Ji et al showed that two stage revisions fared better with eradicating infections in tumour prosthesis.^{8,9,15} Jeys also pointed out that only 10% of infections occur around the 12 month period with majority occurring in the first few months after surgery. Flint and Grimer also showed two stage revisions to be a better treatment protocol with good infection control and salvage of the tumour prosthesis.^{5,21}

Pala, in his extensive review on complications showed that Type 4 failure (Infection) occurred in 9.3% of cases.¹⁰ Surprisingly the survivorship for infection in primary surgeries were 84% at 5 year versus 95% in revision surgeries. Marvogenis et al, showed similar survival rates of 88% at 10 years after two stage revisions.¹¹ Angelini, showed knee arthrodesis to be a viable salvage procedure for infected tumour prosthesis. However the success rates for the arthrodesis was only 50% at 5 years.¹³

The bacteriological profile in other series is similar to our series with the most common organisms seen being *Staphylococcus spp.*^{5,11,15-17} The sub species varied between studies with certain studies reporting *Staph. epidermidis* being more common than *Staph. aureus* in our study.^{5,11,12}

Fukagawa et al tried high dose antibiotic infusion in salvage of knee implants with good success rates for total knee arthroplasty (100%) but infected tumour prosthesis fared poorly (20%).¹⁸ We however performed radical debridement, wound lavage , antibiotics for 6 weeks and VAC in all our patients with excellent results (100% infection free) at 8 months.

CONCLUSION

Infections in orthopaedic surgeries remains a nightmare for every orthopaedic surgeon due to presence of expensive metallic prosthesis and implants. These metallic implants allow biofilm formation with poor

access to antibiotics. Persistent infections may result in either removal of the implants or in certain resistant situations, removal of the entire limb as a life saving measure. The role of VAC has been established in treating open wounds, non-healing ulcers and closure of complex soft tissue defects. We have now extended the use of VAC to treat a certain group of infected tumour prosthesis with excellent results. However early detection of infection, prompt decision making, radical debridement and correct use of VAC are all keystones to reproduce excellent results.

Funding: No funding sources

Conflict of interest: None declared

Ethical approval: The study was approved by the institutional ethics committee

REFERENCES

1. Aponte-Tinao LA, Ayerza MA, Muscolo DL, Farfalli GL. What Are the Risk Factors and Management Options for Infection After Reconstruction With Massive Bone Allografts. *Clin Orthop Relat Res.* 2016;474(3):669-73.
2. Pattanashetty OB, B B D, Pillai A, Endigeri P. Dedifferentiated Chondrosarcoma of Proximal Tibia and Fibula with an Infected Ulcer: A Case Report. *J Orthop Case Rep.* 2016;6(2):9-12.
3. Kundu ZS, Gupta V, Gogna P, Sangwan SS. Partial-limb salvage after persistent infection in the distal femoral prosthesis: straight-plasty--a novel technique. *J Coll Physicians Surg Pak.* 2014;24(3):213-5.
4. Morii T, Morioka H, Ueda T, Araki N, Hashimoto N, Kawai A, et al. Functional analysis of cases of tumor endoprostheses with deep infection around the knee: a multi institutional study by the Japanese Musculoskeletal Oncology Group (JMOG). *J Orthop Sci.* 2013;18(4):605-12.
5. Healey JH. CORR Insights™: High infection rate outcomes in long-bone tumor surgery with endoprosthetic reconstruction in adults: a systematic review. *Clin Orthop Relat Res.* 2013;471(6):2028-9.
6. Wafa H , Grimer RJ, Reddy K, Jeys L, Abudu A, Carter SR, et al. Retrospective evaluation of the incidence of early periprosthetic infection with silver treated endoprosthesis in high risk patients : case control study . *Bone Joint J.* 2015;97(2):252-7.
7. Rocco G, Martucci N, La Rocca A, La Manna C, De Luca G, Fazioli F, et al. Post-operative local morbidity and the use of vacuum assisted closure after complex chest wall reconstruction with new and conventional materials. *Ann Thoracic Surg.* 2014;98(1):291-6.
8. Jeys L, Grimer RJ. The long term risks of infection and amputations with limb salvage surgery using endoprosthesis. *Recent Results Cancer Res.* 2009;179:75-84.
9. Harges J, Ahrens H, Gosheger G, Nottrott M, Dieckmann R, Henricks MP, et al. Management of

- complications of megaprosthesis. *Unfalchirurg.* 2014;117(7):607-13.
10. Pala E, Trovaarelli G, Calabro T, Angelini A, Abati Cn, Ruggieri P. Survival of modern knee tumour prosthesis: failures, functional results and a comparative statistical analysis. *Clin Orthop Relat Res.* 2015;473(3):891-9.
 11. Marvogenis AF, Pala E, Angelini A, Calabro TT, Romagnoli C, Romantini M, et al. Infected prosthesis after lower extremity bone tumour resection: Clinical outcome of 100 patients. *Surg Infect (Larchmt).* 2015;16(3):267-75.
 12. Kundu ZS, Gupta V, Gogna P, Sangwan SS. Partial limb salvage after persistent infection in the distal femur prosthesis : straight plasty- a novel technique. *J Coll Physicians Surg Pak.* 2014;24(3):213-5.
 13. Angelini A, Henderson E, Trovarelli G, Ruggieri P. Is there a role of knee arthrodesis with modular endoprosthesis for tumour and revision of failed endoprosthesis? *Clin Orthop Relat Res.* 2013;471(10):3326-35.
 14. Pilge H, Gradl G, Von Eisenhart-Rothe R, Gollwitzer H. Incidence and outcome after infection of megaprosthesis. *Hip Int.* 2013;22(8):583-90.
 15. Ji T, Guo W, Yang R, Tang X. Two stage revisions for prosthesis infection in patients with bne tumour after knee prosthetic replacement. *Zhongguo Xiu Fu Chong Jian Wai KE Ze Zhi.* 2012;26(1):21-5.
 16. Marvogenis AF, Papagelopoulos PJ, Coll-Mesa L, Pala E, Guerra G, Ruggieri P. Infected tumour prosthesis. *Orthopedics.* 2011;32(12):991-8.
 17. Graci C, Maccauro G, Muratori F, Spinelli MS, Rosa MA, Fabbriani C. Infection following bone tumour resection and reconstruction using tumoural prosthesis- A literature review. *Int Immunopathol Pharmacol.* 2010;23(4):1005-13.
 18. Fukagawa S, Matsuda S, Miura H, Okazuki K, Tashiro Y, Iwamoto Y. High dose antibiotic infusion for infected knee prosthesis without implant removal. *J Orthop Sci.* 2010;15(4):470-6.
 19. Flint MN, Griffin AM, Bell RS, Wunder JS, Ferguson PC. Two stage revision of infected uncemented lower extremity tumour endoprosthesis. *J Arthroplasty.* 2007;22(6):859-65.
 20. Kunhe CA, Taeger G, Nast-Kolb D, Ruchholtz S. Knee arthrodesis after infected tumour megaprosthesis of the knee using an intramedullary nail for callus distraction. *Lagenbecks Arch Surg.* 2003;388(1):56-9.
 21. Grimer RJ, Belthhus M, Chandrasekar C, Carter SR, Tillman RM. Two stage revision for infected endoprosthesis used in tumour surgery. *Clin Orthop Relat Res.* 2002;295:193-203.

Cite this article as: Balasubramanian N, Sindhuja P. Salvage of infected proximal tibial tumour prosthesis using vacuum assisted closure in seven patients. *Int J Res Orthop* 2017;3:172-6.