

Original Research Article

Management of supracondylar fracture humerus type 3 in children with percutaneous K-wire vs. open reduction and internal fixation with K-wire

Shaik Md Waseem Ahmed^{1*}, R. Biju²

Department of Orthopedics, ¹Chalmeda AnandRao Institute of Medical Sciences, Bommakal Village, Karimnagar, Telagana, ²Narayana Medical college hospital, Nellore, Andhra Pradesh, India

Received: 05 October 2017

Revised: 12 November 2017

Accepted: 14 November 2017

*Correspondence:

Dr. Shaik Md Waseem Ahmed,
E-mail: drwaseem113@gmail.com

Copyright: © the author(s), publisher and licensee Medip Academy. This is an open-access article distributed under the terms of the Creative Commons Attribution Non-Commercial License, which permits unrestricted non-commercial use, distribution, and reproduction in any medium, provided the original work is properly cited.

ABSTRACT

Background: Aim of the study is to determine the relation between the reduction technique percutaneous pinning and open reduction and internal fixation with K-wire used in management of supracondylar humerus fractures in paediatric age group and the ultimate elbow status (functional and cosmetic), so that appropriate reduction technique can be adopted for better functional and cosmetic outcome.

Methods: Children below 12 years with Gartland's type III supracondylar fractures managed by closed reduction and percutaneous K-wire fixation and open reduction and K-wire fixation and Flynn's criteria was used to grade the outcome of surgical fixation. 10 Closed reduction and K-wire fixation and 10 open reduction and K-wire fixation were done.

Results: Most of the fractures were sustained when the patient had fallen down on out stretched hand while playing or slip and fall. According to Flynn's grading, there are 7 excellent, 2 good and 1 fair functional result observed in closed reduction and k wire fixation. There are 4 excellent, 3 good and 3 fair functional results observed in open reduction and k wire fixation with statistically significant p value 0.04.

Conclusions: Open reduction through lateral approach and internal fixation wire K wires is safe and effective method of treatment, if indicated, in supracondylar fractures of humerus in children and is associated with a good outcome. A small incision medially in cases where medial epicondyle cannot be defined to visualize the epicondyle and the ulnar nerve, by which iatrogenic ulnar nerve palsy in percutaneous fixation can be prevented.

Keywords: Supracondylar fracture, Flynn's criteria, Open reduction, K wire fixation

INTRODUCTION

Supracondylar fractures of the distal humerus are almost exclusively a fracture of the immature skeleton and it often instills a sense of apprehension in the treating surgeon. As man evolved from quadruped to biped the purpose of the forelimbs in the animals is changed from mere walking to prehension of the hands in human beings. Whenever a person falls instinctly, it is the hand

that comes for the protection; hence it is the bones of upper limbs that are likely to be fractured. Fracture classification is the same as for extension-type supracondylar fractures.¹ Type I, un displaced fracture; type II, minimally angulated with cortical contact; and type III, totally unstable displaced distal fracture fragment. Supracondylar extension type 0f fractures generally occur as a result of a fall onto the outstretched hand with the elbow in full extension. The fracture in the

sagittal plane was classically described by Kocher as extending obliquely from anterior and distal to posterior and proximal.²

At the beginning of 20th century, treatment began to change from simple passive methods to more aggressive and active methods. Scientific reasons and study began to alter the method of treatment. Newer imaging techniques greatly enhanced the ability to obtain and maintain an adequate reduction, with a marked reduction in incidence of complications.

The difficulties experienced by surgeons in making an accurate diagnosis; the facility with which serious blunders can be made in prognosis and treatment; and the fear shared by so many of the subsequent limitation of function, serve to render injuries in the neighborhood of the elbow less attractive than they might otherwise have proved. These concerns are applicable even today. In other bones, good results can often be obtained with minimal treatment, but in the elbow, more aggressive treatment is often required to avoid complications.

Because children tend to protect themselves with their outstretched arms when they fall, upper-extremity fractures account for 65% to 75% of all fractures in children.³

The most common area of the upper extremity injured is the distal forearm, 7% to 9% of upper-extremity fractures involve the elbow.^{4,5}

The distal humerus accounts for approximately 86% of fractures about the elbow region. Supracondylar fractures are the most frequent elbow injuries in children, reported to occur in 55% to 75% of patients with elbow fractures.⁶ Lateral condylar fractures are the second most common, followed by medial epicondylar fractures. Fractures of the olecranon, radial head and neck, and medial epicondyle and T-condylar fractures are much less common.

In the literature, the notable evolution in the management of supracondylar fractures has been an increasing emphasis on early motion. The difficulty in adequately stabilizing a closely reduced or openly reduced fractures without extremes of positioning the elbow has led to the development of internal fixation. The accurate reduction and stable fixation can often optimize ultimate function and limit long-term disability.

This study has been undertaken to observe the results of management of supracondylar fractures by closed reduction and percutaneous K-wire fixation and open reduction and K-wire fixation. Patients selected for this study were children below 12 years with Gartland's type III fractures who were admitted and treated in the Narayana Medical College Hospital, Nellore between August 2012 to March 2014.

METHODS

This is a prospective study including the patients operated for displaced supracondylar fractures of humerus from Aug 2012 to Mar 2014 in Narayana Medical college hospital, Nellore. Antero-posterior and Lateral radiographs were taken for all cases. Anthropometric data, type of fracture, neuro-vascular status, associated injuries, surgical approach used, reduction method used, complications and outcome were recorded. Flynn's criteria⁷ was used to grade the outcome of surgical fixation.

Inclusion criteria

Children with displaced supracondylar fracture of humerus with an open physis, (Grade III Gartland's type) willing to participate in study after giving informed consent.

Exclusion criteria

Exclusion criteria were patients with displaced fracture but with closed physis; undisplaced and minimally displaced fractures (Gartland type I and II); compound fractures.

Indications

For closed reduction

Fresh closed displaced fractures of less than 1 week duration and with no neurovascular injury that demand repair.

For open reduction

1. Failed closed reduction
2. Old fractures (>1 week duration)
3. Fractures with neurovascular injury that demand repair

Technique of reduction

The patient is anesthetized, and the affected arm is extended over the screen of the C-arm fluoroscopic unit. Longitudinal traction is applied first to dislodge the proximal fragment, which may be entrapped in the brachialis muscle, the ante-cubital fascia, or the superficial fat and skin.

Milking maneuver

If traction does not restore length and alignment, milking maneuver has been described by Archibeck and Peters to disengage the proximal fragment from the soft tissue.^{8,9} This maneuver is carried out by manipulating the soft tissue over the fracture to pull the soft tissue away from the proximal fragment rather than simply applying traction on the bones, which may not allow reduction of a

buttonholed proximal fragment. Once length is restored, medial or lateral translation is corrected. The image intensifier is helpful for this because the medial and lateral columns should be realigned on the AP image. Rotation is corrected simultaneously, but in general, malrotation resolves as traction is applied and as the medial and lateral alignment is corrected, due to the effect of the surrounding soft tissue. A flexion reduction maneuver is then performed with pressure of the thumb over the olecranon and to a variable degree, over the distal condyles of the humerus. Generally, the fracture reduction can be felt, and the elbow is then held in hyper flexion and pronation to achieve a stable reduction.

The pulse is usually obliterated in this position, and the hand is pale. But circulation will be restored in nearly all cases once the fracture is stabilized and the elbow is extended.

Confirming reduction

AP (Jones' view) and lateral views are obtained using the image intensifier. With the elbow flexed, a pure AP view is difficult to interpret, so the actual AP view is taken by rotating the C-arm slightly medially and laterally to view the columns of the distal humerus and the reduction of the fracture. The C-arm should be rotated to obtain AP and lateral views rather than attempting to rotate the arm and losing a tenuous reduction. An anatomic or nearly anatomic reduction is a prerequisite for skeletal stabilization.

Acceptable reduction

An acceptable position is determined by

1. Anterior humeral line transecting the capitellum on the lateral X-ray,
2. Baumann angle of 72 to 81 degrees or equal to the other side and
3. An intact olecranon fossa.

In patients in whom a closed reduction cannot be obtained, there is risk that entrapment of neurovascular structures prevents realignment and open reduction is indicated.

Methods of pinning

1. Lateral pinning (parallel or divergent): Two or three lateral pins provide less stability than crossed pins, but there is no risk to the ulnar nerve, which is a significant benefit of this technique¹⁰⁻¹³.
2. Crossed pinning.

Open reduction

Indications

1. Failed gentle closed reduction

2. Old fractures (>1 week duration)
3. Fractures with neurovascular injury that demand repair
4. Compound fractures

Traction management of type III supracondylar fractures

1. sidearm or lateral skin traction (Dunlop's traction)
2. Overhead traction (skeletal traction)

The indications for traction are:

1. As the definitive management for fracture with supracondylar comminution or medial column comminution that is not suitable for pinning and would certainly collapse with simple casting after reduction. The usual duration of traction is usually about 14 days before cast immobilization in this rapidly healing fracture
2. Traction allows swelling to decrease and facilitates closed reduction. In this technique, patients are placed in sidearm or overhead skin traction for 3 to 5 days until elbow hyper flexion can be tolerated for closed reduction and percutaneous pinning.

Two categories

1. Impairment of the function
2. Cosmetic squealae

Statistical analysis used student's t test for quantitative variables by SPSS 16.0 version software.

RESULTS

This is a prospective and retrospective study including the 20 patients operated for displaced supracondylar fractures of humerus from August 2010 to March 2014 prospectively. Closed reduction and K-wire fixation were done in 10 cases and open reduction and K-wire fixation in 10 cases.

Age Incidence

All cases selected had open physis and between 0-12 yrs of age. 20% in 0-4 years, 50% in 5-9 years and 30% in 10-12 years were enrolled. 5 cases in 5-9 years and 5 cases in 10-12 years belong to open reduction and K wire fixation. There are 5 female and 5 male cases belongs to closed reduction and K wire fixation. Whereas 10 cases are belongs to male category.

Etiology

In the present series all cases of both groups had a history of trauma either direct or indirect. In closed reduction and K wire fixation, 5 are of fall on outstretched hand while playing, 3 cases are of Slip and fall, and one each case on fall from height and RTA etiology were observed. In

open reduction and k wire fixation, 3 cases are of fall on outstretched hand while playing, 3 cases are of slip and fall, 2 cases in fall from height and 2 cases in RTA were observed. In open reduction, 8 Fall on outstretched hand while playing, 6 cases in Slip and fall on outstretched hand, each 3 cases in fall from height and RTA were recorded. Most of the fractures were sustained when the

patient had fallen down on out stretched hand while playing or slip and fall. 5 cases in left and 5 cases in right sided fractures and these are managed through Closed Reduction and K wire fixation. 8 cases in left and 2 cases in right sided fractures and these are managed through closed open reduction and K wire fixation (Figure 1).

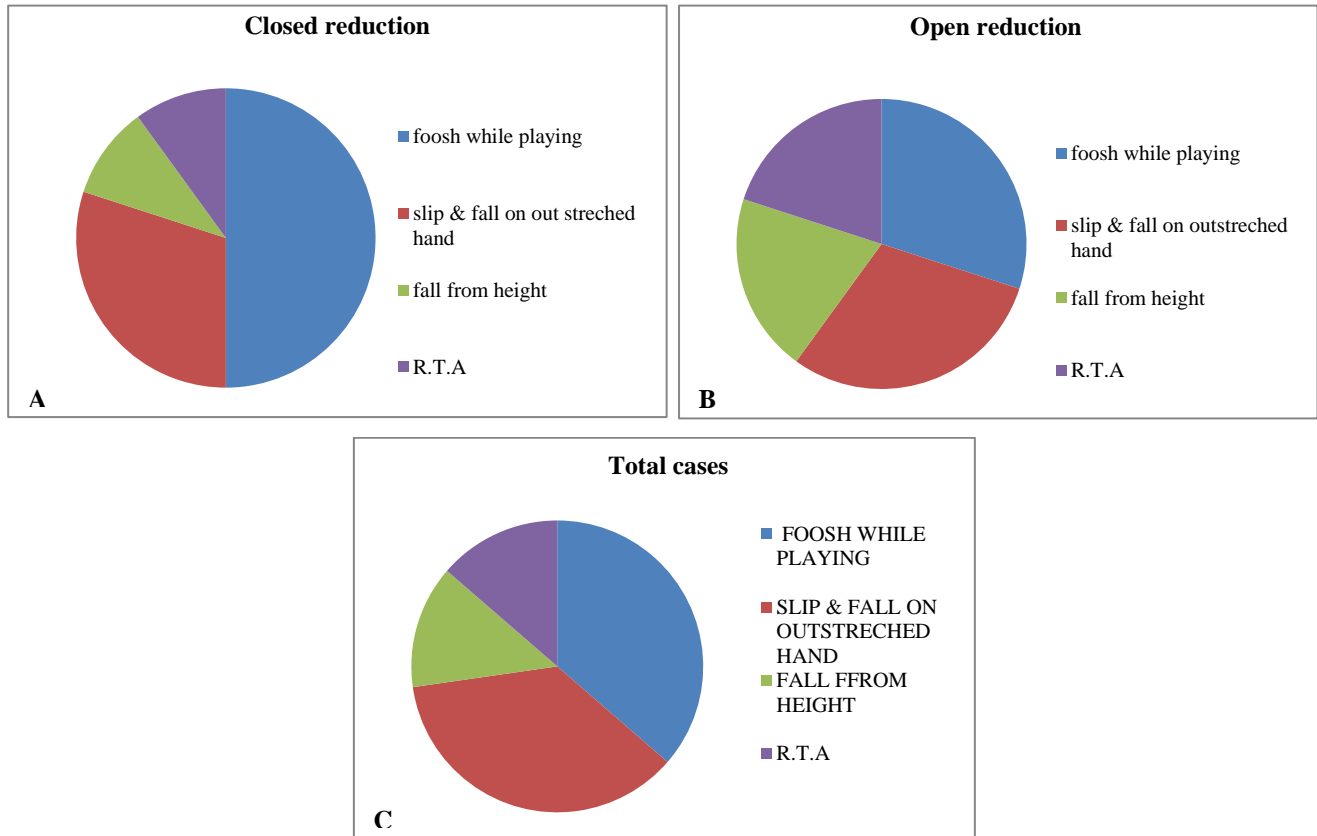


Figure 1: Mode of injury and open reduction and k wire fixation. *FOOSH- fall on out stretched hand. (A= Closed reduction; B= Open reduction; C= Total cases).

Associated fractures

1 case (Green stick # both bones forearm) in those treated with closed reduction. 1 case (closed # distal radius) in those treated with closed reduction. Overall 1% of cases have been associated with other #.

Associated vascular injury

3 cases (30%) of those operated by open reduction are associated with vascular injury. 2 cases of brachial artery impingement. 1 case of brachial artery injury observed. Overall 15% of cases are associated with vascular injury that demanded vascular exploration.

Associated neurological injury

There are 2 cases of associated median nerve injury and 2 cases of associated radial nerve injury were observed.

Overall, 4 cases (20%) had associated neurological injury.

Type of construct used

7 cases used lateral pinning and 3 cases used crossed pinning. 8 cases managed through lateral pinning and 2 cases through crossed pinning in open reduction and K wire fixation. There are 4 cases failed closed reduction, 3 cases had vascular injury, 3 cases had delayed presentation (>1 week) were indication of open reduction in our series.

Complications

Ulnar nerve palsy in 1 case (treated by closed reduction and crossed construct), pin tract infection in 2 cases, cubitus varus in 1 case (closed reduction) and there was no delayed union, non-union, Myositis ossificans and Volkmann’s ischemic contracture cases.

Grading of results (as per Flynn's)

The lower of the two ratings is the overall rating, and an elbow that has a varus deformity is automatically graded as poor (Table 1).

Table 1: Grading of results as per Flynn's.

Result	Loss of carrying angle (in degrees)	Loss of elbow range (in degrees)
Excellent	0-5	0-5
Good	6-10	6-10
Fair	11-15	11-15
Poor	>15	>15

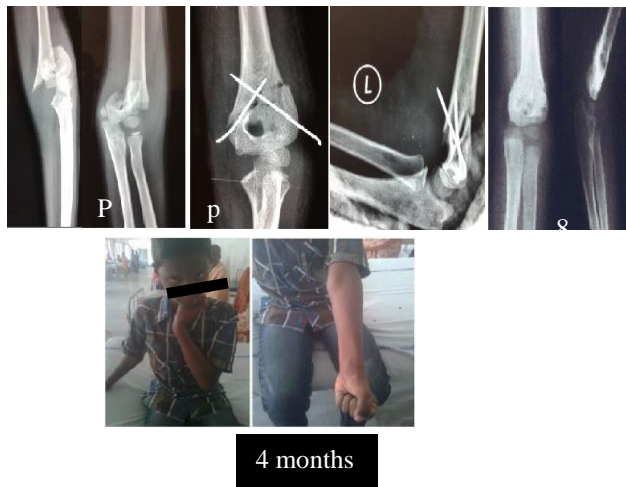

Figure 2: X-ray and clinical pictures of case 2.

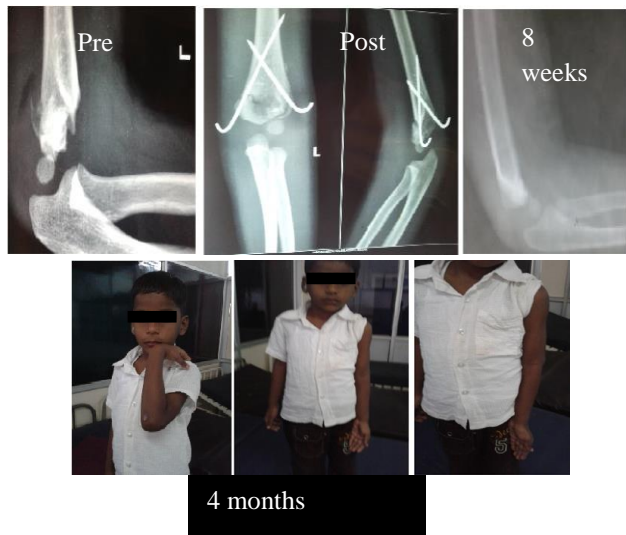


Figure 3: X-ray and clinical pictures of case 3.

There are 7 excellent, 2 good and 1 fair functional results observed in closed reduction and k wire fixation. There are 4 excellent, 3 good and 3 fair functional results observed in open reduction and K wire fixation. P value is 0.04, hence p value is statistically significant. All clinical

assessments were associated with radiographs (Figures 2-4).

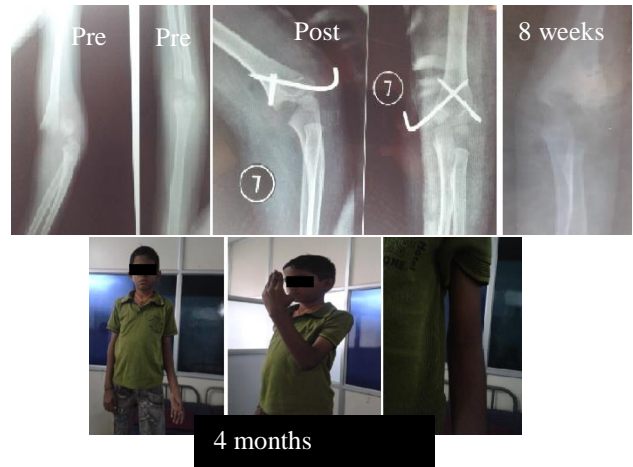

Figure 4: X-ray and clinical pictures of case 4.

DISCUSSION

Supracondylar fractures of humerus are common fractures occurring in childhood. Prompt and effective treatment should be given to these injuries to achieve best possible results. Adequate history and clinical evaluation including neurovascular status of the limb, radiological diagnosis and classifying the fracture are imperative before giving any mode of treatment. Anatomical reduction and stable fixation followed by proper physiotherapy are mandatory to get good results. Our series consists of 20 cases of displaced (Gartland's Type III) supracondylar fractures of humerus in children treated by either closed reduction and percutaneous K wire fixation or open reduction and K wire fixation under general anesthesia and C-arm control.

Of all the supracondylar fractures, only those patients with open physis and who belonged to Gartland's Type III are included in our study. Out of 20 cases, all the cases were of extension type with either postero-medial or postero-lateral displacement of distal fragment.

Wilkins et al compiled data from 7212 fractures occurring in 61 major series.¹⁴ They observed male dominance with 62.8%; non-dominant limb involved in 60.5% of cases. Average age was 6.7 years. 1% of cases were flexion type. In 1% of the cases, ipsilateral fractures of forearm were found; 1% was open fractures. Neurological injury found in 7.7% of cases, out of these radial nerve was involved in 41.2%; median nerve was involved in 36% of cases, ulnar nerve in 22.8% of cases.

In our series, average age was found to be 7.5 in cases operated by closed reduction and 8.9 yrs in cases operated by open reduction. Overall the average age was found to be 8.2 yrs, with 8.46yrs in boys and 7.4 yrs in girls. When compared to Wilkins study average age of incidence in our study is 1.5 yrs more towards elder side.

There is male preponderance with 75% (overall), which is comparable to Wilkins study (62.8%).¹⁴ In our series supracondylar fractures are common in non-dominant side with an incidence of 65% which is comparable to Wilkins study and observation of Cheng et al.¹⁰

It was found that the injury was caused by low energy trauma. Most of them were sustained due to fall on outstretched hand due to slip and fall or while playing at home or school, which accounts for 70% of cases. 15% of cases were injured in RTA and 15% of cases sustained injury due to fall from height. Out of the 20 cases, 3 cases had an association with vascular injury.

1% of cases, one each in those treated by closed reduction and open reduction were associated with fractures of ipsilateral forearm. Green stick # of distal end of both bones associated with closed supracondylar # was managed conservatively and the distal radius # associated with supra condylar fracture was managed with percutaneous k wire fixation.

Culp et al, observed 12.8% neural injuries in their retrospective review of displace extension type of supracondylar fractures in 101 children. 70% of them spontaneously resolved at a mean of 2.5 months. They concluded that observation and supportive therapy is the preferred initial approach; if there is no clinical or electromyographic evidence of return of neural function at 5 months after injury, exploration and neurolysis is indicated.¹⁵

Lyons et al, found 13.3% of neural compromise, combined nerve and vascular compromise in 2.9% of patients. Median nerve injury accounted for 58.9% of nerve injuries, followed by radial (26.4%) and ulnar (14.7%) lesions, 80% of them are anterior interosseous nerve compromise.¹⁶

In our series the overall incidence of neural involvement was 20%. Out of these median nerve was involved in 2 cases (10%) and radial nerve was involved in 2 cases (10%). Spontaneous recovery occurred in all within a mean time of 4 months without any surgical intervention.

Vascular compromise was found in 3 cases. The overall incidence was 15%. Exploration was done in all cases. Compression of the artery was released in two cases. Intimal injury and thrombus was found in one case which was treated by thrombectomy and end to end anastomosis.

Majority of the cases were admitted on the day of injury. All cases were taken up under general anesthesia as early as possible. Out of 10 cases operated by open reduction, 40% had irreducible # by closed method, 20% had # with delayed presentation (>1 week), 20% had closed vascular injury, 10% had vascular injury and 10% had nerve palsy.

Reitman et al managed 65 type III fractures with open reduction and pinning.¹⁷ Of the 65 patients who were managed with open reduction, 46 (71%) were due to irreducibility of fracture, 16 (24%) had associated vascular compromise, 8 (12%) were open and one was associated with post reduction nerve palsy. According to the criteria of Flynn et al, 18 (55%) elbows were rated excellent, 8 (24%) were rated good three (9%) were rated fair and 4 (12%) were rated poor after an average of 5.8 months post injury.⁷

Skaggs et al concluded that there was no difference with regard to maintenance or fracture reduction between the crossed pins configuration and the two lateral pin configuration. They found that use of a medial pin was associated with ulnar nerve injury in 4% of the cases.¹⁸

Reynolds et al have shown that there is a biomechanical advantage of crossed pin construct as opposed to two lateral pin construct. However they have found 4.5% incidence of ulnar nerve injury with medial pin placement.¹⁹

We have fixed the reduced fracture with a crossed pin technique in 25% of cases and a lateral two pin construct in 75% of cases. Our criteria for a medial pin was to place it if the fixation is found to be unstable with two lateral pins alone.

No neuro vascular deficit occurred in cases of open reduction and K wire fixation. Ulnar neuropraxia was identified in 1 case of closed reduction and crossed pin construct and it recovered within 4 weeks. Immediately after identifying the palsy the K wire was removed. In order to protect the ulnar nerve during medial pin placement, push the nerve anteriorly during pinning or use a small incision over the medial epicondyle in the presence of gross swelling.

The results of the treatment were assessed using the criteria of Flynn et al., to compare the motion and carrying angle of the injured and the un injured elbow.⁷ The function is graded in 5 degree intervals of loss of flexion or extension, and the cosmetic appearance of elbow is graded in 5 degree intervals of change in the carrying angle, with any varus angulation resulting in a poor grade. Yaokreh et al observed that in paediatric extension-type supracondylar fractures of elbow, out of 58 children, outcomes were satisfactory in 30 (90.9%) patients treated with percutaneous pinning and in 23 (92%) patients treated with open reduction and cross-wiring. Iatrogenic nerve injury in two (3.4%) patients. Cubitus varus occurred in two (6.06%) patients after closed treatment and in one (4%) patient after open treatment.²⁰

In our study out of 10 cases managed by closed reduction excellent to good results are seen in 90% of cases and

only 1 case had a poor result, which had a varus deformity due to loss of reduction.

Out of 10 cases that were managed by open reduction, excellent result is seen in 4 cases (40%), good result is seen in 3 cases (30%) and poor result in 3 (30%) cases.

Poor result is seen in one case of fracture with vascular injury and in two cases that presented late with resolved compartment syndrome. The most probable causes of poor results are:

a. Vascular injury

- I) Extensile incisions given for the vessel repair and grafting.
- II) Delayed mobilization

b) Delayed presentation with compartment syndrome:

- I) Decreases the pliability of the soft tissue preventing closed reduction.
- II) Iatrogenic damage to soft tissue adds up to the stiffness.

In conclusion, excellent to good results were obtained in about 90% of cases of closed reduction and K wire fixation and excellent to good results in 70% of cases operated by open reduction and K wire fixation. The indication of open reduction remains limited because of risk of stiffness of injury due to iatrogenic soft tissue injury. It is recommended to limit lateral approach for prevention of stiffness which may be more common in posterior approach. Open reduction and internal fixation is an effective and safe method of treatment if indicated and is associated with good outcome. The concept of anatomical reduction and percutaneous pinning, followed by early and proper physiotherapy is the choice of obtaining excellent results functionally and cosmetically in Gartland's type III supracondylar fracture humerus management in children.

CONCLUSION

Higher incidence in males and in non-dominant humerus. The K wires should be separated by a minimum distance of 10 mm at the fracture site. The C-arm should be rotated, and not the arm to get an intraoperative lateral view. The concept of gentle closed reduction and percutaneous K wire fixation followed by early physiotherapy is the treatment of choice for obtaining excellent results functionally and cosmetically in Gartland's Type III supracondylar fractures of humerus in children. Open reduction through lateral approach and internal fixation wire K wires is safe and effective method of treatment, if indicated, in supracondylar fractures of humerus in children and is associated with a good outcome. A small incision medially in cases where medial epicondyle cannot be defined to visualize the epicondyle and the ulnar nerve, by which iatrogenic ulnar

nerve palsy in percutaneous fixation can be prevented. Observation and supportive therapy is the preferred initial approach in nerve injuries associated with this fracture. K wires can be removed safely at 3-4 weeks after injury and mobilization of the elbow should be started after the third week.

Funding: No funding sources

Conflict of interest: None declared

Ethical approval: The study was approved by the institutional ethics committee

REFERENCES

1. Gartland JJ. Management of supracondylar fractures of the humerus in children. *Surg Gynecol Obstet.* 1959;109(2):145-54.
2. Kocher T. *Beitrage zur Kenntniss Einiger Praktisch Wichtiger Fracturformen.* Edited by Sallmann C, Basil, 1895.
3. Topping RE, Blanco JS, Davis TJ. Clinical evaluation of crossed-pin versus lateral-pin fixation in displaced supracondylar humerus fractures. *J Pediatr Orthop.* 1995;15(4):435-9.
4. Bristow WR. Myositis ossificans and Volkmann's paralysis: notes on two cases, illustrating the rarer complications of supracondylar fracture of the humerus. *Br J Surg.* 1923;10:475-81.
5. Campbell CC, Waters PM, Emans JB, Kasser JR, Millis MB. Neurovascular injury and displacement in type III supracondylar humerus fractures. *J Pediatr Orthop.* 1995;15(1):47-52.
6. Copley LA, Dormans JP, Davidson RS. Vascular injuries and their sequelae in pediatric supracondylar humeral fractures: toward a goal of prevention. *J Pediatr Orthop.* 1996;16(1):99-103.
7. Flynn JC, Mathews JG, benoit RL. Blind pinning of displaced supracondylar fractures of the humerus in children: sixteen years experience with long term follow up. *J Bone Joint Surg Am.* 1974;56:263-72.
8. Archibeck MJ, Scott SM, Peters CL. Brachialis muscle entrapment in displaced supracondylar humerus fractures: a technique of closed reduction and report of initial results. *J Pediatr Orthop.* 1997;17(3):298-302.
9. Peters CL, Scott SM, Stevens PM. Closed reduction and percutaneous pinning of displaced supracondylar humerus fractures in children: description of a new closed reduction technique for fractures with brachialis muscle entrapment. *J Orthop Trauma.* 1995;9(5):430-4.
10. Cheng JC, Lam TP, Shen WY. Closed reduction and percutaneous pinning for type III displaced supracondylar fractures of the humerus in children. *J Orthop Trauma.* 1995;9(6):511-5.
11. Onwuanyi ON, Nwobi DG. Evaluation of the stability of pin configuration in K-wire fixation of displaced supracondylar fractures in children. *Int Surg* 1998;83(3):271-4.

12. Arino VL, Lluch EE, Ramirez AM, et al. Percutaneous fixation of supracondylar fractures of the humerus in children. *J Bone Joint Surg (Am)*. 1977;59(7):914-6.
13. Skaggs DL, Cluck MW, Mostofi A, et al. Lateral-entry pin fixation in the management of supracondylar fractures in children. *J Bone Joint Surg Am*. 2004;86(4):702-7.
14. Wilkins KE, Beaty J. *Fractures in Children*. Philadelphia: Lippincott-Raven, 1996.
15. Culp RW, Osterman AL, Davidson RS et al: Neural injuries associated with supracondylar fractures of the humerus in children. *J Bone Joint Surg*. 1990;72:1211-5.
16. Lyons ST, Quinn M, Stanitski CL. Neurovascular injuries in type III humeral supracondylar fractures in children. *Clin Orthop Relat Res*. 2000;(376):62-7.
17. Reitman RD, Waters P, Millis M. Open reduction and internal fixation for supracondylar humerus fractures in children. *J Pediatr Orthop*. 2001;21:456-9.
18. Skaggs DL, Hale JM, Bassett J, Kaminsky C, Kay RM, Tolo VT. Operative treatment of supracondylar fractures of the humerus in children. The consequences of pin placement. *J Bone Joint Surg Am*. 2001;83(5):735-40.
19. Reynolds RA, Mirzayan R. A technique to determine proper pin placement of crossed pins in supracondylar fractures of the elbow. *J Pediatr Orthop*. 2000;20(4):485-9.
20. Yaokreha JB, Gicquel P, Schneider L, Stanchina C, Karger C, Saliba E, et al. Compared outcomes after percutaneous pinning versus open reduction in paediatric supracondylar elbow fractures. *Orthop Traumatol Surg Res*. 2012;98:645-51.

Cite this article as: Ahmed SMW, Biju R. Management of supracondylar fracture humerus type 3 in children with percutaneous K-wire vs. open reduction and internal fixation with K-wire. *Int J Res Orthop* 2018;4:120-7.