

## Original Research Article

# Evaluation of temporomandibular joint disorders using cone beam computed tomography

Sonam Kohli<sup>1\*</sup>, Rahul Krishan Sharma<sup>2</sup>, Anchal Goel<sup>3</sup>, M. K. Sunil<sup>4</sup>

Department of Dental Surgery, <sup>1</sup>ASCOMS & Hospital, Sidhra, J&K; <sup>2</sup>Daswani Dental College Kota, Rajasthan; <sup>3</sup>Inderprastha Dental College Sahibabad, Ghaziabad; <sup>4</sup>Guru Nank Dev Dental College and Research Institute, Sunam, Punjab, India

**Received:** 02 May 2017

**Revised:** 09 May 2017

**Accepted:** 15 May 2017

### \*Correspondence:

Dr. Sonam Kohli,

E-mail: [dr.sonamkohli1988@yahoo.in](mailto:dr.sonamkohli1988@yahoo.in)

**Copyright:** © the author(s), publisher and licensee Medip Academy. This is an open-access article distributed under the terms of the Creative Commons Attribution Non-Commercial License, which permits unrestricted non-commercial use, distribution, and reproduction in any medium, provided the original work is properly cited.

## ABSTRACT

**Background:** The aim of this study was to evaluate efficacy of segmental cone beam computed tomography (CBCT) in detecting bony changes in condyle and thickness of roof of glenoid fossa in temporomandibular joint (TMJ) disorders.

**Methods:** The study group comprised of 10 temporomandibular disorders (TMD) patients of either sex between the age group of 20-60 years diagnosed as TMDs by clinical evaluation using the research diagnostic criteria was considered. After the clinical examination, radiographic investigations were carried out which included digital OPG, transcranial radiograph and CBCT scan. TMJ Evaluation included: (a) bony changes of the condyle (flattening, erosion, sclerosis, osteophytes, resorption); (b) joint space (normal, increased, reduced, bony contact between the condyle and the mandibular fossa); and (c) bony changes of mandibular fossa (normal, sclerosis, erosion, resorption). The radiographic findings were statistically analysed.

**Results:** Significant difference between OPG, transcranial and CBCT were found for the presence of erosion (P=0.000), thickness of roof of glenoid fossa (P=0.000), deformed contour (P=0.001), joint space (P=0.011), subchondral sclerosis (P=0.011), irregularity of articular surface and eminence (P=0.000), flattening (P=0.050).

**Conclusions:** Using CBCT as imaging technique in our study to detect osseous changes in the TMJ was proved to be effective as compared to the conventional radiographic techniques, the results achieved with CBCT was 100%. The results obtained in our study prove to be a full proof one and it seems to promise to go one step closer to detect progression and severity of the osseous changes in the condylar head and mandibular fossa in patients with TMDs.

**Keywords:** Temporomandibular joint, Cone beam computed tomography, Transcranial, Glenoid fossa, Sclerosis, Osteophytes

## INTRODUCTION

TMDs are recognized as the most common chronic orofacial pain conditions confronting dentists and other health care providers. It refers to cluster of disorders characterized by pain in the preauricular area, pain in the TMJ, or in the region of muscles of mastication, also limitation and deviation in the mandibular range of

motion, and felt noises in the TMJ during mandibular function.<sup>1-3</sup>

Joint Imaging provides information about joint status and function that helps establish a definitive diagnosis in TMJ and cervical joint disorders. The most common techniques for TMJ imaging are the transcranial radiograph, tomogram without contrast, arthotomogram with contrast, CT scan and MRI.<sup>4</sup>

Cone beam computed tomography technique (CBCT) presents an innovation of tomographic imaging system and subsequent volumetric image reconstruction for dentistry. When compared with other methods of tomographic imaging, CBCT is characterized by rapid volumetric image acquisition from single low radiation dose scan of the patient.<sup>5-8</sup>

CBCT's accuracy and lack of superimposition makes it possible to measure the roof of the glenoid fossa and visualize the location of the soft tissue around the TMJ, which can offer a workable diagnosis and reduce the need for MRI.<sup>9</sup>

Currently CBCT is most commonly used in the assessment of bony and dental pathologic conditions including fractures, maxillofacial deformity, fracture recognition, preoperative assessment of impacted tooth, TMJ disorders and in analysis of available bone for implant placement.<sup>10</sup> The incorporation of 3D into dental practice and craniofacial imaging is now a reality. Craniofacial CBCT was designed to counter some of the limitations of earlier generations of CT scanning devices and to make 3D technique practical for dentistry.<sup>11,12</sup>

## METHODS

This study was carried out in the Department of Oral Medicine and Maxillofacial Radiology, D. J. College of Dental Sciences and Research, Modinagar. CBCT Imaging for the study was performed at Dr. Sahai's Dental and Maxillofacial Diagnostics, Raj Nagar, Ghaziabad. The study group comprised of 10 TMD patients of either sex between the age group of 20-60 years reported to the Department of Oral Medicine and Radiology during the time period from January 2012 to January 2013. Patients diagnosed as TMDs by clinical evaluation using the research diagnostic criteria were considered. The patients were informed about the radiographic procedure provided to them and they agreed and signed the consent form.

Inclusion criteria were patients with TMJ disorders with age group of 20-60 years of age of both the sexes and exclusion criteria were patients with any TMJ malignancy and with any traumatic condition of TMJ.

### Clinical examination

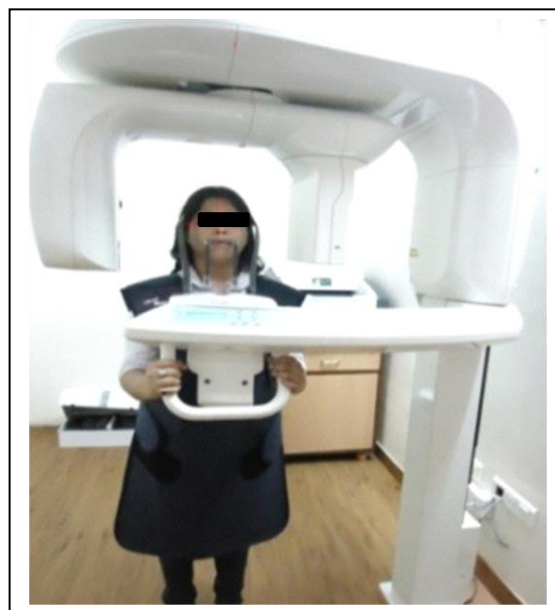Patients were made to sit comfortably on a dental chair. Clinical examinations were carried out wearing sterile hand gloves and mouth mask with the patient seated appropriate to the procedure being performed. Recording of demographic data, general history, TMD history and physical examination were carried out in a systematic manner. Clinical examination was based on the research diagnostic criteria. After the clinical examination, radiographic investigations were carried out which included digital OPG, transcranial radiograph and CBCT scan.

**Table 1: Research diagnostic criteria/TMD classification (1992).**

Clinical location	RDC/TMD diagnosis
Muscle	Myofascial pain
	Myofascial pain with limited opening
Disc displacement	Disc displacement with reduction
	Disc displacement without reduction with limited opening
	Disc displacement without reduction, without limited opening
Articular bone	Arthralgia
	Osteoarthritis of TMJ
	Osteoarthrosis of TMJ

### Methodology for CBCT scan

Limited CBCT Scan (CS 9300, Care stream Health Inc. Rochester, NY) of the right and left TMJs were obtained in closed mouth position using the TMJ program at exposure field (FOV) – 8 cm × 8 cm with default exposure parameters 5 mA and 90 kVp at voxel size 200 microns (0.2 × 0.2 × 0.2 mm) and scan time 6.20 seconds (Figure 1).



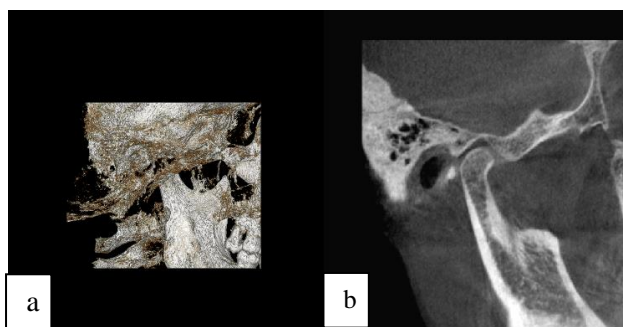
**Figure 1: Positioning of patient for CBCT scan.**

### Patient positioning

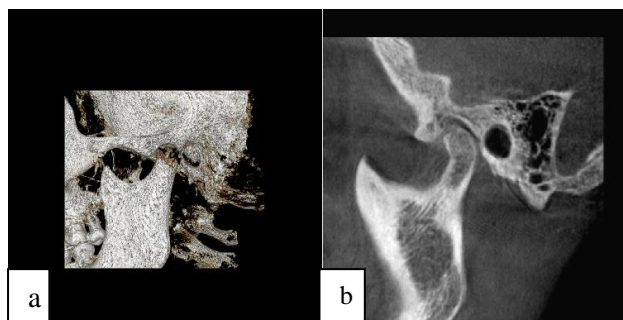
Patient entry within the rotative arm of the unit followed by lowest position of adjustable chin rest base and use of 3D bite platform between the upper and lower arches. Patient adjustment was performed using laser positioning beams to align mid-sagittal plane and 3D FOV beam to align vertical dimension of exposed tissue volume. Selection of right / left TMJ 3D program leads to auto-

orientation of the unit center of rotation (focal trough) over the right / left TMJ region of the patient.

Image reconstruction in true axial, sagittal and coronal planes was performed by the CS 3D software program. Oblique MPR were reconstructed according to the individual angle of the condylar head within the glenoid fossa. These images were obtained parallel or perpendicular to the long axis of the condyle as in Figure 2 and 3.



**Figure 2: CBCT findings of right TMJ. a) slight posterior position of condylar head with in glenoid fossa and b) slight flattening of articular surface of right TMJ condylar head.**



**Figure 3: CBCT findings of left TMJ. a) mild flattening of articular surface of left TMJ condylar head and b) mild articular surface irregularity and grade I erosion present in middle third of condylar head.**

Alternatively, the axial image of the TMJ was used as reference view for secondary reconstruction by tracing a line that corresponds to long axis of examined condyle. The software then generates para-sagittal and para-coronal sections perpendicular to antero-posterior and transverse long axis of condylar head.

#### TMJ assessment<sup>5</sup>

*Criteria for determination of type of condylar bone change*

- Type N: No proliferation or thickening on the cortical surface of the condyle; displaying typical morphology.

- Type F: Flattened contour at the anterosuperior and/or posterosuperior portions of the condyle.
- Type E: Proliferation or partial hypodense change with or without roughening on the cortical surface of the condyle
- Type D: The condyle has a deformed contour, like a beak, without proliferation nor partial hypodense change on the condylar surface.
- Type S: Type D accompanied by Type E.

Measurement of the thickness of the roof of glenoid fossa will be performed on the paracoronal images. Linear measurements will be made 3 times by a single investigator on the thinnest area of the glenoid fossa identified among multiple slices on the monitor; the mean value of the 3 readings will be recorded.<sup>13</sup>

*Criteria for the assessment of osseous changes of the condyle*

Osseous changes of the condyles:

- Flattening :defined as a flat bony contour deviating from the convex form;
- Erosion, defined as an area of decreased density of the cortical bone and the adjacent subcortical bone;
- Osteophytes: defined as marginal bony outgrowths on the condyle;
- Sclerosis: defined as an area of increased density of cortical bone extending into the bone marrow; and
- Resorption: defined as partial loss of condylar head.

*Criteria for the assessment of severity of erosion in the condylar head*

- 0: Absence of erosion
- 1: Slight erosion: when decreased density is observed only in the cortical bone
- 2: Moderate erosion: when decreased density is observed in the cortical bone and extends to the upper layers of the adjacent subcortical bone
- 3: Extensive erosion: when decreased density is observed in the cortical bone and extends below the upper layers of the adjacent subcortical bone.

*Criteria for the assessment of severity of osteophyte formation in the condylar head*

- 0: absence
- 1: Slight, when marginal bony outgrowth on the condyle was less than 1 mm
- 2: Moderate, when marginal bony outgrowth on the condyle was 1–2 mm
- 3: Extensive, when marginal bony outgrowth on the condyle was more than 2 mm.

*Osseous changes of the mandibular fossae*

(1) erosion, (2) sclerosis and (3) resorption.

### Criteria for the assessment of joint space

- Increased, when the distance between the condylar head and mandibular fossa was more than 4 mm;
- Normal, when the distance between the condylar head and mandibular fossa was between 1.5 mm and 4 mm;
- Reduced, when the distance between the condylar head and mandibular fossa was less than 1.5 mm; and
- Bony contact between condyle and mandibular fossa.

### Statistical analysis

The comparative analysis was carried out between OPG, TR and CBCT group. Finding of Mean and standard deviation in OPG, TR and CBCT are illustrated in Table 2

and 3. Correlation between the observed radiographic findings were analysed with ANOVA using statistica 6.0 for windows software. Statistical analysis revealed significant differences between OPG, TR and CBCT.

### RESULTS

The mean  $\pm$  standard deviation of severity of erosion; thickness of roof of glenoid fossa; deformed contour; joint space; flattening; subchondral sclerosis; irregularity of articular surface and eminence in CBCT group was  $1.4 \pm 1.075$ ;  $1.8 \pm 0.422$ ;  $1.2 \pm 1.229$ ;  $0.6 \pm 0.516$ ;  $0.500 \pm 0.527$ ;  $0.6 \pm 0.516$ ;  $0.90 \pm 0.316$  (Table 2).

The study comprised of total number of 10 subjects out of which 8 were female subjects and 2 were male subjects. In our study it was reported that the male and female subjects were included in the ratio of 1:4.

**Table 2: Distribution of Mean and Standard Deviation in OPG, Transcranial and CBCT group.**

	Groups	N	Mean	Std. deviation	P value
<b>Erosion</b>	OPG	10	0.00	0.000	0.000
	Transcranial	10	0.00	0.000	
	CBCT	10	1.40	1.075	
<b>Thickness of glenoid fossa</b>	OPG	10	0.00	0.000	0.000
	Transcranial	10	0.00	0.000	
	CBCT	10	1.8	0.422	
<b>Deformed contour</b>	OPG	10	0.00	0.000	0.001
	Transcranial	10	0.00	0.000	
	CBCT	10	1.20	1.229	
<b>Joint space</b>	OPG	10	0.10	0.316	0.011
	Transcranial	10	0.10	0.316	
	CBCT	10	0.6	0.516	
<b>Subchondral sclerosis</b>	OPG	10	0.10	0.316	0.011
	Transcranial	10	0.10	0.316	
	CBCT	10	0.6	0.516	
<b>Irregularity of articular surface &amp; eminence</b>	OPG	10	0.00	0.00	0.00
	Transcranial	10	0.00	0.00	
	CBCT	10	0.90	0.316	
<b>Flattening</b>	OPG	10	0.1000	0.316	0.050
	Transcranial	10	0.1000	0.316	
	CBCT	10	0.5000	0.527	

It was found that the most common radiographic findings in CBCT were flattening (100%), subchondral sclerosis (50%), erosion (80%), irregularity of articular surface (90%), deformed contour (60%), increased thickness of roof of glenoid fossa (80%), and reduced joint space (60%). Conventional radiographic technique i.e. Digital OPG and Transcranial showed only flattening (70%), reduced joint space (10%), Sclerosis (10%). Deformed contour, erosion, irregularity of articular surface and eminence were not seen in any of the subjects (Figure 4).

The severity of erosion in our study was observed in total of 8 subjects, out of which 6 were female subjects and 2 were male subjects. Degree of erosion was 60% in female subjects and 20% in male subjects. In our study slight

erosion was seen in 40% of the subjects, moderate erosion was observed in 20% of the subjects and extensive erosion was observed in 20% of the subjects. On comparing 3 groups it was observed that severity of erosion was 100% absent in OPG and TR whereas in CBCT 20% of cases showed moderate erosion, 20% showed extensive erosion, 40% showed slight erosion and 20% showed absence of erosion (Table 3 and Figure 5).

Irregularity of articular surface and eminence was absent in 100% of the cases in OPG and TR while in CBCT 90% of cases showed presence of irregularity of articular eminence and 10% cases showed absence of irregularity of articular surface (Table 3 and Figure 6).

Thickness of roof of glenoid fossa appeared to be normal in 20% of the cases and increased in 80% of the cases. Measurement of thickness of roof of glenoid fossa was not applicable in OPG and transcranial, hence in 100% of the cases thickness of roof of glenoid fossa was not measured (Table 3 and Figure 7).

Subchondral sclerosis was observed in 10% of cases in OPG and TR while in CBCT 50% of the cases showed

presence of subchondral sclerosis and 50% showed absence of erosion (Table 3).

Joint space appeared to be normal in 90% of the cases in OPG and TR while in CBCT 40% of the cases appeared to have normal joint space, where as 60% of the cases showed reduced joint space. No bony contact was observed in any of the cases (Table 3).

**Table 3: Average percentage (%) difference between OPG, transcranial and CBCT for the presence of erosion, thickness of roof of glenoid fossa, deformed contour, joint space, subchondral sclerosis, flattening, irregularity of articular surface and eminence**

		Groups		
		OPG (%)	Transcranial (%)	CBCT (%)
<b>Erosion (Grading according to severity of erosion criteria)</b>	Absent	100	100	20
	Slight	0	0	40
	Moderate	0	0	20
	Extensive	0	0	20
<b>Thickness of roof of glenoid fossa</b>	Not applicable	100.0	100.0	0.0
	Normal	0.0	0.0	20.0
	Increased	0.0	0.0	80.0
<b>Irregularity of articular surface and eminence</b>	Absent	100.0	100.0	10.0
	Present	0.0	0.0	90.0
<b>Subchondral sclerosis</b>	Absent	90.0	90.0	50.0
	Present	10.0	10.0	50.0
<b>Joint space</b>	Normal	90.0	90.0	40.0
	Reduced	10.0	10.0	60.0
<b>Deformed contour</b>	Not present	100.0	100.0	40.0
	Anterior beak	0.0	0.0	20.0
	Anterior and posterior beak	0.0	0.0	20.0
	Beak at medial pole	0.0	0.0	20.0
<b>Flattening</b>	Absent	30.0	30.0	0.0
	Present	70.0	70.0	100.0

**Table 4: Distribution of osseous changes in TMJ.**

Distribution of Osseous changes in TMJ	OPG (Right side)	OPG (Left side)	OPG (Total no. of patients)	TR (Right side)	TR (Left side)	TR (Total no. of patients)	CBCT (Right side)	CBCT (Left Side)	CBCT (Total no. of patients)
<b>Erosion</b>	0	0	0	0	0	0	4	7	8
<b>Type F</b>	4	5	7	4	5	7	9	8	10
<b>Reduced joint space</b>	1	1	1	1	1	1	4	2	6
<b>Subchondral sclerosis</b>	1	1	1	1	1	1	3	3	6
<b>Irregularity of articular surface and eminence</b>	0	0	0	0	0	0	7	8	9
<b>Thickness of roof of glenoid fossa</b>	0	0	0	0	0	0	6	7	6
<b>Type D</b>	0	0	0	0	0	0	5	4	6

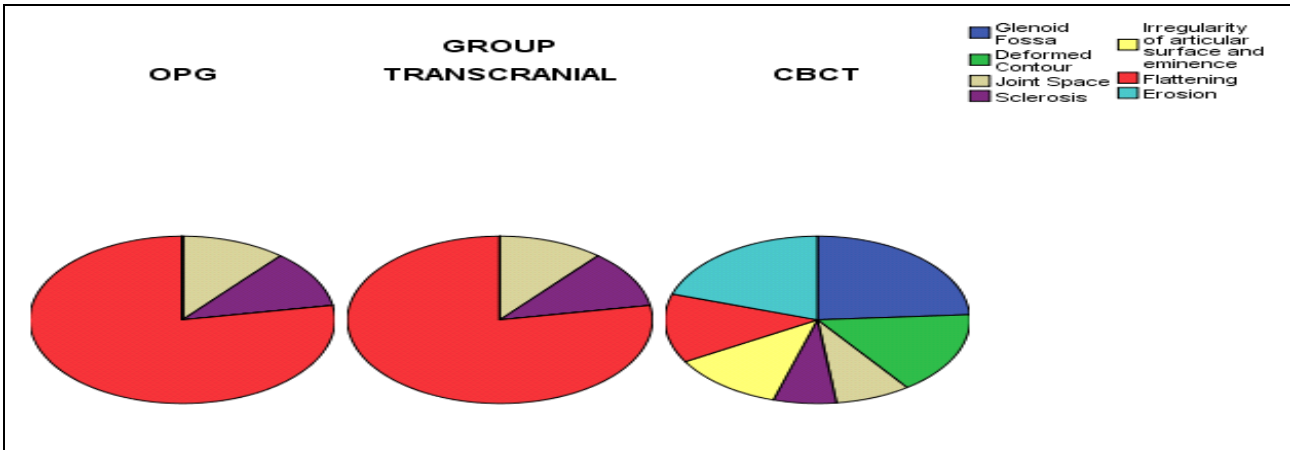


Figure 4: Distribution of osseous changes in OPG, transcranial and CBCT group.

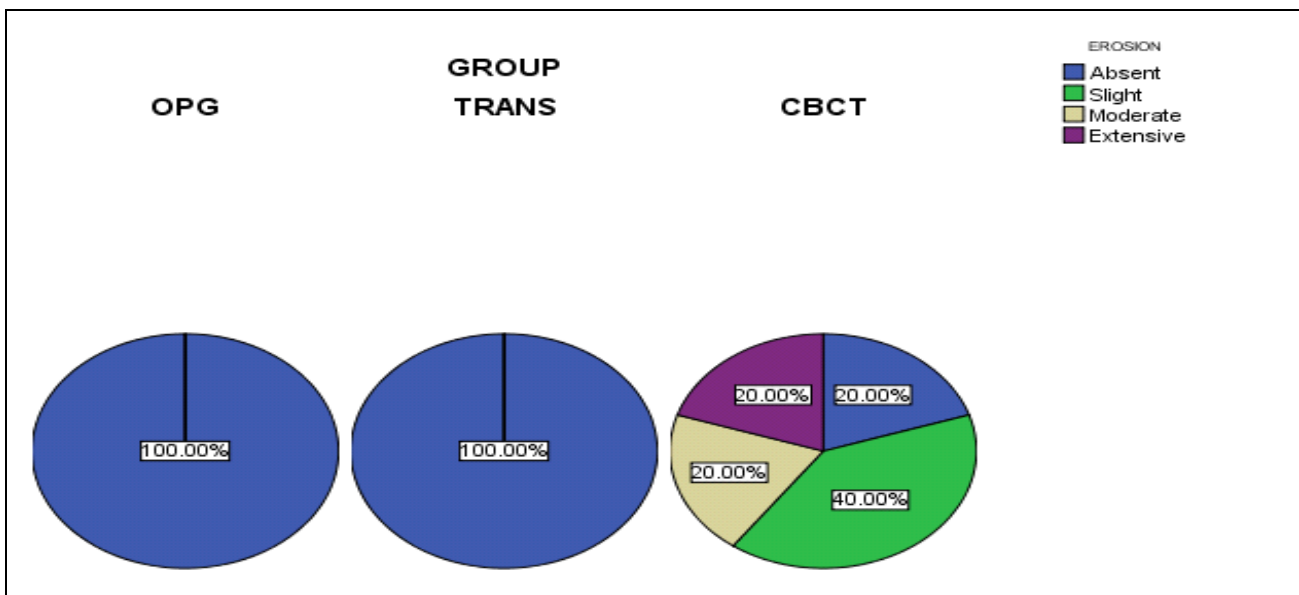


Figure 5: Severity of erosion in OPG, transcranial and CBCT group.

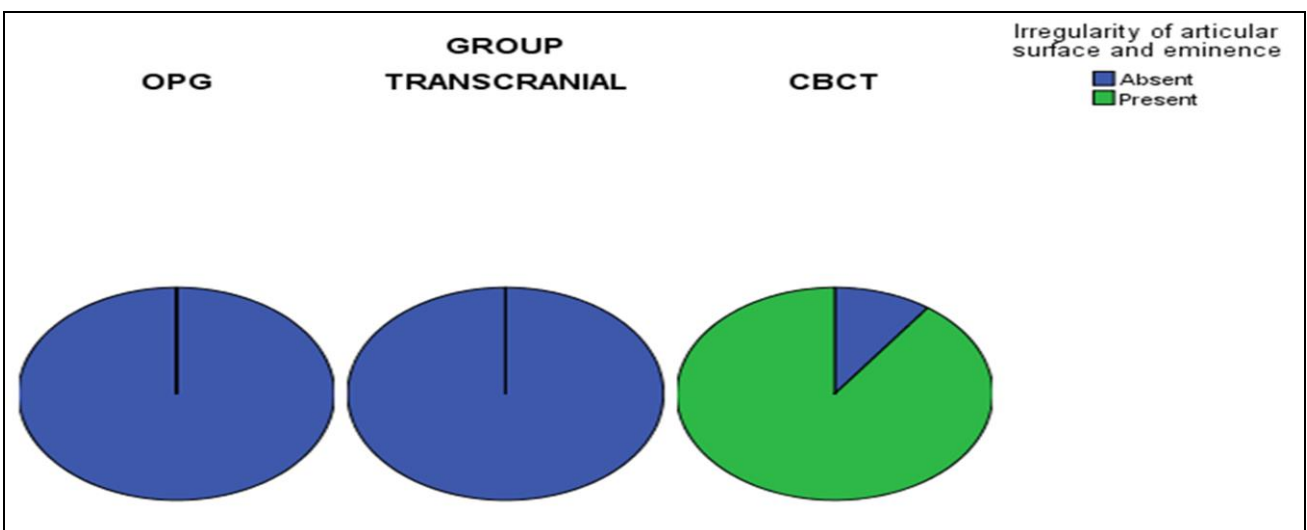


Figure 6: Evaluation of irregularity of articular surface and eminence in OPG, TR and CBCT group.

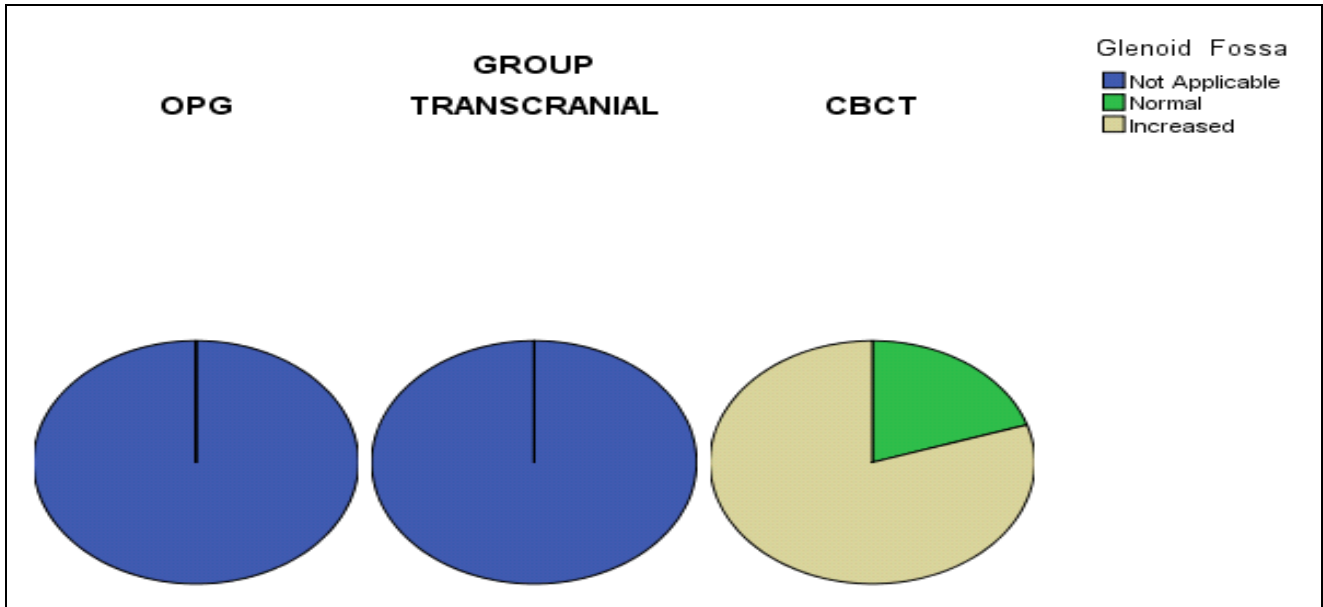


Figure 7: Measurement of thickness of roof of glenoid fossa in OPG, transcranial and CBCT group.

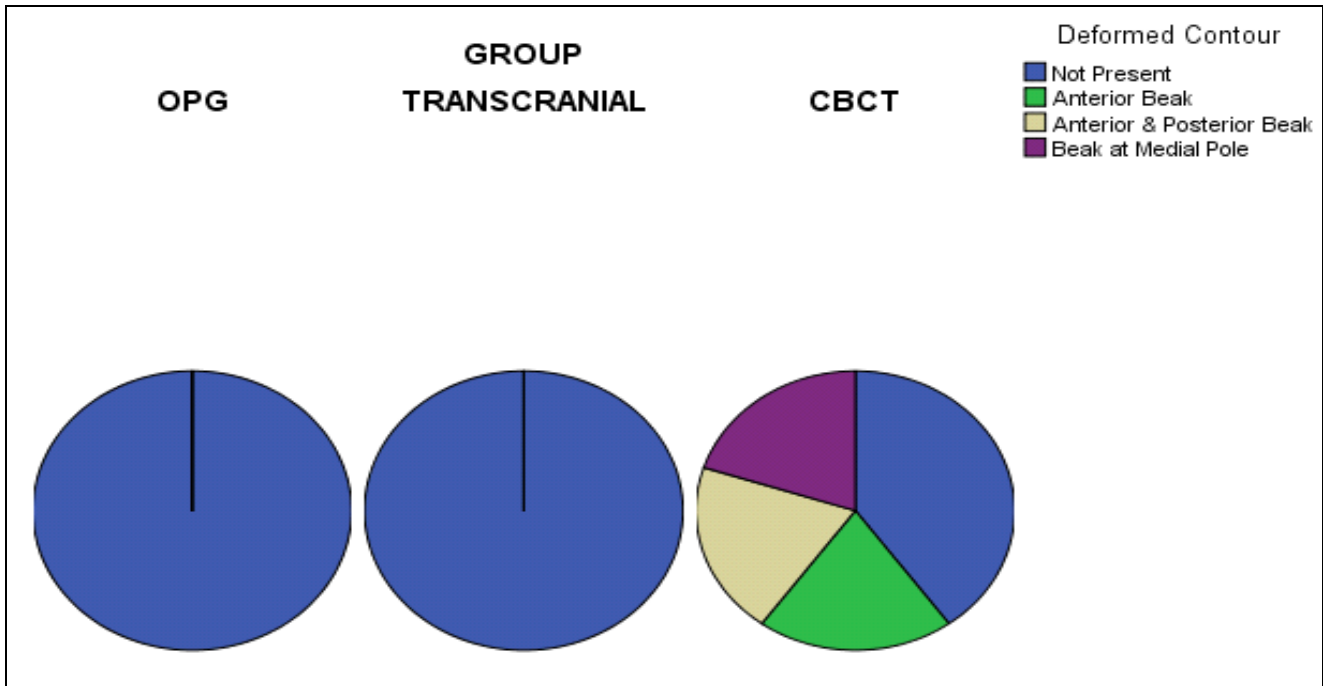


Figure 8: Evaluation of deformed contour in OPG, transcranial and CBCT group.

Deformed contour appeared to be absent in 100% of the cases in OPG and TR, while in CBCT 40% of the cases showed absence of deformed contour, 20% of cases appeared to have anterior beak, 20% of the cases showed anterior along with the posterior beak and 20% of the cases showed beak present at the medial pole of condyle (Table 3 and Figure 8).

**DISCUSSION**

The Present study was conducted to evaluate the usefulness and efficacy of CBCT in 10 subjects of

TMDs. The TMJ is a rather difficult area to investigate radiographically. A number of imaging techniques have been developed over the years; however, there is still no single technique that provides accurate imaging of all the components of the complex anatomy of the joint. Modern imaging modalities, such as MRI and CT, are now being used more frequently for radiographic examination of the TMJ.<sup>5,14</sup>

Radiographic examination of the TMJ is a decisive factor for the differential and final diagnosis of several pathological conditions of the TMJ.<sup>15</sup> Various

conventional radiographic projections like panoramic, transcranial and transpharyngeal are limited for the type of evaluation like erosion of cortical boundary, sclerosis, osteophyte formation and reduction of joint biological space.<sup>16</sup>

In our study it was reported that the male and female subjects were included in the ratio of 1:4 which correlates with the other studies done by Riden, Juniper, Linde, Isacson and Jonsson. dos Anjos Pontual et al did a study in 2012 which showed that high prevalence of degenerative bone alteration in TMJs is more frequent in women.<sup>17</sup>

Alexiou et al did a study, which showed that slight erosion was found in 25% of the joints, moderate erosion was present in 19% of the joints and severe erosion was seen in 15% of the joints which is similar to the results observed in our study.<sup>5</sup> Pountal et al (2012) documented that flattening and osteophytes are the most prevalent types of degenerative bony changes and also stated that erosion is the initial stage of degenerative changes, indicating that TMJ is unstable and changes in bone surface will occur.<sup>17</sup>

Honda et al in 2004 did a study similar to ours but on cadavers specimen using 3D X image tool to measure thickness of roof of glenoid fossa and observed that bone thickness measurement by CBCT method was effective.<sup>13</sup>

Gynther et al in 1998 stated that sclerosis develops secondarily in more progressive forms of the disease.<sup>18</sup> But in our study we found 50% of the sclerosis in female and 10% in male subjects in young subjects, which is indicative for progression of disease in younger age group.

Alxeiou et al in 2009 observed reduced joint space in only 50% of the subjects.<sup>5</sup> Bony contact between condylar head and mandibular fossa was observed in 25% of the joints. According to the available literature a few studies were reported in the evaluation of joint space through CBCT.

Flattening in our study was observed in 10 subjects, out of which 8 were female subjects and 2 were male subjects. Alxeiou et al in 2009 stated that flattening and erosion are the most common radiographic findings of the condyle. Dos Anjos Pontual et al in 2012 observed flattening in 59% of the cases. He stated that flattening and osteophytes are the most prevalent of degenerative bony changes. He also documented that high prevalence of flattening may be explained by the possibility that this bone change represents an adaptive alteration, the first change of progressive disease secondary to internal derangement.

Deformed contour and irregularity of articular surface in our study was observed in total of 6 and 9 subjects. Campos et al in 2008 did a similar study observed that

91% of the cases showed changes in condyle and only 1% of the cases showed changes in articular surface.<sup>19</sup> He documented that degenerative changes were significantly more frequent in the condyle than in articular eminence. But in our study more changes were seen in articular surface and eminence.

Campos et al in 2008 documented that degenerative changes were significantly more frequent in the condyle than in articular eminence. But in our study more changes were seen in articular surface and eminence.<sup>19</sup>

Hintze et al in 2007 did a similar study to ours by comparing the diagnostic accuracy of CBCT images with conventional tomographic images for the detection of morphological TMJ changes. He observed no significant differences in diagnostic accuracy for detection of bone changes in condyle (i.e. flattening, defects and osteophytes) and in the articular tubercle (i.e. flattening and defects) between CBCT images and conventional tomograms.<sup>20</sup>

It was observed that higher occurrence of osteoarthritic lesion of condyle was sclerosis followed by bony proliferation and ill-defined cortical bone. As far as the difference between male and female subject was concerned it was observed that maximum number of patients with TMDs was female subjects. Most of the bony changes in the condyle were seen in female subjects as compared to male subjects.

Using CBCT as imaging technique in our study to detect osseous changes in the TMJ was proved to be effective as compared to the conventional radiographic techniques. An attempt was made to compare efficacy of CBCT with conventional radiographic technique in detecting changes in TMJ disorders and observed that CBCT is more effective in detecting any bony changes as compared to OPG and TR. Further, more studies need to be carried out to determine the effectiveness of CBCT in TMJ Disorders among either sex of the population and in larger sample of subjects. Further studies are also required with large sample to compare the efficacy of CBCT with other conventional radiographic techniques.

*Funding: No funding sources*

*Conflict of interest: None declared*

*Ethical approval: The study was approved by the institutional ethics committee*

## REFERENCES

1. Dworkin SF. Epidemiology of signs & symptoms in TMDS: clinical signs in case & control. *JADA.* 1990;120:273-81.
2. Tomislav B, Miljenko M, Josipa K, Mirko L. A quantitative analysis of splint therapy of displaced temporomandibular joint disc. *Ann Anat.* 2009;191(3):280-7.



3. Buescher JJ. TMJ Disorders. *Am Fam Physician.* 2007;76(10):1477-82.
4. Friction JR, Chung SC. Contributing factors: A key to chronic pain. In: Friction JR, Kroening RJ, Hathaway KM, editors. *TMJ and Craniofacial Pain: Diagnosis and Management.* MO: Ishiyaku EuroAmerica: St Louis; 1988.
5. Alexiou KE. Evaluation of the severity of temporomandibular joint osteoarthritic changes related to age using cone beam computed tomography. *Dentomaxillofacial Radiol.* 2009;38:141-7.
6. White S, Pharoah M. *Textbook of Oral Radiology. Principles & Interpretations.* 6th Edition. Elsevier; 2008.
7. Jin JY. Combining scatter reduction and correction to improve image quality in cone beam computed tomography. *Med Phys.* 2010;37:5634.
8. Schulze D. Radiation exposure during midfacial imaging using 4 and 16 slice computed tomography, cone beam computed tomography systems and conventional radiography. *Dentomaxillofac Radiol.* 2004;33:83-6.
9. Honda K. Relationship between patient characteristics, mandibular head morphology and thickness of the roof of the glenoid fossa in symptomatic temporomandibular joints. *Dentomaxillofac Radiol.* 2007;36(5):277-81.
10. Scarfe WC, Farman AG. Cone Beam Computed Tomography: A paradigm shift for clinical dentistry. *J Australian Dental Pract.* 2007:92-100.
11. Martinez-Blanco M. Osteoarthrosis of the temporomandibular joint. A clinical and radiological study of 16 patients. *Med Oral.* 2004;9:106-15.
12. Tyndall DA. Cone-beam CT diagnostic applications: Caries, periodontal bone assessment, and endodontic applications. *Dent Clin North Am.* 2008;52(4):825-41.
13. Honda K. Evaluation of the usefulness of the limited cone-beam CT (3DX) in the assessment of the thickness of the roof of the glenoid fossa of the temporomandibular joint. *Dentomaxillofac Radiol.* 2004;33:391-5.
14. Benson BW. Disorders of the temporomandibular joint. *Dent Clin North Am.* 1994;38:167-85.
15. Tsiklakis K. Radiographic examination of the temporomandibular joint using cone beam computed tomography. *Dentomaxillofac Radiol.* 2004;33:196-201.
16. Meng JH. Diagnostic evaluation of the temporomandibular joint osteoarthritis using cone beam computed tomography compared with conventional radiographic technology. *Beijing Da Xue Xue Bao.* 2007;39(1):26-9.
17. dos Anjos Pontual ML, Freire JSL, Barbosa JMN, Frazão MAG, dos Anjos Pontual A, Fonseca da Silveira MM. Evaluation of bone changes in the TMJ using CBCT. *DMFR.* 2012;41:24-9.
18. Gynther GW. Comparison of arthroscopy and radiography in patients with temporomandibular joint symptoms and generalized arthritis. *Dentomaxillofac Radiol.* 1998;27:107-12.
19. Campos MI. Analysis of Magnetic resonance imaging characteristics and pain in the TMJ with and without degenerative changes of condyle. *Int J Oral Maxillofac Surg.* 2008;37:529-34.
20. Hintze H. Cone beam CT and conventional tomography for the detection of morphological temporomandibular joint changes. *Dentomaxillofac Radiol.* 2007;36:192-7.
21. Dworkin SF, LeResche L, DeRouen T. Assessing clinical signs of temporomandibular disorders: Realibility of clinical examiners. *J Prosthetic Dentistry.* 1990;63(9):574-9.

**Cite this article as:** Kohli S, Sharma RK, Goel A, Sunil MK. Evaluation of temporomandibular joint disorders using cone beam computed tomography. *Int J Res Orthop* 2017;3:698-706.