

Original Research Article

A prospective comparative study of mini-open versus arthroscopic repair of supraspinatus tear

Pavan Kumar Chebbi, Manik Rana*, Muthu Kishore M.

Department of Orthopaedics, Sanjay Gandhi Institute of Trauma and Orthopaedics, Bengaluru, Karnataka, India

Received: 22 March 2020

Revised: 22 April 2020

Accepted: 24 April 2020

*Correspondence:

Dr. Manik Rana,

E-mail: manikrana08@gmail.com

Copyright: © the author(s), publisher and licensee Medip Academy. This is an open-access article distributed under the terms of the Creative Commons Attribution Non-Commercial License, which permits unrestricted non-commercial use, distribution, and reproduction in any medium, provided the original work is properly cited.

ABSTRACT

Background: Supraspinatus tear is very common and more frequent among older individuals. Before the arthroscopy came into high demand, the open repair of supraspinatus tear was the preferred method of surgery. Recently, the mini-open technique of repair has also gained popularity because of certain factors like better repair strength, requires less expertise and facilitates early active mobilization. Still, the gold standard modality of repair is yet to be determined as both modalities are associated with good clinical outcomes and both have their pros and cons. We decided to compare functional and clinical outcomes of arthroscopic and mini-open repair.

Methods: This was a randomised study with 32 patients in each group, aged between 18 and 60 years and all patients were cases of traumatic tear of Supraspinatus tendon. From January 2016 to March 2018, alternate patients were selected for mini-open and arthroscopic repair who fulfilled our criteria.

Results: Follow up was done after 12 months postoperatively and the results were evaluated using University of California Los Angeles (UCLA) shoulder score. None left the study. In arthroscopic group, out of 32 patients, 28 got excellent or good result whereas in mini open out of 32 patients 27 achieved excellent or good outcome.

Conclusions: Arthroscopic method provides better visualization of shoulder anatomy whereas Mini-open method has better repair strength and is affordable. The necessity of an arthroscopy set up might not be required for supraspinatus repair as both the modalities show similar functional and clinical outcomes, reducing the economic burden on the patients.

Keywords: Supraspinatus repair, Arthroscopic, Mini open, UCLA score

INTRODUCTION

Supraspinatus is a part of shoulder's rotator cuff. It takes origin from supraspinatus fossa of scapula and inserts into the superior facet of greater tuberosity of humerus. The supraspinatus muscles functions as an initiator of shoulder abduction (first 0-15 degrees). Among all the rotator cuff tendon injuries, supraspinatus tear is very common and it is most common in older individuals.^{1,2} As the tendon undergoes several degenerative changes in many metabolic diseases, its tear is very common after even a trivial fall over the shoulder.³ Rotator cuff repair was first

described by Codman over a century ago.⁴ Before the arthroscopy came into high demand, the open repair of supraspinatus tear was the preferred method of surgery.⁵ But as the researchers found more and more benefits of arthroscopy like better intraarticular visualization and less infection rate, the arthroscopic supraspinatus reconstruction became the surgery of choice.⁶ From past few years, the mini-open technique of repair has also gained popularity because of certain factors like better repair strength, requires less expertise and facilitates early active mobilization.⁷ Still, the gold standard modality of repair is yet to be determined as both modalities are associated with

good clinical outcomes and both have their pros and cons.⁸⁻¹⁰ There are many studies comparing the functional and clinical outcomes of arthroscopic and mini-open repair.^{11,12} Many studies have shown that mini-open requires less tissue dissection and decreased chances of deltoid muscle detachment.¹²⁻¹⁷ On the other hands in arthroscopic method, there is decreased post-operative pain, shorter hospital stay and faster rehabilitation.^{18,19} Also, many studies have data to prove that there is no significant differences between the two modalities.^{18,20} In the trauma institute there is a facility of performing both types of surgeries, but as most of the patients visiting the hospital belong to below poverty line group and cannot afford arthroscopic surgery and having some evidence that mini open repair can be comparable to arthroscopic repair, hence the current study was done to compare both the methods.

METHODS

This was a randomised study done on patients undergoing supraspinatus repair using arthroscopic and mini-open technique at Sanjay Gandhi Institute of Trauma and Orthopaedics, Bangalore which is also a tertiary teaching hospital after taking approval from the institutional ethical committee. Patients were selected on the basis of history, clinical examination and MRI showing full thickness supraspinatus tear. The inclusion criteria were patients with age between 18 and 60 years and all patients were cases of traumatic tear of supraspinatus tendon. Exclusion criteria were diabetic patients, previous history of any fractures around shoulder joint, any associated injury except long head of biceps and history of any intraarticular injections. From January 2016 to March 2018, 64 patients fulfilling the inclusion criteria were enrolled in the study. Alternate patients were selected for mini-open and arthroscopic repair. An informed consent was taken from all the patients before their participation in the study. So, 32 patients underwent mini-open repair and 32 underwent arthroscopic repair.

Two senior surgeons experienced in both arthroscopic and mini-open technique performed the surgeries. For the arthroscopic repair, the arthroscope was placed in the subacromial space through a standard posterior portal. Lateral and posterolateral working portals were subsequently established. The tear was adequately mobilized and repaired by attaching the supraspinatus to the prepared greater tuberosity using either the single-row or the double-row repair technique with a suture anchor. The number of anchors and sutures used depended on the tear size and pattern, which was re-evaluated during the surgeries. For the mini-open group, the approach was initiated with a 5 cm lateral incision starting at the anterior border of the acromion. The fibres of the deltoid muscle were split by blunt dissection, and maximal visualization was established using a soft tissue retractor. Care was taken not to damage the axillary nerve running close to the distal edge of the incision and to minimize detachment of deltoid muscle fibres from the lateral part of the acromion.

Partial bursectomy was performed using dissection scissors. The rest of the procedure was basically the same for both techniques.

For post-operative pain management, intravenous acetaminophen and a cyclooxygenase-2 selective inhibitor was administered till postoperative day 3. From day 3 to day 8 oral tablet containing combination of acetaminophen 325 mg and tramadol 37.5 mg was given. For additional pain control in some patient intramuscular diclofenac was administered if needed.

This rehabilitation protocol was same for both the groups and all the patients followed it satisfactorily. Patients were started with pendulum and passive motion exercises until day 5. After this passive range of motion exercises were started. Active range of motion exercises were started at 6 weeks postoperatively, muscle strengthening exercises were started at 3 months. Follow up was done after 12 months postoperatively and the results were evaluated using University of California Los Angeles (UCLA) shoulder score.^{21,22}

Statistical analysis was performed using statistical package of social science (SSPS) version 20 software.

RESULTS

Among the 64 patients in the study, 39 were <40 years of age and 25 were >40 years of age. Also, there were total 34 males and 30 females. Demographics of both study groups are mentioned below (Figure 1 and 2).

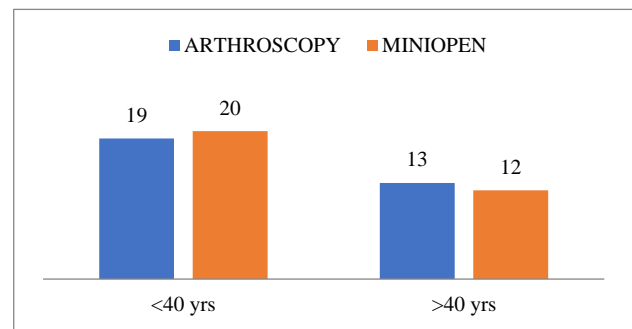


Figure 1: Age distribution in both study groups.

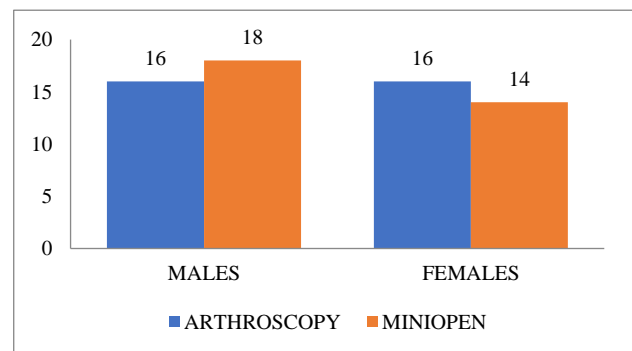


Figure 2: Sex distribution in both study groups.

At the end of 12 months follow up, the results were analysed using UCLA shoulder score as it is simple and there are least chances of inter observer errors. For arthroscopic repair group, total 32 patients were there. No patient left the follow up in between. The results according to the UCLA shoulder score were: 13 patients got excellent result, 15 patients got good result and only 4 patients got fair result. None of the study patients got poor result in this group. So, out of 32 patients ,28 got excellent or good result i.e. 87.5% of the patients in this group (Table 1 and 2).

None of the patient left the follow up in mini open group which also had 32 patients. At the end of 12 months, the result according to UCLA shoulder score were: 11 patients achieved excellent result, 16 patients achieved good result and only 5 patients got fair result. None of the patient in this group also had poor outcome. So, out of 32 patients 27 achieved excellent or good outcome i.e. 84.3% of the patient of this particular group (Table 1 and 2).

Table 1: Final outcome of UCLA score.

Interpretation	Group		Total N (%)	Fisher's exact test
	Arthroscopy N (%)	Mini Open N (%)		P value
Excellent	13 (40.6)	11 (34.4)	24 (37.5)	0.89 (NS)
Fair	4 (12.5)	5 (15.6)	9 (14.1)	
Good	15 (46.9)	16 (50)	31 (48.4)	
Total	32 (100)	32 (100)	64 (100)	

*p<0.05 Statistically significant, p>0.05 Non-significant, NS.

Table 2: UCLA scoring.

Variables	Group	N	Mean	SD	Mean difference	95% confidence interval of the difference		P value (significance)
						Lower	Upper	
Function	A	32	9.13	1.24	0.06	-0.58	0.71	(NS)
	M	32	9.06	1.34				
Pain	A	32	8.75	1.41	0.31	-0.39	1.02	0.38 (NS)
	M	32	8.44	1.41				
Strength of forward flexion	A	32	4.47	0.57	0.28	-0.02	0.59	0.07 (NS)
	M	32	4.19	0.64				
Forward flexion range of motion	A	32	4.56	0.72	0.06	-0.30	0.42	0.73 (NS)
	M	32	4.50	0.72				
Patient satisfaction	A	32	5.00	0	-	-	-	-
	M	32	5.00	0				
Score	A	32	31.44	3.37	0.25	-1.44	1.94	0.78 (NS)
	M	32	31.19	3.38				

A- Arthroscopic repair; M- Mini open repair, *p<0.05- statistically significant, p>0.05- non significant, NS.

DISCUSSION

Arthroscopic supraspinatus repair is a very common modality of definitive management of supraspinatus tear.¹¹ The 2 most important benefits of an arthroscopic repair are small incision and better visualization of the tear.^{8,12} It has become a hugely popular modality for supraspinatus repair and surgeon’s skills and experiences are still improving.^{23,24} Moreover, causes less pain and as the result rehabilitation is quite compliant. On the other hand, mini open repair carries the advantage of open repair without injuring the deltoid to much extent. Mini-open repair gained popularity in past few years. The important benefit in this modality is that the strength of repair is very good because of which early active mobilization can be started. The mini-open technique of rotator cuff repair has been recommended as a transition between fully open and fully

arthroscopic methods of rotator cuff repair.²⁵ Open rotator cuff repair offers the advantage of technical ease and skills being easy to acquire. No special equipment is required, and greater exposure is obtained to allow a clearer visualization of identified pathology.

The present study is based on the outcomes evaluated using UCLA shoulder score which has several parameters like pain, function, range of active forward flexion, strength of forward flexion and patient satisfaction. No other parameters are taken into consideration for the study. These parameters are evaluated and compared between the 2 study groups. According to some researches, patients who underwent arthroscopic repair obtained good results in terms of functional score as compared to mini open group.²⁶⁻²⁸ When pain is taken as one of the parameters, some studies found there is no significant differences

between the 2 groups.^{12-14,17} The results are also similar to the mentioned studies. For arthroscopy and mini open groups, the mean scores for pain at the end of 12 months follow up were 8.75 and 8.44 respectively making the difference statistically non-significant. Function of the affected shoulder is one of the most important criteria to find the outcome of a particular surgery. When this was compared between the 2 study groups arthroscopy group had mean score of 9.13 as compared to 9.06 for mini open group. This difference was also found to be statistically non-significant.

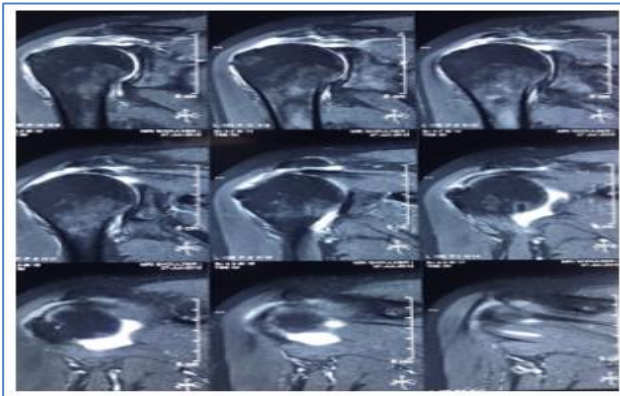


Figure 3: Coronal sections of MRI showing supraspinatus tear.

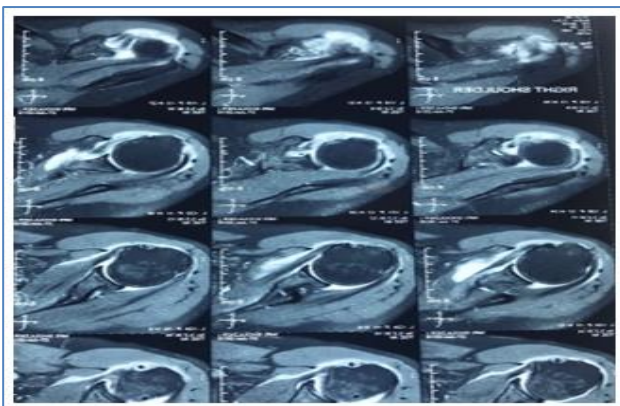


Figure 4: Axial sections of MRI showing supraspinatus tear.

In the UCLA scoring, strength and range of active forward flexion are 2 important parameters for evaluating the outcome. Even when these 2 parameters were compared among the 2 groups, no statistically significant difference was observed. For range of active forward flexion, arthroscopy group had mean score of 4.56 compared to 4.50 of mini open group with p value being 0.73. For strength of forward flexion, the mean scores were 4.47 and 4.19 for arthroscopy group and mini open group respectively with p value of 0.07. All of the patients in the present study were satisfied with their outcomes. Studies suggest arthroscopic repair has very good short as well as long term results.

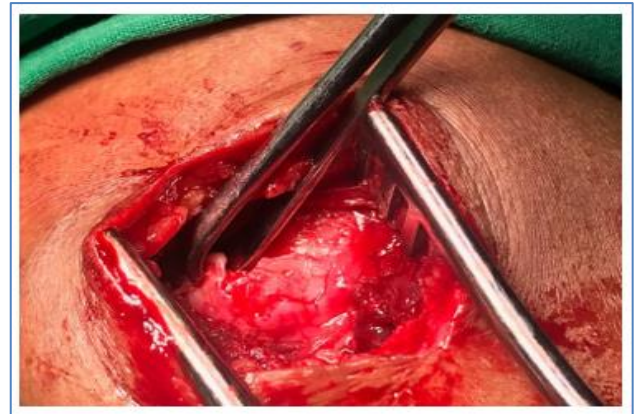


Figure 5: Mini open technique showing the supraspinatus tear.

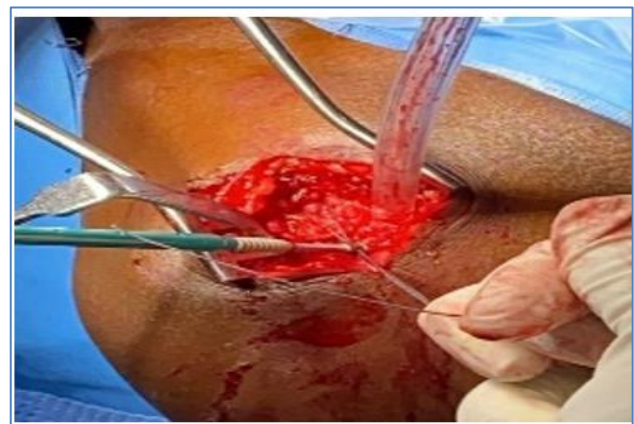

Figure 6: Mini open technique repair of supraspinatus tear with suture anchor.

Over the past 5 years, a number of studies on arthroscopic cuff repair, with generally good results, have been published. They achieved good to excellent results in the UCLA score in 83% to 95% of the cases.^{10,16,19,29-31} In the present study after 12 months of follow-up, 87.5% patients managed to get excellent or good outcomes according to the UCLA score. Therefore, results of the study are comparable to most of the other studies. Added to this, multiple studies demonstrated the efficacy of the mini open technique.^{32,33} In the present study, 84.3% excellent to good results was noticed. Only 3 patients got superficial surgical site infection which were well treated. 1 re-tear which was a suture anchor failure due to osteoporotic bone was observed. It was also repaired successfully. Overall mini open results are comparable to other previous studies. The study found that both the modalities have almost similar long and short term functional and clinical outcomes as that of other study.³⁴

CONCLUSION

The arthroscopic method provides better visualization of the shoulder anatomy which is essential as the academic part in the teaching institute of the present study, whereas

mini-open repair has better repair strength and can be afforded by every class of patients visiting the hospital as most of the patients visiting the hospital from different parts of the country belong to low socio economic strata. Also, it requires lesser instrumentation and is relatively quicker. Even on the basis of functional outcome no technique is superior to one other producing similar result over long term. So, depending on the patient's need the method of choice of repair can be customised. Also, mini-open method can be an essential decision-making tool in the set ups where arthroscopic facilities are not available.

Funding: No funding sources

Conflict of interest: None declared

Ethical approval: The study was approved by the institutional ethics committee

REFERENCES

- Campbell's operative orthopaedics; shoulder and elbow injuries: Rotator cuff tears. 2012.
- Neal L, Millar MB, Wu X, Tantau R, Silverstone E, George AC, et al. *Clin Orthop Relat Res.* 2009;467:966-78.
- Nho SJ, Yadav H, Shindle MK, Macgillivray JD. Rotator cuff degeneration: etiology and pathogenesis. *Am J Sports Med.* 2008;36(5):987-93.
- Codman EA. Complete rupture of the supraspinatus tendon. Operative treatment with report of two successful cases 1911. *J Shoulder Elbow Surg.* 2011;20:347-9.
- Iyengar JJ, Samagh SP, Schairer W, Singh G, Valone FH, Feeley BT. Current trends in rotator cuff repair: Surgical technique, setting and cost. *Arthroscopy.* 2014;30:284-8.
- Baker DK, Perez JL, Watson SL, Gerald MG, Ponce BA. Arthroscopic vs. Open rotator cuff repair: which has a better impact profile. *J Shoulder Elbow Surg.* 2010;26:5.
- Duralde XAR, Greene T. Mini-open rotator cuff repair via an anterosuperior approach. *J Shoulder Elbow Surg.* 2008;9(1):715-21.
- Shinners TJ, Noordsij PG, Orwin JF. Arthroscopically assisted mini-open rotator cuff repair. *Arthroscopy.* 2002;18:21-6.
- Kim SH, Ha KI, Park JH. Arthroscopic versus mini-open salvage pair of the rotator cuff tear: outcome analysis at 2 to 6 years' follow-up. *Arthroscopy.* 2003;19:746-54.
- Burkhart SS, Danaceau SM, Pearce CE. Arthroscopic rotator cuff repair: analysis of results by tear size and by repair technique-margin convergence versus direct tendon-to-bone repair. *Arthroscopy.* 2001;17:905-12.
- Vicenti G, Moretti L, Carrozzo M, Pesce V, Solarino G, Moretti B. Evaluation of long-term postoperative outcomes between mini-open and arthroscopic repair for isolated supraspinatus tears: a retrospective analysis. *Musculoskelet Surg.* 2018;102(1);21-7.
- Youm T, Murray DH, Kubiak EN. Arthroscopic versus mini-open rotator cuff repair: a comparison of clinical outcomes and patient satisfaction. *J Shoulder Elbow Surg.* 2005;14:455-9.
- Sauerbrey AM, Getz CL, Piancastelli M. Arthroscopic versus mini open rotator cuff repair: a comparison of clinical outcome. *Arthroscopy.* 2005;21:1415-20.
- Verma NN, Dunn W, Adler RS. All-arthroscopic versus mini-open rotator cuff repair: a retrospective review with minimum 2 years follow up. *Arthroscopy.* 2006;22:587-94.
- Kang L, Henn RF, Tashjian RZ. Early outcome of arthroscopic rotator cuff repair: a matched comparison with mini-open rotator cuff repair. *Arthroscopy.* 2007;23:573-82.
- Severud EL, Ruotolo C, Abbott DD. All arthroscopic versus mini open rotator cuff repair: a long-term retrospective outcome comparison. *Arthroscopy.* 2003;19:234-8.
- Warner JJ, Tetreault P, Lehtinen J. Arthroscopic versus mini-open rotator cuff repair: a cohort comparison study. *Arthroscopy.* 2005;21:328-32.
- Buess E, Steuber KU, Waibl B. Open versus arthroscopic rotator cuff repair: a comparative view of 96 cases. *Arthroscopy.* 2005;21:597-604.
- Gartsman GM, Brinker MR, Khan M. Early effectiveness of arthroscopic repair for full-thickness tears of the rotator cuff: an outcome analysis. *J Bone Joint Surg Am.* 1998;80:33-40.
- Morse K, Davis AD, Afra R. Arthroscopic versus mini-open rotator cuff repair: a comprehensive review and meta-analysis. *Am J Sports Med.* 2008;36:1824-8.
- Hudak PL, Amadio PC, Bombardier C. Development of an upper extremity outcome measure: the DASH (disabilities of the arm, shoulder and hand). The Upper Extremity Collaborative Group (UECG). *Am J Ind Med.* 1996;29:602-8.
- Chen ZB, Hong GX, Wang FB. Instruction DASH (Disability of Arm Shoulder and Hand). *Chinese J Reparative Reconstructive Surg.* 2004;18:520-1.
- Shan L, Fu D, Chen K. All arthroscopic versus mini-open repair of small to large sized rotator cuff tears: a meta-analysis of clinical outcomes. *PLoS One.* 2014;9:94421.
- Shen C, Tang ZH, Hu JZ. Does immobilization after arthroscopic rotator cuff repair increase tendon healing: a systematic review and meta-analysis. *Arch Orthop Trauma Surg.* 2014;134:1279-85.
- Yamaguchi K, Levine WN, Marra G. Transitioning to arthroscopic rotator cuff repair: the pros and cons. *Instr Course Lect.* 2003;52:81-92.
- Baker CL, Liu SH. Comparison of open and arthroscopically assisted rotator cuff repairs. *Am J Sports Med.* 1995;23:99-104.
- Zwaal VDP, Thomassen BJ, Nieuwenhuijse MJ. Clinical outcome in all-arthroscopic versus mini-open rotator cuff repair in small to medium-sized

- tears: a randomized controlled trial in 100 patients with 1-year follow-up. *Arthroscopy.* 2013;29:266-73.
28. Cho CH, Song KS, Jung GH. Early postoperative outcomes between arthroscopic and mini-open repair for rotator cuff tears. *Orthopedics.* 2012;35:1347-52.
 29. Tauro JC. Arthroscopic rotator cuff repair: Analysis of technique and results at 2 and 3 years follow-up. *Arthroscopy.* 1998;14:45-51.
 30. Wilson F, Hinov V, Adams G. Arthroscopic repair of full thickness tears of the rotator cuff: 2 to 14 years follow-up. *Arthroscopy.* 2002;18:136-144.
 31. Murray TS, Lajtai G, Mileski RM, Snyder SJ. Arthroscopic repair of medium to large full-thickness rotator cuff tears: Outcome at 2 to 6 years follow-up. *J Shoulder Elbow Surg.* 2002;11:19-24.
 32. Bigliani L, Cordasco F, McIlveen S. Operative treatment of massive rotator cuff tears: long-term results. *J Shoulder Elbow Surg.* 1992;1:120-30.
 33. Cofield RH, Parvizi J, Hoffmeyer PJ, Lanzer WL. Surgical repair of chronic rotator cuff tears. *J Bone Joint Surg Am.* 2001;83:71-7.
 34. Verma NN, Dunn WR, Altchek DW. All arthroscopic versus mini-open rotator cuff repair: a retrospective review with minimum 2 years follow-up. *PLoS One.* 2014;9(4):94421.

Cite this article as: Chebbi PK, Rana M, Kishore MM. A prospective comparative study of mini-open versus arthroscopic repair of supraspinatus tear. *Int J Res Orthop* 2020;6:777-82.