

Original Research Article

Treatment of stable and unstable intertrochanteric fractures using proximal femoral nail and their functional assessment using modified Harris hip score

Lakshya P. Rathore*, Lokesh Gupta, Sanjay Thakur, Sandeep Vaidya,
Devender Sharma, Anurag Sharma

Department of Orthopaedics, SLBS GMCH, Mandi, Himachal Pradesh, India

Received: 11 October 2018

Revised: 20 November 2018

Accepted: 23 November 2018

*Correspondence:

Dr. Lakshya P. Rathore,

E-mail: dr.lakshya.rathore@gmail.com

Copyright: © the author(s), publisher and licensee Medip Academy. This is an open-access article distributed under the terms of the Creative Commons Attribution Non-Commercial License, which permits unrestricted non-commercial use, distribution, and reproduction in any medium, provided the original work is properly cited.

ABSTRACT

Background: Intertrochanteric fracture is common injury and is found in both elderly and the young. Proximal femoral nail (PFN) has been in widespread use for the same in the recent past. There are advocates both for and against this implant. The aim was to study the results of PFN in the treatment of intertrochanteric fractures and their functional evaluation using the modified Harris hip score.

Methods: A prospective study done on 104 patients operated for intertrochanteric fractures with PFN. Patients were followed up at 6 weekly intervals and evaluated at each visit using the modified Harris hip score (HHS).

Results: The study consisted of 104 patients aged from 36 to 96 years with average age of 67.8 years. Most patients belonged to 60-80 years category. Malunion was observed in three patients (2.8%) and non union was not seen in any patient. Excellent to good results were seen in 73% patients 18% patients had a fair outcome, 7.7% had poor and 2% patients had very poor outcome.

Conclusions: PFN is a good implant for intertrochanteric fracture treatment that demands a sound technique and a good reduction prior to insertion. The assessment of results using HHS has been too similar to those obtained using Kyle's criteria in the previous studies, proving its role in the same.

Keywords: Intertrochanteric fractures, Proximal femoral nail, Harris hip score

INTRODUCTION

Fractures of the intertrochanteric region are common in the elderly.¹ Along with the high cost of surgery, they are the most frequently operated fracture type, and have the highest postoperative fatality rate of surgically treated fractures. Interestingly there has been no significant improvement in mortality or functional recovery over the past 50 years of surgical treatment. Although predominantly associated with low-energy falls in the setting of osteoporosis in older age patients, high-energy trauma in young patients can result in similar patterns of fracture.²

The conservative treatment has high complication rate which result from prolonged immobilisation like pneumonia and thromboembolism. Also malunion, varus deformity and limb shortening are common along with bed sores.³ The primary goal of fracture treatment is to return the patient to his/her prefracture level of function while mobilising the elderly patient as soon as possible. Many different surgical procedures and implants have been described for fixation of intertrochanteric fractures like plate and screw constructs, either nail or screws for the head fixation, nail constructs with either nail or screws, external fixation, and arthroplasty.⁴ Previously the use of DHS (dynamic hip screw) and DCS (dynamic

condylar screw) has been famous in the stable and unstable fracture patterns respectively. But with the advent of PFN (proximal femoral nail) in 1996, there has been an immense shift of preference of implant choice among surgeons towards the latter.⁵ While there are many studies that support PFN as a better implant, there are others that have shown PFN to have a high complication rate.⁶⁻¹¹ In our study, we have followed patients of intertrochanteric fractures who were operated with PFN and scored using Harris hip score.

METHODS

The study consisted of 104 patients who presented to Sri Lal Bahadur Shastri Government Medical College and Hospital, Mandi at Ner Chowk, Himachal Pradesh, India in the last 3 years and had suffered from intertrochanteric fractures of which 64 were retrospective and 40 prospective with minimum one year of follow up. The study took place from August 2016 to August 2017. Only the cases operated with PFN were selected. Pathological and open fractures were excluded from the study. After clinical diagnosis and radiological confirmation, patient was evaluated as a whole since most of the patients were elderly. Pre-anaesthetic assessment was done on all patients about fitness for surgery and medical consultation was sought for, if required. Patient under anaesthesia was taken on a fracture table and closed reduction of femoral neck fracture was attempted first and open reduction was reserved for those patients in whom acceptable closed reduction was not attainable. The nail used was either standard short PFN with a length of 25cm or a long PFN with varying size according to the patient. Both types had proximal bend of 6 degrees with proximal diameter of 14mm and distal diameter varied patient to patient from 9-12 mm. neck shaft angle was 135 degrees. Radiographs were taken on the first and wound inspection done on 2nd, 5th and 10th post-operative day. Suture removal was done on 14th day. Side sitting and knee range of motion started on 2nd day. Patients did partial weight bearing walking from the outset and gradually increased based on follow up radiographs for callus and union. Intravenous antibiotics were given for 3 days followed by oral antibiotics till suture removal. Patients were followed up 6 weeks, 3 months, 6 months and 1 year and score according to Harris hip score.

RESULTS

Our study comprised of a total of 104 patients ranging from the ages of 39 to 96 years with an average of 67.8 years. Maximum patients belonged to the age group of 60-80 years (55%) as shown in Figure 1. Males (54%) were more in number as compared to females (46%) (Figure 2). Most of the patients suffered injury due to fall (87.5%) while some due to road traffic accident (12.5%). The most common type of fracture encountered was 31A2 (53%) followed by 31A1 (27%) and 31A3 (20%) as per the AO/OTA classification. Hence unstable fracture pattern was more common (72%). Open

reduction was required in 22% (23 patients) while closed reduction sufficed in 78% (81 patients).

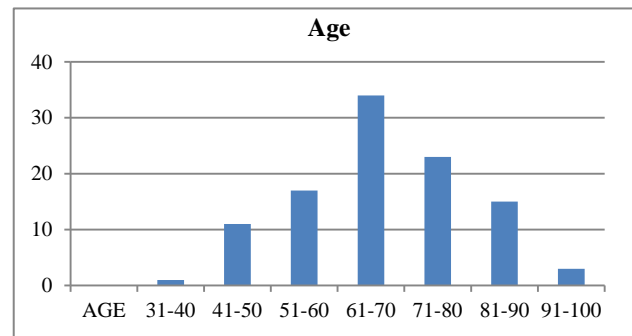


Figure 1: Age distribution.

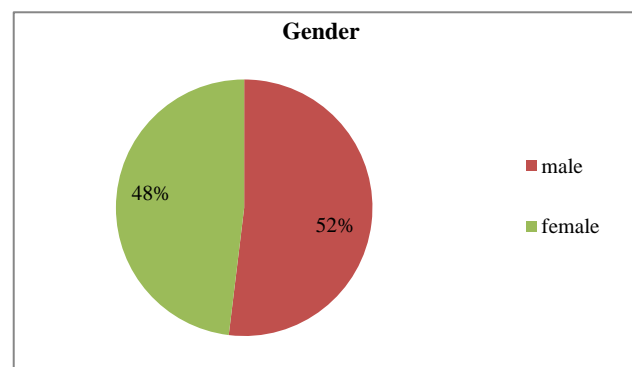


Figure 2: Gender distribution.

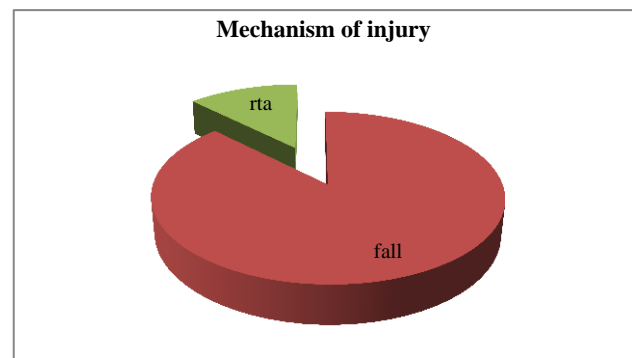


Figure 3: Mechanism of injury.

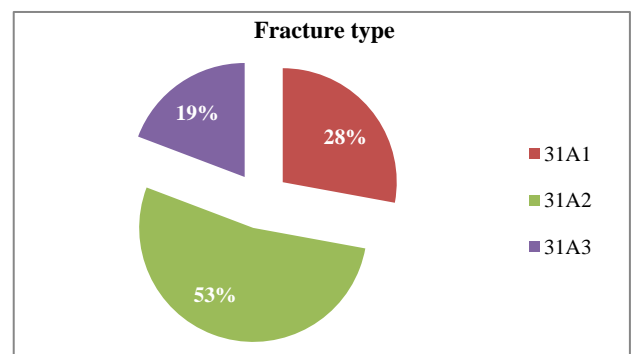


Figure 4: Fracture type (AO/OTA)




Figure 5: Reduction method.

Short PFN of standard length was used in 61.5% patients and varying lengths longer than that used in 28.8% (Figure 6). The most commonly used diameter of PFN was 10 mm (70%). Post-operative neck shaft angle achieved were mostly from 121-130 (59%) while most of them had it above 120 degrees (93%).

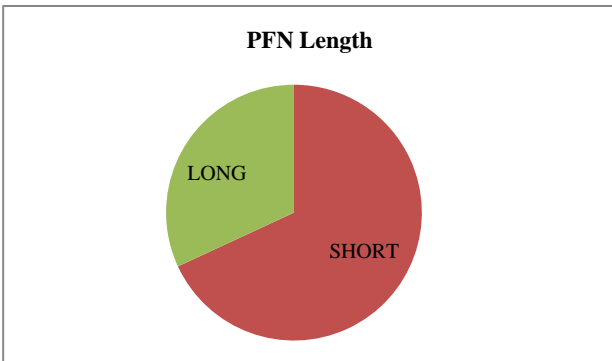


Figure 6: Type of PFN used based on length.

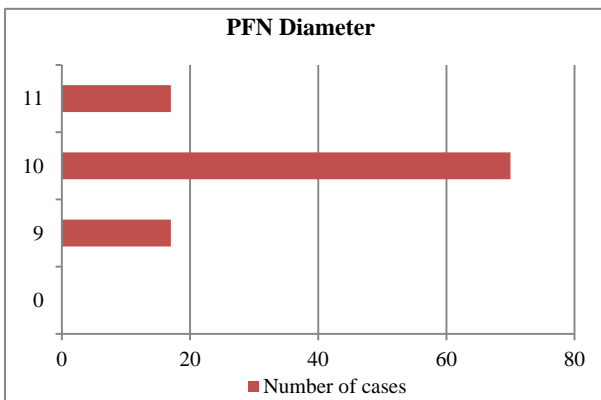


Figure 7: Type of PFN used based on diameter.

The complication rate in our study was 18.3% (19 patients). Varus reduction seen in 3 (2.8%) cases, shortening in two patients (1.9%), z effect in two (1.9%) and infection in eight patients (7.7%), which was deep in only one patient requiring a single debridement. Proximal screw cut out was seen in one patient (0.9%). Malunion was observed in three patients (2.8%) and non union was

not seen in any patient. Patients were evaluated according to HHS at varying intervals throughout the recovery period and final scoring was done at minimum one year follow up. There were maximum patients in excellent to good results range (73% patients). 18% patients had a fair outcome, 7.7% had poor and 2% patients had very poor outcome (Figure 8).

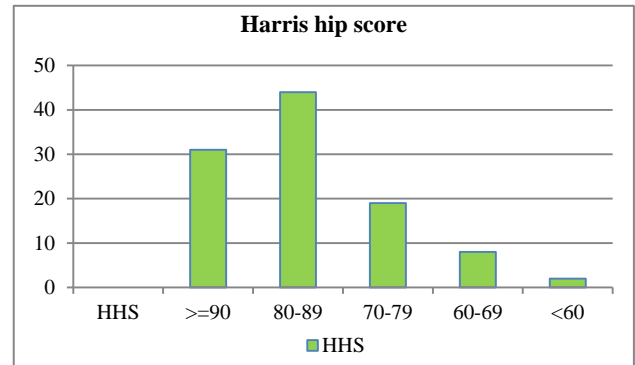


Figure 8: Outcome assessment using Harris hip score.

DISCUSSION

The intertrochanteric fracture has long been recognised as a challenge by orthopaedic surgeons worldwide. The major difficulty lied not so much as in union but in restoration of optimal function in the shortest possible time, hopefully without complications, that too in the elderly patients in whom this fracture is common. The favourable outcome is dependent on type of injury, patient related factors and surgeon related factors. Since long DHS has been considered as a gold standard implant for stable intertrochanteric fractures. Along with more soft tissue dissection, larger exposure, cut out of lag screw, longer surgical time, higher blood loss, varus collapse and medialisation of shaft especially if used in unstable fractures has led to the shift in the paradigm in the treatment of unstable intertrochanteric fractures.¹²

PFN has proved to be very advantageous especially in unstable fracture patterns. Also, biomechanically PFN implants have an advantage to DHS implants since it has a shorter moment arm as compared to DHS. Intramedullary devices have been shown to be biologically stronger and can withstand higher static and several fold higher cyclical loading than dynamic hip screw.¹³ The stem of PFN acts as a check against the medialisation of the shaft of femur. Hence, the medial support is essentially compensated by the implant.¹⁴ In unstable intertrochanteric fractures axial telescoping and rotational stability are of profound importance which cannot be stressed upon enough. In addition to being biomechanically stronger than extra medullary implants, PFN provides both these requirements with minimal dissection¹⁵

In our study, the major cause of injury was fall (87.5%) which comprised primarily of the people from 60-80

years of age and only in 12.5% it was due to road traffic accident. This finding can be attributed to the fact that our state is a hilly area. The incidence was almost comparable among males (54%) and females (46%) which can be due to the fact that females are also involved in work outside the house especially terrace farming in the mountains. In contrast many studies have reported the incidence to be more common in females.^{3,16,17} The most common type of fracture (31A2) however was similar to that in the previous studies.¹⁸

Since there are two proximal screws in the implant under study, we cannot measure accurately the tip apex distance (TAD). However studies have shown positive correlation with femoral neck screw and TAD if kept below 25 mm.¹⁹ The same study by Holt et al also recommends that PFN femoral neck screw should follow the same course as the IMHS (and not be placed somewhat lower as usually recommended) and the anti-rotation screw should not exceed the line between tip of neck screw and tip of IM nail.

The percentage of people with good to excellent functional results came out to be about 90.3%. Although, we have used Modified Harris Hip Score to assess our results, the outcomes have been similar to the previous studies that have used Kyle's criteria for the same.²⁰ Hence it would be safe to say that HHS is an effective tool to measure the outcome of intertrochanteric fractures treated with PFN. There was no case of non union in our study which is in agreement with the 0-3% rate of non union in the literature.²¹⁻²³ As illustrated in various previous studies PFN is associated with many complications such as difficulty in reducing fracture, tough distal locking, especially in long PFN, Z effect and reverse Z effect, splintering of greater trochanter while inserting nail.²⁴⁻²⁶ Altogether, the complication rate is comparable to the study by Gadegone and Salphale and the study by Domingo et al.^{27,28} The complication rate of our study is higher than some studies like that conducted by Pajarinen et al who reported only 6% complication rate.²⁹

The migration of screws, proximal screw superiorly and distal inferiorly and vice versa, as seen in Z and reverse Z effect is attributed mainly to the impaction at the fracture site and osteoporotic bone.³⁰ Also, the cervical screw is advised to be kept at least 10mm shorter than the hip screw in order to prevent the weight loading on the cephalic screw which may lead to the z effect. In this situation the cephalic screw only acts as a derotation screw. Kim et al have reported increased rate of complications in an unstable fracture pattern combined with osteoporosis, like femoral head screw cut out, varus angulation. More than 50% of patients with the above fracture profile were seen to have these complications.³¹ As reported by Schatzker the malunion seen is usually in varus and external rotation, for which a valgus osteotomy is advised for lateralization of shaft to restore the mechanical axis of the femur.³² Varus malunion is a

common cause of trendelenburg lurch and many patients are seen to require walking aid.⁶

Since its first introduction, PFN has undergone many modifications and new versions with a single proximal screw are available. Albeit, Leung in Hong Kong noted the variations in the Asian femur bone as compared from western population and designed Gamma AP (Asia Pacific) nail for Asian population with reduced length, diameter and mediolateral angle.³³

CONCLUSION

The role of PFN in the treatment of intertrochanteric fractures has been speculated in the past also and as the results of this study point out, its is favourable implant to use for the same with low complication rates given the surgeon is using the correct technique which is not hard to master and prior to nail insertion a good reduction has been obtained. The results of functional assessment postoperatively that were obtained using the HHS scale were found to be similar to those reported with Kyle's criteria in previous studies.

Funding: No funding sources

Conflict of interest: None declared

Ethical approval: The study was approved by the institutional ethics committee

REFERENCES

- Gullberg B, Johnell O, Kanis JA. World-wide projections for hip fracture. *Osteoporos Int.* 1997;7(5):407-13.
- Thomas A. Russell. Intertrochanteric Fractures. Rockwood And Green's Fractures In Adults, 7th Edition. Wolters Kluwer Health; 2004: 1597-1599.
- Myderrizi N. Proximal femoral nailing is better choice in treatment of intertrochanteric fracture in elderly people. *Int Surg J.* 2016;3:781-5.
- Koval KJ, Baumgaertner MR, Taksali S. Intertrochanteric Hip Fractures: Intramedullary Hip Screws. *Master Techniques in Orthopaedic Surgery: Fractures*, 2nd Edition, Philadelphia, United States, Lippincott Williams and Wilkins; 2006: 249-250.
- Simmermacher RK, Bosch AM, Van der Werken C. The AO/ASIFproximal femoral nail (PFN): A new device for the treatment of unstable proximal femoral fractures. *Injury.* 1999;30:327-32.
- Kulkarni GS, Limaye R, Kulkarni M, Kulkarni S. Current concept review Intertrochanteric fractures. *Indian J Orthop.* 2006;40:16-23.
- Anjum MP, Hussain FN, Mehboob I. Treatment of intertrochanteric femoral fractures with a proximal femoral nail (PFN): A short follow up. *Nepal Med Coll J.* 2009;11:229-31.
- Lindsey RW, Teal P, Probe RA, Rhodas D, Davenport S, Schander K, et al. Early experience with a gamma nail for petitrochanteric fractures of

- the proximal femur. *J Orthop Trauma.* 1991;71:1649-58.
9. Hardy DC, Descamps PY, Krallis P, Fabeck L, Smets P, Bertens CL, et al. Use of an intramedullary hip-screw compared with a compression hip-screw with a plate for intertrochanteric femoral fractures. A prospective, randomized study of one hundred patients. *J Bone Joint Surg Am.* 1998;80:618-30.
 10. Baumgaertner MR, Curtin SL, Lindskog DM. Intramedullary versus extramedullary fixation for the treatment of intertrochanteric hip fractures. *Clin Orthop Relat Res.* 1998;348:87-94.
 11. Parker MJ, Handoll HH. Gamma and other cephalocondylic intramedullary nails versus extramedullary implants for extracapsular hip fractures in adults. *Cochrane Database Syst Rev.* 2005;16:CD000093.
 12. Murray RC, Frew JF. Trochanteric fractures of the femur; a plea for conservative treatment. *J Bone Joint Surg Br.* 1949;31B:204-19.
 13. Curtis MJ, Jinnah RH, Wilson V, Cunningham BW. Proximal femoral fractures: A biomechanical study to compare intramedullary and extramedullary fixation. *Injury.* 1994;25:99-104.
 14. Pavelka T, Houcek P, Linhart M, Matejka J. Osteosynthesis of hip and femoral shaft fractures using the PFN-long. *Acta Chir Orthop Traumatol Cech.* 2007;74:91-8.
 15. Radford PJ, Needoff M, Webb JK. A prospective randomised comparison of the dynamic hip screw and the gamma locking nail. *J Bone Joint Surg [Br].* 1993;75:789-93.
 16. Endigeri P, Pattanashetty OB, Banapatti DB, Pillai A, Ullas T. Outcome of intertrochanteric fractures treated with proximal femoral nail: A prospective study. *J Orthop Traumatol Rehabil.* 2015;8:25-9.
 17. Neikar S, Sajjan NY, Telkar NB, Nasequddin S. Clinical research on dynamic hip screw and proximal femoral nail in the treatment of intertrochanteric fractures. *J Evid Based Med Healthc.* 2017;4(90):5350-4.
 18. Domingo LJ, Cecilia D, Herrera A, Resines C. Trochanteric fractures treated with a proximal femoral nail. *Int Orthop.* 2001;25:298-301.
 19. Holt G, Nunag P, Duncan K, Gregori A. Outcome after short intramedullary nail fixation of unstable proximal femoral fractures. *Acta Orthop Belg.* 2010;76:347-55.
 20. Raichandani K, Surana R, Bhardwaj A, Garhwal S, Jain H, Raichandani S. Treatment of Stable and Unstable Intertrochanteric Fracture with Short Proximal Femoral Nail: Our Experience with 100 Patients. *Int J Med Res Prof.* 2017;3(2):111-5.
 21. Bridle SH, Patel AD, Bircher M, Calvert PT. Fixation of intertrochanteric fractures of the femur. A randomised prospective comparison of the Gamma nail and the dynamic hip screw. *J Bone Joint Surg.* 1991;73-B:330-4.
 22. Butt MS, Krikler SJ, Nafie S, Ali MS. Comparison of dynamic hip screw and gamma nail: a prospective, randomized, controlled trial. *Injury.* 1995;26:615-8.
 23. Madsen JE, Naess L, Aune AK, Alho A, Ekeland A, Strømsøe K. Dynamic hip screw with trochanteric stabilizing plate in the treatment of unstable proximal femoral fractures: a comparative study with the Gamma nail and compression hip screw. *J Orthop Trauma.* 1998;12:241-8.
 24. Gadegone WM, Salphale YS. Proximal femoral nail: an analysis of 100 cases of proximal femoral fractures with an average follow up of 1 year. *Int Orthop.* 2007;31:403-8.
 25. Strauss EJ, Kummer FJ, Koval KJ, Egol KA. The "Z-effect" phenomenon defined: a laboratory study. *J Orthop Res.* 2007;25:1568-73.
 26. Domingo LJ, Cecilia D, Herrera A, Resines C. Trochanteric fractures treated with a proximal femoral nail. *Int Orthop.* 2001;25:298-301.
 27. Gadegone WM, Salphale YS. Proximal femoral nail – An analysis of 100 cases of proximal femoral fractures with an average follow up of 1 year. *Int Orthop.* 2007;31:403-8.
 28. Tyllianakis M, Panagopoulos A, Papadopoulos A, Papisimos S, Mousafirios K. Treatment of extracapsular hip fractures with the proximal femoral nail (PFN): long term results in 45 patients. *Acta Orthop Belg.* 2004;70:444-54.
 29. Kim WY, Han CH, Park JI, Kim JY. Failure of intertrochanteric fracture fixation with a dynamic hip screw in relation to pre-operative fracture stability and osteoporosis. *Int Orthop.* 2001;25:360-2.
 30. Domingo LJ, Cecilia D, Herrera A, Resines C. Trochanteric fractures treated with a proximal femoral nail. *Int Orthop.* 2001;25:298-301.
 31. Pajarinen J, Lindahl J, Michelsson O, Savolainen V, Hirvensalo E. Pertrochanteric femoral fractures treated with a dynamic hip screw or a proximal femoral nail. *J Bone Joint Surg Br.* 2005;87(1):76-81.
 32. Schatzker J, Tile M. Subcapital and intertrochanteric fractures. The rationale of operative fracture care (IInd ed) Springer: Berlin; 1996: 340.
 33. Leung KS, So WS, Shen WY, Hui PW. Gamma nails and dynamic hip screws for peritrochanteric fractures-a randomized prospective in the elder patients. *J Bone Joint Surg Br.* 1992;74(3):345-51.

Cite this article as Rathore LP, Gupta L, Thakur S, Vaidya S, Sharma D, Sharma A. Treatment of stable and unstable intertrochanteric fractures using proximal femoral nail and their functional assessment using modified Harris hip score. *Int J Res Orthop* 2019;5:162-6.