

Case Report

Large intramuscular plexiform neurofibroma of thigh: a multidisciplinary team approach

Aminda Mandal¹, Satyam Kumar^{2*}, Avinash K. Sinha¹, Deepak Kumar²,
Prabhat K. Dwivedi³, Nikesh D. Panchbhai², Lavleen Pandey⁴

¹Department of Plastic Surgery, ²Department of Orthopaedics, ³Department of Anaesthesia, ⁴Department of Surgery, Bokaro General Hospital, Bokaro Steel City, Jharkhand, India

Received: 30 July 2020

Accepted: 30 September 2020

***Correspondence:**

Dr. Satyam Kumar,

E-mail: kumar7here@gmail.com

Copyright: © the author(s), publisher and licensee Medip Academy. This is an open-access article distributed under the terms of the Creative Commons Attribution Non-Commercial License, which permits unrestricted non-commercial use, distribution, and reproduction in any medium, provided the original work is properly cited.

ABSTRACT

Large plexiform neurofibroma of lower extremity involving the muscle is a rare entity. In this article we present the case of plexiform neurofibroma of right thigh involving the muscular plane and entrapment of the sciatic nerve. A 28 year lady presented with a plexiform neurofibroma of right thigh of size 60 cm×30 cm×25 cm with a positive family history of neurofibromatosis type 1. MRI was done for the assessment of the tumour and the adjacent structure involvement. The neurofibroma was removed with a multidisciplinary team approach with an intensive peri operative management. The pathological diagnosis was plexiform neurofibroma with diffuse neurofibroma. We have reported a rare case of large plexiform neurofibroma of lower extremity with muscle involvement and nerve entrapment.

Keywords: Neurofibromatosis, Plexiform neurofibroma, Schwannoma, Intramuscular, Von Recklinghausen

INTRODUCTION

Neurofibromas are benign tumors that arise from the nerve sheath. In 90% of cases they present as solitary lesions, with the remainder presenting in patients with neurofibromatosis type 1 (NF1), an autosomal dominant genetically inherited disease. NF1 occurs in 1 in 3000 births and has been referred to as peripheral neurofibromatosis or von Recklinghausen disease. Neurofibromatosis type 2 (NF2) is a genetically determined disorder which affects 1 in 40000 individuals worldwide. There are three major types of neurofibroma: cutaneous, spinal and plexiform.¹

According to Stedman's medical dictionary, plexiform neurofibroma (PN) is a type of neurofibroma representing an anomaly rather than a true neoplasm in which the proliferation of all elements of the nerve occur from the

nerve sheath thereby resulting in an irregularly thickened, distorted tortuous structure.² Giant neurofibromas are a surgical challenge because of their vascularity and extensive infiltration and require pre-operative and postoperative management strategies.³ Surgical treatment decisions and frequency of follow up should be made judiciously and individualized for each patient.⁴ We present this patient with PN because of its giant size, a rare intramuscular location and associated with neurofibromatosis type 1.

CASE REPORT

A 28 years lady presented to our plastic surgery opd with the complaint of a large size tumour of size approx. 60 cm×30 cm×25 cm extending from right hip to right knee from last 12 years leading to difficulty in walking and standing. Patient has a positive family history of NF 1.

On examination a large mass of size 60×30×25 cm was present on the posterior aspect of the right thigh extending from hip joint to upper end of popliteal fossa, with a smooth surface and defined margin (Figure 1). Tumour was mobile and pinchable with engorged venous prominence over the surface. Hip joint movement was hampered due to large mass and involvement of hip joint capsule. More than six cafe au lait spots are present of size more than 15mm, multiple subcutaneous neurofibroma was present. Adjacent to index tumour another tumour of size 20×20 cm was present near sacrum region with ulceration, and another tumour of size 15×15 cm was involving the right knee. Remaining systemic examination was essentially normal.

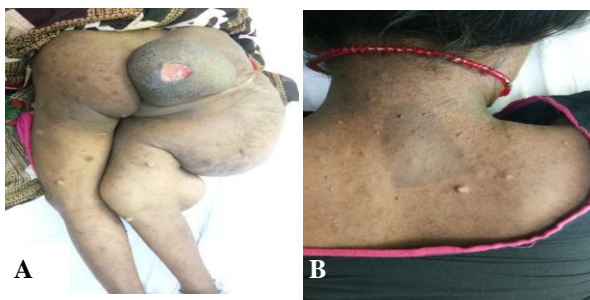

Figure 1: A) A large plexiform neurofibroma involving right thigh, B) Cafe-au-lait.

X-ray pelvis revealed the scoliosis and iliac bone loss on right side (Figure 2). MRI impression suggested a heterogenous infiltrating mass in muscular and subcutaneous plane involving whole of the right thigh in posterolateral compartment, reaching up to gluteal region and right side of the pelvis with cortical irregularity of right femur and right sacral nerve entrapment in the lesion (Figure 3).

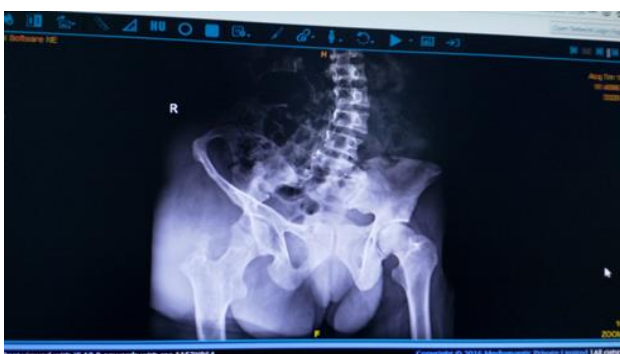

Figure 2: X-ray pelvis showing scoliosis with right iliac bone loss

The patient underwent the excision of the tumour with a multidisciplinary team approach under general anaesthesia. During this procedure dissection plane is created medially from the obturator muscle plane and laterally by dividing the iliopubic tract, dissection was done from above right hip joint capsule to mid thigh.

Tumour with a size of 60×30×25 cm and a mass of 6 kg was excised, which correspond to the most of the thigh extension of neurofibroma and cosmetic correction of the tumour site is done (Figure 4).

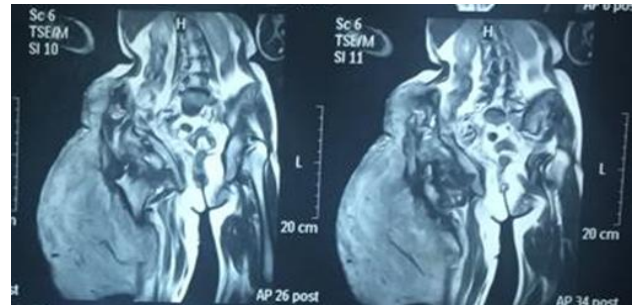


Figure 3: A heterogenous infiltrating mass in muscular and subcutaneous plane involving whole of the right thigh in posterolateral compartment, with cortical irregularity of right femur and right sacral nerve entrapment in the lesion.

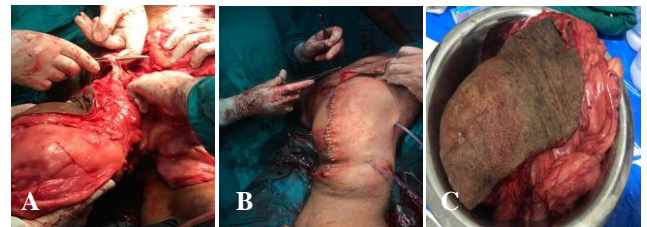

Figure 4: A) Entrapped sciatic nerve, B) closure of the wound, C) excised tumour mass.

Intraoperatively patient received 3 units of whole blood. In post-operative transient period of shock was present which was managed in intensive care unit and also by the transfusion of 3 units of whole blood. Patient was discharged after 5 days and stitch out done on the post-operative day 14 (Figure 5). Pathological examination revealed a plexiform and diffuse neurofibroma.

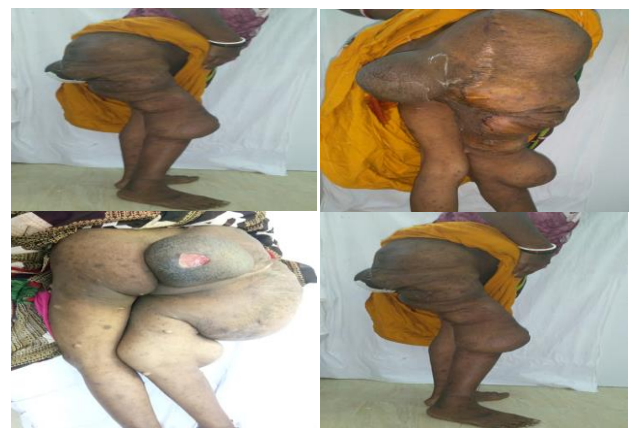

Figure 5: A) Post-operative day 14 after stitch removal, B) pre-operative image plexiform neurofibroma (posterior view), C) post-operative image after tumour resection (lateral view).

DISCUSSION

Neurofibromas are, first described by Smith in 1849 and Von Recklinghausen in 1882 later, benign tumours arising from nerve sheath.⁵ PNs are said to be pathognomonic for neurofibromatosis. There are two distinct neurofibromatosis (NF) syndromes, where Schwann cells form tumors. 70% are autosomal dominant and 30% arise from sporadic mutations. NF 1 (Von Recklinghausen's disease) is the commoner variant, affecting approximately 1:4000 births. It arises from a gene mutation on chromosome (Ch.) 17.⁶

To diagnose NF1, two of the following clinical features must be present; six or more café-au-lait macules >5 mm in diameter in prepubertal and >15 mm in diameter in post pubertal individuals, two or more neurofibromas of any type of one plexiform neurofibroma, freckling of the axillary or inguinal regions, optic glioma, two or more Lisch nodules, a distinctive bony lesion such as sphenoid dysplasia or thinning of the long bone cortex with or without pseudoarthrosis and a first-degree relative with NF1.⁷

Plexiform neurofibroma most commonly seen on the face and neck, cases of lower extremity plexiform neurofibroma are seen less frequent. Also this condition is commonly seen in west and is rarely found in the Indian subcontinent. Plexiform neurofibromas are not generally well circumscribed or encapsulated, the overlying skin is thick and friable with nontensile strength; in plexiform neurofibromas there is an abundance of dilated and friable blood vessels inside the tumour tissues.⁸ Plexiform neurofibromas (PNFs) rarely grow to be larger than 5 cm; however, neurofibromas can undergo continuous enlargement and eventually become giant lesions. Early childhood, puberty, and childbearing age are considered to be the periods of greatest risk for disease progression. Furthermore, PN have a potential for transformation into highly malignant peripheral nerve sheath tumours, which occur in approximately 5% of patients.⁹

There are very few case reports that discuss plexiform neurofibroma resections in the lower limbs.^{10,11,12} Giant neurofibroma is a poorly defined term used to describe a neurofibroma that has grown to a significant but undefined size. However, the term "giant neurofibroma" be used for referring to those neurofibromas weighing 20% or more of the patient's total corporal weight.¹³ In our case specimen weights 6kg so we will consider it as a large plexiform neurofibroma rather than giant. MRI is recommended in evaluating and diagnosing plexiform neurofibroma. Since the MRI appearance of this tumour is characteristic, other lesions can possibly be ruled out. In addition, MRI's multiplanar capability is ideally suited to demonstrate the extension of this large tumors.¹⁴

Operative indications are postural disfigurement, malignancy risk (8-15%), pressure symptoms,

orthopaedic problems (scoliosis, osteoporosis). The treatment for neurofibroma can vary depending on clinical symptoms, size and location of the tumour, and subtype, and complete excision should be performed in order to prevent recurrence. Operative difficulties present in these tumours as lower extremity tumour are highly vascular so risk of massive blood loss is present.^{15,16} It is postulated that these haemorrhages are caused by rupture of friable vasculature secondary to arterial dysplasia or vascular invasion by the neurofibroma.¹⁶ Therefore, the most immediate challenge for surgical management is haemostasis, especially when the dissection is intralesional as in our case. Diathermy is of limited use as the tissue is very friable.¹⁶ A number of authors have reported significant blood loss during surgery requiring high volume transfusion. Other operative complexity are because of chronicity of tumour nerve entrapment occur results in nerve injury during dissection, infiltration of tumour in muscle and subcutaneous plane creates difficulty in creating the dissection plane and involvement of the joint capsule. Intramuscular neurofibromas are rare and not detected till they cause a significant damage to the neighbouring tissues.¹⁷

The main treatment of plexiform neurofibromas is surgery. As suggested by other authors, pre-operative embolization can reduce the intraoperative bleeding yet it can also cause extensive tissue damage, delay wound healing and require VAC Therapy; therefore preoperative imaging plays an important role in evaluating each specific case. Preoperative trans-arterial embolization is not a gold standard approach, especially in plexiform neurofibroma due to the subsequent tissue necrosis.¹⁸

There is a tendency for the tumour to recur from micro invasion of the involved nerves, subsequently affecting the patient's quality of life.¹⁹ Regrowth after surgery is common, 20% of cases after total resection, 45% of cases after partial resection.²⁰

In our case a multidisciplinary team approach is taken by plastic surgery, orthopaedic, anaesthesia, transfusion medicine and intensive care unit department for the pre-operative optimization, intra operative resection of tumour and cosmetic correction of tumour site by plastic surgery team and hip joint capsule and sciatic nerve care being taken by orthopaedic team. Along with it other concern departments who provide support in this case.

This case is being discussed because of its rare location, a large size, erosion of bones right ilium which incapacitated the movements and its intramuscular extension.

CONCLUSION

Lower limb large plexiform neurofibroma is a rare condition that requires both clinical and radiological evaluation, mainly with MRI. Treatment is surgical which require perioperative management strategies with

multidisciplinary team approach. Proper surgical planning should be supported by MRI as it indicates the vasculature of the plexiform neurofibroma and muscular involvement.

Funding: No funding sources

Conflict of interest: None declared

Ethical approval: Not required

REFERENCES

1. Freeman BJC, Lavy C. Spine, Bailey & Love's Short Practice of Surgery. 27th ed. Great Britain: CRC Press; 2018;481.
2. Ferner RE, Gutmann DH. International consensus statement on malignant peripheral nerve sheath tumors in neurofibromatosis. Cancer Research. 2002;62(5):1573-7.
3. Reddy PRK, Rajashekar S, Samagandi S. Giant plexiform neurofibroma of left gluteal and thigh region: a case report. JEMDS. 2015;4(16):2813-7.
4. Gutmann DH, Aylsworth A, Carey JC, Korf B, Marks J, Pyeritz RE, et al. The diagnostic evaluation and multidisciplinary management of neurofibromatosis and neurofibromatosis 2. Journal of the American Medical Association. 1997;278(1):51-7.
5. Le LQ, Parada LF. Tumor microenvironment and neurofibromatosis type I: connecting the GAPS. Oncogene. 2007;26(32):4609-16.
6. Greenbaum AR, Chan CLH. Skin and subcutaneous tissue, Bailey & Love's Short Practice of Surgery. 27th ed. Great Britain: CRC Press; 2018;594-5.
7. Woodruff JM. Pathology of tumors of the peripheral nerve sheath in type neurofibromatosis. Am J Med Genet. 1999;89:23-30.
8. Mukherji MM. Giant neurofibroma of the head and neck. Plast Reconstr Surg. 1974;53(2):184-9.
9. Korf BR. Malignancy in neurofibromatosis type 1. Oncologist. 2000;5(6):477-85.
10. Vélez R, Barrera-Ochoa S, Barastegui D, Pérez-Lafuente M, Romagosa C, Pérez M. Multidisciplinary management of a giant plexiform neurofibroma by double sequential preoperative embolization and surgical resection. Case Rep Neurol Med. 2013;2013:1-8.
11. Zhou J, Li M, Luo C, He Q, Yin Z, Peng H, et al. Giant neurofibroma in the right lower limb of a 26-year-old woman: report of a case. Int. Surg. 2012;97:71-7.
12. Ross AL, Panthaki Z, Levi AD. Surgical management of a giant plexiform neurofibroma of the lower extremity. World Neurosurg. 2011;75(5):754-7.
13. Vélez R, Barrera-Ochoa S, Barastegui D, Pérez-Lafuente M, Romagosa C, Pérez M. Multidisciplinary management of a giant plexiform neurofibroma by double sequential preoperative embolization and surgical resection. Case Reports in Neurological Med. 2013;2013:1-8.
14. Ros PR, Eshaghi N. Plexiform neurofibroma of the pelvis: CT and MRI findings. Magn Reson Imaging. 1991;9(3):463-5.
15. Morello F, Shah P, Dowling K, Siskin G. A hemorrhagic complication of neurofibromatosis. J Vascular Interventional Radiol. 2001;12(6):773-4.
16. White N, Gwanmesia I, Akhtar N, Withey SJ. Severe haemorrhage in neurofibromatoma: a lesson. British Journal of Plastic Surgery. 2004;57(5):456-7.
17. Weiss SW, Goldblum JR. Enzinger and Weiss, soft tissue tumours. 4th ed. St. Louis: Mosby-Harcourt health sciences company; 2002.
18. Villani R, Michelina VV, Fabbri E, Tassone D, Morselli PG. Lower limb giant plexiform neurofibroma: preoperative evaluation and surgical planning. Int Surg J. 2016;3:1646-9.
19. Dave SP, Farooq U, Civantos FJ. Management of advanced laryngeal and hypopharyngeal plexiform neurofibroma in adults. Am J Otolaryngol. 2008;29:279-83.
20. Needle MN, Cnaan A, Dattilo J, Chatten J, Phillips PC, Shochat S, et al. Prognostic signs in the surgical management of plexiform neurofibroma: the Children's Hospital of Philadelphia experience, 1974-1994. J Pediatr. 1997;131(5):678-82.

Cite this article as: Mandal A, Kumar S, Sinha AK, Kumar D, Dwivedi PK, Panchbhai ND, et al. Large intramuscular plexiform neurofibroma of thigh: a multidisciplinary team approach. Int J Res Orthop 2020;6:1312-5.