

Case Report

Broken needle in gluteal region following an intramuscular injection: a case report

Jagdeep Singh¹, Anoop Kalia^{2*}, Ravinder Kumar Banga³, Anshul Dahuja¹

Department of Orthopaedics, ¹Guru Gobind Singh Medical College and Hospital, Faridkot, ²Max Super Speciality Hospital, Mohali, ³Government Medical College, Patiala, Punjab, India

Received: 03 May 2019

Accepted: 18 May 2019

***Correspondence:**

Dr. Anoop Kalia,

E-mail: kaliaanoop@gmail.com

Copyright: © the author(s), publisher and licensee Medip Academy. This is an open-access article distributed under the terms of the Creative Commons Attribution Non-Commercial License, which permits unrestricted non-commercial use, distribution, and reproduction in any medium, provided the original work is properly cited.

ABSTRACT

Incidence of broken hypodermic needle in patients has been decreased because of superior manufacturing techniques. Breaking of hypodermic needle after intramuscular injection has been rarely reported. We report a case of broken needle in the gluteal region in a 36 years old woman following an intramuscular injection. Patient arrived in the emergency after 2 days of the episode. Patient was taken for surgery for removal of the needle. Initially attempts for removal of needle were made without use of image intensifier under local anaesthesia, but it failed as it was very difficult to locate the needle. Patient was taken up for surgery under spinal anaesthesia with the use of image intensifier. Broken needle was located and removed. The following case describes the management of broken hypodermic needle and suggests valuable guidelines for minimising the chances of undue complications arising due to needle migration.

Keywords: Injection, Needle, Intramuscular

INTRODUCTION

The occurrence of broken hypodermic needle following an intramuscular injection is very rarely seen. This is due to superior quality of steel used in the manufacturing of these needles and good injection techniques.^{1,2} Also the use of disposable needles has considerably reduced these types of episodes.^{3,4} A good knowledge and awareness of the difficulties in retrieving the broken needle is need to avoid any complications.

CASE REPORT

A 35 years old lady came to the emergency department with complaints of severe pain in the right gluteal region. History taking revealed that the pain occurred after an intramuscular injection given by a local practitioner for relief of joint pain. She was accompanied by the local

practitioner, who confirmed her version of the narrative. After that the patient had severe pain in the injection site.

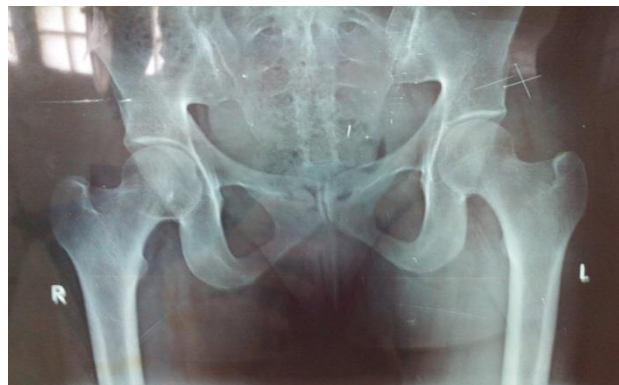

Figure 1: Broken part of needle in gluteal region posteriorly along skin marker pins.

On examination of injection site mark, swelling and mild redness was present. Patient had a limp while walking and there was severe tenderness at the injection site. Routine blood investigations were done and x- rays of pelvis with both hips by applying radio opaque skin markers. On x- ray, the broken needle was identified and it was seen that it had migrated more posteriorly (Figure 1) from the injection site.

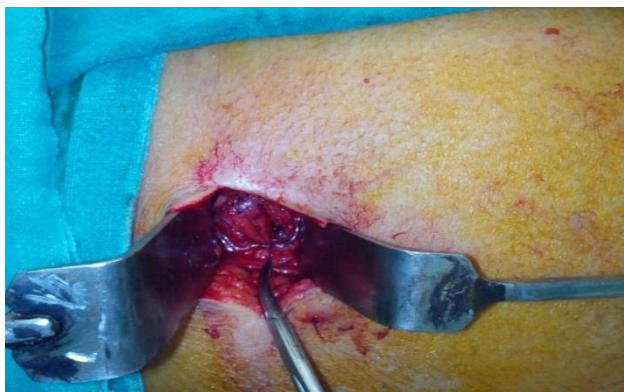

Figure 2: Incision over the skin marker site.

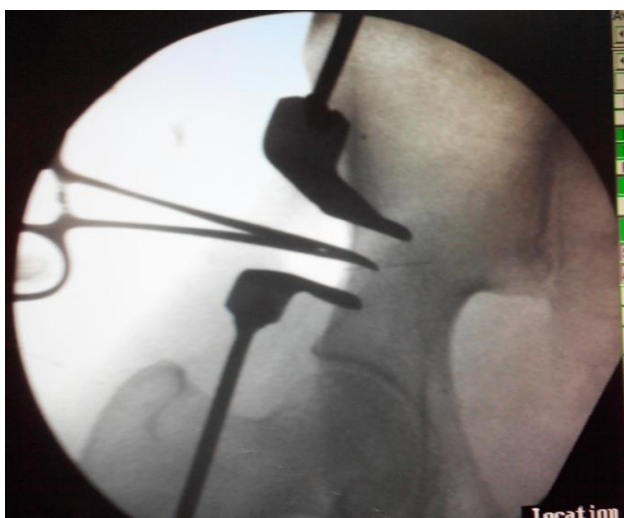


Figure 3: Identification of needle under image intensifier.



Figure 4: Removed broken needle.

An attempt was given for the surgical removal of broken needle in emergency operation theatre under local anaesthesia without the help of image intensifier but it failed. On the following day needle removal was done under spinal anaesthesia with the help of image intensifier. An incision was made at the injection site. Skin subcutaneous tissue was separated. A long artery forceps was used to locate the broken needle using image intensifier (Figure 2 and 3). Needle was found to be present deep within the muscle fibres of the gluteus maximus muscle. Needle was identified and removed (Figure 4). Wound was stitched in layers. Aseptic dressing done.

DISCUSSION

Incidence of needle breakage have been reported in previous literature and majority of being case reports related to needle breakage during dental procedure.^{1,7} On extensive review of literature, authors did not find any previous study or case report on broken hypodermic needle during intramuscular injection. The clinical events in this case were interesting. The patient was accompanied by the person who gave the injection to the patient and had broken the needle during the procedure. Due to paucity of grade 1 or 2 evidence data, Literature is not on proper consensus that whether the broken needles should be removed or not. Brown et al feel that removal is not always necessary unless the patient develops signs and symptoms due to the broken needle.^{8,9} While the other ones suggest definite removal due to risk of needle migrating in the tissues, perforating a vital structure and injuring the neurovascular structures.^{5,7,10,11} A recent case report described rare case of an intravenous drug user which a retained broken needle fragments in the inferior wall of the right ventricle.¹²

A further reason in favour of needle removal is the possible psychological trauma to the patient that may result from the knowledge that the needle has been retained somewhere in the gluteal region.

Accurate localisation of the needle most important aspect. In our case metallic markers were pasted on the skin using a tape and different views of the X-rays have been taken to localise the position of the broken needle. However it is very time consuming and not sufficiently accurate but still beneficial in localizing the foreign body. Intra operatively we have used image intensifier for localization and removal of needle. This method has been widely used by the previous authors with a good success rate.^{13,14} The use of metal detectors have been used in previous studies but such devices are not available at every centre.¹⁵ Magnets were also tried earlier but unfortunately modern hypodermic needle is non magnetic.¹⁶

Regarding the prevention of this complication several important aspects need to be considered. Correct injection technique must be followed while giving injections. A

small part of the needle just distal to its hub must be kept protruding outside the skin while giving the injection. This will help in easy removal of the needle in case a needle breakage occurs while giving the injection.

Injection should be given at the correct anatomical site. Injections given at improper site may lead to sciatic nerve injury which may lead to weakness and hypoesthesia of the affected limb. This occurs due to direct injury caused by the medicine in the injection which affects the sciatic nerve.

Finally, despite the rarity of this complication and the improvement in needles, there is no room for complacency and a meticulous injection technique is imperative.

CONCLUSION

The management of broken hypodermic needle following an intramuscular injection is a 37 years old lady is described. Instant surgical removal of the needle is required owing to its possible migration to the vital structures and the psychological and medicolegal implications which could arise. Proper injection technique and correct site of injection is very important as improper technique and an injection given at wrong site may lead to sciatic nerve injury.

Funding: No funding sources

Conflict of interest: None declared

Ethical approval: Not required

REFERENCES

1. Augello M, von Jackowski J, Gratz KW, Jacobsen C. Needle breakage during local anesthesia in the oral cavity--a retrospective of the last 50 years with guidelines for treatment and prevention. *Clin Oral Investig*. 2011;15:3-8.
2. Malamed SF, Reed K, Poorsattar S. Needle breakage: Incidence and prevention. *Dent Clin North Am*. 2010;54:745-56.
3. Fitzpatrick B. The broken dental needle. *Aust Dental J*. 1967;12:243.
4. Thompsons M, Wright S, Cheng LH, Starr D. Locating broken dental needles. *Int J Oral Maxillofac Surg*. 2003;32:642-44.
5. Sahin B, Yildirimturk S, Sirin Y, Basaran B. Displacement of a Broken Dental Injection Needle Into the Perivertebral Space. *J Craniofac Surg*. 2017;28(5):474-7.
6. Moore K, Khan NR, Michael LM, Arthur AS, Hoit D. Endovascular retrieval of dental needle retained in the internal carotid artery. *J Neuro Int Surg*. 2017;9:26.
7. Sencimen M, Bayar GR, Gulses A. Removal of the retained suture needle under C-arm fluoroscopy: a technical note. *Dent Traumatol*. 2010;26(6):527-9.
8. Brown LJ, Meerkotter VA. Unusual experience with a broken needle. *J Dent Ass S Afr*. 1963;18:74.
9. Malamed SF. *Handbook of Local Anaesthesia*. 2nd ED. St Louis: Mosby; 2012: 230-231.
10. Fraser-Moodie W. Recovery of broken needles. *Brit Dent J*. 1958;105:79.
11. Bedrock RD, Skigen A, Dolwick MF. Retrieval of broken needle in the pterygomandibular space. *J Am Dent Assoc*. 2003;130:685-7.
12. Fu X, Chen K, Liao X, Shen K. Case report: surgical removal of a migrated needle in right ventricle of an intravenous drug user. *Subst Abuse Treat Prev Policy*. 2017;12:51.
13. Cohen DM, Garcia CT, Dietrich AM, Hickey RW Jr. Miniature C-Arm imaging: an in vitro study of detecting foreign bodies in the emergency department. *Pediatr Emerg Care*. 1997;13:247-9.
14. Ma CJ, Jan CM, Hsieh JS, Huang YS, Wang WM, Chan HM, et al. Successful localization and surgical removal of ingested sewing needles under mini C-Arm Fluoroscopy :a case report. *Kaohsiung J Med Sci*. 2006;22:457-60.
15. Mcdonogh T. Anunusual case of trismus and dysphagia. *Br Dent J*. 1996;33:465-6.
16. Chittenden HB, Chandra A, Sandy CJ. Use of an electromagnet to retrieve a broken fascia needle during frontalis sling surgery. *Ophthal Plast Reconstr Surg*. 2005;21(6):469-70.

Cite this article as: Singh J, Kalia A, Banga RK, Dahuja A. Broken needle in gluteal region following an intramuscular injection: a case report. *Int J Res Orthop* 2019;5:744-6.