

Original Research Article

Fibular collateral ligament reconstruction of knee using titanium button: a new fixation technique and an outcome of 35 cases

Sanjay Kumar Rai*, Rohit Varma, Sunitkumar Wani

Department of Orthopaedics, Indian Naval Hospital Ship, Asvini, Colaba, Mumbai, Maharashtra, India

Received: 19 February 2017

Revised: 25 March 2017

Accepted: 01 April 2017

***Correspondence:**

Dr. Sanjay Kumar Rai,

E-mail: skrai47@yahoo.com

Copyright: © the author(s), publisher and licensee Medip Academy. This is an open-access article distributed under the terms of the Creative Commons Attribution Non-Commercial License, which permits unrestricted non-commercial use, distribution, and reproduction in any medium, provided the original work is properly cited.

ABSTRACT

Background: The fibular collateral ligament (FCL) is an important stabilizer of the lateral side of the knee through the whole range of motion. Likewise, it resists external rotation near full extension. Many techniques has been described in the literature for fixation of graft to the fibula like interference screws, making loop around the fibula head but nothing has been said about Titanium button fixation at Fibula end. In our series graft has been fixed at Fibula end using Titanium button. In this article we described our new graft fixation technique.

Methods: We included 35 patients all were soldier of Indian army and navy who got their knee injured during duties, sport, training and accident, were operated with new technique of graft fixation at Fibula end.

Results: As far as my search in the present literature while writing our present study the graft fixation at Fibular end using Titanium button has not yet described by any author. This fixation is robust and results were promising. Out of 35 cases only 02 patients developed knee stiffness and none were has lateral knee opening (Varus stress test was negative). All patients were available for follow up for 18 months.

Conclusions: Based on our new technique of the graft fixation at Fibular end using Titanium button we can conclude that this technique is simple and fixation is robust with promising results.

Keywords: FCL injury, Semitendinosus autograft, Titanium button, Varus instability

INTRODUCTION

The fibular collateral ligament (FCL) is an important stabilizer of the lateral side of the knee.¹ Tear or injury to the FCL rarely occurs in isolation. They are typically associated with other knee ligament injuries such as the anterior cruciate ligament (ACL), posterior cruciate ligament, other posterolateral corner (PLC) structures, and multiligament knee injuries.² FCL tears can occur because of direct varus stress, twisting injuries and hyperextension of the knee. FCL or also known as Lateral collateral ligament injuries rarely occur in isolation and care must be taken to perform a thorough diagnostic work-up. As it is invariably associated with ACL or meniscus injury as well. Clinical examination and stress

radiographs are usually used in the diagnosis. Varus stress radiographs of knee have shown good inter and intra-observer reliability. When the knee flexed at 20°-30 degree and side-to-side lateral gapping difference of 2.7 to 4.0 mm in varus stress radiographs represents a complete FCL tear, whereas a side-to-side difference greater than 4 mm represents a combined PLC injury. MRI imaging is a must in order to identify any other concomitant injuries.

The current standard of care for isolated grade I and II injuries of the FCL is nonsurgical treatment (conservative) with a brace for 4 to 6 weeks.³ Many school of thought, study and clinical experience have reported that grade III injuries does not heal properly

resulting in knee instability.⁴ If this ligament will not reconstructed well in time that leads to a varus thrust gait with increased forces on the medial compartment of the knee. In the long term, this can result in meniscal injuries and medial compartment osteoarthritis. Varus instability due to a deficient FCL has also been shown to increase forces on the ACL and posterior cruciate ligament.⁵ Therefore, FCL should be repair and/or reconstruct at the time of ACL reconstruction and if not done this can put undue stress on the graft(s) and lead to graft failure.

In literature it has been proved that, both repair and reconstruction have been used for grade III injuries to the FCL. However, repair has been reported to lead to a higher rate of re surgery.⁶ Several reconstruction methods have been reported in the literature, including different grafts sources such as quadriceps tendon, semitendinosus - patella bone and bone-patella tendon-bone.⁷⁻⁸ Other groups have reported on augmentation techniques with the biceps femoris tendon, biceps femoris tenodesis, and advancement of the proximal FCL attachment.⁸ In recent years, there has been an increased focus on anatomic reconstructions that have been reported to restore the native biomechanics of the knee.⁹

Many techniques has been described in the literature for fixation of graft to the fibula like interference screws, making loop around the fibula head but nothing has been said about Titanium button fixation at Fibula end. In our series graft has been fixed at Fibula end using Titanium button.

The purpose of our new surgical technique is to describe the outcome of this new technique for anatomic reconstruction of the FCL using semitendinosus autograft.

METHODS

In our study 35 patients all were soldier of Indian army and Navy who got their knee injured during duties, sport, training and accident. The study was conducted in Indian Navy hospital ship Asvini, Colaba, Mumbai between March 2013 to December 2015.

Patients age group between 19 to 45 years who had ACL and LCL tear with positive varus test were included. MRI was done for confirmation of diagnosis. Patients who has previous surgery on same knee for same ligaments tear and patients had osteoarthritis knee Gd III were excluded from study

All patients were evaluated clinically an MRI was done to identify other ligament injury. Each patient underwent pre-anaesthesia checkup and surgery was performed in supine position under spinal anaesthesia.

Surgical procedures

The patient was placed in supine position with the injured leg in a leg holder. A well-padded thigh tourniquet is subsequently placed on the upper thigh of the operative leg. The surgical leg is prepped and draped and the tourniquet is inflated (300 mm Hg).

Surgical approach

First step

A Semitendinosus graft was harvested from injured leg and makes it doubled and placed on graft tensioner as we all do in ACL reconstruction.

The length of double prepared graft was 12-16 cm and diameter was 5-7 mm.

Second step

A lateral hockey stick incision was made to the skin along the iliotibial band and is extended distally between the lateral fibular head and Gerdy's tubercle. It is necessary to identify the common peroneal nerve behind the neck of fibula.

Sharp dissection is performed down to the fascia overlying the iliotibial band. Skin flaps with subcutaneous tissue are made anteriorly and posteriorly. The posterior skin flap should have sufficient subcutaneous tissue and vascularity to support wound healing and avoid skin necrosis postoperatively. The nerve is then retracted from the surgical field to minimize the risk of injury during the operation.

Once the nerve has been isolated, a 1-cm longitudinal incision is made in the distal aspect of the long head of the biceps femoris tendon, along the fibers of the tendon to access the biceps bursa, where the FCL insertion can be found.¹⁰ A mark was made with sterile pen on the distal end of the remnant FCL.

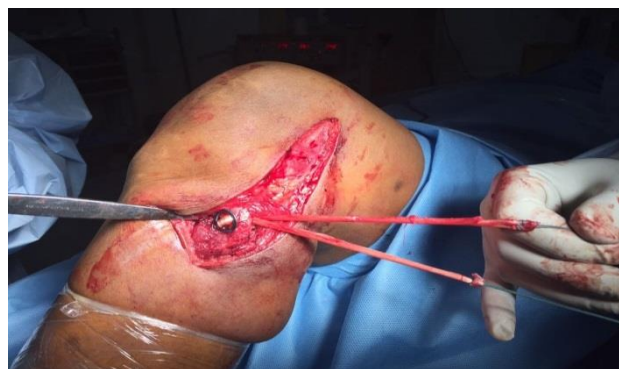

Figure 1: Graft fixation at fibular end is being done using titanium button.

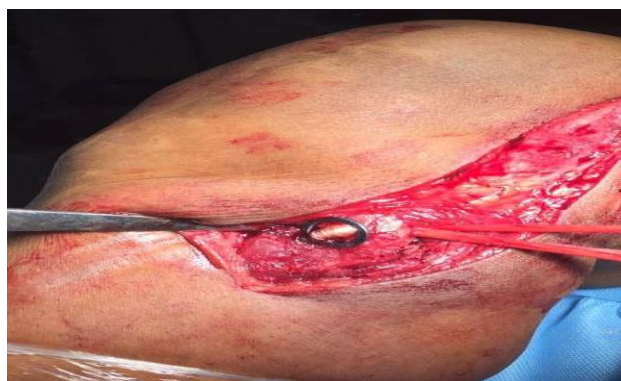

Figure 2: Graft fixation to fibula using titanium button.

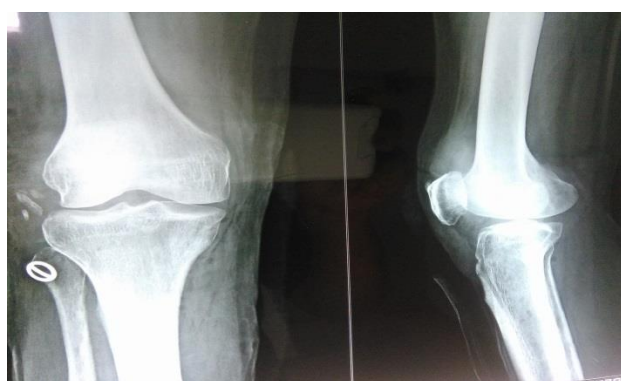

Figure 3: Postoperative X-ray titanium button is well seated at fibula head.

The anterior arm of the long head of the biceps femoris tendon is incised longitudinally, and the distal attachment of the FCL is sharply dissected to create room for the reconstruction tunnel on the fibular head. A guide pin is drilled from the FCL attachment on the lateral aspect of the fibular head (8.2 mm posterior to the anterior margin of the fibular head and 28.4 mm distal to the tip of the fibular styloid process, aimed at the posteromedial down slope of the fibular head, distal to the popliteofibular ligament attachment.¹¹ Aiming too proximally can damage the attachment of the popliteofibular ligament. A 6-mm reamer (Arthrex, Naples, FL) is used to create a

reconstruction tunnel on the fibular head. The prepared graft was passed through Titanium button and then passed through Fibula tunnel as shown in Figure 1. The both end of graft now whip-stitched together and the diameter was 5-7 mm.

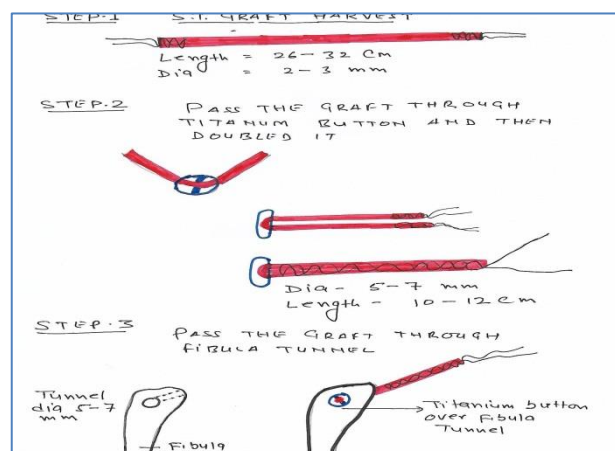


Figure 4: The systemic diagram shows passing of graft into titanium button and in the fibular tunnel.

Next step femoral tunnel was made using drill of 5-7 mm drill bit and exit it from medial side. The graft was passed under superficial structure into the femoral tunnel. The Ethibond suture no 3 was used for suturing end of the graft and delivered through medial side of femoral condyle through the femoral tunnel. The knee was placed in motion for 25 cycles and then it was fixed using 8 × 35 mm bio interference screw.

Once fixation is complete, the knee is moved through a complete range of motion and the varus laxity is tested with a varus stress test for comparison with the preoperative state.

RESULTS

As far as my search in the present literature while writing our study the graft fixation at fibular end using titanium button has not yet described by any author. This fixation is robust and results were promising.

Table 1: Patients with their type of injury and varus test at 18 months.

No of patients	Injury	Varus test after 3 months	Varus test after 9 months	Varus test after 18 months	Knee-ROM
12	ACL + LCL	Nil	Nil	Nil	Full
04	ACL+LCL small chondral lesion MFC	Gd 1	Nil	Nil	Full
09	LCL with medial meniscus tear	Nil	Nil	Nil	Full
10	LCL + ACL + medial meniscus	Nil	Nil	Nil	Full
02	ACL + LCL medial meniscus	Gd 1		Nil	0-90

Out of 35 cases only 02 patients developed knee stiffness even after 9 month so physiotherapy relook arthroscopy was done which reveled arthrofibrosis and was further treated by debridement but still he had only 0-90 of ROM. However no patients were had lateral knee opening at 09 months (Varus stress test was negative). All patients were available for follow up for 18 months.

DISCUSSION

Several non-anatomic-based FCL reconstructions are described in the literature and are used, for anatomical reconstructions of FCL. They are preferred because this reconstruction technique restores near native knee biomechanics, and has also been validated to improve patient outcomes.^{12,13} The graft is fixed at 20° to 30° because biomechanical studies have shown that these are the angles at which the greatest amount of varus instability is created by sectioning the FCL. Coobs et al, biomechanically showed that anatomical FCL reconstruction restores varus, external, and internal rotation to near normal stability to knees with isolated FCL injuries.¹²

In addition, anatomical FCL reconstruction using a semitendinosus graft at an average 2-year follow-up resulted in improved patient outcomes and near-normal lateral compartment stability in patients with grade III injuries of the FCL.

In our study the modified Cincinnati score improved from 27 preoperatively to 80 postoperatively and the International Knee Documentation Committee subjective outcome score improved from 33 preoperatively to 89.4 postoperatively.

The semitendinosus tendon is preferred because it is long enough to match the length of the FCL, which has shown to be 70 mm on average. The graft is also preferred because of its tensile strength and larger size.

Many techniques has been described in the literature for fixation of graft to the fibula like interference screws, making loop around the fibula head but nothing has been said about Titanium button fixation at Fibula end. In our series graft has been fixed at Fibula end using Titanium button.

The graft fixation at Fibula end was done using Titanium button which is not yet described by any author. This fixation technique is newer in literature hence we suggest this fixation while reconstruction of FCL. This new fixation technique is robust and the results are promising even after 18 months of follow up.

We recommend our new method of graft fixation at Fibula end using Titanium button while anatomical reconstruction of grade III FCL injuries.

CONCLUSION

Many techniques has been described in the literature for fixation of graft to the fibula like interference screws, making loop around the fibula head but nothing has been said about Titanium button fixation at Fibula end. In our series graft has been fixed at Fibula end using Titanium button. The graft fixation at Fibula end was done using Titanium button which is not yet described by any author. This fixation technique is newer in literature hence we suggest this fixation while reconstruction of FCL. This new fixation technique is robust and the results are promising even after 18 months of follow up. We recommend our new method of graft fixation at Fibula end using Titanium button while anatomical reconstruction of grade III FCL injuries.

Funding: No funding sources

Conflict of interest: None declared

Ethical approval: The study was approved by the institutional ethics committee

REFERENCES

1. Gollehon DL, Torzilli PA, Warren RF. The role of the posterolateral and cruciate ligaments in the stability of the human knee. A biomechanical study. *J Bone Joint Surg Am.* 1987;69:233–42.
2. LaPrade RF, Terry GC. Injuries to the posterolateral aspect of the knee: Association of anatomic injury patterns with clinical instability. *Am J Sports Med.* 1997;25:433–9.
3. Geeslin AG, LaPrade RF. Outcomes of treatment of acute grade III isolated and combined posterolateral knee injuries: A prospective case series and surgical technique. *J Bone Joint Surg Am.* 2011;93:1672–83.
4. Griffith CJ, Wijdicks CA, Goerke U, Michaeli S, Ellermann J, LaPrade RF. Outcomes of untreated posterolateral knee injuries: An in vivo canine model. *Knee Surg Sports Traumatol Arthrosc.* 2011;19:1192–7.
5. LaPrade RF, Muench CW, Wentorf FA, Lewis JL. The effect of injury to the posterolateral structures of the knee on force in a posterior cruciate ligament graft: A biomechanical study. *Am J Sports Med.* 2002;30:233–8.
6. Black BS, Stannard JP. Repair versus reconstruction in acute posterolateral instability of the knee. *Sports Med Arthrosc Rev.* 2015;23:22–6.
7. Chen CH, Chen WJ, Shih CH. Lateral collateral ligament reconstruction using quadriceps tendon-patellar bone autograft with bioscrew fixation. *Arthroscopy.* 2001;17:551–4.
8. Latimer HA, Tibone JE, ElAttrache NS, McMahon PJ. Reconstruction of the lateral collateral ligament of the knee with patellar tendon allograft: Report of a new technique in combined ligament injuries. *Am J Sports Med.* 1998;26:656–62.

9. Liu P, Wang J, Zhao F, Xu Y, Ao Y. Anatomic, arthroscopically assisted, mini-open fibular collateral ligament reconstruction: An in vitro biomechanical study. *Am J Sports Med.* 2014;42:373–81.
10. LaPrade RF, Hamilton CD. The fibula collateral ligament-biceps femoris bursa. An anatomic study. *Am J Sports Med.* 1997;25:439–43.
11. LaPrade RF, Ly TV, Wentorf FA, Engebretsen L. The posterolateral attachments of the knee: A quantitative and qualitative morphologic analysis of the fibular collateral ligament, popliteus tendon, popliteofibular ligament, and lateral gastrocnemius tendon. *Am J Sports Med.* 2003;31:854–60.
12. Chen CH, Chen WJ, Shih CH. Lateral collateral ligament reconstruction using quadriceps tendon-patellar bone autograft with bioscrew fixation. *Arthroscopy.* 2001;17:551–4.
13. Coobs BR, LaPrade RF, Griffith CJ, Nelson BJ. Biomechanical analysis of an isolated fibular (lateral) collateral ligament reconstruction using an autogenous semitendinosus graft. *Am J Sports Med.* 2007;35:1521–7.

Cite this article as: Rai SK, Varma R, Wani S. Fibular collateral ligament reconstruction of knee using titanium button: a new fixation technique and an outcome of 35 cases. *Int J Res Orthop* 2017;3:573-7.