

Case Report

Open anterolateral fracture dislocation of ankle joint: a rare case report

Prasanna Anaberu, R. Prathik*, R. Manish

Department of Orthopaedics, J.J.M. Medical College, Davangere, Karnataka, India

Received: 20 October 2018

Accepted: 06 December 2018

***Correspondence:**

Dr. R. Prathik,

E-mail: prathik9009@gmail.com

Copyright: © the author(s), publisher and licensee Medip Academy. This is an open-access article distributed under the terms of the Creative Commons Attribution Non-Commercial License, which permits unrestricted non-commercial use, distribution, and reproduction in any medium, provided the original work is properly cited.

ABSTRACT

Anterior ankle dislocation with associated compound bi-malleolar fracture is a rare injury. Ankle fracture dislocations most frequently occurs in young males caused by high energy trauma. The direction of the joint dislocation is determined by the position of the foot and the direction of the force being applied. A middle aged male presented to us with history of road traffic accident and was diagnosed to have anterior dislocation of right ankle joint with compound bi-malleolar fracture. Patient was taken to emergency operation theatre for wound debridement and immediate ankle reduction done under sedation. Due to wound contamination fracture fixation was delayed, once the wound healed bi-malleolar fracture fixation was done.

Keywords: Ankle joint, Compound fracture, Anterior dislocation, Bi-malleolar fracture

INTRODUCTION

Ankle is a modified hinge joint. It is comprised of six articular surfaces of three bones which articulate with each other. Ankle mortise is formed by distal most part of tibia and fibula which are held other by syndesmotoc ligaments. Motor vehicle accidents and sports injuries with high velocity of injury leads ankle fracture dislocations most commonly in young males.¹⁻³ Depending upon the direction of dislocation of the talus in relation to tibia these injuries can be classified as anterior, posterior, posteromedial and posterolateral dislocations.⁴ In majority of reported cases it presents as an open injury making the closed injury more rare presentation. Medial and lateral ligaments provide momentous stability to the ankle joint.

When the foot is stabilized on the ground, and the lower leg is forced posteriorly with forced ankle dorsiflexion may cause anterior ankle dislocation.² Direction of the force being applied and the foot position predicts the

direction of dislocation of the ankle joint.³ To relieve the pressure on the neurovascular structures, and to reduce swelling and to avoid skin compromise, it is judicious to reduce such dislocations at the earliest.

CASE REPORT

A 45 yr old male patient Mr Manjunatha from Chitradurga district, Karnataka, India. He was brought to Chigateri government hospital Davangere, by his family members with alleged history of road traffic accident. Patient was hit by a car while crossing the road and sustained injury to right ankle. Pain was sudden in onset, localized to the right ankle, excruciating in nature, aggravated on movement relieved on immobilization. It was associated with bleeding from wound over right ankle. On general physical examination patient was pale, Vitals were stable and systemic examination was normal. Patient was unable to walk.

On local examination, patient lies in supine position with bilateral anterior superior iliac spine, patella at same

level. A compound irregular triangle shaped wound of 5×7×6 cm present over the right medial aspect of ankle with exposed distal tibia and its articulating surface (Figure 1 and 2). Multiple abrasions present over the right leg, foot and heel. All movements at the right ankle were restricted, movements at right knee joint were normal and active toe movements of right foot present. Dorsalis-pedis artery was palpable whereas posterior tibial artery was not palpable.

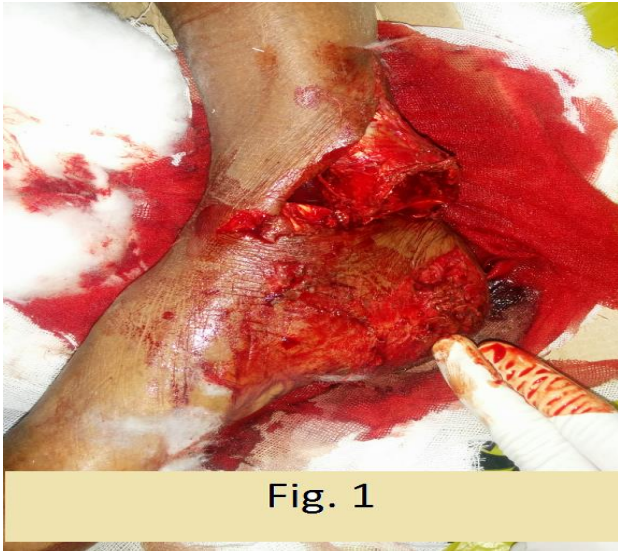


Fig. 1

Figure 1: Presentation of patient to casualty with open anterolateral dislocation of right ankle joint.

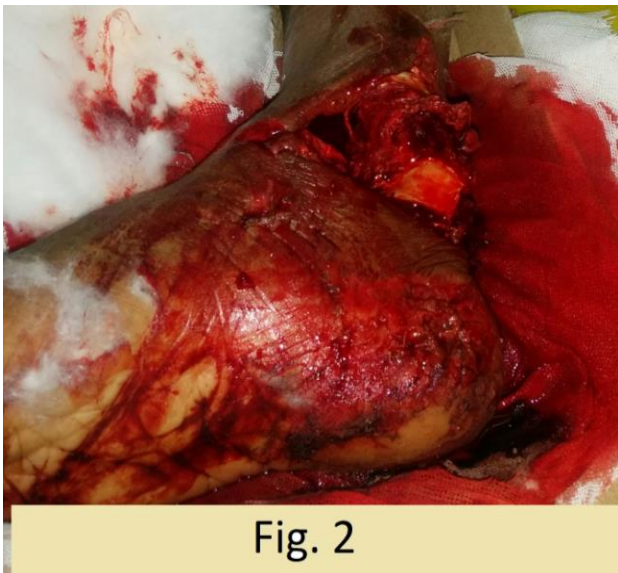


Fig. 2

Figure 2: Inferior view of articulating surface of tibia.

Blood Investigations- Within normal limits.

X- rays of ankle and foot showed Anterior dislocation of right ankle joint with Bi-malleolar fracture(Figure 3a, 3b).

The purpose of immediate reduction of dislocated joint is to relieve pressure on neurovascular structures. Patient was administered intravenous opioid analgesic infusion. Culture was taken. Wound was thoroughly washed with 4 liters of normal saline then cleaned with povidone iodine and hydrogen peroxide wash. Closed reduction was attempted under sedation. Longitudinal traction and counter-traction were given, followed by a posteriorly directed force on the foot. Even after sufficient traction and counter traction ankle dislocation was irreducible. Later on exploration tibialis posterior tendon was found to be resisting the reduction, tendon was retracted and reduction was successful (Figure 4). Following the reduction, posterior tibial artery was palpable. Yet there was subluxation of right distal tibia and was unstable due to syndesmotomic and ligamentous injury. Due to gross contamination and poor skin condition, fracture fixation was deferred.

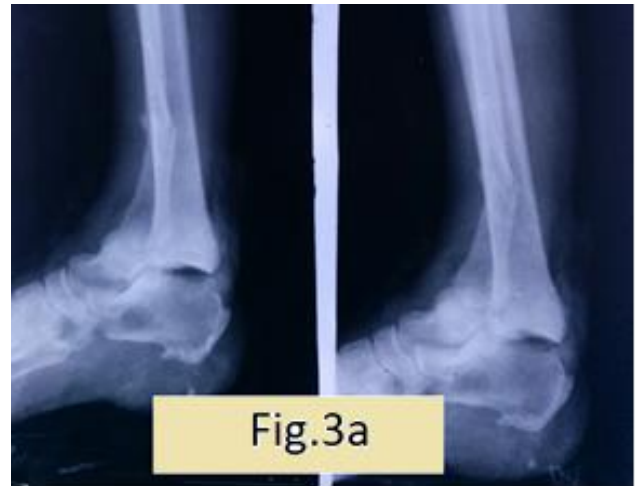

Fig.3a

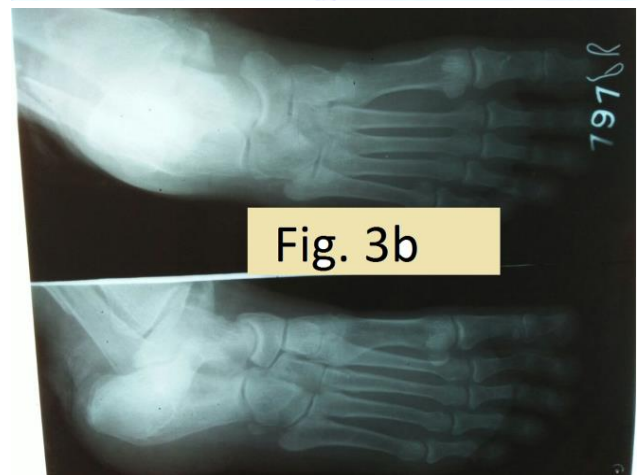


Fig. 3b

Figure 3: Plain radiographs of right ankle taken in anteroposterior, lateral and oblique views (a and b) Visualizing anterolateral dislocation of ankle joint with medial malleolus and distal 1/3rd fibula fracture.

2.1 Course of ankle dislocation reduction

After reduction of the ankle dislocation, thorough wash was given, stay sutures was applied (Figure 5).

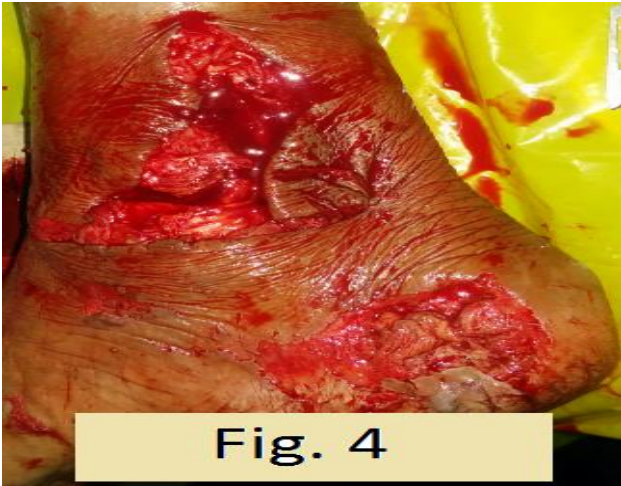

Figure 4: Post reduction image of right ankle.

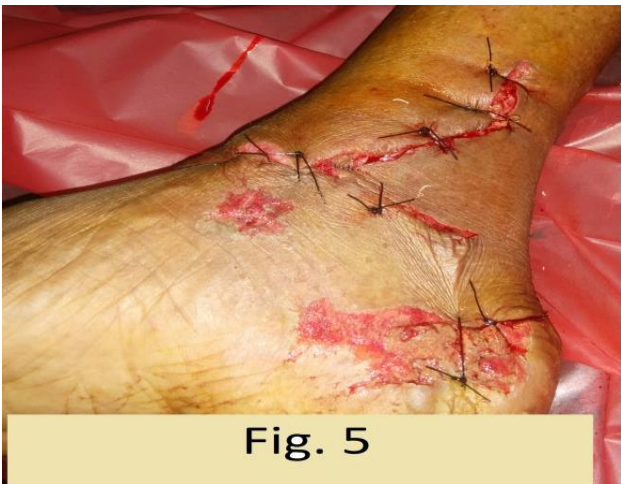

Figure 5: Stay sutures applied after through wash.

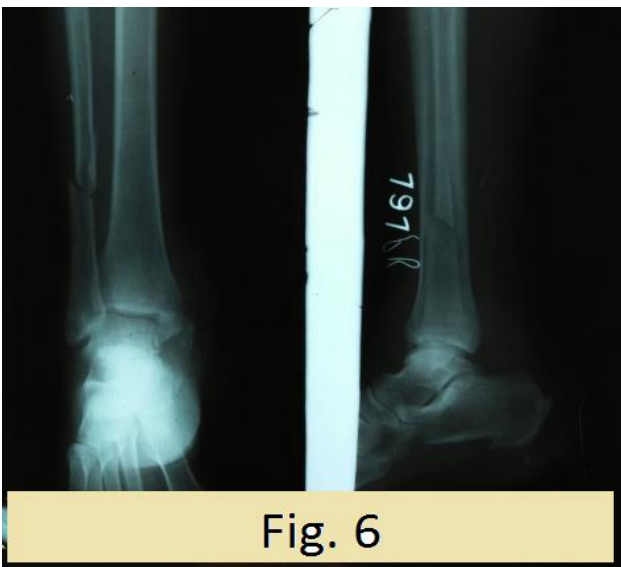


Figure 6: Radiograph taken in anteroposterior and lateral views: after immediate post reduction of ankle joint.

Check x-rays were taken to assess the reduction as well stability of the ankle joint (Figure 6).

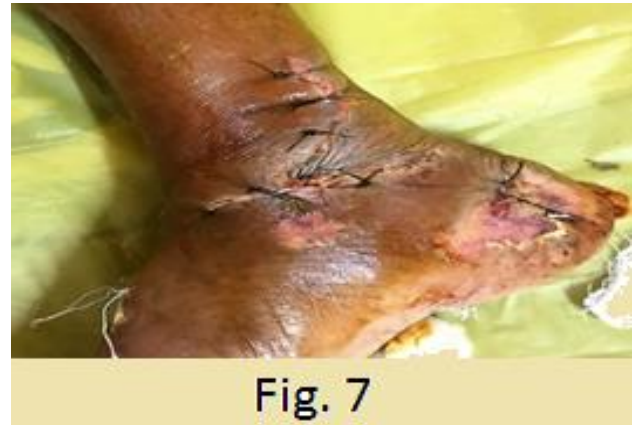

Figure 7: Wound status of right ankle joint five days after injury.

Post-operatively daily wound dressings were done with Mupirocin ointment (Figure 7). Once the wound started healing with granulation tissue, fracture fixation was planned. After 20 days patient was posted for Bi-malleolar fracture fixation. Medial malleolus fracture was fixed with two AO cannulated screws and fibula was fixed with seven holed semitubular plate along with five cortical screws and one syndesmotomic screw (Figure 8).

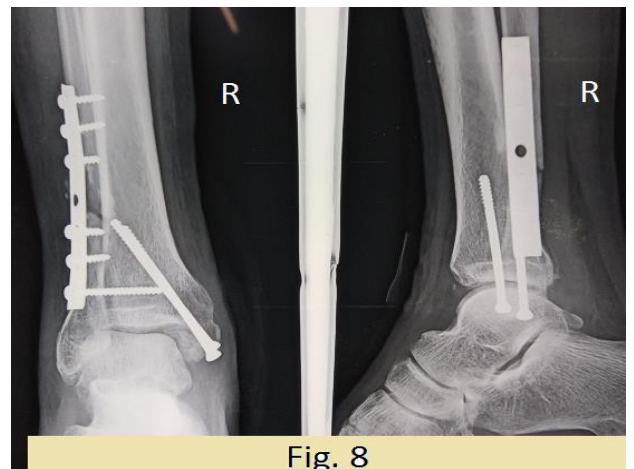


Figure 8: Radiograph of right ankle joint: visualizing bi-malleolar fixation with two AO cannulated screws and fibular fixation by seven holed semitubular plate along with five cortical screws and one syndesmotomic screw.

Sutures were removed on 15th post-operative day. Patient was immobilized with below knee cast for 10 weeks. Patient was advised strict non-weight bearing and was reviewed once a month until 4 months. After 10 weeks cast was removed, gradual weight bearing and active ankle movements were initiated. Patient initially had right ankle stiffness due to prolonged immobilization. Following intensive physiotherapy for 1 month, patient

gradually developed 20-30 degree of plantar flexion and 5-10 degree dorsiflexion. Eventually patient achieved good range of motion in the right ankle.

DISCUSSION

Anterolateral dislocations have been reported rarely in the literature. Anterolateral dislocations are due to result of posterior force applied to the tibia with ankle in dorsiflexion associated with ligament injury. In the ankle, the ligaments are stronger than the malleoli so that dislocations are usually accompanied by the fracture. Closed types of ankle dislocations are commonly reported in literature than open types.

Bohler in 1937, first described the interposition of anteriorly displaced posterior tibial tendon in a tibiotalar dislocation.⁶ Similarly, in our case tibialis posterior tendon was found to be interposed between the distal tibia and the talus, obstructing the reduction. Following the retraction of the tendon anatomical reduction was achieved.

In certain circumstances osseous injury can be complicated and needs open fracture repair due to open wounds. Open repair might be delayed because of deprived soft tissue status.⁷

Primary open reduction and internal fixation of open ankle fracture dislocation are usually not done due to possible wound infection and complexity. In the present case scenario we consider thorough wound debridement as the most important step in the management of such compound injuries. Further fracture fixation could be planned once the soft tissue resumes to normal status.

For the efficacious patient outcomes, immediate joint reduction and sustaining indiscrete neurovascular status are pivotal.⁸

CONCLUSION

In this rare case report we found that, early diagnosis, immediate relocation of the joint and assessing

neurovascular status along with surgical treatment is of paramount importance in determining overall successful outcome of the patient.

Funding: No funding sources

Conflict of interest: None declared

Ethical approval: Not required

REFERENCES

1. Southerland JT (ed). McGlamry's Comprehensive Textbook of Foot and Ankle Surgery, 4th Edition. Lippincott Williams & Wilkins; 2013.
2. Karampinas PK, Stathopoulos IP, Vlamis J, Polyzois VD, Pneumatikos SG. Conservative treatment of an anterior-lateral ankle dislocation without an associated fracture in a diabetic patient: a case report. *Diabet Foot Ankle.* 2012;3:10.3402/dfa.v3i0.18411.
3. roble RR, Nepola JV, Malvitz TA. Ankle dislocation without fracture. *Foot Ankle.* 1988;9:64-74.
4. Rivera F, Bertone C, De Martino M, Pietrobono D, Ghisellini F. Pure dislocation of the ankle: three case reports and literature review. *Clin Orthop.* 2001;382:179-84.
5. Ortolani A, Bevoni R, Russo A, Marcacci M, Girolami M. Posterior tibial tendon displacement behind the tibia and its interposition in an irreducible isolated ankle dislocation: a case report and literature review. *Joints.* 2016;4(3):183-8.
6. Bohler L. the treatment of Fractures, English ed. 4, William Wood Publishers, Baltimore; 1936: 453.
7. Giordana CP, Koval KJ. Treatment of fracture blisters: a prospective study of 53 cases. *Orthop Trauma.* 1995;9:171-6.
8. Saied A, Ziaiyie A. Neglected ankle dislocation. *J Foot Ankle Surg.* 2007;46:307-9.

Cite this article as: Anaberu P, Prathik R, Manish R. Open anterolateral fracture dislocation of ankle joint: a rare case report. *Int J Res Orthop* 2019;5:192-5.