

Original Research Article

Arthroscopic fixation of anterior cruciate ligament tibial avulsion fractures: the suture “bridge” pull out technique and evaluation of results

Mihir R. Patel¹, Ushma K. Butala^{2*}, Nirlepsinh S. Thakor³,
Raunik R. Bansod³, Rohan A. Dhotre³

¹Department of Orthopaedics, ²Department of General Surgery, H. B. T. Medical College and Dr R. N. Cooper Hospital, Juhu, Mumbai, Maharashtra, India

³Department of Orthopaedics, K. B. Bhabha Municipal General Hospital, Bandra, Mumbai, Maharashtra, India

Received: 26 June 2017

Revised: 16 July 2017

Accepted: 19 July 2017

*Correspondence:

Dr. Ushma K. Butala,

E-mail: ushmabutala83@gmail.com

Copyright: © the author(s), publisher and licensee Medip Academy. This is an open-access article distributed under the terms of the Creative Commons Attribution Non-Commercial License, which permits unrestricted non-commercial use, distribution, and reproduction in any medium, provided the original work is properly cited.

ABSTRACT

Background: Tibial anterior cruciate ligament (ACL) avulsion fractures are a common injury in children and adolescents. Operative treatment is indicated for type 2, 3 and 4 fractures. Arthroscopic fixation is the preferred method and numerous fixation options are described. The purpose of this study is to evaluate the results of a new technique of arthroscopic fixation.

Methods: A retrospective study was done involving twelve patients having displaced ACL tibial avulsion fractures. The arthroscopic suture “bridge” pull out technique was used to fix these fractures. Patient symptoms like knee pain, locking, clicking, sensation of giving way and clinical signs like tenderness, range of motion, Mc Murray’s test, stability test and Lysholm knee scores were evaluated pre operatively and post operatively at 3 months and 6 months. Patient satisfaction was noted at latest follow up.

Results: One patient had type 2, 7 patients had type 3 and 4 patients had type 4 tibial ACL avulsion fractures. All the fractures united and all patients achieved full knee range of motion by 2 months post-operative. The clinical symptoms and signs improved post operatively. The mean Lysholm knee score at 3 months follow up was 88.8 and at 6 months follow up were 98.8. At latest follow up, all the patients were satisfied with their knee function.

Conclusions: The arthroscopic suture “bridge” pull out technique is an effective method for fixation of ACL tibial avulsion fractures with respect to knee stability, range of motion and resumption of pre injury activity level.

Keywords: Knee arthroscopy, Suture pull out, Bridge, ACL tibial avulsion

INTRODUCTION

Tibial anterior cruciate ligament (ACL) avulsion fractures are a common injury in children and adolescents. In adults they account for 1% to 5% of ACL injuries.¹ They are caused by a hyperextension injury of the knee or by a

direct force over the distal femur with the knee in flexion. Meyers and McKeever have classified these injuries depending on the amount of displacement of the ACL tibial fragment as follows: type 1—minimal or undisplaced fracture fragment; type 2—elevation of only the anterior half of the fragment; type 3—complete displacement of the

fragment; type 4 (modified by Zaricznj) – comminution of the displaced fragmented.

Non operative treatment in form of immobilization is indicated for type 1 fractures. Non operative treatment for type 2 to type 4 fractures, in form of manipulation in extension fails to achieve reduction of the fragment as the fracture lies in the intercondylar notch and not between the articulating surface of the tibia and femur.²

Operative treatment is indicated for type 2, 3 and 4 fractures as these displaced fractures can develop non-union or malunion resulting in knee instability and anterior impingement causing loss of knee extension³. Surgical techniques include open or arthroscopic reduction and internal fixation. Open reduction and internal fixation involves arthrotomy, soft tissue dissection and prolong immobilisation resulting in high chance of knee stiffness.³ The arthroscopic technique is the preferred treatment modality as it allows magnified vision, accurate reduction, minimal soft tissue dissection, stable fixation and management of associated intra articular pathologies. The fixation options include wires, staples, screw and sutures. The advantage of using sutures is that they provide very stable and rigid fixation and don't need removal.

The suture fixation techniques described in literature utilise two tunnels drilled on either side of the tibial ACL fragment. The sutures are then passed around the ACL and passed through the tunnels followed by tying over the anteromedial tibial bone bridge. This suture construct can result in excessive ACL tension, uneven compression of the bony fragment and elevation of the anterior part of the fractured fragment. The overtensioning of the ACL can result in restricted knee range post operatively and the anterior elevation of the fragment can cause impingement in extension. With increasing knowledge of anatomical ACL reconstruction, recreating the ACL footprint anatomically without overtensioning the ACL comes to attention. The purpose of this study is to evaluate the results of repairs of ACL tibial bony avulsion fractures using the suture “bridge” pull out technique.

METHODS

This was a retrospective study conducted in the department of orthopaedics at a secondary level hospital in the time period September 2012 to September 2015. Patients having displaced ACL tibial avulsion fractures as diagnosed on plain -radiography were included in this study. Twelve patients were included in this study.

Pre-operative data recording included age, sex, side, mechanism of injury, duration since injury and complains with respect to pain, locking, clicking, sensation of giving away and swelling. Clinical examination included tenderness, range of motion, Mc Murray's test and tests for instability. Lysholm knee score was recorded pre

operatively. Radiological investigations included X-rays and magnetic resonance imaging (MRI) of the knee.

Spinal anaesthesia was administered to all patients. A high thigh tourniquet was applied and the patient's leg was positioned in an arthroscopic leg holder at the edge of the table. Standard anterolateral (AL) portal for viewing and the anteromedial (AM) portal for instrumentation were established. The fracture hematoma was drained followed by a diagnostic arthroscopy to confirm the ACL tibial avulsion fracture and the status of the ACL. Partial menisectomy was performed for the two patients with meniscal tears. A motorised shaver was used to remove fracture debris from the fracture bed. An arthroscopic probe was used to provisionally reduce the fragment into the fracture crater. The intermeniscal ligament was excised with a motorised shaver as it prevented reduction of the fracture fragment.

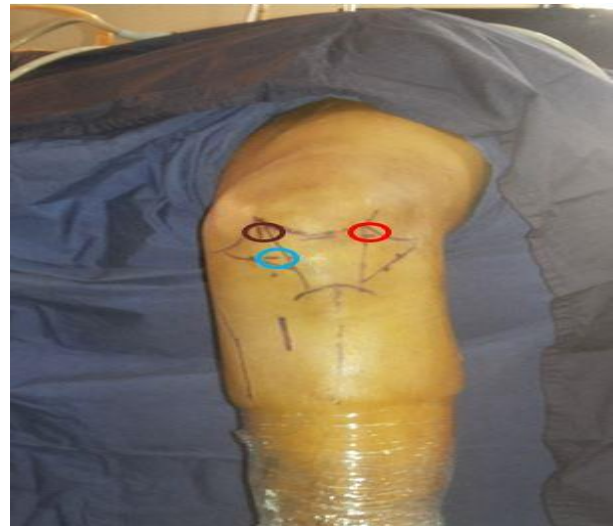

Figure 1: Knee portals used: brown-high anteromedial portal; red-standard standard anterolateral portal; blue-standard anteromedial portal.

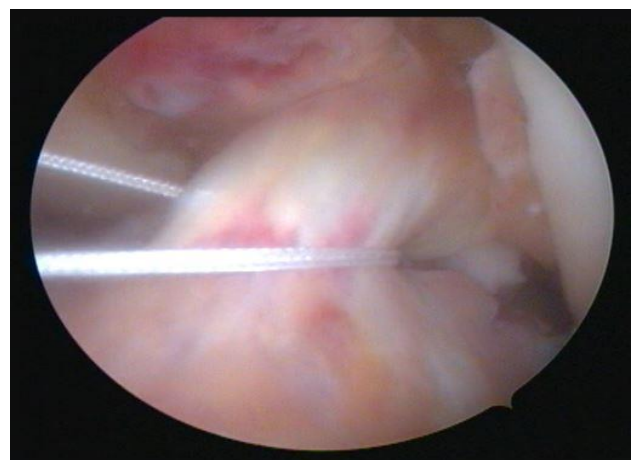


Figure 2: “Thread 1” looped around the ACL.

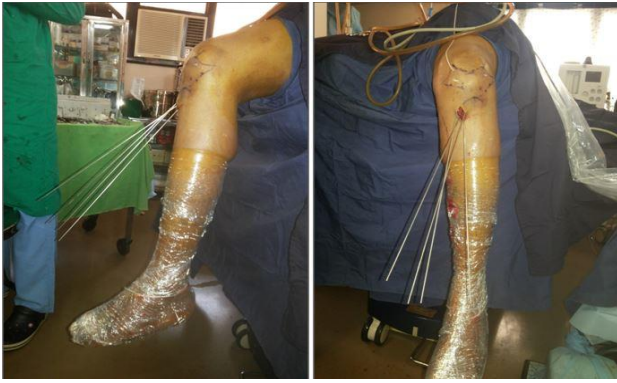

Figure 3: Extra articular view of the four wires.

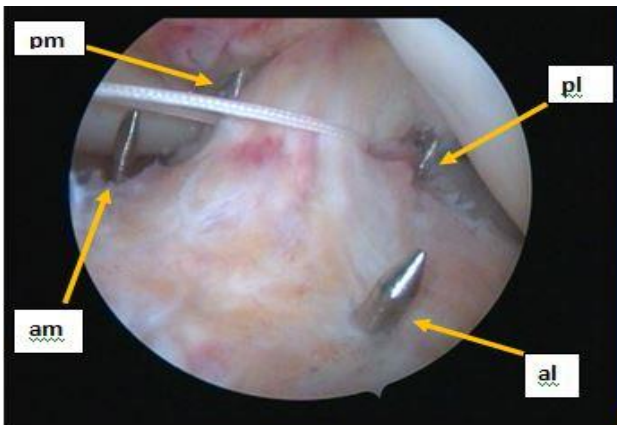


Figure 4: Position of the 4 wires in relation to the ACL tibial avulsion fracture. [pm: posteromedial wire; pl: posterolateral wire; am: anteromedial wire; al: anterolateral wire].

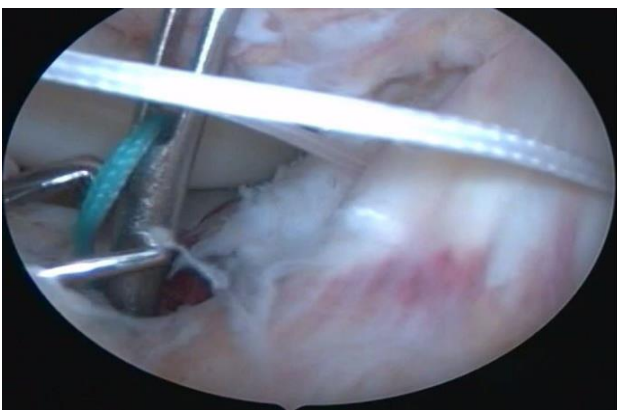


Figure 5: Beath pin with a suture shuttle passed through the anteromedial tunnel.

A high anteromedial portal was established in line with the medial aspect of the intercondylar notch for instrumentation and suture management (Figure 1). With the arthroscope in the AM portal, a curved suture hook (Spectrum II, Conmed Linvatek) was used through the AL portal to pass a single No. 1 suture through the ACL at its attachment into the bony fragment. Both the ends of this suture were retrieved through the high AM portal

thus looping the ACL at its base. This No. 1 suture was used to shuttle a No. 2 fibre wire (thread 1) through the ACL and secured in the high AM portal (Figure 2). A 2cm vertical incision was made on the anteromedial surface of the tibia beginning 3 cm distal to the joint line. Using the ACL tip aimer guide (Acufex, Smith and Nephew) placed through the AM portal, four 1mm wires were drilled through the external portion of the guide into the fracture crater, maintaining a 10mm bone bridge (Figure 3), as follows: posterolateral (pl) and posteromedial (pm) wires were drilled just lateral and medial to the ACL respectively, at the point where it was looped. The anteromedial (am) and anterolateral (al) wires were drilled in the anterior part of the fracture crater in relation to the anterior horn of the medial and lateral meniscus (Figure 4). A 3.5 mm arthroscopic reamer was used to ream over these wires to create four tunnels (pl, pm, am and al). The tips of the wires were covered with a scoop to prevent any cartilage injury by the reamer or by the wire tips. Four suture shuttles were passed into the joint from the anteromedial tibial incision, one through each of the tunnels, using a beath pin (Figure 5). Each suture shuttle was of different colour to aid in suture management. All the suture shuttles were retrieved through the high AM portal. Using these suture shuttles, four no. 2 fibre wires (thread 1, 2, 3 and 4), including the one previously passed through the ACL base, were shuttled through the four tunnels to create a suture bridge over the ACL tibial avulsion fracture fragment (Figure 6). Care was taken to ensure that the fibre wire passed through the ACL base initially (thread 1) was shuttled from the pm to the pl tunnel. Thus a suture bridge was created by virtue of the four fibre wires passing from one tunnel to the other over the ACL tibial avulsion fragment as follows: thread 1– from pm to pl tunnel; thread 2– from pl to am tunnel; thread 3– from pm to al tunnel and thread 4– from am to al tunnel (Figure 7). The free ends of the four fibre wires were pulled out through the anteromedial tibial incision. The ACL tibial avulsion fragment was reduced using an arthroscopic probe and the fibre wires were synched and knotted over the anteromedial bone bridge. Thread-1 was tied first followed by thread- 2 and 3 and thread- 4 was tied last. All the threads were tied over the anteromedial bone bridge. In case the external opening of two tunnels coalesced then a titanium endobutton was used over which the threads were tied. The knee was taken through a range of motion to confirm the stability of fixation and any anterior impingement.

Postoperatively the knee was placed in a long knee brace and ankle pump exercise, static quadriceps sets, active straight leg raises were started immediately after surgery. Active knee bending was started as per pain relief, usually from the 2nd postoperative day. The patients were mobilised non weight bearing till 6 weeks postoperatively. Bed side knee bends and prone knee bends are started after 4 weeks. Full weight bearing with long knee brace was allowed after 6 weeks. The long knee brace was discontinued after 2 months. The patient

is allowed running, jumping and sporting activities after 6 months. Postoperative data recording was done on the 3rd and 6th month follow up as follows: patient complaints of pain, locking, clicking, sensation of giving way and swelling; clinical examination for tenderness, range of motion, McMurray’s test and tests for instability and Lysholm knee score.

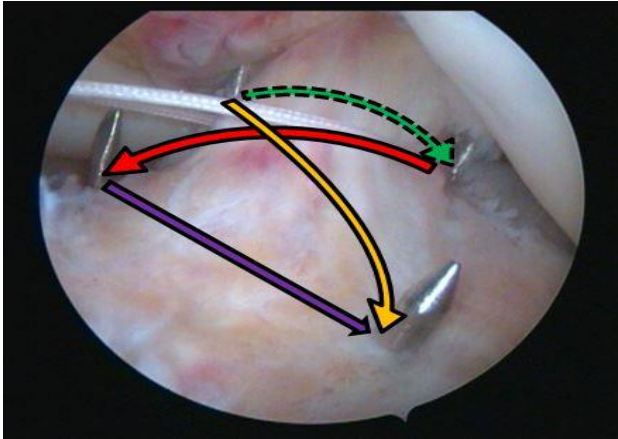


Figure 6: Pattern of suture shuttling through the 4 tunnels to create a suture bridge.

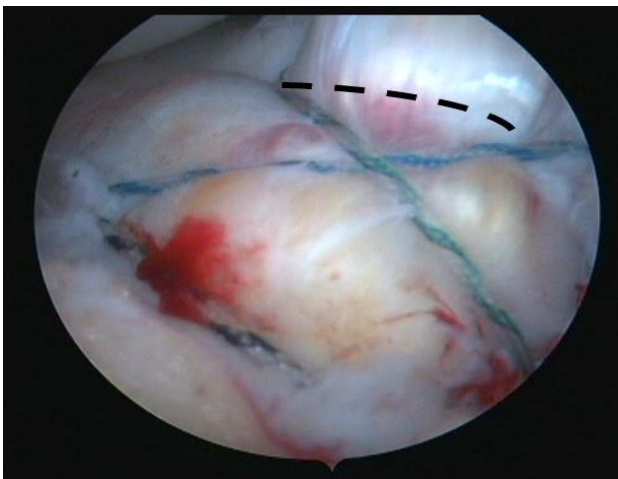


Figure 7: The final “suture bridge” construct.

At latest follow up, patient satisfaction with respect to knee pain, range of motion, stability and return to previous activity level was noted.

RESULTS

Of the twelve patients included in the study, 9 were males and 3 were females (Figure 8) having a mean age of 25.5 years (range: 14 to 45 years) (Figure 9). The left knee was involved in 4 cases and the right knee in 8 cases (Figure 10). All the patients had a twisting knee injury following which their knee complaints started. Five patients had a road traffic accident (RTA), five had a twisting injury due to a fall and two patients had a twisting injury during a sporting activity (Figure 11). Ten

patients presented acutely at an average time of 1.8 weeks (range: 1 to 4 weeks) from injury. Two patients had a delayed presentation at 24 and 32 weeks post injury.

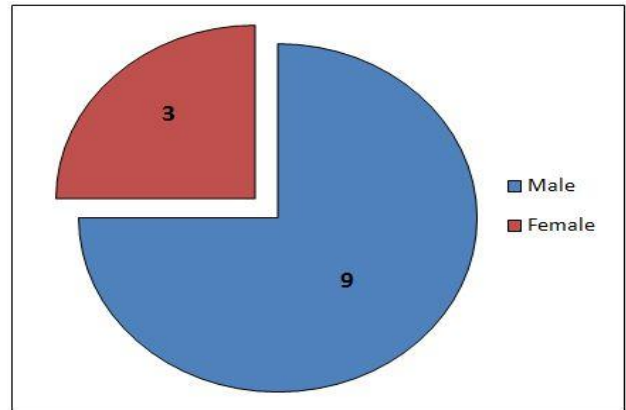


Figure 8: Sex distribution of the study.

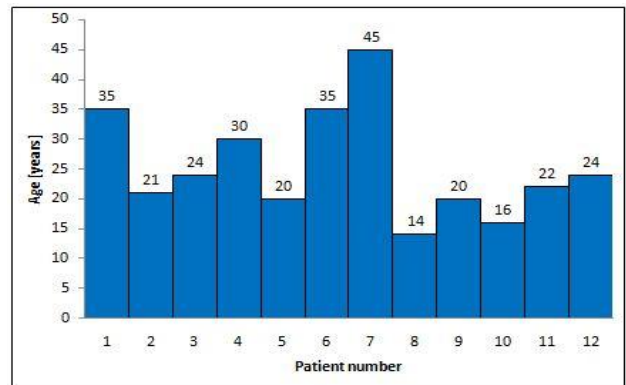


Figure 9: Age distribution of the study.

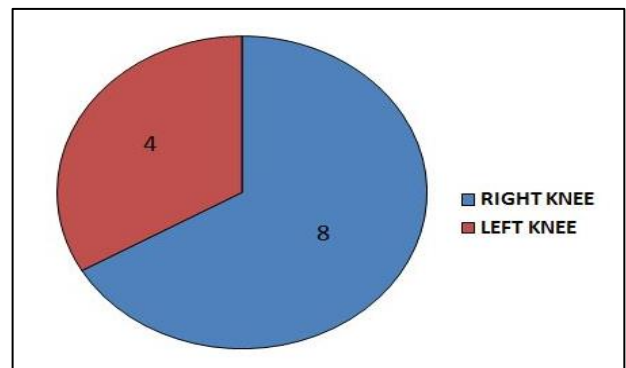


Figure 10: Side distribution of the study.

All patients presented with chief complaints of knee pain. The two patients who presented late complained of locking, clicking and sensation of giving way while walking. One patient who presented acutely complained of clicking from the knee. All the patients who presented acutely had knee swellings. All the patients had anterior knee joint line tenderness. The two patients with delayed presentation had full knee range of motion. The mean knee range of motion of the patients who presented

acutely was 60 degrees (range: 30 to 120 degrees). Mc Murray’s test was positive in only one patient. This test was not performed for the patients who presented acutely. Anterior drawer test was performed in 2 patients and was positive (grade 3) in both. Lachman’s test was performed in all the patients and was positive in all (grade 3: n=7, grade 2: n=5). The pre-operative Lysholm knee score was not calculated for the patients with acute presentation. The pre-operative Lysholm knee score for the two patients who had a delayed presentation was 41 and 50.

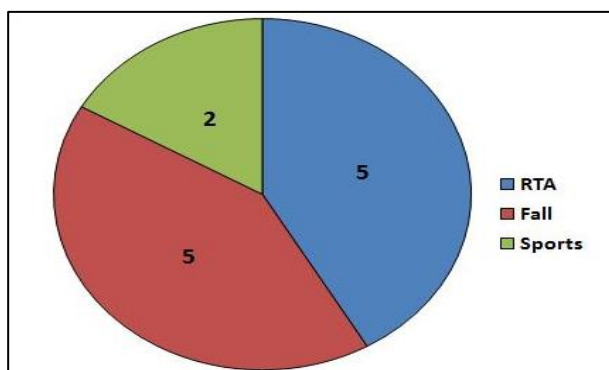


Figure 11: Distribution of mechanism of injury.

On X-ray of the knee, 1 patient had type 2, 7 patients had type 3 and 4 patients had type 4 tibial ACL avulsion fractures. MRI of all patients showed an intact ACL with one patient having a medial meniscus and one patient having a lateral meniscus tear.

Diagnostic arthroscopy confirmed the findings of tibial ACL avulsion fracture with an intact ACL in all the patients. None of the patients had any chondral lesions. One patient had a lateral and one patient had a medial meniscus tear.

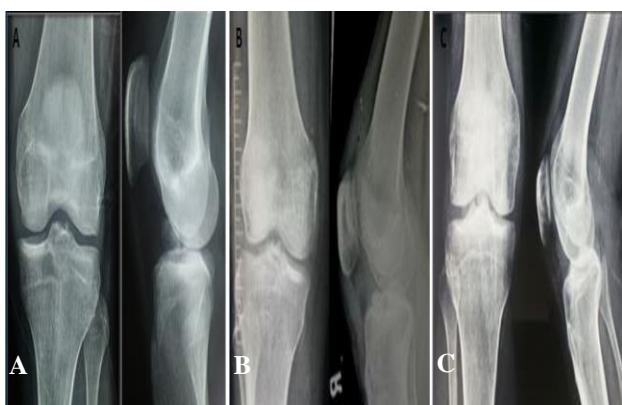


Figure 12: X-ray of a knee with ACL tibial bony avulsion. (A) pre-operative x ray; (B) post-operative x-ray; (C) 2 months post-operative X-ray.

All the fractures united and all patients achieved full knee range of motion by 2 months post operatively (Figure 12).

At 3 months follow up, 5 patients complained of pain in the knee. Two patients complained of clicking from the knee while bending. Two patients had knee effusions in postoperative period which settled down with exercise restriction and anti-inflammatory medications [indomethacin (25 mg), three times daily] for three days. None of them complained of sensation of giving way. Three patients had anterior knee joint line tenderness. Mc Murray’s test, anterior drawer test and Lachman’s test were negative in all the patients. The 3 month follow up mean Lysholm score was 88.8.

At 6 months follow up, only one patient had intermittent knee pain. None of the patients had any knee locking or sensation of giving way. One patient had intermittent knee clicking and one patient had occasional knee swelling which resolved on the medication mentioned previously. All of them had full knee range of motion. Knee joint line tenderness, McMurray’s test, anterior drawer and Lachman’s test were negative for all the patients. The 6 month follow up mean Lysholm score was 98.8 (Figure 13).

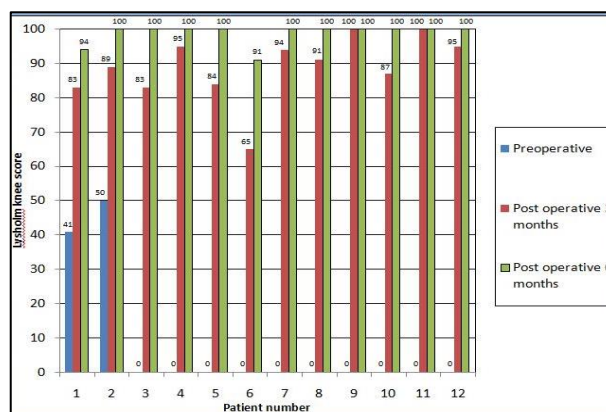


Figure 13: Lysholm knee score of patients in the study.

At latest follow up all the patients were satisfied with their knee function with respect to pain, range of motion and stability and had resumed their previous level of activities.

DISCUSSION

Displaced ACL tibial avulsion fractures (Meyers and McKeever type 2, 3 and 4) need operative intervention as immobilization fails to obtain reduction of the fracture fragment into its crater as the fracture is in the non-articular part of the knee (intercondylar notch) and not in the tibio-femoral articulation.⁴ Malunited or non-united ACL tibial avulsion fractures can cause anterior instability and restricted knee range of motion.^{5,6} Anterior instability occurs because the ACL remains lax due to no tibial bony attachment. Restricted knee range and occurs due to anterior impingement of the bony fragment in terminal extension.⁴ Two patients in this study who had a

delayed presentation complained of instability in form of sensation of giving way and had Lachman's test positive on examination.

Arthroscopic reduction and internal fixation is the preferred treatment option for displaced ACL tibial avulsion fractures. The arthroscopic techniques have the advantage of being minimally invasive resulting in minimal scarring of the fat pad and the retro patellar tendon space, thus reducing the chances of post-operative stiffness. In the present study all the patients achieved full knee range of motion by two months post operatively. The arthroscopic techniques also provide magnified and illuminated vision of the intercondylar notch thus enabling accurate reduction and secure fixation. It also provides an opportunity to identify and treat any other associated intra articular pathology. In the present study two out of the twelve patients had associated meniscal tears which were identified and addressed arthroscopically in the same surgical setting.

A variety of fixation techniques have been used to fix these fractures arthroscopically, some of them being screw (antegrade, retrograde), K-wires, wire loops, staples, suture anchors and sutures.^{2,3,7,8} Most of the ACL tibial avulsion fractures are just a sliver of bone being held together by the fibres of the ACL. The fracture bed is of poor bone quality due to the fracture. Invariably comminution is noted arthroscopically even in type 2 and 3 fractures. Although Tsukada et al reported that antegrade screw fixation was more effective to obtain initial rigid fixation than pull out suture fixation for ACL avulsion fractures, we believe that this technique requires drilling of the bony fragment which can cause its comminution.⁴ Veselko and Senekovik reported fixing thirty two fractures with cannulated screws and washers. Fixing comminuted fracture with screw and washer was technically impossible.⁷ Yip et al have mentioned that the bony components in avulsion injuries are very small and cancellous and thus the purchase of screws or wires is unreliable.⁹ There is risk of screws backing out into the joint, posterior neurovascular injury, extension block by the screw head or washer during the postoperative period and need for hardware removal after 8 to 10 weeks.^{4,8} Use of single or multiple staples have the same disadvantage as that of screws and they are placed in the fractured bone bed which has poor hold for implants. Sundararajan et al reported backing out of a staple in one out of twenty two patients in their study.² They advocated staple removal in case of radiological loosening or back out. The use of multiple suture anchors does give multiple points of fixation but there is a possibility of pullout of the anchors.³ K-wires have insecure fixation and there is possibility of migration. All metal implants can affect future knee imaging due to metal artefacts and can interfere with any other future knee surgery.

The use of pull through sutures to fix the ACL tibial avulsion fracture has many advantages compared to the previously discussed metal fixation options. Huang et al

mentioned that suture fixation techniques do not require further surgery for implant removal.³ The sutures hold the fragment at the bone–ligament interface and thus have very good hold even in comminuted fractures.⁶ The use of sutures does not need drilling of the fragment and thus can be used even in comminuted fractures and gives secure fixation as they are tied over the anteromedial tibial cortical bony bridge. Multiple sutures can be used for fixation of the bony fragments. Sutures do not cause any artefact in future imaging nor interfere with any future knee surgery.³

Sutures are commonly used in a Figure of 8 configuration where two tunnels are drilled from the anteromedial tibia into the knee joint, anteromedial and anterolateral to the fracture fragment.⁶ Single or multiple sutures are passed around the ACL and passed into these tunnels with or without crossing anterior to the ACL. The suture ends are then synched and tied over the anteromedial tibial cortical bone bridge thus obtaining secure reduction and fixation of the ACL tibial avulsion fracture. We have noted that as the sutures are tightened, the anterior part of the ACL tibial avulsion fracture fragment gets elevated. This is because the sutures pass immediately anterior to the ACL and there is no compression over the anterior part of the fracture fragment. This can cause malunion of the anterior part of the fracture fragment and impingement on extension. Another disadvantage of this configuration is that as the sutures are tightened, the ACL fragment can displace anteriorly due to pull of the sutures around the ACL towards the anteriorly placed tunnels. This can overtighten the ACL and can cause post-operative restriction in the knee range of motion. The suture “bridge” pull out technique while retaining all the advantages of use of sutures for fixation, overcomes the above mentioned shortcomings of the Figure of 8 configuration. Four tunnels are drilled from the anteromedial tibia into the fracture crater in relation to the ACL tibial fracture fragment as follows: posterolateral (pl), posteromedial (pm), anteromedial (am) and anterolateral (al) (Figure 4). Four sutures are then passed through these tunnels and the free ends are secured over the anteromedial tibia as follows: thread- 1 from pm to pl tunnel, thread- 2 from pm to al tunnel, thread- 3 from pl to am tunnel and thread- 4 from am to al tunnel– thus creating a bridge of sutures over the tibial ACL fragment, similar to the suture bridge construct used for rotator cuff repair in the shoulder. The first suture (thread 1), is passed through and not around the ACL and tied first as it compresses the fragment into the fracture crater. This prevents anterior translation of the fracture fragment and over tightening of the ACL. Thread- 2 and 3 are then tied, further providing compression across the fracture. Finally thread- 4 is tied as this suture provides compression in the anterior part of the fracture fragment and prevents its elevation. This suture construct provides uniform compression and very secure fixation of the tibial ACL avulsion fracture.

Most common complications after arthroscopic fixation of ACL bony avulsion are non-union, arthrofibrosis, infection and motion limitation³. In the present study we used the suture “bridge” technique which provides uniform compression across the fracture and hence we did not have any non-union in our series. We started knee range of motion immediately after surgery as the “suture bridge” configuration provided secure fixation and hence we did not have any case of arthrofibrosis in our series. There is no elevation of the anterior part of the fragment and hence there is no impingement in extension. There is no anterior translation of the ACL tibial fragment and no overextension of the ACL and hence there is no restriction in the knee range of motion postoperatively.

Limitation of the study

The drawbacks of the present study are the small number of patients. There may also be concerns about drilling four tunnels across open physes in children having these fractures. We do not advocate using this technique in children as drilling four tunnels can cause physeal injury and the small knee size may not accommodate four tunnels.

CONCLUSION

The present study was a small attempt to study the clinical results of fixation of ACL tibial avulsion fractures using a new technique. The arthroscopic suture “bridge” pull out technique is an effective method for fixation of anterior cruciate ligament tibial avulsion fractures with respect to knee stability, range of motion and resumption of pre injury activity level.

Funding: No funding sources

Conflict of interest: None declared

Ethical approval: Not required

REFERENCES

1. Gans I, Baldwin KD, Ganley TJ. Treatment and management outcomes of tibial eminence fractures in pediatric patients. A systematic review. Am J Sports Med. 2014;42(7):1743-50.
2. Sundararajan SR, Rajasekaran S, Bernard SL. Displaced anterior cruciate ligament avulsion fracture: Arthroscopic staple fixation. Indian J Orthop. 2011;45(4):324-9.
3. Huang TW, Hsu KY, Cheng CY. Arthroscopic suture fixation of tibial eminence avulsion fractures. Arthroscopy. 2008;24(11):1232-8.
4. Tsukada H, Ishibashi Y, Tsuda E. A biomechanical comparison of repair techniques for anterior cruciate ligament tibial avulsion fracture under cyclic loading. Arthroscopy. 2005;21(10):1197-201.
5. Horibe S, Shi K, Mitsuoka T. Nonunited Avulsion Fractures of the Intercondylar Eminence of the Tibia. Arthroscopy. 2000;16(7):757-62.
6. Zhao J, Huangfu X. Arthroscopic treatment of nonunited anterior cruciate ligament tibial avulsion fracture with figure-of-8 suture fixation technique. Arthroscopy. 2007;23(4):405-10.
7. Veselko M, Senekovic V. Simple and safe arthroscopic placement and removal of cannulated screw and washer for fixation of tibial avulsion fracture of the anterior cruciate ligament. Arthroscopy. 1996;12:259-262.
8. In Y, Kim JM, Woo YK. Arthroscopic fixation of anterior cruciate tibial avulsion fractures using bioabsorbable suture anchors. Knee Surg Sports Traumatol Arthrosc. 2008;16(3):286-9.
9. Yip DKH, Wong JWK, Chien EP. Arthroscopic surgery in the posterior compartment of the knee: Suture fixation of anterior and posterior cruciate ligament avulsions. Arthroscopy. 2003;19(3):1-4.

Cite this article as: Patel MR, Butala UK, Thakor NS, Bansod RR, Dhotre RA. Arthroscopic fixation of anterior cruciate ligament tibial avulsion fractures: the suture “bridge” pull out technique and evaluation of results. Int J Res Orthop 2017;3:979-85.