

Original Research Article

Study comparing the efficacy of platelet rich plasma versus steroid versus placebo in lateral epicondylitis

Ganesh Kumar Reddy Mundla*, Praveen Kumar Venkataramana,
Manoj Kumar Reddy Koduru, Biju Ravindran

Department of Orthopaedics, Narayana Medical College and Hospital, Nellore, Andhra Pradesh, India

Received: 18 January 2017

Accepted: 06 February 2017

*Correspondence:

Dr. Ganesh Kumar Reddy Mundla,

E-mail: ganeshkumarreddym@yahoo.com

Copyright: © the author(s), publisher and licensee Medip Academy. This is an open-access article distributed under the terms of the Creative Commons Attribution Non-Commercial License, which permits unrestricted non-commercial use, distribution, and reproduction in any medium, provided the original work is properly cited.

ABSTRACT

Background: Lateral epicondylitis is seen more commonly in non-athletes than athletes. Non-operative methods are the mainstay of treatment being effective in more than 95% of cases. Platelet rich plasma (PRP) has shown promising results in many studies as compared to steroid injection & other modes of conservative management. Hence, this study was done to evaluate PRP efficacy in our clinical setup and in the people of age group most commonly being affected.

Methods: This randomized study was conducted at Narayana Medical College Hospital, Nellore, for a period of two years from December 2014 to June 2016 on 150 consenting patients diagnosed as suffering from lateral epicondylitis. Using lottery method for randomization the patients were divided into three groups, based on which the treatment was received. Group-N with 50 patients received 3 ml of normal saline as placebo. Group-P with 50 patients received 3 ml of extracted PRP injection. Group-S with 50 patients received depot preparation of 40 mg of methyl prednisolone injected into the affected area. The data collected and recorded in the appropriate proforma. Post therapy assessment was done using with Oxford elbow score.

Results: The overall mean ages of the patients in the three groups (Group P, Group S and Group N) are 38.62 ± 7.53 , 37.82 ± 7.79 and 36.3 ± 6.93 respectively. Female preponderance was observed in all the groups. Most common presenting complaint was elbow pain seen in 100% of cases. Most common side involved was the dominant side, right side involvement was seen in 136 cases and left side in 14 cases. The Oxford elbow score pre-treatment in all the groups was not statistically significant and the Oxford elbow score at the end of 12 weeks and 24 weeks treatment showed that PRP and steroid was better than normal saline in control of pain.

Conclusions: Lateral epicondylitis or tennis elbow is a painful debilitating condition of elbow, which creates disturbance in functional activities. A single injection of PRP at the site of the elbow pain resulted in relief of pain in patients with longer duration as compared to local steroids to other conservative treatments.

Keywords: Tennis elbow, Platelet rich plasma, Steroid, Lateral epicondylitis

INTRODUCTION

Lateral epicondylitis commonly known as tennis elbow, remains one of the most perplexing disorders of musculoskeletal system. It is thought to result from overuse or repetitive micro-trauma resulting in a primary tendonosis of extensor carpi radialis brevis (ECRB) muscle with or without involvement of extensor

digitorum communis (EDC) and extensor carpi radialis longus (ECRL). Repeated dorsiflexion or pronation and supination are the most common aetiological factor.¹

Many treatment options are available like use of NSAIDS, steroid injections, physiotherapy but all these have short term relief.^{2,3} Now-a-days, injections of platelet rich plasma (PRP) was proved to be efficacious

treatment. PRP is a good source of many growth factors & cytokines like PDGF, TGF-beta, IGF-1, IGF-2, FGF, VEGF, EGF, keratinocyte growth factors & connective tissue growth factors and found to be one of the new way of treating this painful & disabling condition.⁴

PRP is a concentrate of platelets derived from the patient's own blood. The mechanism of action of PRP therapy in chronic tendinopathies is varied and hypothesized to include angiogenesis, increase in growth factor expression and cell proliferation, increase the recruitment of repair cells and tensile strength. PRP owing to its high content of various growth factors it is found to be more efficacious as a healing agent. However, studies on lateral epicondylitis with PRP treatment have yielded inconclusive results.⁵⁻⁷

Hence, this study was conducted with an aim to explore the efficacy of PRP in patients of tennis elbow in our study place and in the age group most commonly being affected. The main objective of the study was to compare the efficacy of local injection of PRP versus corticosteroids in terms of pain relief assessed by Oxford elbow score.

METHODS

This single blind randomized study was conducted at Narayana Medical College Hospital for a period of two years from December 2014 to June 2016 on 150 consenting patients of being diagnosed as suffering from tennis elbow/lateral epicondylitis who fulfilled a pre-determined the inclusion & exclusion criteria. The study was initiated after obtaining an ethical clearance from the institution's ethical clearance committee. A written informed consent was taken from the patient or a legal heir before recruiting the patients to the study.

Patients of age group 20-40 years of both the sexes with symptoms typical to lateral epicondylitis with clinically diagnosed as suffering from tennis elbow were included in the study.

Patients more than 40 years or less than 20 years old, patients suffering from elbow pain due to other causes like rheumatoid arthritis, osteochondritis dissecans, crystal arthropathies like gout, radial tunnel syndrome, cervical lesions, shoulder pathology, patients already treated by steroid injection, patients already undergone surgical intervention and any local skin pathology at injection site were excluded from the study.

Using lottery method patients were randomized into three groups consisting 50 patients in each based on which the treatment was received.

- Group P: 50 patients received 3 ml of the extracted PRP into the affected area
- Group S: 50 patients received 40 mg of depot methyl prednisolone into the affected area.

- Group N: 50 patients received 3 ml normal saline into the affected area.

Autologous PRP preparation

Autologous PRP was prepared using the platelet separation system in accordance with the manufacturer guideline. With an 18 G needle, 54 ml of venous blood collected from the participant's cubital vein and transferred into a 60 ml syringe primed with 6 ml of anticoagulant citrate dextrose solution.

Another 2 ml of the venous blood collected and sent to the hospital laboratory for determination of platelets and leucocytes count. The collected blood was transferred into the disposable separation tube and spun using a centrifuge at 3200 rpm at room temperature for 15 minutes.

Centrifugal force separates the blood components into three distinct layers based on their particular densities. The heaviest particles, the red blood cells sunk at the bottom of the tube, the least dense constituents the platelet-poor plasma (PPP) move to the top of the tube, while the platelet-rich plasma (PRP) remained at the centre. The whole PPP was extracted into a 30 ml syringe and discarded. Following this, PRP was extracted into a 10 ml syringe. Since an acidic anticoagulant (anticoagulant citrate dextrose solution – solution A [ACD-A]) was added during the collection of venous blood, collected PRP is buffered to increase the pH to normal physiological levels, just before injection. This is accomplished by adding 8.4% sodium bicarbonate solution in a ratio 0.05 ml of sodium bicarbonate to 1 ml of PRP. No activating agent was added to the PRP before administration. The time taken to prepare PRP is about 30 minutes.

After assessment of baseline parameters, the patients were given treatment according to their allotted group and they were evaluated with Oxford elbow score at the time of getting the injection, at the end of 12 weeks and at the end of 24 weeks.⁸

After the injection for pain relief paracetamol/paracetamol with tramadol was used in all the groups for the first day following which only paracetamol (500 mg) tablets were allowed as rescue medication for a maximum period of one week. Post treatment physiotherapy was also same in all the groups.

Post injection protocol

Patients are instructed to limit extensive use of their upper limb for the next 24 hours and to use pain medication only if necessary.

The data was collected and recorded in an appropriate proforma and then transferred to a master chart and then analyzed for statistical significance.



Figure 1: Locating the site of injection for tennis elbow.

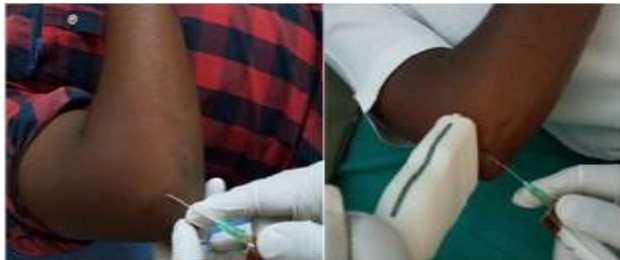

Figure 2: Patient receiving local platelet rich plasma injection.

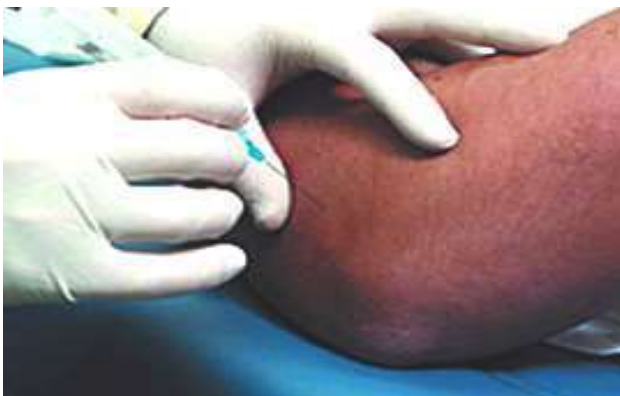

Figure 3: Patient receiving depot preparation of methyl prednisolone.

RESULTS

The 150 patients participated in the study were divided into three groups consisting 50 in each. Lateral epicondylitis was the common presenting symptom in all the study participants. The overall mean ages of the patients in the three groups (Group P, Group S and Group N) are 38.62 ± 7.53 , 37.82 ± 7.79 and 36.3 ± 6.93 respectively with a p value 0.94 that was not statistically significant as shown in Figure 4.

Gender distributions of the patients in all the three groups are tabulated in Table 1. Females preponderance seen in all the groups.

In the present study, right side elbow was dominantly affected in most of the cases in all the three groups compared to left side elbow as given in Table 2 and this difference was not significant statistically ($p = 0.99$).

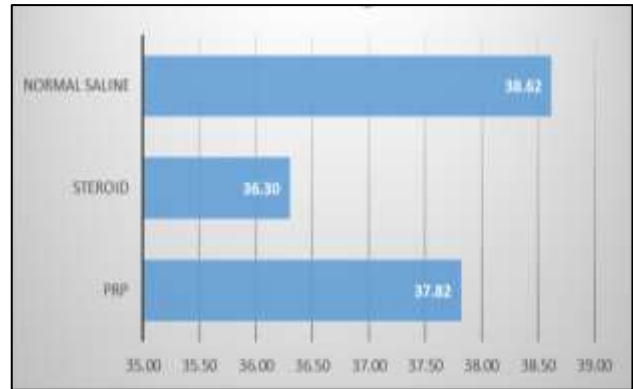


Figure 4: Age distribution of the study participants.

Table 1: Gender distribution of the study participants.

Group		Number of patients	Percent	P value
Normal saline	Females	38	76	0.889
	Males	12	24	
	Total	50	100	
PRP	Females	37	74	
	Males	13	26	
	Total	50	100	
Steroid	Females	40	80	
	Males	10	20	
	Total	50	100	

Table 2: Laterality of epicondylitis in three groups.

Group		Number of patients	Percent
Normal saline	Left	6	12.0
	Right	44	88.0
	Total	50	100.0
PRP	Left	4	8.0
	Right	46	92.0
	Total	50	100.0
Steroid	Left	4	8.0
	Right	46	92.0
	Total	50	100.0

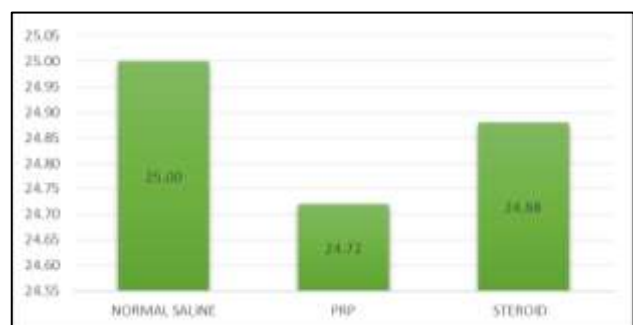

Figure 5: The Oxford elbow score before treatment.

The Oxford elbow score before treatment in the normal saline, steroid, and the PRP groups respectively are 25 ± 4.3 , 34.88 ± 4.6 and 31.7 ± 3.4 and on comparison the difference was found to be not significant ($p = 0.81$) and the same was presented in Figure 5.

Figure 6 presents the Oxford elbow score at the end of 12 weeks of treatment. It was 25 ± 4.31 , 34.3 ± 3.8 and 31.38 ± 2.88 in the normal saline, PRP and steroid groups respectively. The p value equals to 0 and is extremely statistically significant indicating that PRP is better than steroid, and steroid was better than normal saline in control of pain at the end of 12 weeks.

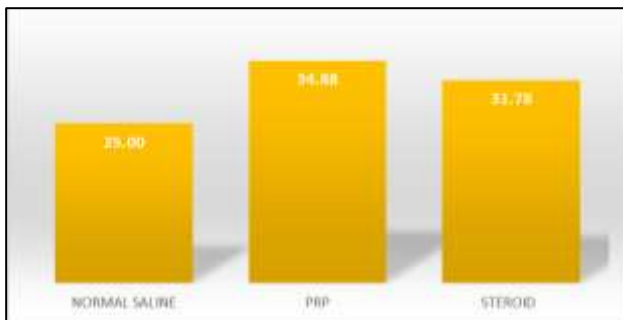


Figure 6: The Oxford elbow score at the end of 12 weeks treatment.

The Oxford elbow score at the end of 24 weeks of treatment in the steroid and the PRP groups were 31.38 ± 2.89 and 34.76 ± 3.87 respectively and the p value equals to 0 and is extremely statistically significant indicating that PRP has a better effect in control of pain than that of steroid at end of 24 weeks as shown in Figure 7.

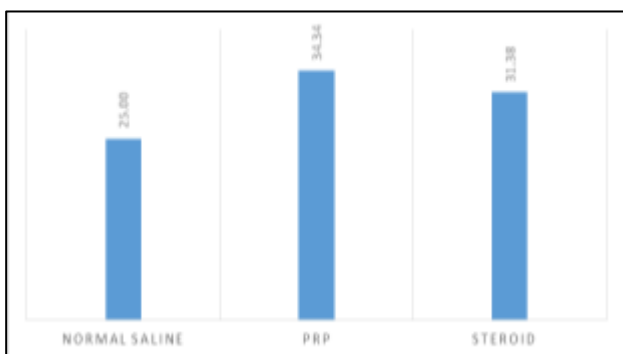


Figure 7: The Oxford elbow score at the end of 24 weeks treatment.

Table 3 presents the Oxford elbow score comparison in normal saline group at different time periods of treatment and notified that there was no statistical significant improvement in control of pain irrespective of treatment schedule.

The Oxford elbow score comparison between pre-treatment and 12 weeks & 24 weeks post treatment in

PRP group was presented in Table 4. An extremely significant ($p = 0.0001$) pain control was observed when a comparison was made in PRP group between different treatment schedules. When comparison was made for Oxford elbow score between 12 weeks and 24 weeks significant improvement ($p = 0.5324$) was not observed in control of pain.

Table 3: The Oxford elbow score comparison in the placebo group.

Placebo Group	Pre-treatment	12 weeks	24 weeks
Mean	25.00	25.00	25.00
Std. Deviation	4.314	4.314	4.314
N	50	50	50

Table 4: The Oxford elbow score comparison between pre-treatment, 12 weeks and 24 weeks treatment in PRP group.

PRP Group	Pre-treatment	12 weeks	24 weeks
Mean	24.72	35.3	34.76
Std. Deviation	4	4.01	3.17
SEM	0.57	0.57	0.45
N	50	50	50

Table 5 presents the comparative results of treatment schedule in steroid group. On comparison between the pre-treatment with 12 weeks and 24 weeks, it was observed that significant control ($p = 0.0001$) of pain was achieved at the end of 12 and 24 weeks treatment and by comparing 12 weeks and 24 weeks, the control of pain was almost similar and the p value was found to be 0.5324 which is not significant.

Table 5: The Oxford elbow score comparison between pre-treatment, 12 weeks and 24 weeks treatment in steroid group.

Steroid Group	Pre-treatment	12 weeks	24 weeks
Mean	24.88	31.78	31.38
Std. Deviation	4.04	3.46	2.9
SEM	0.57	0.49	0.41
N	50	50	50

DISCUSSION

Lateral epicondylitis (LE) or tennis elbow is an important condition of the upper extremity with an incidence of up to 4-7/1000 patients per year, having a substantial impact on athletes and workers.⁹⁻¹² Many treatment regimens are available. NSAIDs and corticosteroids are used in traditional medicine but found to be not effective in long

term. Physiotherapy had shown some improvement though a sub-cohort of patients remain refractory.^{1,3} But now-a days, Polidocanol, prolotherapy, autologous whole blood and PRP injection therapies have reported promising outcomes for LE and other sports related tendinopathies.¹³

PRP injections consists of activated platelets which discharge bioactive signaling molecules, including three adhesion molecules and seven growth factors.¹⁴ Two large animal studies have recently reported improved healing of repaired dog and porcine cruciate ligaments following PRP therapy.^{15,16}

The current study was designed to estimate the efficacy of PRP injections and steroids at different treatment schedules. In the present study, the mean age group was 37.82 ± 7.79 and 36.3 ± 6.93 respectively in PRP and steroid groups. This was similar in the studies done by Yadav et al in which the mean age group was 36.6 and 36.7 in the two groups respectively.¹

In this study, the males affected by tennis elbow were 33 and females were 77 and the most common presenting complaint seen in 100% of cases was elbow pain. Similar female preponderance was also reported in earlier studies.^{17,18}

Chard et al and Hazelman et al stated that lateral epicondylitis involves dominant arm more frequently, this finding is similar to our study, the commoner side involved was the dominant side in which right side involvement was seen in 94 cases and left side in 6 cases.^{19,20}

In our study the Oxford elbow score pre-treatment in the steroid and the PRP groups were similar with the p value equals 0.8428 not statistically significant but there was a significant improvement noted in the Oxford elbow score end of 12 weeks of treatment with the p value equals less than 0.0001 extremely statistically significant indicating that PRP has a better effect in control of pain than the steroid depot end of 12 weeks, 24 weeks

Similar findings were noted in different studies by Mishra et al and Gosens et al compared the effectiveness of leukocyte enriched PRP to standard corticosteroid treatment for lateral epicondylitis and found that at short term follow up both groups showed significant improvement in pain and function.^{5,21}

Omar et al, has reported that effect of corticosteroid injections lasts for about three months while that of PRP injections last for more than 6 months in providing pain relief in tennis elbow.²²

Hechtman et al concluded that a single injection of PRP gives significant relief in recalcitrant cases of lateral epicondylitis which is comparable to our study.²³ Gosens et al in his study, stated that the recurrence rate and need

for repeated injection or surgery was also larger higher in the corticosteroid group than in the PRP group.²¹

Andia et al studied thirteen prospective controlled studies, comprising of 886 patients which includes diverse tendons.²⁴ 53.8% of studies used identical PRP protocol and they concluded that irrespective of findings of the PRP administration, critical issues such as optimal volume and numbers of injections are still unclear. The effect of PRP could essentially stem from the needle penetration in combination with injection of a relatively high volume and notified that saline has no effect in painful lesions.

Limitations of the study

The study duration was for two years the tennis elbow is a self-limiting and recurrent disease, the study term was short as to study the recurrences which is the main drawback of this study.

CONCLUSION

The results revealed that the long term efficacy of PRP treatment is better. Therefore, we concluded PRP as a superior treatment option in cases of tennis elbow.

Funding: No funding sources

Conflict of interest: None declared

Ethical approval: The study was approved by the institutional ethics committee

REFERENCES

1. Yadav R, Kothari SY, Borah D. Comparison of Local Injection of Platelet Rich Plasma and Corticosteroids in the Treatment of Lateral Epicondylitis of Humerus. J Clin Diagn Res. 2015;9(7):5-7.
2. Croisier JL, Foidart-Dessalle M, Tinant F, Crielaard JM, Forthomme B. An isokinetic eccentric programme for the management of chronic lateral epicondylar tendinopathy. Br J Sports Med. 2007;41:269-75.
3. Buchbinder R, Green SE, Youd JM, Assendelft WJ, Barnsley L, Smidt N. Shock wave therapy for lateral elbow pain. Cochrane Database Syst Rev. 2005;4:CD003524.
4. Borriore P, Gianfrancesco AD, Pereira MT, Pigozzi F. Platelet-rich plasma in muscle healing. Am J Phys Med Rehabil. 2010;89(10):854-61.
5. Mishra A, Pavelko T. Treatment of chronic elbow tendinosis with buffered platelet-rich plasma. Am J Sports Med. 2006;34(11):1774-8.
6. Mishra A, Collado H, Fredericson M. Platelet-rich plasma compared with corticosteroid injection for chronic lateral elbow tendinosis. PMR. 2009;1(4):366-70.

7. Raeissadat SA, Rayegani SM, Hassanabadi H, Rahimi R, Sedighipour L, Rostami K. Is Platelet-rich plasma superior to whole blood in the management of chronic tennis elbow: one year randomized clinical trial. *BMC Sports Sci Med Rehabil.* 2014;18(6):12.
8. Dawson J, Doll H, Boller I, Fitzpatrick R. The development and validation of a patient-reported questionnaire to assess outcomes of elbow surgery. *J Bone Joint Surg Br.* 2008;90:466-73.
9. Hamilton P. The prevalence of humeral epicondylitis: a survey in general practice. *J R Coll Gen Pract.* 1986;36:464-5.
10. Kivi P. The etiology and conservative treatment of humeral epicondylitis. *Scand J Rehabil Med.* 1983;15:37-41.
11. Ono Y, Nakamura R, Shimaoka M, Hiruta S, Hattori Y, Ichihara G, et al. Epicondylitis among cooks in nursery schools. *Occup Environ Med.* 1998;55:172-9.
12. Ritz BR. Humeral epicondylitis among gas and waterworks employees. *Scand J Work Environ Health.* 1995;21:478-86.
13. Struijs PA, Smidt N, Arola H, Dijk VC, Buchbinder R, Assendelft WJ. Orthotic devices for the treatment of tennis elbow. *Cochrane Database Syst Rev.* 2002;1:CD00182.
14. Everts PA, Knape JT, Weibrich G, Schönberger JP, Hoffmann J, Overvest EP, et al. Platelet-rich plasma and platelet gel: a review. *J Extra Corpor Technol.* 2006;38:174-87.
15. Anitua E, Andía I, Sanchez M, Azofra J, del Mar Zaldueño M, de la Fuente M, et al. Autologous preparations rich in growth factors promote proliferation and induce VEGF and HGF production by human tendon cells in culture. *J Orthop Res.* 2005;23:281-6.
16. Murray MM, Spindler KP, Abreu E, Muller JA, Nedder A, Kelly M. Collagen-platelet rich plasma hydrogel enhances primary repair of the porcine anterior cruciate ligament. *J Orthop Res.* 2007;25:81-91.
17. Nirschl RP, Pettrone FA. Tennis elbow. The surgical treatment of lateral epicondylitis. *J Bone & Joint Surg.* 1979;61(6):832-9.
18. VCIII D, Milanese S, Worth D, Grimmer-Somers K. The Anatomy of the Forearm Extensor Muscles and the Fascia in the Lateral Aspect of the Elbow Joint Complex. *Anatom Physiol.* 2013;3(117):2161.
19. Chard MD, Hazleman BL. Tennis elbow—a reappraisal. *Rheumatology.* 1989;28(3):186-90.
20. Binder AI, Hazleman BL. Lateral humeral epicondylitis—a study of natural history and the effect of conservative therapy. *Rheumatol.* 1983;22(2):73-6.
21. Gosens T, Peerbooms JC, van Laar W, den Ouden BL. Ongoing Positive Effect of Platelet-Rich Plasma Versus Corticosteroid Injection in Lateral Epicondylitis: A Double-Blind Randomized Controlled Trial With 2- year Follow-up. *American J Sports Med.* 2011;39(6):1200-8.
22. Omar AS, Ibrahim ME, Ahmed AS, Said M. Local injection of autologous platelet rich plasma and corticosteroid in treatment of lateral epicondylitis and plantar fasciitis: Randomized clinical trial. *The Egyptian Rheumatol.* 2012;34:43-9.
23. Hechtman KS, Tjin-A-Tsoi EW, Zvijac JE, Uribe JW, Latta LL. Biomechanics of a less invasive procedure for reconstruction of the ulnar collateral ligament of the elbow. *American J Sports Med.* 1998;26(5):620-4.
24. Andia I, Latorre PM, Gomez MC, Burgos-Alonso N, Abate M, Maffulli N. Platelet-rich plasma in the conservative treatment of painful tendinopathy: a systematic review and meta-analysis of controlled studies. *Br Med Bull.* 2014;110(1):99-115.

Cite this article as: Mundla GKR, Venkataramana PK, Koduru MKR, Ravindran B. Study comparing the efficacy of platelet rich plasma versus steroid versus placebo in lateral epicondylitis. *Int J Res Orthop* 2017;3:207-12.