

Case Series

Multiple stab incision technique to prevent postoperative acute compartment syndrome of leg in proximal and segmental fracture tibia and fibula: a prospective study

K. Parthasarathi Naik, Shankarlinga S.*, Basavaraj S. Kyavater, Prashanthkumar M.

Department of Orthopedic, K. S. Hospital Koppal, Karnataka, India

Received: 11 September 2022

Revised: 26 September 2022

Accepted: 28 September 2022

*Correspondence:

Dr. Shankarlinga S.,

E-mail: drshankarlingsajjan@gmail.com

Copyright: © the author(s), publisher and licensee Medip Academy. This is an open-access article distributed under the terms of the Creative Commons Attribution Non-Commercial License, which permits unrestricted non-commercial use, distribution, and reproduction in any medium, provided the original work is properly cited.

ABSTRACT

The objective is to study the effectiveness of Multiple stab incision technique in preventing acute compartment syndrome (ACS) in proximal and segmental fractures of both bones (Tibia and fibula) in leg. This study is prospective done at K. S. Hospital Koppal, Karnataka spanning for a period of one year (April 2020 to April 2021). A total of 20 patients of both genders aged 20-60 years were included in the study. Multiple stab incision technique was performed in patients after fixation of Tibia by either closed nailing or MIPPO plating. This procedure was done under spinal anesthesia. Multiple stab incision technique significantly decreased the chances of post-op ACS in proximal and segmental fractures of both bones (tibia and fibula) in leg. Multiple stab incision technique is help full in preventing developing compartment syndrome.

Keywords: Multiple stab incision technique, ACS, Both bones (tibia and fibula)

INTRODUCTION

Acute compartment syndrome (ACS) is a potentially serious complication following a tibia fracture. The rates of ACS with tibia fractures ranges from 2% to 9%.¹⁻³ Compartment syndrome occurs where there is excessive swelling within a closed fascia-bone space. The elevated pressure causes a decrease in capillary blood flow due to a decrease in the pressure gradient at the microcirculation level.^{4,5} Failure to diagnose the increased pressure within the closed anatomic space associated with acute compartment syndrome may lead to devastating consequences, including nerve injury, muscle necrosis, and loss of function.⁶ Evidence suggests that fasciotomy should be performed when compartment syndrome is present, when there is suspicion that the compartment or compartments should be prophylactically treated, and when a lack of blood flow will permanently alter the patient's condition.^{7,8}

Prevalence of ACS following tibial fractures varies widely due to differing diagnostic techniques and patient samples, although young (<35 years of age) men seem to be at greatest risk.^{1-3,9} Most cases of ACS associated with tibial fractures occur in the diaphysis, though cases of ACS has resulted from a Salter Harris II distal tibia fracture caused by a skateboard accident in a boy aged 14 years and from a Pilon fracture in a man aged 19 years who was not wearing the restraints during the motor vehicle collision.^{10,11}

Typically the pain associated with ACS is disproportionate to tibial injury severity.⁶ Pain can be an unreliable or impractical indicator due to unconsciousness from a head injury, non-functioning sensory and motor nerves from a spinal injury, young patient age, variations in tolerance to discomfort, cultural mores, nerve injury, and physical location of the compartment syndrome in the body.¹²⁻¹⁴ Because of the variation in presentation and

symptoms, clinicians often use compartment pressure as a diagnostic tool. Classically there are six clinical findings in the diagnosis of compartment syndrome: (1) pain in the affected extremity, disproportionate to the injury; (2) pain induced by the stretching of the compartment muscles; (3) paresis of the muscles of the compartment; (4) hypoesthesia or paraesthesia in the topography of the nerves that run through the affected segment; (5) hardening or inflammation, or both, of the affected site; and (6) reduced or absent distal pulses.¹⁵ The most important clinical finding is hardening, strain in the affected segment (if accompanied by pain), swelling, decreased sensitivity as well as difficulty in moving the limb.¹⁶

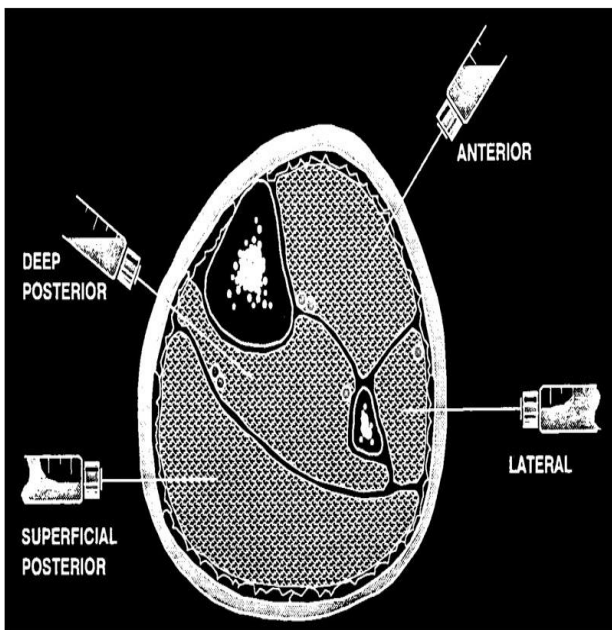


Figure 1: Compartment of leg.

Pressure measurements

Several ACS measurement devices are available, including the needle manometer and wick and slit catheters.¹⁷⁻²⁰ A hand-held portable intra-compartmental pressure monitoring system that allows assessment of compartmental pressure changes over time and an electronic ACS monitor are also commercially available. McQueen et al advocate continuous monitoring to determine whether differential pressure, or the difference between diastolic and compartment pressures, falls below a threshold level of 30 mm Hg, which is an indication of acute compartment syndrome.²¹ They found that average delays from admission to fasciotomy and from fracture manipulation/fixation to fasciotomy were significantly shorter in thirteen tibial diaphyseal fracture patients who had early monitoring than in 12 patients who had late or no monitoring.²¹ Despite the apparent clinical success championed by McQueen et al the use of continuous compartment monitoring (CCM) to heighten clinical awareness and confirmation of clinical findings is not typical in most trauma centers.⁶

Despite the advancements in compartment pressure monitoring there is not currently a gold standard for definitively determining which patients do and which do not have ACS.^{6,22} Clinical signs and symptoms and practitioner experience continue to serve as the key diagnostic criteria in most cases of ACS.¹ One of the challenges associated with diagnosing ACS is that time of injury and onset of ACS cannot be simultaneously defined.²

ACS results in a cascade of changes in inflammatory markers, including elevated white blood cell count and a positive erythrocyte sedimentation rate, yet these are nonspecific markers for the condition.²³ Creatine kinase, myoglobin, and fatty acid-binding proteins, which are found in skeletal and cardiac muscle, increase at variable times following muscle ischemia, yet are not specific enough to differentiate among muscle injury, ACS, and a cardiac event.^{24,25} Further research is needed to predictably use biomarkers in the assessment of ACS. Magnetic resonance imaging, ultrasound, scintigraphy, laser Doppler flowmetry, pulse oximetry, compartment hardness, vibratory sensation, and tissue ultrafiltration have all been shown to have only poor to moderate success in definitively predicting skeletal muscle anoxia. These methods require further study before clinicians can use them to the predictably assess acute compartment syndrome.⁶

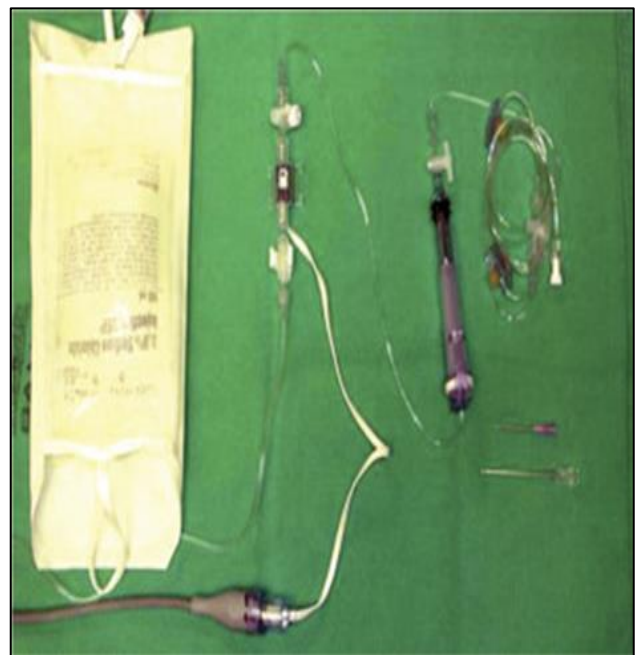

Figure 2: Whiteside's compartment pressure monitor using standard intraoperative arterial pressure monitor.

Near-infrared spectroscopy (NIRS), an optical technique, has also been tested as a method for assessment of lack of muscle oxygenation in traumatic leg injuries.²⁶ The technology for NIRS is based on relative tissue transparencies of oxygenated and deoxygenated

hemoglobin rather than through indirect compartment pressures as found in catheters, and has been a common technique to assess oxygenation during physical activity and exercise. NIRS wavelengths, though mostly of low depth, can be used to determine hemoglobin saturation and thereby may be used as a non-invasive method to determine acute compartment syndrome in superficial muscle compartments. A few studies have assessed the sensitivity of NIRS as a diagnostic tool for chronic exertional compartment syndrome, but the clinical value in assessing tibial acute compartment syndrome has yet to be shown conclusively.^{27,28}

CASE SERIES

This is a prospective study and patients were selected by using convenient method. patient who came to K.S. hospital Koppal between period of April 2020 to April 2021 with isolated leg fractures which has been diagnosed by clinically and confirmed by radiologically were included in the study (Figure 3-5). A total of 20 patients of both genders aged 20-60 years were included in the study. All patients underwent Multiple Stab Incisions placed with a 15 number blade on either side (medial and lateral) of leg after stable fixation of tibia by either nailing or by Mippro technique under spinal anesthesia (Figure 6). Post operatively patients were managed with elevation of lower limb, analgesics and IV Antibiotics for 5 days. Patients were rigorously monitored for signs of ACS-Procedure was done after obtaining informed written consent. Patients were rigorously monitored for signs of acute compartment syndrome: distal pulse, pain out of proportion, paresthesia, pain on passive stretch and Pressure symptoms.

Regular post op dressings were done on postop days 3, 6 and 9. Patients were discharged on postop day 10. patients were followed up at 6 weeks, 3 months, 6 months and a year.

Inclusion criteria included patients with age between 20-60 years both gender with proximal tibia bicondylar fractures Schatz Ker type 5 and 6 requiring bicolumnar plating and segmental tibia fractures.

Exclusion criteria excluded open fractures Gustilo Anderson classification type 2 and 3, hepatic/renal/cardio-pulmonary abnormality, bleeding diathesis and local skin infections.

For the study we enrolled twenty patients aged twenty to sixty (20-60) years, patients reviewed after 10 days of discharge for suture removal and on examination the Multiple Stab Incisions were healing well with no skin tension and wrinkles on leg seen. At the end of six weeks and three months follow up the multiple stab incisions healed well. Fractures union achieved at six months follow up. No signs of infection or going for compartment observed.

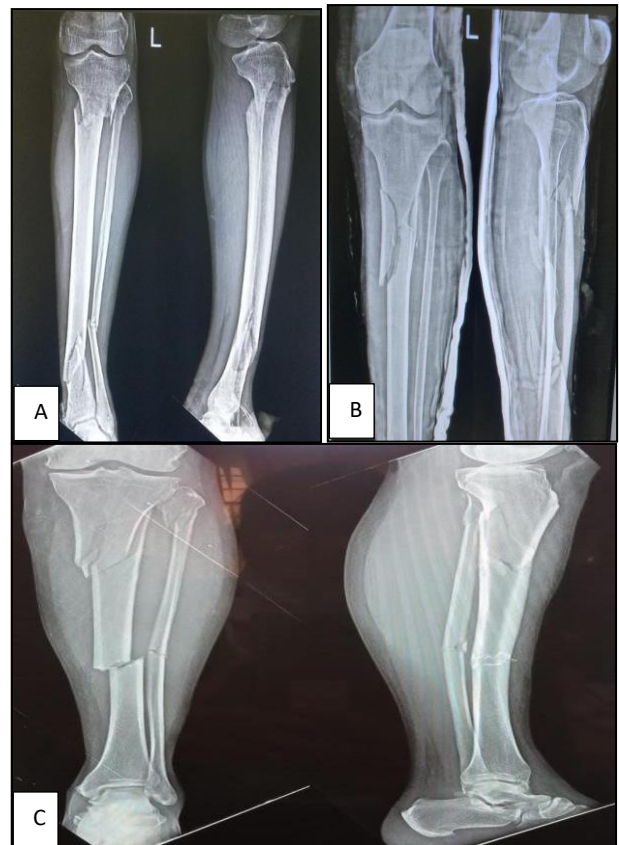

Figure 3 (A-C): Pre op X-rays of segmental fractures and comminuted proximal both bones fractures of leg.

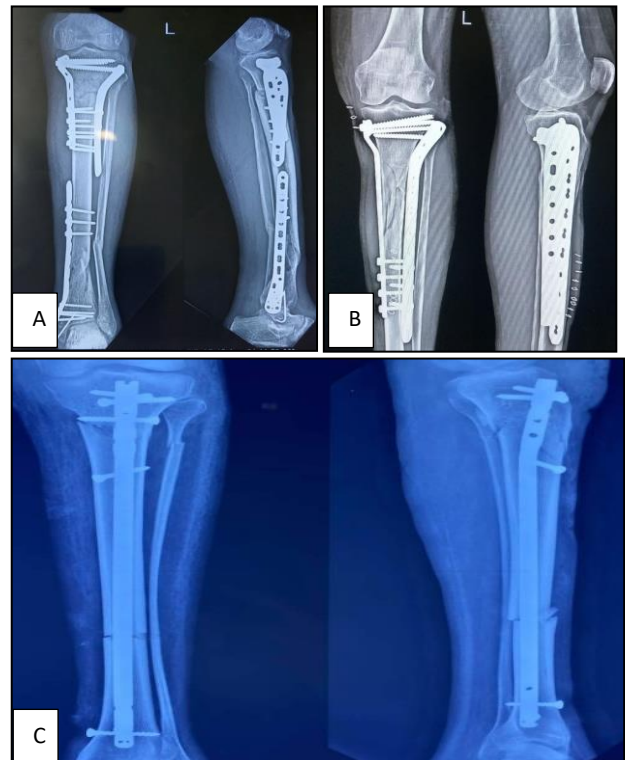

Figure 4 (A-C): Post op X-rays of ORIF with MIPPO plating of segmental and proximal tibia and interlocking nail of segmental tibia fractures.

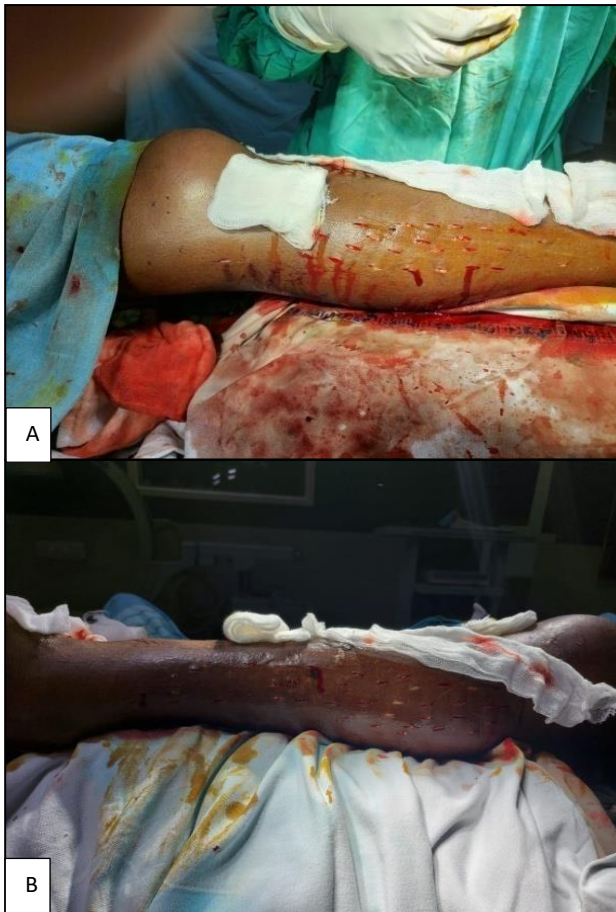


Figure 5 (A and B): Multiple stab incisions on both sides of leg.

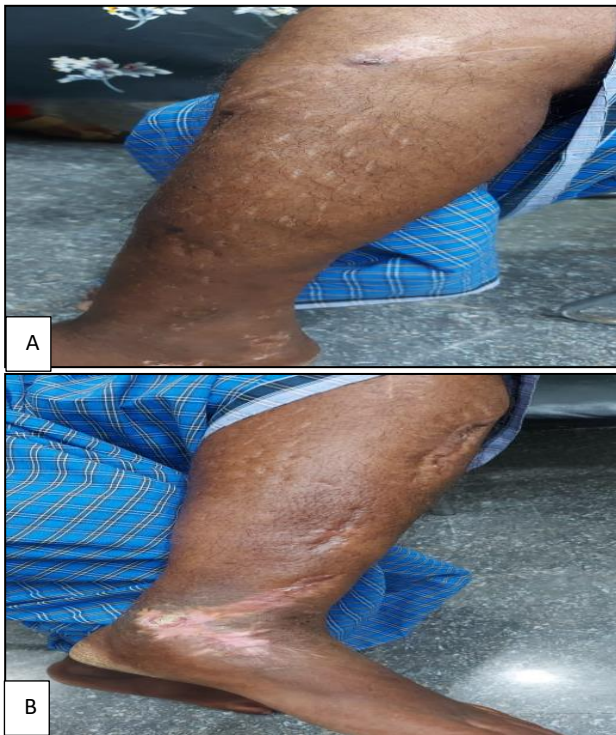


Figure 6 (A and B): Healed multiple stab incisions.

DISCUSSION

In our study we observed that multiple stab incisions technique is effective in prevention of post operative ACS by preventing easy drainage of the excessive interstitial fluid which may intern accumulate and cause rise of compartment pressure in the leg.

Reaming of tibial diaphysis will increase intra medullary pressure which in turn may cause compartment pressure, in order to prevent progression into compartmental syndrome multiple stab incisions was found to be effective in our study.²⁹

In our study we operated delayed presentation of bicolumnar proximal tibia fracture with plating (MIPPO) and multiple stab incision. We found oedema subsided along with stab incision are healing well in a week following surgery.³⁰

Although the study sample is small and this technique is yet to be studied in large number of cases over a period of time to determine its efficiency and drawbacks if any.

Limitation

Study sample size was inadequate, short duration of study and study was limited to leg which needs to apply to other parts of limb.

CONCLUSION

We conclude that multiple stab incisions technique is effective in prevention of post operative ACS.

Funding: No funding sources

Conflict of interest: None declared

Ethical approval: Not required

REFERENCES

1. DeLee JC, Stiehl JB. Open tibia fracture with compartment syndrome. Clin Orthop Relat Res. 1981;(160):175-84.
2. McQueen MM, Christie J, Court-Brown CM. Acute compartment syndrome in tibial diaphyseal fractures. J Bone Joint Surg Br. 1996;78(1):95-8.
3. Blick SS, Brumback RJ, Poka A. Compartment syndrome in open tibial fractures. J Bone Joint Surg Am. 1986;68(9):1348-53.
4. Ouellette EA. Compartment syndrome in obtunded patients. Hand Clin. 1998;14(3):431-50.
5. Har-Shai Y, Silbermann M, Reis ND. Muscle microcirculatory impairment following acute compartment syndrome in the dog. Plast Reconstr Surg. 1992;89(2):283-9.
6. Shadgan B, Menon M, O'Brien PJ, Reid WD. Diagnostic techniques in acute compartment syndrome of the leg. J Orthop Trauma 2008;22(8):581-7.

7. Sheridan GW, Matsen FA 3rd. Fasciotomy in the treatment of the acute compartment syndrome. *J Bone Joint Surg.* 1976;58(1):112-5.
8. Rorabeck CH. The treatment of compartment syndromes of the leg. *J Bone Joint Surg Br.* 1984;66(1):93-7.
9. Hope MJ, McQueen MM. Acute compartment syndrome in the absence of fracture. *J Orthop Trauma.* 2004;18(4):220-4.
10. Cox G, Thambapillay S, Templeton PA. Compartment syndrome with an isolated Salter Harris II fracture of the distal tibia. *J Orthop Trauma.* 2008;22(2):148-50.
11. Patillo D, Della Rocca GJ, Murtha YM, Crist BD. Pilon fracture complicated by compartment syndrome: a case report. *J Orthop Trauma.* 2010;24(6):54-7.
12. Gross RH, Cook M, Barfield WR. Codetron as adjunctive treatment in pediatric patients following spinal surgery. *J S C Med Assoc.* 2007;103(7):182-4.
13. Eaton RG, Green WT. Volkmann's ischemia. A volar compartment syndrome of the forearm. *Clin Orthop Relat Res.* 1975;(113):58-64.
14. Matsen FA 3rd, Krugmire RB Jr. Compartmental syndromes. *Surg Gynecol Obstet.* 1978;147(6):943-9.
15. Ernest CB, Brennaman BH, Haimovici H. Fasciotomia. In: Haimovici H, Ascer E, Hollier LH, Strandness DE Jr, Towne JB, editors. *Cirurgia vascular: principios e técnicas.* 4th ed. Di-Livros; São Paulo. 2000;1290-8.
16. Pitta GBB. Lesiones de la arteria poplitea por traumatismo en la vida civil. *Anais do XVIII Congresso Del Capitulo Latino Americano. II Congresso Nacional de Angiologia; Punta Del Leste.* 1986;76.
17. Whitesides TE, Haney TC, Morimoto K, Harada H. Tissue pressure measurements as a determinant for the need of fasciotomy. *Clin Orthop Relat Res.* 1975;(113):43-51.
18. Holden CE. The pathology and prevention of Volkmann's ischaemic contracture. *J Bone Joint Surg Br.* 1979;61(3):296-300.
19. Rorabeck CH, Castle GS, Hardie R, Logan J. Compartment pressure measurements: an experimental investigation using the slit catheter. *J Trauma.* 1981;21(6):446-9.
20. Mubarak SJ, Hargens AR, Owen CA. The wick catheter technique for measurement of intramuscular pressure. A new research and clinical tool. *J Bone Joint Surg Am.* 1976;58(7):1016-20.
21. McQueen MM. How to monitor compartment pressures. *Tech Orthop.* 1996;11(1):99-101.
22. Prayson MJ, Chen JL, Hampers D. Baseline compartment pressure measurements in isolated lower extremity fractures without clinical compartment syndrome. *J Trauma.* 2006;60(5):1037-40.
23. Vrouenraets BC, Kroon BB, Klasse JM. Value of laboratory tests in monitoring acute regional toxicity after isolated limb perfusion. *Ann Surg Oncol.* 1997;4(1):88-94.
24. Soricter S, Mair J, Koller A. Early assessment of exercise induced skeletal muscle injury using plasma fatty acid binding protein. *Br J Sports Med.* 1998;32(2):121-4.
25. van Nieuwenhoven FA, Kleine AH, Wodzig WH. Discrimination between myocardial and skeletal muscle injury by assessment of the plasma ratio of myoglobin over fatty acid-binding protein. *Circulation.* 1995;92(10):2848-54.
26. Shuler MS, Reisman WM, Kinsey TL. Correlation between muscle oxygenation and compartment pressures in acute compartment syndrome of the leg. *J Bone Joint Surg Am.* 2010;92(4):863-70.
27. van den Brand JG, Nelson T, Verleisdonk EJ, van der Werken C. The diagnostic value of intracompartmental pressure measurement resonance imaging, and near-infrared spectroscopy in chronic exercise compartment syndrome: a prospective study in 50 patients. *Am J Sports Med.* 2005;33(5):699-704.
28. Garr JL, Gentilello LM, Cole PA. Monitoring for compartmental syndrome using near-infrared spectroscopy: a noninvasive continuous transcutaneous monitoring technique. *J Trauma.* 1999;46(4):613-8.
29. Mullet H, Al-Abed K, Prasad CVR, O'Sullivan M. Outcome of compartment syndrome following intramedullary nailing of tibial diaphyseal fractures. *Int J Care Injured.* 32(5):P347-32.
30. Pitta GBB, Dos Santos TFA, Dos Santos FTA, Da Costa Filho EM. Compartment syndrome after tibial plateau fracture. *Rbo Rev Bras Ortop.* 2014;49(1):86-8.

Cite this article as: Naik KP, Shankarlinga S, Kyavater BS, Prashanthkumar M. Multiple stab incision technique to prevent postoperative acute compartment syndrome of leg in proximal and segmental fracture tibia and fibula: a prospective study. *Int J Res Orthop* 2022;8:xxx-xx.