

DOI: <http://dx.doi.org/10.18203/2320-1770.ijrcog20161711>

Case Report

Huge myxoid leiomyoma of cervix presenting as irreducible prolapse- management by vaginal myomectomy

Archana Mishra^{1*}, Sunita Malik¹, Kavita Agarwal¹, Sufian Zaheer², Akriti Gautam¹

¹Department of Obstetrics and Gynaecology, ²Department of Pathology, Vardhman Mahavir Medical College and Safdarjung Hospital, South Delhi-110029, Delhi, India

Received: 22 March 2016

Accepted: 23 April 2016

*Correspondence:

Dr. Archana Mishra,

E-mail: drarchanamishra@rediffmail.com

Copyright: © the author(s), publisher and licensee Medip Academy. This is an open-access article distributed under the terms of the Creative Commons Attribution Non-Commercial License, which permits unrestricted non-commercial use, distribution, and reproduction in any medium, provided the original work is properly cited.

ABSTRACT

Cervical leiomyoma consists 1-2% of all leiomyoma and myxoid degeneration of cervical fibroid is very rare. We present an old neglected case of huge necrotic cervical leiomyoma presenting with prolapse of mass and pelvic organs in a woman with multiple co-morbidities. Early management was necessary for improving her quality of life and controlling blood sugar. In lack of fitness for anaesthesia we performed her vaginal myomectomy under Intravenous Sedation. Prolapse was reducible and in absence of septic foci blood sugar profile improved. Vaginal myomectomy is a safe and quick procedure with least surgical morbidity and should be considered in cervical fibroids.

Keywords: Cervical leiomyoma, Myxoid degeneration, Prolapse, Vaginal myomectomy

INTRODUCTION

Leiomyoma is most common tumor of female genital tract but cervical leiomyoma are rare with incidence of only 1-2%.¹ Clinical entity of Myxoid leiomyoma was first described by Tavassoli and Norris in a case series 10 cases of leiomyoma most of which were pregnant women.² Myxoid degeneration of cervical fibroid is very rare. Cervical leiomyomas are classified as interstitial, supravaginal and polypoidal. The above mentioned case was polypoidal type which is known for cervical elongation. Cervical fibroids present with pressure effects on urethra, bladder neck and other urinary complaints according to their site. Surgical management of cervical fibroid depends upon the type of cervical fibroid and patient's desire to conserve uterus. We are presenting a case of huge necrotic myxoid leiomyoma of polypoidal type which lead to irreducible prolapse uterus. The patient was unfit for anaesthesia and major surgery due to several co-morbidities.

CASE REPORT

A 45 year old para 7 presented to our outpatient department with high grade fever and painful abducted gait. She complained of something coming out of introitus for past 3 years, difficulty in micturition for past 2 years, difficulty in walking due to irreducible mass for 2 months and fever for 4 days. Initially the mass used to reduce by itself or on manual reposition but for past 1 year the mass could not be repositioned and became irreducible. In her medical history she had history of pulmonary Koch's, diabetes mellitus, hypertension and bronchiectasis. Her menstruation was regular with average flow. She was taking irregular treatment for all her medical problems. On examination patient was average built, walking in painful abducted gait and she had to support the prolapsed mass while standing or walking. She had high grade fever. Added sounds were present on chest auscultation. On local examination there was third degree cervical descent with 1st degree cystocele. A large pedunculated mass of size 16x14x6

cm with pedicle of 4 cm thickness arising from anterior lip of cervix on serosal surface (Figure 1).

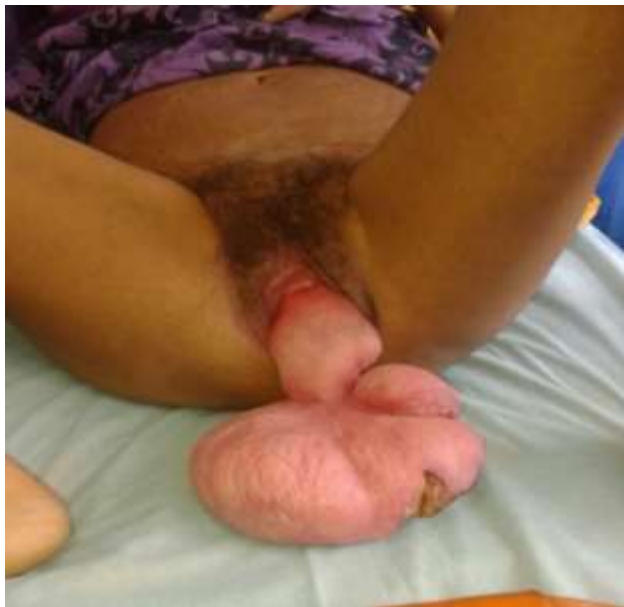

Figure 1: Large cervical fibroid resulting in uterine prolapse.

Inferior surface of mass had a large ulcer which was necrotic and malodorous (Figure 2).

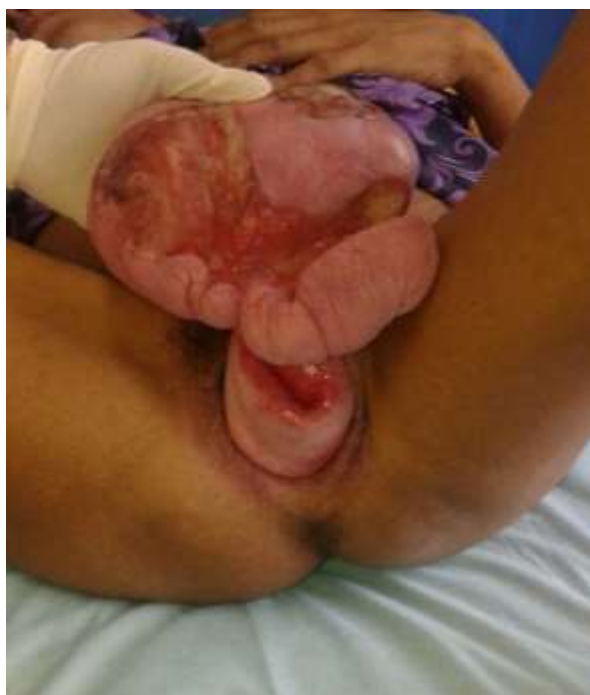

Figure 2: A large infected ulcer on the prolapsed fibroid.

Cervix was hypertrophied, elongated but otherwise healthy. Patient was admitted with diagnosis of degenerated cervical fibroid with third degree cervical descent and cystocele. As cervix was clearly visualized

so chronic inversion could be safely ruled out. Routine investigations necessary for surgery and anaesthesia fitness along with fever investigations were sent. Patient was diagnosed to be suffering from dengue fever and she also had one episode of diabetic ketoacidosis due to uncontrolled blood sugars which was managed accordingly. She was managed with antibiotics for chest infection and dressing of infected mass.

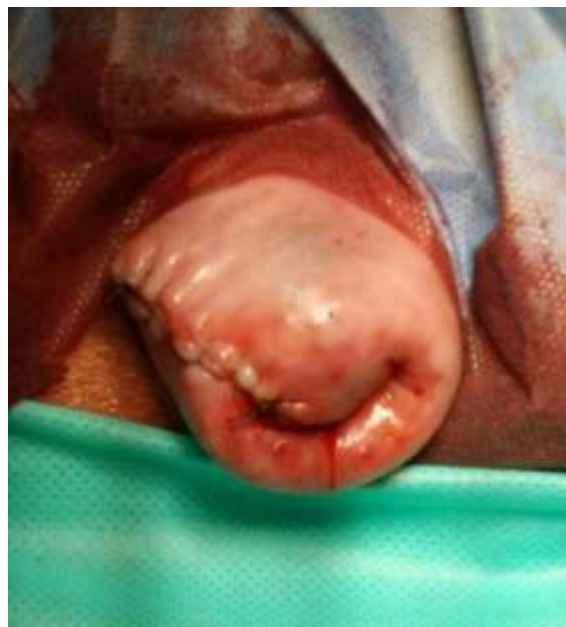

Figure 3: Appearance of cervix after surgery.

Even after 13 days of admission patient was not fit for anaesthesia due to co-morbidities. Decision of vaginal myomectomy under Intravenous Sedation was taken.

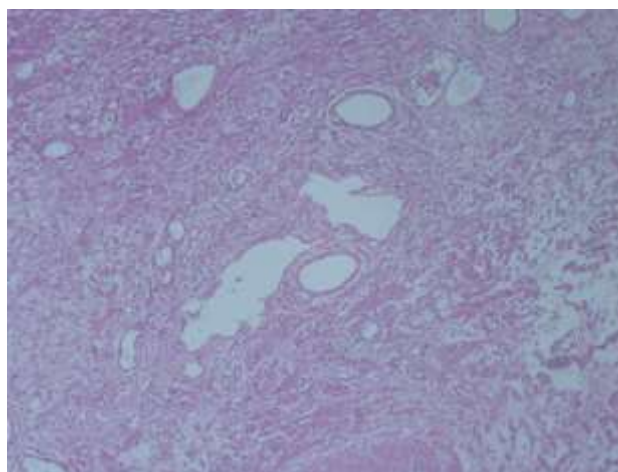


Figure 4: Leiomyoma was composed of spindle-shaped cells with uniform cigar shaped nuclei embedded in an abundant myxoid stroma (H and E, 10x).

The prolapsed leiomyoma was removed as one piece with monopolar diathermy at the base of thick stalk.

Hemostatic sutures were taken as per need and reconstruction of outer surface of cervix was done. Estimated blood loss was only 30 cc. She was allowed to move and take orally just after two hours of surgery. Cervix healed and resembled normal cervix and was reducible inside the introitus after surgery (Figure 3). Her urinary complaints subsided and in absence of septic foci her sugar profile normalised. Histopathological analysis of the mass confirmed a 13x11x4 cm white myxoid mass (Figure 4). Outer lining of mass was of stratified epithelium and underneath was leiomyoma with myxoid degeneration. An ulcer of 3x2 cm was seen on the inferior surface of mass. Patient was discharged with advice of follow up and option of vaginal Hysterectomy and pelvic floor repair in case her pelvic organ prolapse increases and becomes symptomatic.

DISCUSSION

Reporting such old neglected cases reflects the lower priority and lack of accessibility of medical care for women in India. To best of our knowledge and search of literature there was only one report of myxoid degeneration of cervical fibroid.³ There are 4 more similar reports of uterine prolapse due to cervical fibroids in English medical literature.^{4,7} One of these cases was similarly managed by vaginal myomectomy due to co-morbidity.⁴ It is the only reported case of prolapse of such a huge myxoid leiomyoma. Management of this case was challenging as the patient was not fit for anaesthesia and major surgery. Vaginal myomectomy is a safe and quick procedure with least surgical morbidity.⁷

Safety of vaginal myomectomy is established and it is the treatment of choice for prolapsed pedunculated cervical fibroid.^{8,9} As carcinomatous changes are reported in only 1.7% of cervical polyps so biopsy before definitive management is not usually necessary.¹⁰ Take home message is that such patient should be thoroughly investigated and evaluated for associated co-morbidities and management should be decided accordingly.

Funding: No funding sources

Conflict of interest: None declared

Ethical approval: Not required

REFERENCES

1. Drinville JS, Memarzadeh S. Benign disorders of the uterine corpus. In: DeCherney AH, Nathan L, editors. *Current obstetrics and gynaecologic diagnosis and treatment*. 10th ed. New York: Lange McGraw Hill; 2007:639-53.
2. Tavassoli FA, Norris HJ. Smooth muscle tumors of the vulva. *Obstet Gynecol.* 1979;53(2):213-7.
3. Kamra HT, Dantkale S, Birla K, Sakinlawar P, Narkhede R. Myxoid leiomyoma of cervix. *J Clin Diagn Res.* 2013;7(12):2956-7.
4. Ikechebelu JI, Eleje GU, Okpala BC, Onyiaorah IV, Umeobika JC, Onyegbule OA, et al. Vaginal myomectomy of a prolapsed gangrenous cervical leiomyoma. *Niger J Clin Pract.* 2012;15(3):358-60.
5. Khan AM, Seraphim A. Prolapse of large necrotic cervical fibroid. *J Obstet Gynaecol.* 2011;31(7):671.
6. Suneja A, Taneja A, Guleria K, Yadav P, Agarwal N. Incarcerated procidentia due to cervical fibroid: an unusual presentation. *Aust N Z J Obstet Gynaecol.* 2003;43(3):252-3.
7. Straub HL, Chohan L, Kilpatrick CC. Cervical and prolapsed submucosal leiomyomas complicating pregnancy. *Obstet Gynecol Surv.* 2010;65(9):583-90.
8. Golan A, Zachalka N, Lurie S, Sagiv R, Glezerman M. Vaginal removal of prolapsed pedunculated submucous myoma: a short, simple, and definitive procedure with minimal morbidity. *Arch Gynecol Obstet.* 2005;271:11-3.
9. Ben-Baruch G, Schiff E, Menashe Y, Menczer J. Immediate and late outcome of vaginal myomectomy for prolapsed pedunculated submucous myoma. *Obstet Gynecol.* 1988;72:858-61.
10. Khalil AM, Azar GB, Kaspar HG, Abu-Musa AA, Chararah IR, Seoud MA. Giant cervical polyp. A case report. *J Reprod Med.* 1996;41(8):619-21.

Cite this article as: Mishra A, Malik S, Agarwal K, Zaheer S, Gautam A. Huge myxoid leiomyoma of cervix presenting as irreducible prolapse- management by vaginal myomectomy. *Int J Reprod Contracept Obstet Gynecol* 2016;5:2029-31.