

DOI: <http://dx.doi.org/10.18203/2320-1770.ijrcog20173440>

Review Article

Adolescent endometriosis

Meenu P. Nanthakumar*, Sendhil C. Arumugam

Department of Obstetrics and Gynecology, Mahatma Gandhi Medical College and Research Institute, Pondicherry, India

Received: 26 May 2017

Revised: 14 June 2017

Accepted: 24 June 2017

***Correspondence:**

Dr. Meenu P. Nanthakumar,
E-mail: meenu.doc@gmail.com

Copyright: © the author(s), publisher and licensee Medip Academy. This is an open-access article distributed under the terms of the Creative Commons Attribution Non-Commercial License, which permits unrestricted non-commercial use, distribution, and reproduction in any medium, provided the original work is properly cited.

ABSTRACT

Endometriosis is predominantly a disease of women of reproductive age group. Endometriosis is not uncommon in adolescents. Presentation tends to focus on pain, especially intractable dysmenorrhea and chronic pelvic pain. In around 60% of patients with endometriosis symptoms start in adolescence. Pain unresponsive to treatment is the usual indication for a Laparoscopy. The appearance of endometriotic lesions is different from that of adults. Medical and surgical options for treatment are available. Endometriosis may be progressive and adverse effects may go beyond pain and cause infertility.

Keywords: Adolescence, Dysmenorrhea, Pelvic pain

INTRODUCTION

Endometriosis is predominantly a disease of women of reproductive age group. Endometriosis is not uncommon in adolescents, with majority of women with this condition reporting symptoms starting in adolescence. It is important that health care providers assessing young women with pelvic pain and dysmenorrhea to consider endometriosis in their differential diagnosis in order to avoid delay in diagnosis and management. Given that endometriosis is a progressive disease with increasing morbidity over time, an early diagnosis and optimal management during adolescence is warranted.

Incidence

The prevalence of endometriosis is difficult to determine accurately. Endometriosis was originally felt to be a disease seen in women who had undergone a minimum of 5 years of ovulatory menstrual cycles. However, endometriosis has been documented as early as the premenarchal age group, in girls who have initiated

the menarche.¹ Multiple investigators have reported varying incidence of endometriosis in adolescents. The mean age of adolescents in these studies is between 11 and 22 years of age. They presented with chronic pelvic pain or dysmenorrhea which did not respond to treatment with nonsteroidal anti-inflammatory drugs or oral contraceptives pills (OCP). A subsequent laparoscopic examination performed to evaluate the cause of pelvic pain revealed endometriosis in 47-70% of such girls who failed the initial medical management.²⁻⁴

The Endometriosis Association registry reports that 38% of women with endometriosis had symptoms starting before age 15 years and in such age group an average of 4.2 physician consultations is required before a diagnosis is reached, more than in any other age group.⁵

Presentation and evaluation

Initial delay in the diagnosis of endometriosis in adolescents maybe because the pain is attributed to primary dysmenorrhea and hence considered a “normal”

part of growing up. Secondary dysmenorrhea should be suspected in patients not responding to first-line agents like NSAID and OCP for the treatment of primary dysmenorrhea. Endometriosis is the most common cause of secondary dysmenorrhea in adolescents.² The presentation endometriosis in adolescents often differs from that of adults. Contrary to the conventional cyclic pain associated with endometriosis, majority of adolescents diagnosed with endometriosis report both cyclic and acyclic pain.⁶ The pain is usually disruptive and affects their school, sports and social activities. A pain diary is often useful. They can also have abnormal bleeding associated with dysmenorrhea. Patients should be specifically enquired for bowel and bladder symptoms like diarrhoea, hematochezia, dyschezia, hematuria, dysuria and frequency. These symptoms may be clustered around the time of periods or can occur otherwise too. A history of endometriosis in the family should raise the index of suspicion. Advanced disease and endometriomas are rare in adolescents. Dyspareunia is quite uncommon in adolescents as many are not sexually active and teenagers usually don't present with infertility.^{2,3} Symptoms of endometriosis in adolescents are summarised in Table 1.

Table 1: Summary of symptomatology in adolescents with endometriosis.

Symptoms	Incidence (in %)
Acyclic and cyclic pain	62.5
Acyclic pain	28.1
Cyclic Pain	9.4
Gastrointestinal symptoms	34.3
Urinary symptoms	12.5
Abnormal uterine bleeding	9.4
Vaginal discharge	6.3

Researchers from Belgium have developed a self-report questionnaire to identify adolescent girls at risk for endometriosis. It is a 6 part questionnaire enquiring into the plethora of symptoms of endometriosis and is a promising tool to avoid diagnostic delays.⁷

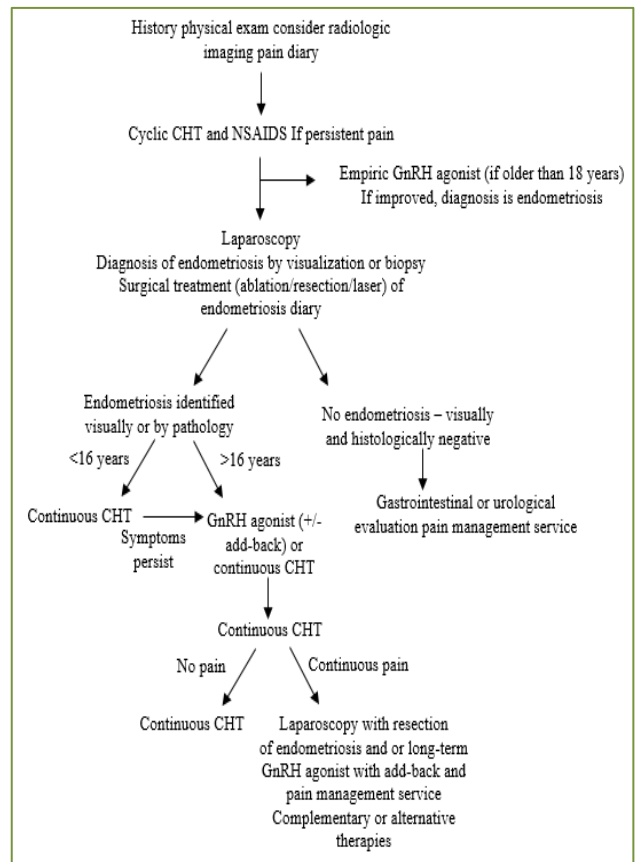
A pelvic examination of the young adolescent maybe limited; however, it is valuable to help rule out pelvic masses and obstructive outflow tract anomalies. Inspection of the external genitalia, with separation and traction of the labia, may demonstrate low outflow tract anomalies. A patent outflow can be determined by placing a Q-tip into the vaginal canal to assess its length and rule out transverse vaginal septum or vaginal agenesis. The physical findings are often normal in this age group even in the presence of endometriosis. Cul-de-sac nodularity, adnexal masses or a fixed, retroverted uterus are uncommon in adolescents with endometriosis, as the disease is predominantly minimal or mild (ASRM stage I or II).⁶

A pelvic ultrasound is indicated in the evaluation of pelvic pain and can reveal an obstructive anomaly or

adnexal mass, which may have been difficult to detect on physical examination. However, USG is not very useful in detecting non-ovarian endometriosis.⁸ Pelvic imaging with MRI is essential if a Müllerian anomaly is suspected. Measurement of CA-125 is nonspecific for diagnosing endometriosis and is generally not recommended.^{9,10}

Management

The American College of Obstetricians and Gynecologists has put forth a stepwise treatment algorithm (Figure 1) for the care of adolescents presenting with dysmenorrhea.¹⁰



NSAIDS-nonsteroidal anti-inflammatory drugs; CHT-combination hormone therapy; GnRH-gonadotropin-releasing hormone

Figure 1: Management algorithm of adolescent endometriosis.

Principles of laparoscopy in adolescents

The ACOG 2005 recommendations include initiation of treatment with nonsteroidal anti-inflammatory drugs and combined oral contraceptive pills (COCs). If symptoms of dysmenorrhea continue beyond 3 months despite these interventions, patients should be offered a diagnostic laparoscopy.¹⁰ Laparoscopic evaluation of the pelvis in adolescent females commonly reveals atypical, endometriotic lesions different from the typical powder

burn lesions seen in adults.^{10,11} These include clear papules, red, flame-like lesions, white lesions, and glandular lesions. These probably represent early lesions and have been shown to have active prostaglandin synthesis within them, attributing to significant pain symptoms.¹²

Subtle, clear, papular lesions are difficult to visualize. Laufer et al described a technique where the pelvis was filled with fluid and then the pelvis inspected laparoscopically under water.¹³ This minimizes light reflection and allows the surgeon to recognize the clear endometriotic implants in a three-dimensional view.

Following laparoscopic confirmation of endometriosis, the extent of the disease is staged using ASRM classification of endometriosis. This will help in future “relook” laparoscopy. Multiple studies confirm the existence of primarily low-stage disease in adolescent patients. Reese et al in their study, found 79.6% of adolescents had endometriosis Stage I. Stage II disease is noted in 12.3% of patients. Only 6.1% and 2.0% had stage III and stage IV disease, respectively.¹⁴

Management

The goals of treatment for adolescents with endometriosis are symptom control, prevention of further disease progression and preservation of fertility. Medical and surgical options are available for the management of endometriosis. Most experts advocate prolonged medical therapy following laparoscopic diagnosis and excision of endometriosis.

Medical management

Combined oral contraceptives

COCs are typically the first line of therapy in adolescents. Use of COC inhibits ovulation, decreases gonadotropin levels reduces menstrual flow and causes decidualization of endometriotic implants. COCs decrease cell proliferation and decrease the ectopic endometrium as well. When severe dysmenorrhea is the primary complaint, continuous COCs may induce amenorrhea and subsequent relief of symptoms.¹⁵ This therapy is only suppressive and not curative. Symptom recurrence was common after stopping therapy for 6 months. Considering present evidence, the Cochrane Database of 2007 concluded that information regarding the long-term benefits of COC in the treatment of endometriosis is insufficient.¹⁶

Progestins

Progesterone agents include medroxyprogesterone acetate (MPA) and 19-nortestosterone derivatives, such as norethindrone and norgestrel. These agents cause decidualization and subsequent atrophy of the ectopic and endometrial tissue. Medroxyprogesterone acetate

may be given in oral forms of 20 to 30 mg daily or the depot form of 150 mg every 3 months. Studies have shown that, on average, 70% to 80% of patients show improvements in pain symptoms.¹⁷ DMPA-SC 104 is equally efficacious as Leuprolide in managing pain symptoms related to endometriosis. However, in the adolescent population, long-term use of progestin therapy needs to be weighed against impaired bone mineralization secondary to the hypoestrogenic environment induced by progestins.¹⁸ Compared with DMPA-SC 104, Leuprolide caused significantly larger decline in both hip and lumbar spine BMD. Thus, one needs to be cautious when placing adolescents on long-term progestin therapy, as the potential risks in regard to future osteoporotic fractures is currently unknown. In addition, progestin therapy is commonly associated with side effects such as weight gain, bloating, mood lability and irregular bleeding.

GnRH agonists

Treatment with GnRH agonists have been found to be extremely effective in alleviating symptoms associated with endometriosis. GnRH agonists induce a medical menopause through a mechanism involving binding to the GnRH receptors in the pituitary. These agonists have a longer half life than endogenous GnRH and induce a down-regulation of receptors. This ceases pituitary gonadotropin output resulting in amenorrhea. The Cochrane Group reviewed the efficacy of GnRH agonists versus the OCP in the treatment of endometriosis and concluded that GnRH agonist was more effective than OCPs taken in the conventional manner.¹⁹ GnRH agonists that have been used include leuprolide acetate, nafarelin, buserelin, and goserelin. Leuprolide can be given as a 3.75-mg injection every 4 weeks or 11.25-mg injection every 12 weeks. However, as with long-term progestin therapy, concerns regarding bone mineralization exist, and thus, the use of GnRH agonists alone is generally limited to patients more than 16 years of age and for a period of 6 months.¹⁰

Add back therapy

Patients with severe symptoms and respond well to GnRH agonist may benefit from continuing the medication for longer than the recommended 6 months. In adolescents, the effect on bone mass is particularly concerning as most of the physiologic increase in bone mass and density occurs during puberty. To help protect against bone demineralization and to reduce the side effects of pseudomenopause associated with GnRH agonist therapy like vasomotor symptoms, vaginal dryness, and mood swings, hormonal “add-back” options are recommended. These include norethindrone acetate (5-mg daily) and combined conjugated estrogens/medroxyprogesterone acetate (0.625/2.5-mg daily). Research has shown that, with both these regimens, the therapeutic effect of GnRH agonists is not diminished, but side effects and bone loss are minimized

in adult women.^{20,21} In fact, given that adolescent females are considered to be rapidly accruing bone mass up to the age of 20 years, some experts in the field recommend initiation of GnRH agonists always in combination with add-back therapy in the adolescent population. Experts in the field suggest BMD monitoring at baseline and every 2 years for patients on long-term GnRH agonist plus add-back therapy.⁶ These patients should also take adequate calcium and vitamin D supplementation to minimise the effect of bone demineralization.

Surgery

Laparoscopy is preferred over laparotomy in adolescents. The laparoscopic procedure should be both diagnostic and therapeutic and to be preferably done by a senior consultant with experience in treating endometriosis. Surgery should be timed in the follicular phase of menstrual cycle. This will help minimise recurrences and adhesions. First port should be intraumbilical and the lateral ports should be placed close to the pubic bone for cosmetic superiority.

The goal of surgical treatment is to remove visible areas of endometriosis and restore normal anatomy by lysis of adhesions. Surgery has been shown to be effective in improving endometriosis symptoms; reported improvement rates range from 38% to 100%.^{22,23} Various techniques are used, including laser vaporization, unipolar or bipolar coagulation, and endocoagulation; no one technique has been shown to be superior to any other. Deeper lesions should be excised. However, symptoms generally return in the majority of patients after 1 year without further treatment and so surgery alone is not considered adequate treatment in the adolescent patient population. These patients need to be put on long term suppressive medical therapy as described above.

Laparoscopy for endometriomas and die

Though endometriomas and DIE are not very common in adolescent age group, when present they pose a surgical challenge. Surgical treatment of endometrioma is to be considered only when medical management fails. Team approach comprising a Gynaec Laparoscopic surgeon, Urologist, Surgical Gastroenterologist is ideal. Preoperative ovarian reserve needs to be measured by testing AMH levels. While handling endometriomas one has to be careful to excise the lesion while at the same time preserving normal ovarian tissue.

Mullerian anomalies and endometriosis

72% of patients with obstructive mullerian anomalies have endometriosis. The clinical outcome in such patients has been reported to differ from those without such obstruction because the disease usually regresses once the the anomaly has been surgically corrected with success. Early intervention reverses endometriosis, reduces dysmenorrhea and promotes fertility.¹⁰

Emergency situations like ruptured endometrioma

Ruptured endometriomas has to be considered when there is severe pain in adolescent girls with known endometriomas. Rarely rupture of endometriotic cyst can be the first presentation of endometriosis in these girls. Emergency Laparoscopy with cystectomy and adhesiolysis is needed.

The role of presacral neurectomy and LUNA, as an adjunct to surgical removal of endometriosis are not clearly defined in the literature, and so these procedures are not advocated on adolescents.²⁴

Role of oocyte cyopreservation

Endometriosis is detected in close to 30% of infertile women and it has been inferred that almost 50% of such patients require IVF conception. Endometriosis adversely affects ovarian reserve. Ovarian endometriomas in particular contain a plethora of toxic agents such as free iron that damage the ovarian reserve. There is a significant reduction of the pool of primordial follicles of affected gonads. Also, surgical removal of endometriosis invariably damages the ovarian cortex and brings down the ovarian reserve. Hence, experts are now considering the role of oocyte and ovarian cortex freezing especially in young patients with bilateral endometriomas or patients with monolateral excision of endometriomas with contralateral recurrence.^{25,26}

Future trends

Selective estrogen receptor modulators (SERMS) and selective progesterone receptor modulators (SPRMs) are the newer hormonal options that have been suggested.^{27,28} However, human studies are lacking in both the groups of drugs. Both have the ability to suppress estrogen dependent endometrial growth without the adverse systemic effects of hypoestrogenism like vasomotor symptoms and loss of BMD. Thus, the need for add-back therapy can be negated. Use of Aromatase inhibitors in the treatment of endometriosis seems to be promising. The enzyme aromatase, a key enzyme in estrogen biosynthesis, appears to be over-expressed in sites of endometriosis. Aromatase inhibitors thus would reduce ovarian and local production of estrogen and can be beneficial in treating this condition.²⁹ Proponents of the immunologic causation theory of endometriosis have suggested that autoimmune modulators may be an effective method of treatment. Anti-tumor necrosis factor therapies have been successfully used to reduce endometriotic growth in animal models.³⁰ So, this line of treatment also warrants further research.

Follow-up

Since endometriosis can be a life-long disease, careful follow-up of the adolescents after surgical diagnosis and treatment is important. The findings should be clearly

explained to the patient and her caretakers. Patient should be reviewed every 3 to 6 months. During this time, her symptoms should be monitored closely and the girl should be educated about the possible, long-term nature of endometriosis and the need to minimize the number of pelvic surgeries. Concerns about fertility and quality of life should be addressed. Unless contraindicated, most patients should be put on OCP after surgery. If the patient does not respond to surgery or has recurrence of symptoms, other modes of long-term, medical therapy are considered and an investigation into other causes of pelvic pain is warranted. Gastroenterology, psychology, and urology experts should be consulted if required and this ensures appropriate evaluation of such patients for coexisting diseases and optimise their care.

CONCLUSION

Endometriosis is a progressive disease and a significant number of women with endometriosis report symptoms starting in adolescence. Presentation tends to focus on pain, especially intractable dysmenorrhea and chronic pelvic pain. When unresponsive to initial medical management, the adolescent girl should be offered laparoscopy because the likelihood of discovering endometriosis in that context is at least 50%. The appearance of lesions found at laparoscopy in adolescents may differ from that in adults. OCPs, DMPA, GnRH agonists and surgical ablation tend to be the practical treatment modalities in this age group. Future work for adolescents should focus on developing safe, minimally invasive, yet definitive options for diagnosis and treatment.

Funding: No funding sources

Conflict of interest: None declared

Ethical approval: Not required

REFERENCES

1. Marsh EE, Laufer MR. Endometriosis in premenarcheal girls who do not have an associated obstructive anomaly. *Fertil Steril.* 2005;83:758-760.
2. Goldstein DP, Leventhal JM, Emans SJ. New insights into the old problem of chronic pelvic pain. *Journal of pediatric surgery.* 1979;14(6):675-80.
3. Chatman DL, Ward AB. Endometriosis in adolescents. *J Reprod Med.* 1982;27:156-60.
4. Emans SH, Laufer MR, Goldstein DP. Dysmenorrhea, pelvic pain, and the premenstrual syndrome In: *Pediatrics and adolescent gynecology.* 4th edition. Philadelphia: Lippencott-Raven Publishers; 1997:363-410.
5. Ballweg ML. Big picture of endometriosis helps provide guidance on approach to teens: comparative historical data show endo starting younger, is more severe. *J Pediatr Adolesc Gynecol.* 2003;16(3 Suppl):S21-6.
6. Laufer MR. Current approaches to optimizing the treatment of endometriosis in adolescents. *Gynecol Obstet Investigation.* 2008;66(suppl. 1):19-27.
7. Geysenbergh B, Dancet EA, D'Hooghe T. Detecting endometriosis in Adolescents: why not start from self-report screening questionnaires for adult women? *Gynecol Obstet Invest.* 2016 Nov 5.
8. Eskenazi B, Warner M, Bonsignore L, Olive D, Samuels S, Vercellini P. Validation study of nonsurgical diagnosis of endometriosis. *Fertil Steril.* 2001;76:929-35.
9. Solnik MJ. Chronic pelvic pain and endometriosis in adolescents Current Opinion. *Obstet Gynecol.* 2006;18:511-8.
10. American College of Obstetricians and Gynecologists. Endometriosis in adolescents. ACOG Committee Opinion No. 310. *Obstet Gynecol.* 2005;105:921-7.
11. Davis GD, Thillet E, Lindemann J. Clinical characteristics of adolescent endometriosis. *J Adolesc Health.* 1993;14:362-8.
12. Vernon MW, Beard JS, Graves K, Wilson EA. Classification of endometriotic implants by morphologic appearance and capacity to synthesize prostaglandins. *Fertil Steril.* 1986;46:801-6.
13. Laufer MR. Identification of clear vesicular lesions of atypical endometriosis: a new technique. *Fertil Steril.* 1997;68:739-40.
14. Reese KA, Reddy S, Rock JA. Endometriosis in an adolescent population: the Emory experience. *J Pediatr Adolesc Gynecol.* 1996;9:125-8.
15. Winkel C, Scialli A. Medical and surgical therapies for pain associated with endometriosis. *J Women's Health Gender Based Med.* 2001;10(2):137-62.
16. Davis L, Kennedy SS, Moore J. Modern combined oral contraceptives for pain associated with endometriosis. *Cochrane Database Syst Rev.* 2007;3:CD001019.
17. Vercellini P, De Giorgi O, Oldani S, Cortesi I, Panazza S, Crosignani PG. Depot medroxyprogesterone acetate versus an oral contraceptive combined with very-low-dose danazol for long-term treatment of pelvic pain associated with endometriosis. *Am J Obstet Gynecol.* 1996;175:396-401
18. Bahamondes L, Perrotti M, Castro S, Faúndes D, Petta C, Bedone A. Forearm bone density in users of depoprovera as a contraceptive method. *Fertil Steril.* 1999;71:849-52.
19. Moore J, Kennedy S, Prentice A. Modern combined oral contraceptives for pain associated with endometriosis (Cochrane Review). In: *The Cochrane Library, issue 2.* Oxford: Update Software Ltd; 2002.
20. Surrey ES, Hornstein MD. Prolonged GnRH agonist and add-back therapy for endometriosis: long-term follow-up. *Obstet Gynecol.* 2002;99:709-19.
21. Barbieri RL. Hormone treatment of endometriosis: the estrogen threshold hypothesis. *Am J Obstet Gynecol.* 1992;166:740-5.

22. Sutton J, Ewen SP, Whitelaw N, Haines P. Prospective, randomized, double blind, controlled trial of laser laparoscopy in the treatment of pelvic pain associated with minimal, mild and moderate endometriosis. *Fertil Steril.* 1994; 4:696-700.
23. Redwine DB. Treatment of endometriosis-associated pain. *Infertil Reprod Med Clin North Am.* 1993;3:697-721.
24. Nezhat CH, Seidman DS, Nezhat FR, Nezhat CR. Long-term outcome of laparoscopic presacral neurectomy for the treatment of central pelvic pain attributed to endometriosis. *Obstet Gynecol.* 1998;91:701-4.
25. Elizur SE, Chian RC, Holzer HE, Gidoni Y. Cryopreservation of oocytes in a young woman with severe and symptomatic endometriosis: a new indication for fertility preservation. *Fertil Steril.* 2009;293:e1-293.e3.
26. Somigliana E, Vigano P, Filippi F, Vercellini P. Fertility preservation in women with endometriosis: for all, for some, for none?. *Human Reprod.* 2015;30(6):1280-6.
27. Chwalisz K, Garg R, Brenner RM, Schubert G, Elger W. Selective progesterone receptor modulators (SPRMs): a novel therapeutic concept in endometriosis. *Ann N Y Acad Sci.* 2002;955:373-88.
28. Buelke-Sam, Bryant HU, Francis PC. The selective receptor modulator, raloxifene: an overview on non-clinical pharmacology and reproductive and developmental testing. *Hum Reprod Update.* 1998;6:413-8.
29. Bulun SE, Zeitoun K, Takayama K, Sasano H. Molecular basis of treating endometriosis with aromatase inhibitors. *Hum Reprod Update.* 2000;6:413-8.
30. Nothnick WB, Curry TE, Vernon MW. Immunomodulation of rat endometriotic implant growth and protein production. *Am J Reprod Immunol.* 1994;31:151-162.

Cite this article as: Nanthakumar MP, Arumugam SC. Adolescent endometriosis. *Int J Reprod Contracept Obstet Gynecol* 2017;6:3213-8.