

DOI: <http://dx.doi.org/10.18203/2320-1770.ijrcog20183340>

Original Research Article

Nonimmune hydrops foetalis (NIHF): value of fetal autopsy and comparison with ultrasound findings

Umamaheswari G.¹, Ramya T.^{2*}, Chaitra V.¹

¹Department of Pathology, ²Department of Obstetrics and Gynecology, PSG Institute of Medical Sciences and Research, Coimbatore, Tamil Nadu, India

Received: 09 June 2018

Accepted: 03 July 2018

***Correspondence:**

Dr. Ramya T.,

E-mail: ramya.t2003@gmail.com

Copyright: © the author(s), publisher and licensee Medip Academy. This is an open-access article distributed under the terms of the Creative Commons Attribution Non-Commercial License, which permits unrestricted non-commercial use, distribution, and reproduction in any medium, provided the original work is properly cited.

ABSTRACT

Background: Nonimmune hydrops foetalis (NIHF) is a terminal catastrophic event of pregnancy caused by numerous diverse etiology. The aim of this study was to assess the significance of foetal autopsy and to compare the prenatal ultrasound (USG) and foetal autopsy findings in cases of NIHF.

Methods: All perinatal autopsies performed at the department of pathology between March 2011-February 2018 were retrospectively reviewed. Of the received 130 autopsies, twenty cases of NIHF were identified, records of which were collected and correlated with maternal medical history, prenatal imaging and autopsy findings.

Results: The malformations with hydrops foetalis were classified according to the involved organ system. They were cardiothoracic (7/20 cases), genitourinary (3/20 cases), gastrointestinal lesions (1/20 cases), chromosomal (4/20 cases) and multisystem anomaly/syndromic association (5/20 cases). Complete agreement between USG and autopsy was seen in 8 (40%) cases. In 5 (25%) cases autopsy findings were in total disagreement with USG diagnosis. The rest of the 7 (35%) cases, autopsy revealed additional information and changed the recurrence risk in two cases.

Conclusions: Present study demonstrates the high rate of discordancy between USG and autopsy examination in cases complicated by NIHF. Foetal autopsy confirms the USG findings (quality control/audit), adds additional findings or changes the final diagnosis, which helps in redefining the recurrence risk and plausible genetic counselling for future pregnancies. Hence present study underscores the need for autopsy in all cases of NIHF.

Keywords: Nonimmune hydrops foetalis, Perinatal/ foetal autopsy, Prenatal imaging, Ultrasound

INTRODUCTION

Hydrops foetalis remains a distressing pregnancy complication with high perinatal mortality. It is characterized by generalized oedema and presence of fluid in pleural, peritoneal and pericardial cavities. Polyhydramnios and abnormally thickened placenta are often associated with hydrops.¹

Traditionally, hydrops is classified into immune and nonimmune types. There is marked reduction in the incidence of immune hydrops due to effective immunologic prophylaxis for maternal isoimmunisation.

Currently, the focus is on nonimmune hydrops foetalis (NIHF), which accounts for >90% of cases of hydrops.²

NIHF is associated with multiple aetiology. The various causes include cardiovascular, genitourinary, thoracic lesions, chromosomal aberrations, infections, haematological, genetic/metabolic, placental and idiopathic.³

Initial diagnosis of hydrops foetalis is usually made by ultrasound. In most of the cases, an accurate and complete antenatal imaging also points to the cause behind the development of hydrops. Despite having a

high diagnostic accuracy, foetal ultrasonography (USG) has some limitations, especially in cases with hydrops. Foetal autopsy in such instances can help to overcome the challenges.

The goals of this retrospective study were to compare the accuracy and completeness of prenatal ultrasonography with perinatal autopsy in cases of NIHF.

METHODS

All perinatal autopsies performed at the department of pathology between March 2011-February 2018, were retrospectively reviewed. It included foetuses of all gestational ages. Causes of deaths were termination of pregnancy for foetal malformations, spontaneous abortions, stillbirths and early neonatal deaths. Of the 130 autopsies, twenty cases of NIHF were identified, records of which were collected and correlated with maternal medical history and prenatal imaging studies.

Immune hydrops foetalis were excluded from the study. Institutional ethical committee approval was obtained. Maternal data collection included maternal age, obstetric history, maternal medical diseases, gestational age of the foetus, and prenatal ultrasound findings.

Sonograms were predominantly performed by radiologists and some by obstetricians trained in obstetric ultrasound examination. The diagnostic criteria for hydrops foetalis were foetal skin oedema >5.0mm with one serous cavity effusion or fluid collection in at least two serous cavities (peritoneal, pleural or pericardial cavities).

The autopsies were performed by pathologists with perinatal experience. Informed written consent was obtained for all cases. A standard autopsy protocol was followed which included foetogram, photography, biometric measurements, external and internal examination. Microscopic examination of relevant organs such as thyroid, thymus, lungs, heart, liver, spleen, pancreas, adrenals, kidneys and ovary (in case of female), testis (in case of male) were done.

The brain was removed and fixed in formalin solution with the help of a gauze in a hanging position, then relevant sections were studied. Spinal cord, bone, muscle were also studied when necessary.

Special stains such as Periodic acid-Schiff (PAS) and Perls' Prussian blue were done if needed. Placental examination was done in all cases, but findings were not considered for the present study.

Placental causes of hydrops were also excluded from the study. Results of karyotype, if known was collected. The final autopsy diagnosis was correlated with prenatal ultrasound findings and results were drawn.

RESULTS

The maternal age ranged from 19 to 35 years with the mean age of 25.55years. Gestational age ranged from 13 to 35 weeks, with the mean gestational age of 21.45 weeks. There were 18 stillborn foetuses and 2 neonates with the Male: Female ratio of 3:2. Authors did not come across any multiple gestation. Four cases had recurrent hydrops.

Prenatal diagnosis of hydrops was noted in 14 cases and in the remaining 6, diagnosis was made at post-mortem. Present data showed prenatal diagnosis of the presence of hydrops in only two-third of the cases.

Subcutaneous oedema and serous cavity effusions were identified in the rest one-third only during autopsy. All of these were second trimester foetuses. Cystic hygroma was identified in five cases.

The malformations with hydrops foetalis were classified according to the involved organ system. They were cardiothoracic (7/20 cases), genitourinary (3/20 cases), gastrointestinal lesions (1/20 cases), chromosomal (4/20 cases) and multisystem anomaly/syndromic association (5/20 cases).

Cardiac lesions (n=4): The cardiovascular malformations included premature closure of ductus (1case), complete heart block(1case), atrioventricular septal defect (AVSD) with persistent left superior vena cava (SVC) with other findings suggestive of Down syndrome(1case) and 1 case of transposition of great arteries (TGA), which also had an associated partial urorectal septum malformations.

Thoracic lesions (n=3): The thoracic lesions were congenital pulmonary adenomatoid malformations (CPAM, 2 cases) and congenital high airway obstruction syndrome (CHAOS, 1 case).

Genitourinary lesions (n=3): Three cases of bladder outlet obstruction (BOO) were included in the group of urogenital malformations, of which one had an associated ventriculomegaly, absent corpus callosum (ACC) with hypoplasia of ductus, right and left pulmonary arteries, distal aortic arch and left subclavian artery

Gastrointestinal lesions (n=1): The gastrointestinal lesions included, a 28weeks foetus with hypertrophic pyloric stenosis.

Chromosomal abnormalities (n=4): Of the 4 cases, two showed phenotypic features of Down syndrome, but karyotype confirmation was not available. Karyotyping was possible in the remaining 2 cases of which one showed partial deletion of short arm of X chromosome (Turner syndrome) and the other showed trisomy 18 (Edwards syndrome) (Figure 1).

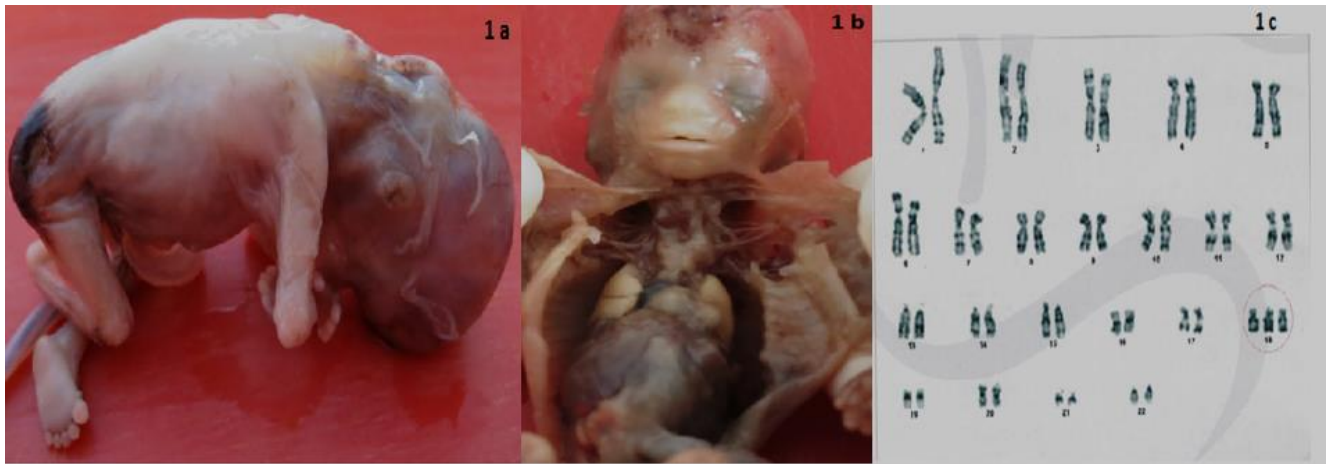


Figure: 1a) Foetus of 14 weeks gestation, with a cystic swelling over the lower occipital region to upper back (cystic hygroma); 1b) same foetus showing large and dilated cavities on the sides of the neck with thin fibrous strands; 1c) Chromosomal analysis of cultured chorionic villi of the foetus revealed the presence of an additional copy of chromosome 18, instead of the usual two copies (Edward's syndrome).

Multisystem anomalies/ syndromic association (n=5): The autopsy findings suggested syndromic associations in five instances. They were one case each of Ellis- Van Creveld syndrome, Multiple congenital anomaly syndrome, VACTERL (vertebral defects, anal atresia, cardiac defects, tracheo-esophageal fistula, renal anomalies and limb abnormalities) association, FRYNS Syndrome and Cerebro-oculo-facio-skeletal syndrome.

Karyotype analysis was done for the last two cases and were found to be normal.

Correlation between prenatal ultrasound and autopsy findings: Complete agreement between USG and autopsy was seen in 8 (40%) cases. In 5 (25%) cases, autopsy findings were in total disagreement with USG diagnosis. The rest of the 7 (35%) cases, autopsy revealed additional information.

Table 1: Autopsy changed ultrasound findings.

Case No.	System involved	Prenatal USG findings	Autopsy findings with diagnosis
1.	Cardiac	HF	Premature ductus closure.
2.	Thoracic	Large cystic hygroma	CPAM
3.	Chromosomal	HF, oesophageal atresia, absence of stomach	Phenotypic features of foetal trisomy No oesophageal atresia Karyotype-not done
4.	Urogenital	No anomaly	BOO-distal urethral stenosis
5.		HF	BOO-distal urethral stenosis Ventriculomegaly, ACC

HF- hydrops foetalis; BOO- bladder outlet obstruction; CPAM- congenital pulmonary airway malformation; ACC –absent corpus callosum.

Cases with complete disagreement has been shown in Table 1.

The fifth case showed no oesophageal atresia, in contrast to prenatal imaging.

Two had bladder outlet obstruction, one each had CPAM and premature closure of ductus.

Though this was a significant disagreement, there was no major shift in the final diagnosis as both modalities suggested chromosomal aetiology.

In all the four cases, there was a complete change in the diagnosis after the autopsy.

Table 2: Autopsy added additional findings.

Case No.	Prenatal USG findings	Additional autopsy findings with diagnosis
1.	Short long bones, polydactyly, tricuspid atresia with VSD-probably Ellis Van Creveld syndrome	Common atrium with complete AVSD- Ellis-Van Creveld syndrome
2.	Polyhydramnios, HF, micrognathia, hypospadias, cleft soft palate, ACC, cardiomegaly, tricuspid regurgitation	Hypotelorism, depressed nasal bridge, low set ears, Heart – secundum ASD, Liver – haemosiderosis Pancreas – giant islets and nesidioblastosis Multiple congenital anomaly syndrome, Zellweger syndrome, Smith Lemli Opitz syndrome.
3.	SUA, TOF, ectopic hydronephrotic Left kidney, Left club foot with absent 2 nd to 5 th digits	Hemivertebra, fusion of ribs on the left side, Atresia of distal sigmoid, rectum with absent anal opening VACTERL association
4.	Left diaphragmatic hernia, hypoplastic left heart, short humerus on left side, absent forearm with claw hand on left side; dilated jugulolymphatic sacs: multiple anomalies and with SUA, could be VACTERL association.	Partial ACC, and hydrocephalus Karyotype was normal -Suggestive of FRYNS Syndrome
5.	HF, Foetal akinesia deformation sequence, sloppy forehead, micrognathia, gross bilateral lateral ventriculomegaly	Cerebro-oculo-facio-skeletal syndrome with persistent urogenital sinus
6.	Increased nuchal translucency, cystic hygroma, absent nasal bone	AVSD with persistent left SVC -Suggestive of Down syndrome
7.	Cystic hygroma with TGA and VSD	Partial urorectal septum malformation

VSD-ventricular septal defect; AVSD- atrioventricular septal defect; HF- hydrops foetalis; ACC-agenesis of corpus callosum; ASD-atrial septal defect; SUA-single umbilical artery; TOF-tetralogy of Fallot; VACTERL-vertebral defects, anal atresia, cardiac defects, tracheo-esophageal fistula, renal anomalies, and limb abnormalities; SVC-superior vena cava; TGA-transposition of great arteries

There were seven cases with additional autopsy findings which has been summarized in Table 2. Authors had two cases with cardiac lesions and the rest of the cases

showed multisystem involvement. After autopsy, two out of seven cases had a change in recurrence risk (Figure 2).

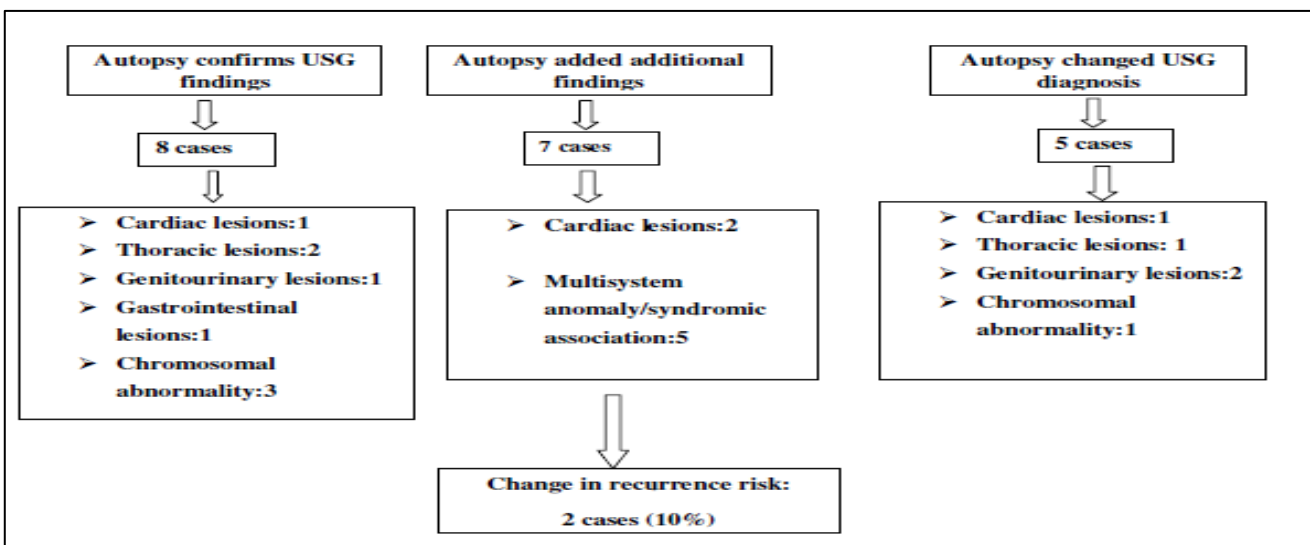


Figure 2: Correlation between prenatal USG findings with foetal autopsy findings.

In cases of multi system involvement, the autopsy finding of hemi vertebra, atresia of distal sigmoid, rectum, anal canal with absent anal opening, completed the diagnosis of VACTERL association (case 3, table 2).

In the same group (case 4, table 2), prenatal diagnosis of VACTERL association was changed to FRYNS syndrome after the identification of central nervous system anomaly (Figure 3).

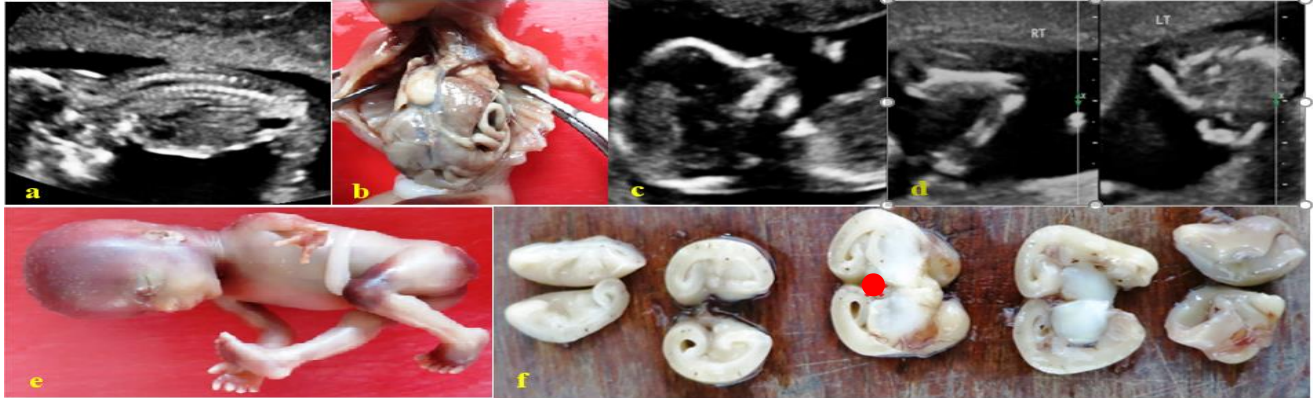


Figure 3: FRYNS syndrome a) USG showing diaphragmatic hernia (stomach, bowel and liver in the thorax) and the corresponding autopsy image; b), c), d) and e) USG of the same foetus showing micrognathia and left claw hand with corresponding autopsy image; f) Cross sections of the brain shows partial agenesis of corpus callosum (●), and ventriculomegaly.

Table 3 highlights the cases that showed full agreement between USG and autopsy findings. This included three cases of chromosomal abnormality, two cases of thoracic lesions (CPAM and CHAOS) and one case each from

cardiovascular system (complete heart block), genitourinary (BOO) and gastrointestinal group (hypertrophic pyloric stenosis). There were none from the multiple anomaly group.

Table 3: Autopsy confirms USG findings.

Case No.	System involved	Prenatal USG findings	Autopsy findings with diagnosis
1.	Cardiac	Polyhydramnios, HF, complete heart block	Complete heart block secondary to fibrosis of cardiac conduction system
2.		CHAOS with HF.	Laryngeal atresia (CHAOS)
3.	Thoracic	Polyhydramnios, HF, CPAM with short long bones	CPAM, type 3
4.	Urogenital	Oligohydramnios, bilateral hydronephrosis, distended bladder	BOO - posterior urethral valves.
5.	Gastrointestinal	Polyhydramnios, HF. Hepatomegaly. Stomach visualized	Hypertrophic pyloric stenosis. Hirsutism.
6.		NT: 3mm. Combined test – increased risk of trisomy 21	Phenotypic features of foetal trisomy Karyotype-not done
7.	Chromosomal	NT: 1.75mm Combined test – increased risk of trisomy 21	Phenotypic features consistent with Turners syndrome Karyotyping shows partial deletion of short arm of X chromosome
8.		Cystic hygroma, HF Single outflow with peri membranous VSD, pulmonary atresia	TGA with hypoplastic pulmonary arterial trunk subaortic VSD Cystic hygroma Anteriorly placed anus Hypoplasia of thymus Karyotyping shows trisomy 18.

DISCUSSION

After extensive search of literature authors came across many studies comparing prenatal USG findings with post-mortem examination. Most of these studies dealt with cases of foetal malformations, stillbirth and neonatal death.⁴⁻⁸ But, there were only few studies comparing the same in cases of NIHF.^{9,10} Hence authors chose to address the accuracy of prenatal USG findings and compare it with perinatal autopsy in cases of NIHF.

Prenatal diagnosis of hydrops was missed in one third of present cases. Fluid collection is initially diagnosed by USG during the first or mid trimester. Significant fluid accumulation is recognized easily, but sometimes the effusions are limited and can escape diagnosis during imaging.

Present data showed complete agreement between USG and autopsy findings in 40% of cases. This was similar to a study by Antonella et al done in 2012.¹¹ In their study they have compared the USG and autopsy findings of 144 second trimester foetuses. In 49% of cases there were total agreement between the two. Additional information was provided by post-mortem in 34% of cases, while in present study it was 35%. Astonishingly in 13% of their cases, functional anomalies detected by ultrasound could not be confirmed by autopsy. This is due to the fact that ultrasound examination is a dynamic examination, optimum to reveal functional changes like valve insufficiencies, flow reversals and sometimes even cavity effusions. This should not be considered as false positive USG findings, but as an advantage of the imaging modality.

In 7 cases (35%), there were additional findings in autopsy not detected by USG. In two of these cases, the additional findings provided by autopsy redefined the recurrence risk. It seems that the higher proportion of additional findings in the present study might be due to critical identification of minor anomalies at autopsy such as anal atresia, partial agenesis of corpus callosum and urorectal septum malformation.¹⁰

The identification of these minor anomalies is significant as they might change the diagnosis from an isolated lesion to complex malformation.⁴

All cases in the multiple anomaly had additional findings in autopsy. The identification of partial agenesis of corpus callosum with hydrocephalus in a case with prenatal imaging diagnosis of VACTERL association changed the final diagnosis to be Fryns syndrome. The other anomalies were concordant. The foetus was 16 weeks at the time of diagnosis, and identification of the cranial anomaly at this gestational age is challenging.¹² Fryns syndrome (FS) is the commonest autosomal recessive syndrome in which congenital diaphragmatic hernia (CDH) is a cardinal feature.¹³ The autosomal recessive inheritance in FS contrasts with the sporadic

inheritance seen in cases of VACTERL anomaly.¹⁴ This underscores the importance of the correct diagnosis for accurate genetic counselling.

Among the cases with cardiovascular lesions, prenatal ultrasound showed increased nuchal translucency, cystic hygroma and absent nasal bone which was all suggestive of trisomy 21. The presence of AVSD, the characteristic heart lesion in these foetuses was made out by post-mortem examination. This more or less confirmed the diagnosis of Down syndrome.

In addition to multiple anomaly, the histological presence of haemosiderosis of the liver with giant islets and nesidioblastosis of the pancreas led to the suggestive diagnosis of multiple congenital anomaly syndrome, Zellweger syndrome, Smith Lemli Opitz syndrome.

One of the study case showed USG findings of Foetal akinesia deformation sequence, with gross bilateral lateral ventriculomegaly. But post-mortem examination also revealed hydranencephaly, lens opacity along with facial and skeletal lesions which led to the diagnosis of cerebro-oculo-facio-skeletal syndrome. Persistent urogenital sinus was noted additionally.

There was total discordance between USG and autopsy in 5 cases of 20(25%). In all 5 cases, though hydrops was diagnosed prenatally, the causative lesion could not be detected by imaging. But autopsy revealed structural anomaly in 4/5 cases. Though all these four lesions (premature closure of ductus, CPAM, BOO) could be identified by antenatal imaging, they were missed. As hydrops foetalis carries a bad prognosis and once it is evident by ultrasound, further careful and complete imaging is overlooked. This could have led to the non-identification of structural abnormality by USG and the discordance with post-mortem examination.

USG as well as autopsy have unavoidable limitations in analysing cases of NIHF. So, they are considered complementary to one another. Both of these modalities depend on the expertise of the personnel, the technological advancement of the ultrasound equipment and the autopsy technique.

The causes for differences in prenatal USG include early gestational age (structures are too tiny to evaluate, respective organs not completed development structurally or functionally), abnormal amount of liquor (oligo/polyhydramnios) which makes visualization of organs difficult, altered maternal habitus (obese, thick abdominal wall) and foetal position. Authors found that additional findings were high in cases of multi system involvement, which was similar to the observation by Rossi et al.⁵ This is attributed to the increased focus of the sonographer on severe and more interesting abnormalities, overlooking minor or less lethal abnormalities or not completing the examination once a major/lethal anomaly is detected.⁴

The main limitations of post-mortem examination are longer duration of reporting and the need for appropriate training and expertise in the field of perinatal pathology. There are a few other factors which may hinder the accurate post-mortem examination:

- intrauterine foetal death with long period of foetal retention and superimposed maceration may distort the foetal anatomy
- in foetuses with suspected CNS abnormality, the autopsy findings may be inconclusive due to extreme autolysis
- satisfactory dissection may not be possible in foetuses of very early gestation with small organs (can be overcome by dissecting microscope) and presence of post-mortem artefacts
- functional anomalies can be missed.^{10,15-18}

Although present study is a retrospective analysis involving less number of cases, it is the only study to specifically correlate the prenatal USG findings and post-mortem examination of foetuses with nonimmune hydrops. This knowledge and further studies involving large number of cases of NIHF will contribute to improve parental counselling.

NIHF is a terminal catastrophic event of pregnancy caused by numerous diverse aetiology and is known for its low diagnostic yield. Initial recognition of hydrops is usually made by ultrasonographic examination. But the aetiology in many cases remains elusive even after a carefully performed imaging.

In such instances post-mortem study of the foetus including placental examination and other ancillary work up like genetic study, testing for infections and metabolic derangements help in identifying the cause. present study demonstrates a high rate of discordancy between USG and autopsy examination in cases complicated by NIHF.

Foetal autopsy confirms the USG findings (quality control/audit), adds additional findings or changes the final diagnosis. Although, foetuses with nonimmune hydrops carry worse prognosis, it is indispensable to identify the genesis of the hydrops to counsel the couple regarding prognosis, recurrence risk and future pregnancy outcomes. Hence present study underscores the need for autopsy in all cases of NIHF.

ACKNOWLEDGMENTS

Authors acknowledge the services of Dr. Ammu Srinivasan, Emeritus Professor, Department of Pathology, PSGIMSR.

Funding: No funding sources

Conflict of interest: None declared

Ethical approval: The study was approved by the Institutional Ethics Committee

REFERENCES

1. Randenberg AL. Nonimmune hydrops fetalis part II: does etiology influence mortality?. *Neonatal Netw.* 2010 Nov-Dec;29(6):367-80.
2. Bellini C, Hennekam RC. Non-immune hydrops fetalis: a short review of etiology and pathophysiology. *Am J Med Genet A.* 2012;158A:597-605.
3. Nagy A, Malcomson RDG. Fetal hydrops. In Yee KT, Malcomson RDG, eds. *Keeling's Fetal and Neonatal Pathology*, 5th ed. London: Springer-Verlag; 2015:299-328.
4. Chescheir NC, Reitnauer PJ. A comparative study of prenatal diagnosis and perinatal autopsy. *J Ultrasound Med.* 1994 Jun;13(6):451-6.
5. Rossi AC, Prefumo F. Correlation between fetal autopsy and prenatal diagnosis by ultrasound: A systematic review. *Eur J Obstet Gynecol Reprod Biol.* 2017 Mar;210:201-6.
6. Antonsson P, Sundberg A, Kublickas M, Pilo C, Ghazi S, Westgren M, et al. Correlation between ultrasound and autopsy findings after 2nd trimester terminations of pregnancy. *J Perinat Med.* 2008;36(1):59-69.
7. Vogt C, Blaas H-GK, Salvesen KA, Eik-Nes SH. Comparison between prenatal ultrasound and postmortem findings in fetuses and infants with developmental anomalies. *Ultrasound Obstet Gynecol.* 2012;39(6):666-72.
8. Boecking CA, Drey EA, Kerns JL, Finkbeiner WE. Correlation of prenatal diagnosis and pathology findings following dilation and evacuation for fetal anomalies. *Arch Pathol Lab Med.* 2016 Oct 20;141(2):267-73.
9. Sankar VH, Phadke SR. Clinical utility of fetal autopsy and comparison with prenatal ultrasound findings. *J Perinatol.* 2006 Apr;26(4):224.
10. Struksnæs C, Blaas HG, Eik-Nes SH, Vogt C. Correlation between prenatal ultrasound and postmortem findings in 1029 fetuses following termination of pregnancy. *Ultrasound Obstet Gynecol.* 2016 Aug 1;48(2):232-8.
11. Vimercati A, Grasso S, Abruzzese M, Chincoli A, de Gennaro A, Miccolis A, et al. Correlation between ultrasound diagnosis and autopsy findings of fetal malformations. *J Prenatal Med.* 2012 Apr;6(2):13.
12. Guibert-Trainer F, Piton J, Billerey J. Agenesis of the corpus callosum. *J Neuroradiol.* 1982;9:135.
13. Slavotinek AM. Fryns syndrome-a review of the phenotype and diagnostic guidelines. *Am J Med Genet.* 2004;124A:427-33.
14. Solomon BD, Pineda-Alvarez DE, Raam MS, Cummings DA. Evidence for inheritance in patients with VACTERL association. *Hum Genet.* 2010;127:731-3.
15. Rodriguez MA, Prats P, Rodriguez I, Cusi V, Comas C. Concordance between prenatal ultrasound and autopsy findings in a tertiary center. *Prenat Diagn.* 2014;34:784-9.

16. Gilbert-Barness E, Debich-Spicer D. Embryo and fetal pathology: color atlas with ultrasound correlation. Cambridge: Cambridge University Press; 2004.
17. Kaasen A, Tuveng J, Heiberg A, Scott H, Haugen G. Correlation between prenatal ultrasound and autopsy findings: A study of second-trimester abortions. *Ultrasound Obstet Gynecol.* 2006;28:925-33.
18. Amini H, Antonsson P, Papadogiannakis N, Ericson K, Pilo C, Eriksson L, et al. Comparison of

ultrasound and autopsy findings in pregnancies terminated due to fetal anomalies. *Acta Obstet Gynecol Scand.* 2006;85(10):1208-16.

Cite this article as: Umamaheswari G, Ramya T, Chaitra V. Nonimmune hydrops foetalis (NIHF): value of fetal autopsy and comparison with ultrasound findings. *Int J Reprod Contracept Obstet Gynecol* 2018;7:3330-7.