

DOI: <http://dx.doi.org/10.18203/2320-1770.ijrcog20182915>

Case Report

Umbilical true knot: a case study

Hima Bindu Kommuri, Valsa Diana G.*

Department of Obstetrics and Gynecology, Rajiv Gandhi Government Women and Children Hospital, Puducherry, India

Received: 22 April 2018

Accepted: 29 May 2018

***Correspondence:**

Dr. Valsa Diana G,

E-mail: valsadiana@gmail.com

Copyright: © the author(s), publisher and licensee Medip Academy. This is an open-access article distributed under the terms of the Creative Commons Attribution Non-Commercial License, which permits unrestricted non-commercial use, distribution, and reproduction in any medium, provided the original work is properly cited.

ABSTRACT

Umbilical cord true knot is a rare condition which affects about 1% of all pregnancies. The incidence is not only very low, but it is often undiagnosed antenatally when present despite the availability of prenatal ultrasonography as in this case, where the diagnosis of true knot of umbilical cord was missed even when an ultrasonogram was done 1 week prior to the presentation of patient with decreased fetal movements to opd. Majority of times it does not have any relation with fetal outcome but in certain occasions it is associated with intrauterine fetal demise as in present case presented here. Risk factors include long umbilical cord, polyhydramnios, small fetus, male fetus, etc.

Keywords: Intrauterine fetal demise, Umbilical cord true knot

INTRODUCTION

The occurrence of true knot of umbilical cord is very rare.¹ It may be defined as entwining of a segment of umbilical cord, usually without obstructing fetal circulation and commonly result from fetal slippage through a loop of the cord.¹ Although the reported incidence of true knots of umbilical cords ranges from 0.3% to 2%.²⁻⁵

Certain factors have been noted to increase its predisposition. These include long umbilical cords, polyhydramnios, small size fetuses, male fetuses, gestational diabetes mellitus, monoamniotic twins, process of undergoing genetic amniocentesis and multiparity.²⁻⁵

In general, the belief is that true knot of the cord is formed between 9 and 12 weeks of gestation.¹ This early gestation is a period where amniotic fluid is relatively large.¹ Paradoxically, there is reported evidence of knot formation of the umbilical cord when a woman is undergoing labor.⁶ The diagnosis of umbilical cord true

knot is difficult antenatally even with use of ultrasonography as there are no characteristic features. Hence this case with a rare presentation is being presented here.

CASE REPORT

A 27-year-old booked primigravida with 39 weeks of gestation, came with complaints of decreased fetal movements since morning. No history of trauma, leaking or bleeding per vaginum. She is not a known case of hypertension or diabetes.

On examination, patient is moderately built and nourished, no pallor, no pedal edema, anicteric, afebrile. Vitals – stable. Per abdomen- uterus term size, relaxed, non-tender. Fetal heart sounds could not be heard.

Per vaginal examination- uneffaced cervix with os closed and station at -3, no abnormal discharge per vaginum. Ultrasonography- shows term size fetus with absent fetal cardiac activity, adequate liquor, grade 3 placenta with calcifications.

The diagnosis of true knot of umbilical cord antenatally is very difficult, the incidence ranges 0.3% to 2%.¹⁻³ Nevertheless, prenatal diagnosis of true knot of the umbilical cord has been demonstrated using ultrasound which will show “cloverleaf pattern” on grey scale images.^{5,6} Although ultrasound was done for this patient, the diagnosis was missed.

As this patient presented with inutero fetal demise, labour was induced for vaginal delivery with vaginal misoprostol. She delivered a dead born male baby with 3.5 kg weight, apgar 0, tobacco coloured liquor and the knot abnormality seen (Figure 1).

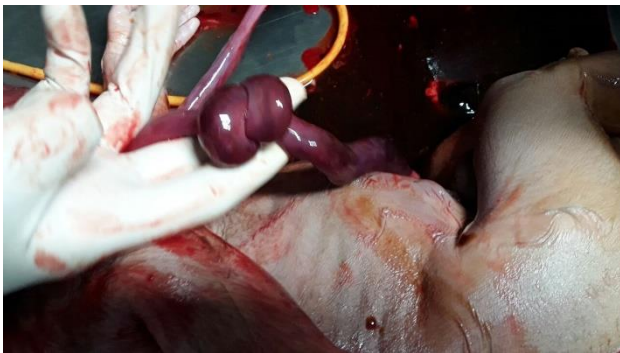


Figure 1: A true knot of umbilical of the umbilical cord.

DISCUSSION

The diagnosis of true knot of the umbilical cord antenatally has not been commonly reported in the literature. A number of factors are associated with increased predisposition to formation of true umbilical cord knot. This is relatively more likely to occur in early pregnancy due to relatively more amniotic fluid and greater fetal movement. True knots are associated with advanced maternal age, multiparity, male foetuses (applicable in this case) and long umbilical cords. A caesarean delivery may be considered if a diagnosis of true cord knot is made early, majority of knots seem to be protected against occlusion by wharton's jelly. False knots on other hand have no clinical significance.^{5,6}

Since the gestation at which true knot actually occur is still unclear, they are difficult to diagnose prenatally. This is because, they have been reported to form in all three trimesters.^{6,7} Some Other researchers of are of opinion that true knots originate intrapartum and as such, there is no characteristic prenatal true knot appearance.^{6,7} The final diagnosis could be made out only after delivery in this patient. The woman did not have retro placental clots and autopsy was not done. In majority of cases, true knots of umbilical cord occur without any clinical significance, however in some rare occasions, there exists an association between umbilical cord knots and intrauterine fetal death as was seen in this case.

Some conditions may enhance the prenatal detection of umbilical knots using ultrasonographic imaging. For instance, in monoamniotic twins where true knot condition was purposely sought after.^{8,9} Though the present case was a singleton pregnancy, the experience is limited to incidental observation.

A 4-fold increase in fetal loss have been reported to result from true knot, seemingly because the umbilical cord vessels can be compressed when the knot tightens.¹ Other possible reasons for the fetal demise could not be identified in this case, the woman did not have retro placental clot and autopsy was not done. Thus, uncertainty lays the utility of antenatal testing in the follow up of pregnancies with true knots.¹⁰

The umbilical cord is called the foetal life line.¹¹ Various abnormalities are observed in the morphology and pathology of the umbilical cord but knowledge of them is rather poor.¹² Study done by Guzikowski et al to assess the role of 2D and 3D ultrasound for diagnosing true knot of umbilical cord found it useful modality.¹³

CONCLUSION

As in present case, prenatal diagnosis of a true umbilical cord knot could not be made out even with the use of ultrasonography antenally and furthermore the current experience on true knot of umbilical cord is limited to incidental observation. Therefore, regular antenatal checkups with more frequency towards the last trimester may be done.

Funding: No funding sources

Conflict of interest: None declared

Ethical approval: Not required

REFERENCES

1. Hershkovitz R, Silberstein T, Sheiner E, Shoham-Vardi I, Holcberg G, Katz M, et al. Risk factors associated with true knots of the umbilical cord. *Eur J Obstet Gynecol Reprod Biol.* 2001;98:36-9.
2. Spellacy WN, Gravem H, Fisch RO. The umbilicalcord complications of true knots, nuchal coils, and cords around the body. Report from collaborative study of cerebral palsy. *Am J Obstet Gynecol.* 1966;94:1136-42.
3. Airas U, Heinonen S. Clinical significance of true umbilical knots: A population-based analysis. *Am J Perinatol.* 2002;19:127-32.
4. Sherer DM, Dalloul M, Zigalo A, Bitton C, Dabiri L, Abulafia O. Power Doppler and 3-dimensional sonographic diagnosis of multiple separate true knots of the umbilical cord. *J Ultrasound Med.* 2005;24:1321-3.
5. Sornes T. Umbilical cord knots. *Acta Obstet Gynecol Scand.* 2000;79:157-9.

6. Maher JT, Conti JA. A comparison of umbilical cord blood gas values between newborns with and without true knots. *Obstet Gynecol.* 1996;88:863-6.
7. Sepulveda W, Shennan AH, Bower S, Nicolaidis P, Fisk NM. True knot of the umbilical cord. *Am J Obstet Gynecol.* 2006;195:896-8.
8. Ramon Y, Cajal CL, Martinez RO. Four-dimensional ultrasonography of a true knot of the umbilical cord. *Am J Obstet Gynecol.* 2006;195:896-8.
9. Deutsch AB, Miller E, Spellacy WN, Mabry R. Ultrasound to identify cord knotting in monoamniotic monochorionic twins. *Twin Res Hum Genet.* 2007;10:216-8.
10. Stempel LE. Beyond the pretty pictures: Giving obstetricians just enough (umbilical) cord to hang themselves. *Am J Obstet Gynecol.* 2006;195:888-90.
11. Guzikowski W, Kowalczyk D, WiA cek J. Diagnosis of true umbilical cord knot. *Arch medical sci AMS.* 2014;10:91-5.
12. Szczepanik ME, Wiittich AC. True knot of the umbilical cord: a report of 13 cases. *Mil Med.* 2007;172:892-4.

Cite this article as: Kommuri HB, Diana VG. Umbilical true knot: a case study. *Int J Reprod Contracept Obstet Gynecol* 2018;7:2956-8.