

DOI: <http://dx.doi.org/10.18203/2320-1770.ijrcog20201262>

Case Report

A rare case report of recurrent ectopic pregnancy

Prema Prabhudev, Sapna I. S., Soujanya M. Muddegoud*

Department of Obstetrics and Gynecology, S. S. Institute of Medical Sciences and Research Center, Davanagere, Karnataka, India

Received: 19 December 2019

Revised: 19 February 2020

Accepted: 26 February 2020

*Correspondence:

Dr. Soujanya M. Muddegoud,

E-mail: soujanyamuddegoud@gmail.com

Copyright: © the author(s), publisher and licensee Medip Academy. This is an open-access article distributed under the terms of the Creative Commons Attribution Non-Commercial License, which permits unrestricted non-commercial use, distribution, and reproduction in any medium, provided the original work is properly cited.

ABSTRACT

This case presenting a 30-year-old lady, a case of G4A1E2 who presented with history of 1 month of amenorrhoea, followed by bleeding per vaginum 1 week back for 3 days. Presented to hospital with spotting PV and pain abdomen for 2 days. UPT done at home was positive. USG revealed right ovarian complex haemorrhagic cyst and left adnexal ectopic pregnancy near left ovarian fimbriae. Conservative management by Methotrexate and Folinic acid regimen was tried but as there were no signs of resolution on serial ultrasonography reports and serial human chorionic gonadotropin (hCG) levels did not fall as expected, hence decision of laparoscopy/laparotomy was made and salpingectomy was done. Later patient was followed up with serial hCG levels.

Keywords: Fallopian tube, Human chorionic gonadotropin, Laparotomy, Recurrent ectopic pregnancy, Salpingectomy, Ultrasound

INTRODUCTION

Ectopic pregnancy occurs in 1.3-2% of all pregnancies and accounts for 0.25 to 2% of all pregnancies worldwide. Most common site for implantation for ectopic is fallopian tube (98.3%) where ampullary (79.6%), isthmic (12.3%), fimbrial (6.2%), ovary (0.15%) and abdominal cavity (1.4%).¹ A study by Rose et al found maximum cases in age group of 21-30 years (43%) which corroborated with the present study (55.6%).² Recurrence in patient who had one previous ectopic pregnancy is high (8-17%). There is increased incidence of ectopic with assisted reproductive techniques. The recurrence rate of ectopic pregnancy after one previous ectopic is 15% and increases to 30% after two previous ectopic pregnancies. The typical triad of amenorrhoea, pain abdomen and bleeding are observed in more than 50% cases. Patients with low (<1000 IU/l) or declining HCG levels are candidates for expectant treatment. Hemodynamically unstable patients, heterotopic

pregnancy with a viable intrauterine pregnancy, tubal rupture, contraindications to methotrexate and failed medical therapy are the indications for surgical treatment.³ It greatly endangers life of women. It is one of the major causes of maternal morbidity and mortality.

Here presenting an interesting case of a lady who had three consecutive ectopic pregnancies and its management.

CASE REPORT

A 30-year-old fourth gravida with previous two ectopic pregnancies and one abortion presented to casualty of SSIMS and RC with complaints of sudden onset of pain abdomen and spotting per vagina for 2 days following one month of amenorrhea and history of bleeding PV for 3 days, 1-week back. UPT done by patient was positive. History of ovulation induction treatment taken for all pregnancies. Her previous menstrual cycles were regular,

normal in duration and flow. Patient gives history of two consecutive right sided tubal ectopic pregnancies following a missed abortion.

First ectopic pregnancy was 6 years back (1 and 1/2 years after last abortion), conceived after ovulation induction, right sided tubal ectopic pregnancy of 6 weeks 5 days gestation for which she underwent laparotomy and right sided salpingotomy in the year 2014. The second one was again right tubal unruptured ectopic 2 years back for which patient underwent laparoscopic right sided salpingectomy in 2017.

This pregnancy patient presented with 1 month of amenorrhea (Conceived after ovulation induction) with pain abdomen and spotting PV and UPT being positive. Her pulse rate was 98 bpm, blood pressure was 110/80 mmHg. Patient was conscious oriented and stable. On examination there was lower abdominal tenderness on both sides, more in left iliac fossa. On per vaginal examination, uterus was normal in size, cervix was firm and tenderness was present in left fornix with cervical motion tenderness.

Ultrasonography (USG) revealed empty uterine cavity with left sided ill-defined degenerative ectopic gestation sac with yolk sac with adjacent decidual reaction and absent embryonic pole near left ovarian fimbriae - left adnexal ectopic pregnancy, right sided functional cyst, hemorrhagic cyst and follicle measuring about 3.5 and 3cm, with significant reactive free fluid in POD.

USG on 18th February 2019

- Ill-defined degenerative ectopic gestational sac with yolk sac with adjacent decidual reaction noted in left adnexa near the left ovarian fimbriae - left adnexal ectopic pregnancy
- Significant reactive free fluid seen in POD
- Right ovarian complex cyst with hemorrhagic component
- Fundal fibroid of 3 × 3 cm (Figure 1).

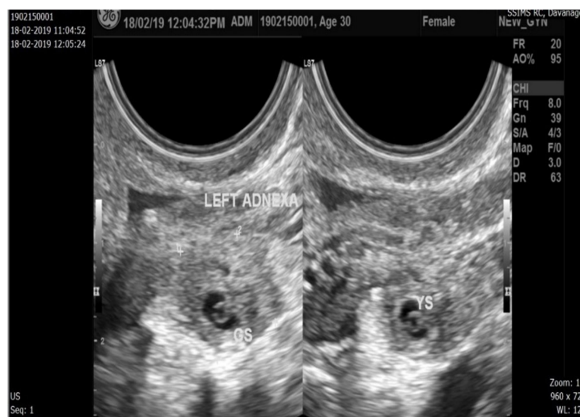


Figure 1: USG on 18th February 2019.

USG on 21st February 2019

- Right ovary appears bulky and shows simple ovarian cyst measuring 4.4 × 3.1 cm and hemorrhagic follicle measuring 2 × 2 cm, multiple hemorrhagic cyst of 2 × 3 cm.
- Degenerative gestational sac with adjacent decidual reaction noted in left adnexa in left ovarian fimbriae
- Embryonic pole not-visualized, yolk sac visualized
- Unruptured ectopic gestational sac in left adnexa
- Reactive fluid seen in POD (Figure 2).

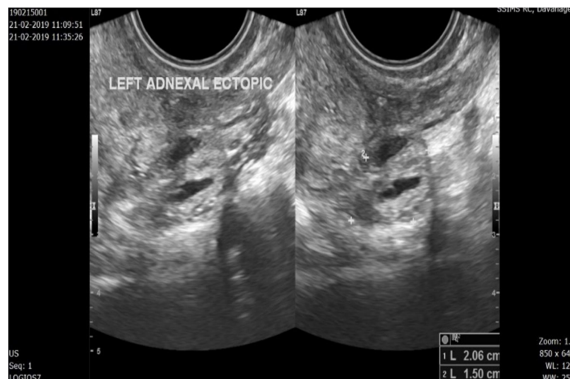


Figure 2: USG on 21st February 2019.

Table 1: Serial Hcg values.

Date	Beta HCG value (mIU/ml)
15 th February 2019	669
18 th February 2019	943
21 st February 2019	917
24 th February 2019	456

Other investigations like complete hemogram, coagulation profile, RFT, LFT were within normal limits and beta HCG level was 669 mIU/ml (below the discriminatory threshold of 1500 mIU/ml).

As patient was hemodynamically stable and had history of previous two ectopic, option of conservative management was opted. Patient was treated with Inj Methotrexate 50 mg/m² BSA on day 0 and was monitored for vitals. Serum beta hCG was repeated after 48 hours which was 943 mIU/ml. Due to rise in serum beta hCG values 2nd dose of Inj. Methotrexate along with Inj Folinic acid (0.1 mg/kg) was given. Serum beta hCG repeated and the value was 917 mIU/ml for which 3rd dose Inj. Methotrexate and 2nd dose Inj. Folinic acid was given. Patient was hemodynamically stable. Repeat scan after 2 days did not reveal any changes and beta HCG was 456 mIU/ml (Table 1). The decision of proceeding to surgical management was made as there were no changes in sac size in serial USG reports.

Patient was prepared for elective laparoscopy/laparotomy for left sided salpingectomy. Due to adhesions from

previous laparotomy, laparoscopic procedure was converted to laparotomy.

Intra operative findings were as follows

- Uterus 8 weeks size
- A fundal fibroid of 4 × 4 cm seen in left cornual region reaching endometrium removed by myomectomy procedure
- A seedling fibroid of 2 × 2 cm on left side of uterus
- A right sided ovarian multiloculated cyst of 4 × 6 cm
- A left sided unruptured (partially resolved) ectopic gestation at isthmus ampullary region
- Right fallopian tube absent and left ovary is normal.

This is an image showing uterus with fundal fibroid of 4 × 4 cm at cornual region reaching endometrium removed by myomectomy procedure (Figure 3).

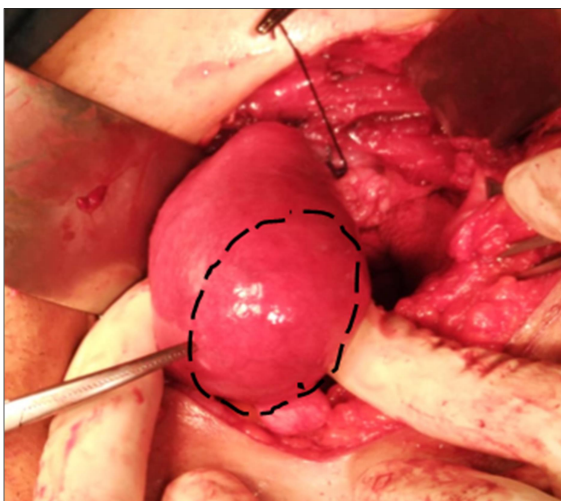


Figure 3: Uterus with fundal fibroid.

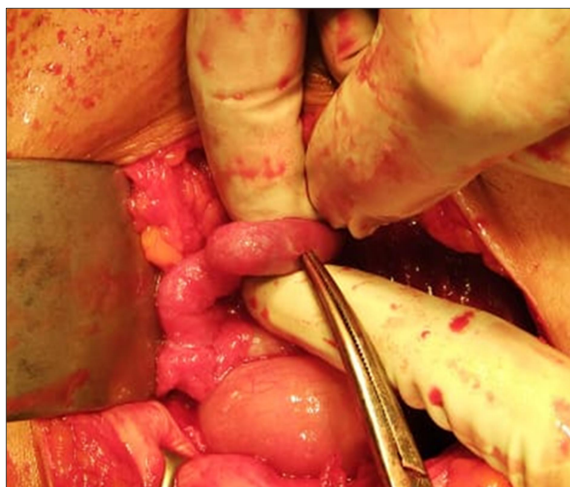

Figure 4: Ectopic gestation.

This is an image showing left sided unruptured (partially resolved) ectopic gestation at isthmus ampullary region (Figure 4).

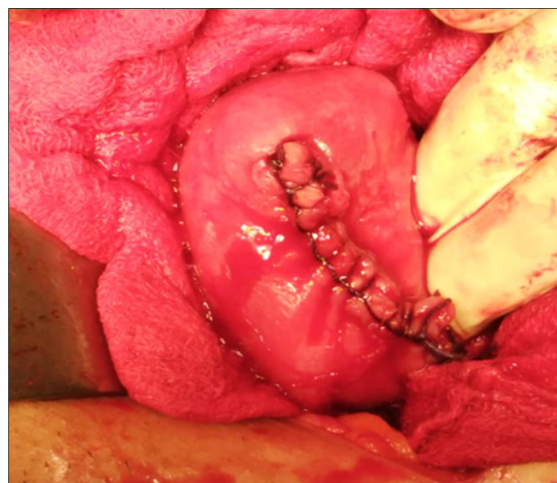


Figure 5: Fundal myomectomy suture site.

This is an image showing fundal myomectomy suture site (Figure 5).

DISCUSSION

Recurrence rates of tubal ectopic after salpingectomy is 10%, salpingotomy is 15% and following medical treatment ranges from 10.2% to 18.7%.^{4,6} It has been reported that the incidence of ectopic pregnancy has increased from 0.5 to 2% in 30 years.^{7,8} A high index of suspicion is important for early diagnosis of ectopic. Expectant management, surgical or medical management are the treatment options for ectopic pregnancy. The patients with low or declining beta hCG levels are candidates for expectant management. Hemodynamically unstable patients, heterotopic pregnancy, tubal rupture, failed medical therapy are indications for surgical treatment.³ In this case, in view of her previous history of recurrent tubal ectopic gestations and non-salvageable tubal condition salpingectomy was ideal option. Complete salpingectomy should be preferred as in future they can be referred for assisted reproductive techniques. Less than one third of the patients who had been treated for PID were identified with infectious tubal pathology. In our case patient had recurrent ectopic in ipsilateral tube after salpingotomy. Early diagnosis of ectopic pregnancy in contralateral tube was possible this time with high suspicion and thus medical management was tried as patient was hemodynamically stable.

CONCLUSION

Early diagnosis with high index of suspicion before the onset of catastrophic event is important in case of recurrent ectopic pregnancy. Here, a rare case of recurrent 3rd ectopic following one-sided salpingectomy

may be due to infectious tubal pathology. Decision of medical management was chosen as patient was hemodynamically stable, later surgical treatment of complete left sided salpingectomy was done which was an ideal option.

Funding: No funding sources

Conflict of interest: None declared

Ethical approval: Not required

REFERENCES

1. Odendaal HJ, Schaetzing AE, Kruger TK. Textbook of Clinical Gynecology. 2nd Edition. Juta Academic publisher. Cape Town, South Africa; 2001.
2. Jophy R, Thomas A, Mhaskar A. Ectopic pregnancy 5 years' experience. *J Obstet Gynecol India.* 2002;52(4):55-8.
3. Yao M, Tulandi T. Current status of surgical and nonsurgical management of ectopic pregnancy. *Fertil Steril.* 1997;67:421.
4. Department of Health. Why mothers die? In: Department of Health, eds. The Report on Confidential Enquiries into Maternal Deaths in the United Kingdom 1997-1999. London: HMSO; 2001.
5. Luciano G. Nardo. The dilemma of recurrent ectopic pregnancy after tubal surgery and in vitro fertilization. What to do? *Reprod Biomed Online.* 2005;10(3):300.
6. Pisarska MD, Carson SA. Incidence and risk factors for ectopic pregnancy. *Clin Obstet Gynecol.* 1999;42(2-8):55-6.
7. Nabeshima H, Nishimoto M, Utsunomiya H, Arai M, Ugajin T, Terada Y, et al. Total laparoscopic conservative surgery for an intramural ectopic pregnancy. *Diagnos Therap Endos.* 2010;2010.
8. Thia EW, Loi K, Wang JJ, Siow A. Methotrexate treatment for ectopic pregnancy at the KK Women's and Children's Hospital, Singapore. *Singapore Med J.* 2009;50(11):1058-61.

Cite this article as: Prabhudev P, Sapna IS, Mudegoud SM. A rare case report of recurrent ectopic pregnancy. *Int J Reprod Contracept Obstet Gynecol* 2020;9:1753-6.