

DOI: <http://dx.doi.org/10.18203/2320-1770.ijrcog20183363>

Case Report

Successful term pregnancy post laparoscopic management of thick perforate upper transverse vaginal septum

Manjula Anagani, Prabha Agrawal*, B. Radhika, Amodita Ahuja

Department of Obstetrics and Gynecology, Maxcure Suyosha Women and Child Hospital, Hyderabad, Telangana, India

Received: 14 June 2018

Accepted: 07 July 2018

***Correspondence:**

Dr. Prabha Agrawal,

E-mail: drprabha1001@yahoo.com

Copyright: © the author(s), publisher and licensee Medip Academy. This is an open-access article distributed under the terms of the Creative Commons Attribution Non-Commercial License, which permits unrestricted non-commercial use, distribution, and reproduction in any medium, provided the original work is properly cited.

ABSTRACT

A 30-year-old woman presented with dyspareunia and infertility and was referred to after failure to visualize cervix during diagnostic laparoscopy by her primary consultant. Preoperative MRI was done which showed mild arcuate uterus with minimum fluid in vaginal cavity with vertical vaginal septum. This was managed successfully by a combined laparoscopic and vaginal approach. She conceived spontaneously and delivered a healthy term baby by caesarean section. Upper thick Transverse Vaginal Septum is a complex congenital malformation posing challenges for its correction, restoring normal healthy sex life and conception. The septum varies in thickness and may be located anywhere along the vagina reducing the functional length of the vagina. Identifying and dissecting the anatomic structures is greatly aided by panoramic view of laparoscope allowing the surgeon to have an increased degree of freedom during surgery.

Keywords: Complex congenital malformation, Dyspareunia, Infertility, Transverse vaginal septum

INTRODUCTION

Transverse Vaginal Septum (TVS) is a rare congenital utero- vaginal anomaly with a reported incidence of 1 in 70,000 females.¹ While it may be an isolated finding, it is often associated with imperforate hymen, ectopic ureter, vesicovaginal fistula, bicornuate uterus and septate uterus.² A vaginal septum is caused by incomplete fusion of the separating tissue between the fused Mullerian ducts and the vaginal plate.³

The majority of vaginal septa are located in the upper and middle third of the vagina; and thicker septa usually are closer to the cervix.³ TVS differs from vaginal agenesis in that the Mullerian structures are usually not affected.⁴ Septae can be perforate or imperforate and vary in their thickness and location in the vagina. Imperforate TVS

present early with signs and symptoms of obstructed menstruation and haematocolpos.

Women with a perforate TVS often have normal menses and usually present with dyspareunia, infertility or tampon usage. Treatment involves surgical resection of the septum and anastomosis of the proximal and distal vagina. This can be performed vaginally, laparoscopically, or via an abdominoperineal approach, depending on the location and thickness of the septum.⁵

The primary goals of surgical intervention in patients with vaginal atresia are to relieve obstruction and pain, to restore a normal sex life, and to preserve the patient's reproductive potential.⁶ Patients and surgeons need to be aware of the complexity and risks involved in managing mid or high thick septae.

CASE REPORT

A 30-year-old female was referred to after failure to visualize cervix during diagnostic laparoscopy for infertility. She came with complaints of dyspareunia and inability to conceive. Her menstrual cycles were regular. On examination she was found to have a vaginal length of 5 cm with upper transverse vaginal septum with non-visualized pin hole aperture. Cervix was not visualized. Preoperative MRI showed mild arcuate uterus 93x59x36.8cm with endometrial thickness 4.3 mm with minimum fluid in vaginal cavity with vertical vaginal septum [Figure 1].

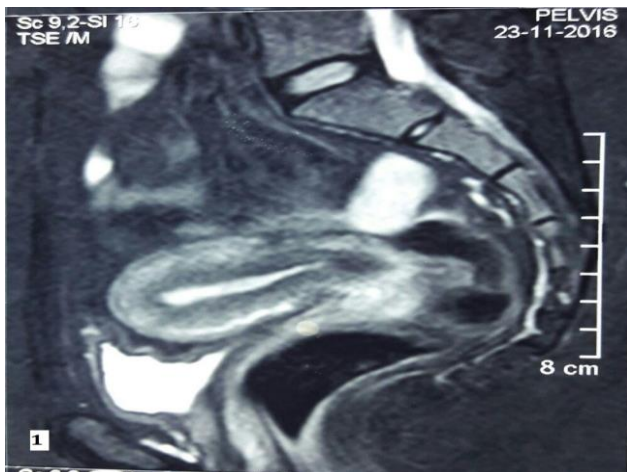


Figure 1: Preoperative MRI showing mild arcuate uterus with min fluid in vaginal cavity with vertical vaginal septum.

Kidneys and pelvic/lyceal system was seen normal. On the basis of clinical examination and radiologic studies, diagnosis of perforate transverse vaginal septum was made and decision of septum resection under laparoscopic guidance was taken. Patient was placed in dorsal lithotomy position. Perineal examination showed blind vagina of length 5cm with non-visualization of cervix. No bulging or bluish discoloration was seen (Figure 2a). laparoscopy showed normal bilateral ovaries and fallopian tubes with normal uterus. Three small 2x2 cm fibroids seen on posterior wall of uterus. The vesicouterine fold was opened (Figure 2b) and anterior colpotomy was done. The posterior peritoneum was opened and the rectovaginal pouch opened and entered into dead space. Once these steps were complete, the cervix was seen from above. A dilator was placed in contact with the septum vaginally and pushed upwards. Once the tip of the dilator becomes visible septum was perforated.

A transverse incision was given on the perforated part of septum and dissection was done carefully (Figure 2c). Vaginally cervix was seen after opening septum (Figure 2d). The vaginal septum was lifted with tissue forceps and separated from vaginal mucosa circumferentially with a scalpel. Anterior colpotomy was closed vaginally.

Raw vaginal edges stitched with everting sutures at 2, 5, 7, 10 o' clock positions. Posterior colpotomy closed laparoscopically. Myomectomy was done and interceed was placed. Postoperative dilatation explained. Follow-up was done after 1, 3 and 6 months, which revealed large capacious vagina with healthy mucocutaneous junction. She was sexually active during follow-up without difficulty. HSG performed at 3 months post-surgery revealed normal uterine cavity with bilateral tubal patency. Patient conceived spontaneously after a year and delivered a healthy term baby by caesarean section.

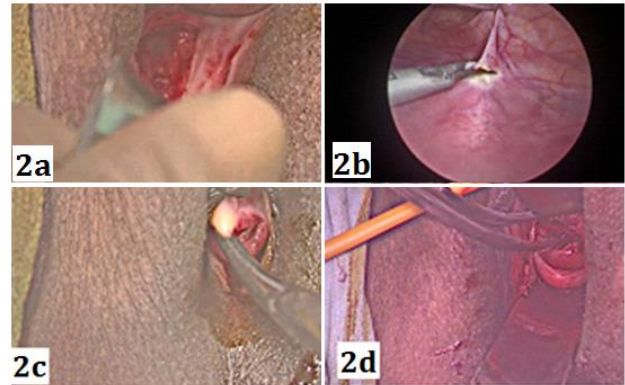


Figure 2: Operative view showing (a) transverse vaginal septum with non-visualization of cervix; (b) laparoscopy guided urinary bladder retraction; (c) opening of transverse vaginal septum from vagina; (d) visualization of cervix after septum resection.

DISCUSSION

The female genital system develops from the paired Mullerian ducts and in close association with the urinary system and hindgut.⁷ Transverse Vaginal Septum is a type of vertical fusion defect arising from fusion of urogenital sinus and paramesonephric ducts. Delaunay first described the transverse vaginal septum in 1877.⁸ The prevalence of this anomaly is reported to be 1 in 70,000.¹ The cause is unknown, although some cases may be the result of a female sex limited autosomal recessive transmission.⁹ A wide variety of Mullerian abnormalities has been described in the literature. Various combinations of the anomalies may co-exist in a single subject.¹⁰ The septa are frequently accompanied by urinary tract abnormalities, such as unilateral renal agenesis, ectopia, or fusion.¹¹ The most common genital anomalies associated are uterus bicollis with an obstructing partial vaginal septum and the unicornuate uterus with a rudimentary horn.¹¹

Upper thick Transverse Vaginal Septum is a complex congenital malformation posing challenges for its correction, restoring normal healthy sex life and conception. The septum may be located anywhere along the vagina and varies in thickness. This may reduce functional capacity of vagina leading to dyspareunia. TVS differs from vaginal agenesis in that the Mullerian

structures are usually not affected.⁴ As a result, the uterus, cervix, and upper portion of the vagina are normal. If the septum is perforate, the thickness can usually be determined upon vaginal examination. For imperforate septae, the thickness of the septum can be measured on MRI. MRI is a matchless tool for high quality images of uterus, adnexa and other pelvic structures.² The presentation of the complete septum is either in neonatal period with mucocolpus or at puberty with pain and/or amenorrhea and pelvic mass which are caused by haematocolpus, haematometra and haematosalpinx.¹² Women with a perforate TVS often have normal menses and usually present with dyspareunia, infertility or tampon usage.

In a study by Williams et al there were 46 cases, all presenting with a diagnosis of TVS between 1998 and 2012. In their study location of septa was described as low < 3 cm, mid 3 -6 cm and high >6 cm depending on the distance from the vaginal introitus to the distal end of the septum.⁵ Thickness of septum varied from <1 cm (thin) to ≥1 cm (thick).⁵ Their study revealed good outcomes for all low and perforate transverse septae. Outcomes in thicker and high septae were poorer, with a high chance of repeat surgery as well as complications like restenosis and rectovaginal fistulae.⁵ In their study there were seven pregnancies. All pregnancies were in the group who had vaginal excision of TVS, as the septae were all thin. In their study group none of the patients with a thick septum conceived.⁵

In a study by Rock et al three patients of TVS, which were low, mid, and imperforate were studied, Two out of three patients had re-stenosis requiring repeat surgery.⁵ Rock et al showed a significantly reduced chance of conception in mid and high septae than low septae.⁵ The cause for low fertility has not yet been determined and vaginal stenosis may be a contributory factor; however, Rock et.al reported high rates of endometriosis in mid and high septae which might be causative.⁵ There is scanty published data on the choice of surgical technique used, short or long-term outcomes following the resection and postoperative pregnancy rates in thick septa. Complications include continued dyspareunia, vaginal re-occlusion, recurrent surgical intervention, endometriosis, infertility and psychological morbidity. Laparoscopy offers an advantage of panoramic view, better depth perception and dissection of anatomic structures thereby avoiding pelvic injuries, adhesions and post-operative morbidity. Vaginal dilation is usually recommended after reconstruction to maintain vaginal patency and capacity and to prevent stricture, stenosis or re-obstruction.⁵ Coital function is usually normal after surgery, and pregnancy rates are 40-50% for septum in the lower or middle third of the vagina.¹³

Funding: No funding sources

Conflict of interest: None declared

Ethical approval: Not required

REFERENCES

1. Sharma R, Weerakkody Y. Transverse vaginal septum. Radiopedia. System: Paediatrics, Gynaecology. Section: Anatomy. Revision 17, rID: 15382. Available at: <https://radiopaedia.org/articles/transverse-vaginal-septum>
2. Jain N, Gupta A, Kumar R, Minj A. Complete imperforate transverse vaginal septum with septate uterus: a rare anomaly. *J Hum Reprod Sci.* 2013 Jan-Mar;6(1):74-6.
3. Gupta R, Bozzay JD, Williams DL, DePond RT, Gantt PA. Management of Recurrent Stricture Formation after Transverse Vaginal Septum Excision. *Case Reports Obstet Gynecol.* 2015;2015.
4. Pushkar P, Rawat SK, Chowdhary SK. Robotic approach to vaginal atresia repair in an adolescent girl. *Urol Annals.* 2015 Jul;7(3):396.
5. Williams CE, Nakhil RS, Hall-Craggs MA, Wood D, Cutner A, Pattison SH, et al. Transverse vaginal septae: management and long-term outcomes. *BJOG: An Int J Obstet Gynaecol.* 2014 Dec;121(13):1653-8.
6. Giannesi A, Marchiole P, Benchaib M, Chevret-Measson M, Mathevet P, Dargent D. Sexuality after laparoscopic Davydov in patients affected by congenital complete vaginal agenesis associated with uterine agenesis or hypoplasia. *Human Reprod.* 2005 Jun 24;20(10):2954-7.
7. Caloia DV, Morris H, Rahmani MR. Congenital transverse vaginal septum: vaginal hydrosonographic diagnosis. *J Ultrasound Med.* 1998 Apr;17(4):261-4.
8. Delaunay JV. Etude sur le cloisonnement transversal du vagin complet et incomplet d'origine congenital. Thesis, Paris. 1877.
9. Reed MH, Griscom NT. Hydrometrocolpos in infancy. *AJR.* 1973;118:1.
10. Ara S, Tahir S. Diagnosis and management of congenital anomalies of vagina. *APMC.* 2011;5:124.
11. Ammann AM, Brewer WH, Hurt WG. A high transverse vaginal septum: sonographic findings. *J Ultrasound Med.* 1983 Oct;2(10):471-2.
12. Meyers RL. Congenital anomalies of the vagina and their reconstruction. *Clin Obstet Gynaecol.* 1997;40:168-80.
13. Tiwari C, Shah H, Singhavi S. Low complete transverse vaginal septum, vesico-ureteric reflux and low anorectal malformation: Case report and review of literature. *Int J Ped Adol Med.* 2016 Jun 1;3(2):81-4.

Cite this article as: Anagani M, Agrawal P, Radhika B, Ahuja A. Successful term pregnancy post laparoscopic management of thick perforate upper transverse vaginal septum. *Int J Reprod Contracept Obstet Gynecol* 2018;7:3429-31.