

DOI: <http://dx.doi.org/10.18203/2320-1770.ijrcog20171984>

Case Report

Uterine arteriovenous malformation

Sneha S. Patki*, Trishula Dabade, Vijay Kumar

Department of Obstetrics and Gynecology, Chinmaya Mission Hospital, Bangalore, Karnataka, India

Received: 22 February 2017

Accepted: 27 March 2017

***Correspondence:**

Dr. Sneha S. Patki,

E-mail: snehaptk@gmail.com

Copyright: © the author(s), publisher and licensee Medip Academy. This is an open-access article distributed under the terms of the Creative Commons Attribution Non-Commercial License, which permits unrestricted non-commercial use, distribution, and reproduction in any medium, provided the original work is properly cited.

ABSTRACT

Uterine arteriovenous malformation (AVM) is a rare condition. It can become life threatening due to the profuse bleeding with which patients may present. This case report presents a case of a 40-year-old lady who presented with repeated episodes of bleeding per vaginum after a dilatation and evacuation for an induced abortion. Ultrasound along with Doppler showed AVM in the anterior body of the uterus which was eventually confirmed by Magnetic Resonance Imaging. With no desire to preserve future fertility, our patient underwent a laparoscopic assisted vaginal hysterectomy successfully. The diagnosis was confirmed on histopathology.

Keywords: Acquired AVM, Doppler, MRI, Uterine arteriovenous malformation, Ultrasound

INTRODUCTION

Uterine arteriovenous malformation (AVM) is a rare but a life-threatening condition with fewer than 100 cases reported in the literature.¹

First described by Dubreil and Loubat, it is seen in women aged 18-72 years but rarely in nulliparous women.²

Classified as congenital and acquired types, uterine AVM's have multiple communications of varying sizes between arteries and veins in the same vicinity.³ Abnormality in the embryological development of primitive vascular structures which result in multiple abnormal communications between arteries and veins result in congenital AVM.

Causes for acquired AVM are usually traumatic - prior Dilatation and Curettage, uterine surgery, uterine trauma, endometrial carcinoma, cervical carcinoma, gestational trophoblastic disease.⁴

Incorporation of venous sinuses in scarred myometrial areas following chorionic villus necrosis may lead to

AVM suggesting that pregnancy may play a role in the pathogenesis.⁵ Severe uterine bleeding with no obvious cause is the most common presentation of uterine AVM. Lower abdomen pain, dyspareunia and anemia due to blood loss can be the other presenting symptoms.⁴

Ultrasound Doppler, computed tomography (CT), magnetic resonance imaging (MRI) and angiography are the various diagnostic modalities for diagnosing uterine AVM's. Angiography is regarded as the gold standard for diagnosis.

Various treatment modalities are available depending on the desire to preserve future fertility. Medical modalities like estrogens, progestins, methyergometrine, danazol and 15-methyl PGF₂ α are tried. For women desiring future fertility, embolotherapy, uterine artery ligation have been used.

CASE REPORT

Case of 40 years female P2L2 with previous 2 full term uneventful vaginal deliveries who visited the out-patient department of Chinmaya Mission Hospital, Bangalore with complaints of bleeding per vaginum on and off for 2

months. She had undergone an induced abortion by Dilatation and Evacuation prior to the bleeding episode in her hometown. She continued to bleed on and off even after the procedure.

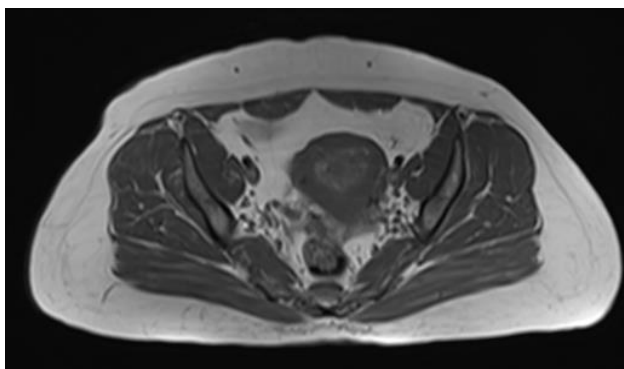


Figure 1: Axial T1 weighted MRI pelvis pre-contrast image.

On examination in the out-patient department, her pulse, temperature and blood pressure were within normal limits. On abdominal examination, no mass was felt per abdomen and spleen and liver were not enlarged.

On per speculum examination, bleeding from os was present. Per vaginum examination revealed a retroverted bulky uterus with cervix pointing anteriorly and cervical os closed.

On transvaginal sonography (TVS), tiny cystic areas in the uterine cavity with no evidence of gestational sac was reported.

A dense echogenic shadow in the endometrial cavity was seen and foreign body was suspected. Overall impression given was of a molar gestation.

Serum β hCg value was 10 μ IU/ml. She underwent a dilatation and evacuation in our hospital and sample was sent for histopathology.

Histopathology report was suggestive of degenerated products of conception. Patient was discharged with stable vitals and on oral antibiotics.

There was no bleeding per vaginum at the time of discharge. Patient returned 16 days after the discharge to the out-patient department with similar complaints of bleeding per vaginum on and off.

On repeating a TVS, it revealed an anteverted bulky uterus measuring 9x5.1 cms, normal myometrium with multiple echogenic foci measuring 4-13mm in the endometrial cavity and free fluid in the pouch of Douglas.

Scan impression was retained products of conception. Serum β hCg was 6.23 μ IU/ml.

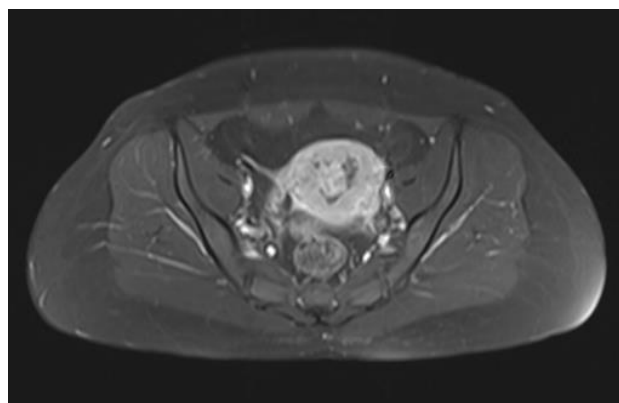


Figure 2: Axial T1 weighted fat saturated post contrast image of the MRI pelvis showing lobulated tortuous intensely enhancing lesion within the endometrial cavity.

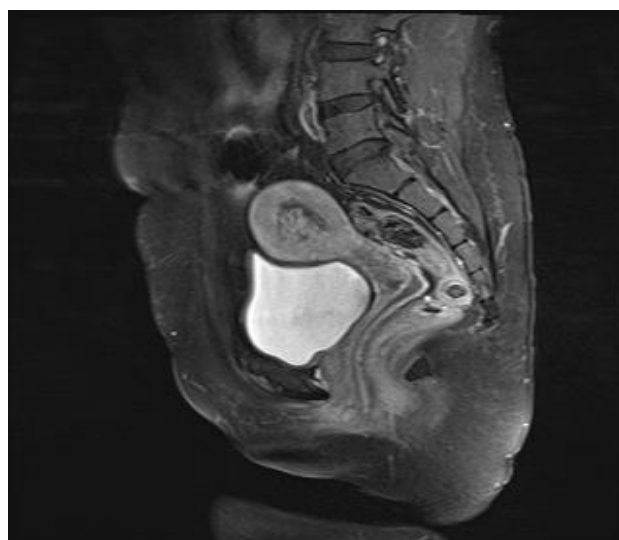


Figure 3: Sagittal T1 weighted post contrast fat saturated image of MRI pelvis showing the tortuous vascular channels in endometrial cavity.

She was advised Tablet methergin once a day for 10 days. No change or reduction in the bleeding pattern was observed by the patient.

She underwent a TVS again, which revealed an anterior myometrial echopattern which was heterogenous with multiple cystic areas within the uterus. Endometrial thickness was 6mm with few calcific foci in the anterior aspect. Doppler showed increased flow with low vascular resistance in the anterior aspect. Uterus measured 8.6x4.4x5.2 cms. Impression of the TVS with Doppler was uterine AVM with calcific foci in the endometrial cavity.

MRI was done which reported a focal area of heterogenous signal intensity lesion with multiple tortuous vascular channels noted in the anterior body of the uterus consistent with AVM measuring 3.6x2.6x3.8 cms.

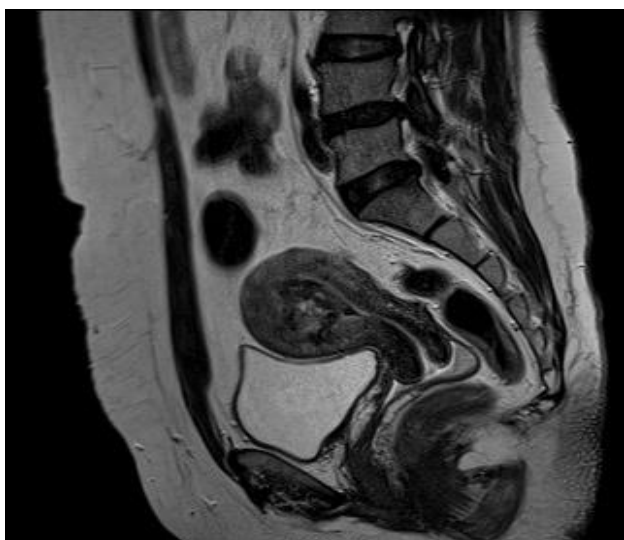


Figure 4: Sagittal T2 weighted image of the MRI pelvis showing multiple tortuous flow voids in the endometrial cavity consistent with the high velocity vascular channels.

She had completed her family and hence a permanent method of treatment was chosen by her - laparoscopic assisted vaginal hysterectomy. Intraoperative findings were - soft, bulky, retroverted uterus with normal tubes and ovaries with minimal filmy adhesions. Post-operative period was uneventful. She was discharged on 4th post-operative day with stable vitals, adequate urine output and a normal diet. Histopathology report was confirming the TVS and MRI report.

DISCUSSION

Uterine AVM's are an uncommon vascular disease and accounts for 2% of all the genital and intraperitoneal haemorrhages.⁶ Proliferation of arterial and venous channels with fistula formation and mixture of capillary-like vessels is seen in AVM. Increased intraluminal pressure causes secondary intimal thickening in the veins making distinction between arteries and veins difficult.⁷

Congenital type have multiple vascular connections and they invade the surrounding structures. The acquired variety is confined to the myometrium and/or endometrium and shows direct communication between intramural branches of uterine artery and myometrial veins.⁸ Acquired AVM's are more common and the potential to develop abnormal communication occurs during the healing process between the arteries and veins when typically a single artery joins a single vein.⁹

In the present case, the abnormal uterine bleeding along with the Serum β hCg values and TVS suggested a diagnosis of retained products of conception, given her past history of induced abortion. After the 2 dilatation and curettages and Serum β hCg values, the suspicion that

it could be a uterine AVM giving a false impression of retained products of conception was postulated.

TVS with Doppler may point to the diagnosis of uterine AVM but it may be confusing as it happened in this case.⁹

Localised area of increased vascularity within the myometrium can be seen in the colour doppler. Pulsed doppler evaluation of the particular area reveals a low resistance blood flow with high peak velocities and evidence of turbulence.³

MRI gives an accurate diagnosis and also delineates the invasion of adjacent organs. Characteristic features are a bulky uterus with a focal mass, disruption of the junctional zones, multiple flow related signal voids within the lesion and prominent parametrial vessels.^{3,10}

The gold standard for the diagnosis is digital subtraction angiography which shows bilateral hypertrophy of uterine arteries that feed a tortuous, hypertrophic arterial mass with large accessory feeding vessels and early drainage in to enlarged hypertrophic veins.¹⁰

Management of a case of uterine AVM depends on her hemodynamic stability and her desire to preserve future fertility. Management can be conservative using medical modalities which was initially tried in this case using methylergometrine which did not benefit the patient. Transcatheter embolisation gives the advantage of fertility preservation.

In the present case, with no desire to preserve fertility, our patient underwent a laparoscopic assisted vaginal hysterectomy with no post-operative complications.

Uterine AVM's should be suspected and a differential diagnosis must be kept in mind especially for women with prior history of induced abortion or dilatation and curettage.

Funding: No funding sources

Conflict of interest: None declared

Ethical approval: Not required

REFERENCES

1. Hickey M, Fraser IS. Clinical implications of disturbances of uterine vascular morphology and function. *Baillieres Best Pract Res Clin Obstet Gynaecol.* 2000;14(6):937-51.
2. Diwan RV, Brennan JN, Selim MA, McGrew TL, Rashad FA, Rustia MU, et al. Sonographic diagnosis of arteriovenous malformation of the uterus and pelvis. *J Clin Ultrasound.* 1983;11(5):295-8.
3. Huang MW, Muradali D, Thurston WA, Burns PN, Wilson SR. Uterine arteriovenous malformations: gray-scale and Doppler US features with MR imaging correlation. *Radiol.* 1998;206(1):115-23.

4. Chen Y, Wang G, Xie F, Wang B, Tao G, Kong B. Embolization of uterine arteriovenous malformation. *Iran J Reprod Med.* 2013;11(2):159-66.
5. Hoffman MK, Meilstrup JW, Shackelford DP, Kaminski PF. Arteriovenous malformations of the uterus: an uncommon cause of vaginal bleeding. *Obstet Gynecol Surv.* 1997;52(12):736-40.
6. Cura M, Martinez N, Cura A, Dalsaso TJ, Elmerhi F. Arteriovenous malformations of the uterus. *Acta Radiol.* 2009;50(7):823-9.
7. Fleming H, Ostor A, Pickel H, Fortune D. Arteriovenous malformations of the uterus. *Obstet Gynaecol.* 1989;73(2):209-13.
8. Nicholson AA, Turnbull LW, Coady AM, Guthrie K. Diagnosis and management of uterine arterio-venous malformations. *Clin Radiol.* 1999;54(4):265-9.
9. Hashim H, Nawawi O. Uterine arteriovenous malformation. *Malays J Med Sci.* 2013;20(2):76-80.
10. Grivell RM, Reid KM, Mellor A. Uterine arteriovenous malformations: a review of the current literature. *Obstet Gynecol Surv.* 2005;60(11):761-7.

Cite this article as: Patki SS, Dabade T, Kumar V. Uterine arteriovenous malformation. *Int J Reprod Contracept Obstet Gynecol* 2017;6:2115-8.