

DOI: <http://dx.doi.org/10.18203/2320-1770.ijrcog20200394>

Case Report

Hyperreactio luteinalis: benign tumour associated with pregnancy mimicking ovarian malignancy

Nazli Tarannum*, Nishat Akhtar

Department of Obstetrics and Gynecology, Jawaharlal Nehru medical College and Hospital, Aligarh Muslim University, Aligarh, Uttar Pradesh, India

Received: 27 August 2019

Revised: 21 December 2019

Accepted: 27 December 2019

***Correspondence:**

Dr. Nazli Tarannum,

E-mail: nazlinator@gmail.com

Copyright: © the author(s), publisher and licensee Medip Academy. This is an open-access article distributed under the terms of the Creative Commons Attribution Non-Commercial License, which permits unrestricted non-commercial use, distribution, and reproduction in any medium, provided the original work is properly cited.

ABSTRACT

Hyperreactio luteinalis refers to pregnancy related enlargement of B/L ovaries rarely unilateral ovary, moderate to marked size due to multiple theca lutein cysts. It is a rare finding associated with pregnancy seen commonly in multiple gestation, GTDs and fetal abnormalities: viz hydrops. It is caused by elevated B-hcg level. We report a case of 28 years old female, primi with 13 spontaneously conceived weeks pregnancy who presented to ANC OPD for regular check-up and vague abdominal discomfort. USG revealed a large right sided ovarian mass, solid cystic in appearance pushing the uterus to left side and upwards. Staging laparotomy was done at 14 weeks viewing it to be a malignant mass. Unilateral right sided oophorectomy was done along with biopsy taken from left ovary. On microscopic histological examination diagnosis of hyperreactio luteinalis unilateral ovary was made. Hyperreactio luteinalis mimicking ovarian malignancy on USG results in unnecessary surgical intervention.

Keywords: Elevated B-hcg level, Solid cystic ovarian mass, Oophorectomy, Pregnancy related

INTRODUCTION

Hyperreactio luteinalis is a rare pregnancy complication. It is second most common ovarian disorder of pregnancy after leuteoma of pregnancy. Highest incidence is associated with GTD and rarely seen with singleton pregnancy.¹ HL is thought to be due to elevated B-hcg level or abnormal ovarian response to normal B-hcg level.¹

Patient with HL are generally diagnosed incidentally at time of Caesarean section with spontaneous regression in postpartum period.²

Burger described first case of HL un-associated with GTDs in 1938, since then 96 case have been reported

from 1953 to 2013, most of which (54%) in last trimester of pregnancy and 16% in 1st TM.³⁻⁵

The case report describes an unusual case of spontaneously conceived pregnancy after an infertility of 3 years and unilateral hyperreactio leutanolis.

CASE REPORT

This patient a 28 years young lady presented for routine antenatal checkup at 13 weeks of gestation with complaints of vague abdominal discomfort and pain right > left side and vomiting.

She was married for 3 years and was unable to conceive; however, had conceived spontaneously.

On per abdomen examination

It revealed 14 weeks palpable uterus, and a firm mass around 10 cms in right hypochondrium separate from uterus seem to have originated from pelvis and was well encapsulated, with no ascites.

Patient was advised ANC scan along with USG whole abdomen and pelvis. On sonography she had a 14 weeks gestation in uterus with normal cardiac activity and a separate heterogeneous echotexture mass of 12 × 9 cm was found in the Right adnexa having solid cystic component with focal vascularity along with solid nodule and few calcifications.

On lab investigation her CA-125 tumour marker level were markedly raised and was found to be 325 (N < 35). MRI was done to further aid in diagnosis. MRI finding were consistent as of sonography mass effect on uterus, displacing it to left side, abutting bladder and compressing right ureter with little free fluid in pelvis. The mass extended up to the undersurface of liver.

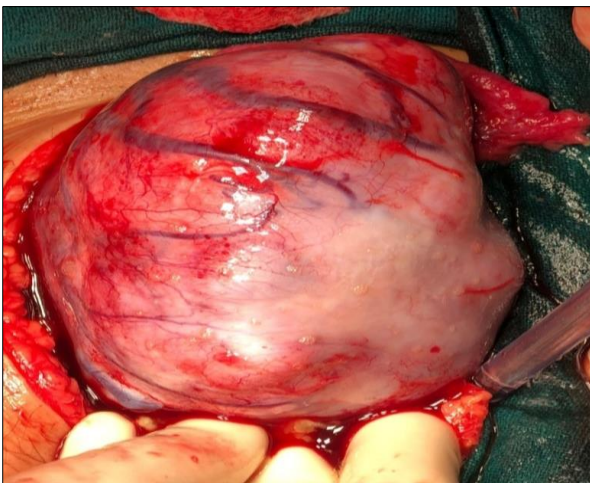


Figure 1: Per op gross tumour.

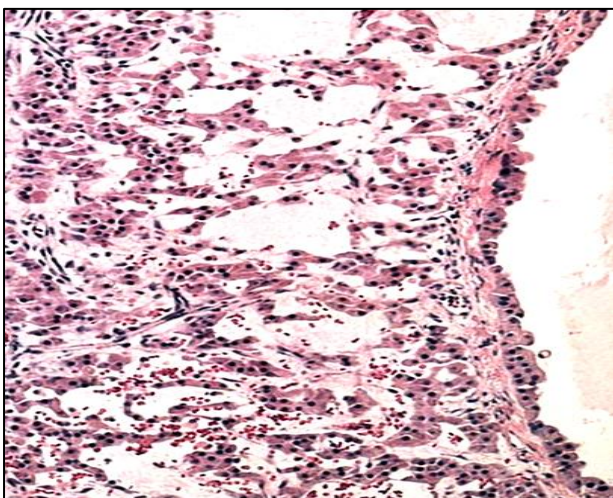


Figure 2: Microscopic view of hyper reactio leutanolis.

As a suspicion of malignancy staging laparotomy was done. Per-op right ovary was seen to be huge, having bosselated appearance with multiple thick vessels as seen in Figure 1. It was around 10 × 15 cm having multiple solid cystic foci appearing it to be a malignant mass. Left ovary however, was found to be normal appearing. Therefore, decision for right sided oophorectomy was taken along with peritoneal washings and biopsy from left ovary and partial omentectomy to rule out malignant foci and cells at other places.

On HPE as seen in (Figure 2) it was reported to show numerous variable sized cysts lined by theca and granulosa cells showing eosinophilic cytoplasm and hob nailing at places, suggestive of hyperreactio leutanolis of ovary, with normal ovarian stroma in other ovary. No malignant cells were seen otherwise.

DISCUSSION

As already mentioned, HL is associated with GTDs, multifetal gestation, fetal hydrops, ovarian hyperstimulation and rarely seen with singleton pregnancy.¹

HL is diagnosed incidentally and may present with vague abdominal discomfort, nausea, emesis, acute abdominal conditions viz torsion or hemorrhage or rarely ascites.² Later in pregnancy it may lead to preeclampsia syndrome or FGR.⁶

This female who conceived after 3 years of infertility had abdominal pain with unilateral adnexal mass and markedly raised CA-125 level. The mass was separate from uterus however producing mass effect and left no space for uterus to grow. On sonography and MRI, it favoured malignancy.⁷

The D/D that included in our case was leutoma of pregnancy, ovarian tumors viz mucinous cyst adenoma, OHSS and acute Meig's syndrome.^{5,8,9}

HL consists of many thin walled leutein cysts with intervening large solid areas which need to be differentiated from mucinous cyst adenoma.⁷

OHSS seen early in pregnancy whereas HL may be seen later also.⁵

HL responds best to conservative management.⁹ No surgery is indicated unless it is imperative to do in cases of complication like torsion or suspicion of malignancy.¹⁰

In our case laparotomy with U/L oophorectomy was done due to suspicion of malignancy.

CONCLUSION

HL is an important diagnosis since it is benign, self-limiting ovarian pathology which can be managed

conservatively except for acute emergencies. It necessitates differentiation from other malignant mass to avoid unnecessary intervention as in our case.

Funding: No funding sources

Conflict of interest: None declared

Ethical approval: Not required

REFERENCES

1. Taylor HS, Pal L, Sell E, Speroff. *Clinical Gynecologic Endocrinology and Infertility. Normal and Abnormal Sexual Development.* 9th edition. Wolters Kluwer; 2019:363-364.
2. Hoffman BL. *Pelvic Mass. Williams Gynecology.* 3rd ed. New York, NY: McGraw-Hill; 2016:266.
3. Van Holsbeke C, Amant F, Veldman J, De Boodt A, Moerman P, Timmerman D. Hyperreactio luteinalis in a spontaneously conceived singleton pregnancy. *Ultrasound Obstet Gynecol.* 2009;33(3):371-3.
4. Cavoretto P, Giorgione V, Sigismondi C, Mangili G, Serafini A, Dallagiovanna C, et al. Hyperreactio luteinalis: timely diagnosis minimizes the risk of oophorectomy and alerts clinicians to the associated risk of placental insufficiency. *Eur J Obstet Gynecol Reprod Biol.* 2014;176:10-6.
5. Foulk RA, Martin MC, Jerkins GL, Laros RK. Hyperreactio luteinalis differentiated from severe ovarian hyperstimulation syndrome in a spontaneously conceived pregnancy. *Am J Obstet Gynecol.* 1997;176(6):1300-2.
6. Gherman RB, Mestman JH, Satin AJ, Goodwin TM. Intractable hyperemesis gravidarum, transient hyperthyroidism and intrauterine growth restriction associated with hyperreactio luteinalis: a case report. *J Reprod Med.* 2003;48:553.
7. Abe T, Ono S, Igarashi M, Akira S, Watanabe A, Takeshita T. Conservative management of hyperreactio luteinalis: a case report. *J Nippon Med Sch.* 2011;78:241-5.
8. Hashmi HA, Tufail A. Hyperreactio luteinalis in association with molar pregnancy. *Pak J Surg.* 2008;24:140-2
9. Cho AR, Song TB, Kim HJ, Kim YH, Kim JW. Vaginal delivery in a spontaneously conceived singleton pregnancy complicated with hyperreactio luteinalis: a case report. *J Womens Med.* 2011;4:53-6.
10. Lynn KN, Steinkeler JA, Wilkins-Haug LE, Benson CB. Hyperreactio luteinalis (enlarged ovaries) during the second and third trimesters of pregnancy: common clinical associations. *J Ultrasound Med.* 2013;32:1285-9.

Cite this article as: Tarannum N, Akhtar N. Hyperreactio leuteinalis: benign tumour associated with pregnancy mimicking ovarian malignancy. *Int J Reprod Contracept Obstet Gynecol* 2020;9:858-60.