

DOI: <http://dx.doi.org/10.18203/2320-1770.ijrcog20162153>

## Case Report

# Uterine necrosis in a case of B-Lynch brace suture

Meena N. Satia\*, Vibha S. More

Department of Obstetrics and Gynaecology, Seth G. S. Medical College and KEM Hospital, Mumbai, Maharashtra, India

**Received:** 12 May 2016

**Revised:** 11 June 2016

**Accepted:** 13 June 2016

**\*Correspondence:**

Dr. Meena N. Satia,

E-mail: meenasatia@kem.edu

**Copyright:** © the author(s), publisher and licensee Medip Academy. This is an open-access article distributed under the terms of the Creative Commons Attribution Non-Commercial License, which permits unrestricted non-commercial use, distribution, and reproduction in any medium, provided the original work is properly cited.

### ABSTRACT

B Lynch is a conservative surgical procedure for Atonic PPH not responding to medical line of treatment very few complications of this procedure have been reported. We describe B-Lynch suture erosion through the uterine wall identified on 16 day postpartum. A 24 year old primigravida underwent a primary low transverse cesarean section at term indication being primigravida with breach presentation intra-operatively there was torrential blood loss and uterus remained flabby despite treatment with uterotonic drugs delayed absorbable suture was used to place B-Lynch suture for control of the hemorrhage and had sepsis for which she had to undergo obstetric hysterectomy.

**Keywords:** B-Lynch, Obstetric hysterectomy, Postpartum haemorrhage, Atonic uterus

### INTRODUCTION

The most common cause of PPH is atonic uterus which is the leading of maternal mortality and morbidity.<sup>1-3</sup> First line to management for atonic uterus is with uterotonic drugs. Majority of cases do respond to medical line of treatment. However, few cases may require second line of surgical treatment like uterine packing, stepwise ligation of the uterine vasculature and if this fails obstetric hysterectomy is definitive surgical management. This result in loss of future fertility. B-Lynch and its modification are conservative management to treat atonic PPH as it preserves fertility. Uterine compression sutures have helped to significantly reduce the number of obstetric hysterectomy. These uterine compression sutures can cause complication like hematometra, pyometra, asherman's syndrome, uterine necrosis.

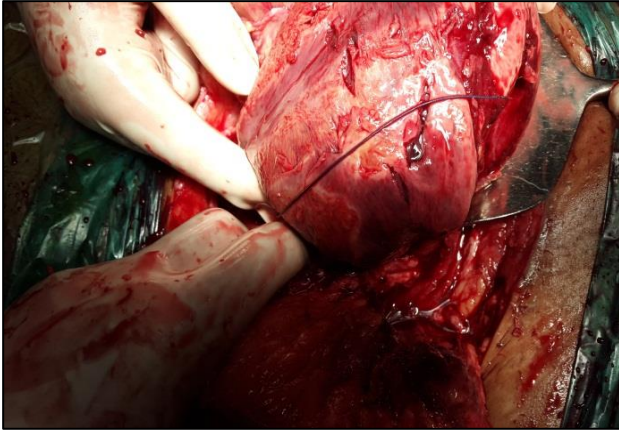
The B-Lynch uterine suture brace is a relatively new technique used for treatment of postpartum haemorrhage before the advent of B-Lynch suture obstetric hysterectomy was performed for atonic PPH. B-Lynch suture should be tried in cases of atonic PPH before proceeding to stepwise ligation of the uterine vasculature. The advantages of B-Lynch suture is that it appears to be

an effective to control severe persistent PPH following failure of vessel ligation before considering obstetric hysterectomy.<sup>4</sup> To date only few complications of this procedure have been reported. We would like to report a case of B-Lynch suture which caused erosion and necrosis of the uterine wall resulting in peritonitis with sepsis identified on day 16 postpartum.

### CASE REPORT

A 24 year primiparas was transferred from private maternity hospital to our receiving room, in view of postoperative abdominal distension, febrile illness and 3-4 episodes of vomiting each day since one week. She had undergone emergency LSCS the indication being primigravida with breach presentation she delivered a male child of 3.2 kg. Intra-operatively uterus was flabby, atonic not responding to uterotonic agents Delayed absorbable suture was used to place B-Lynch suture for control of the haemorrhage on 16<sup>th</sup> day postpartum examination she presented to a tertiary care centre with sepsis operative notes showed that intra-operatively patient had episode of atonic post-partum haemorrhage which was managed by B-Lynch sutures after both the first and second line management of PPH failed. Three

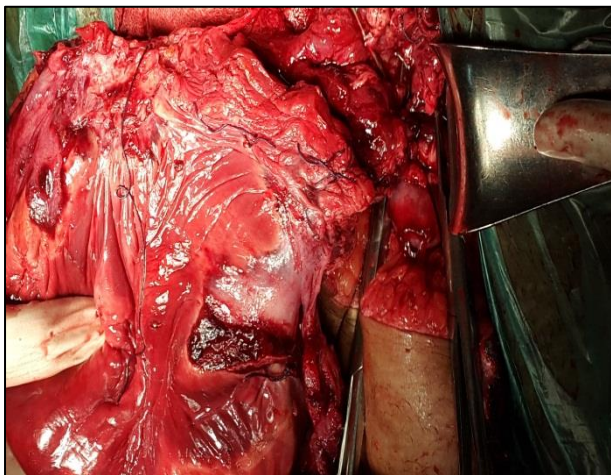
units of packed cell were given immediate postoperative period she had settled ,later she developed high grade fever from day 9 of LSCS for which she was advised to take oral antibiotics for 5 days but her symptoms persisted for which, she was referred to a tertiary care centre for further management.



**Figure 1: Intraoperative findings were as follows.**

Uterus was flabby, necrotic, foul smelling, 26 weeks size. Two vicryl sutures were present on antero-posterior surface of uterus, which had to be cut Post wall of the uterus was densely adherent to the bowel.

Purulent material was seen coming out from uterine cavity communicating with the collection in the parietal wall. The uterine edges were fragile and necrosed.



**Figure 2: Intra-operative findings.**

Pus flakes adherent to bowel at multiple places. Adhesions separated by blunt and sharp dissection serosa tears sutured by the general surgeons.

On examination in receiving room she was febrile and tachypnoeic with a RR of 30 per minute. Her pulse was 124 beats per minute and blood pressure of 110/70 mmHg. On per abdominal examination there was

tenderness in all the quadrants. There was erythema and induration around lower segment caesarean section scar and there was wound gape up to rectus sheath, wound was unhealthy and there was purulent discharge. On per vaginal examination internal os was open, lochia foul smelt, and uterine size was around 24-26 weeks. Provisional diagnosis of puerperal sepsis with abdominal wound gape was made and patient admitted. All her investigations complete blood count, liver and renal function tests, fever profile, high vaginal swab, urine routine microscopy, urine culture and sensitivity and wound swab sent. Her haemoglobin 8.5gm%, WBC count of 30,800 platelets adequate. Fever profile including peripheral smear for malarial parasite, leptospira, dengue, widal for typhoid all tests were negative. Urine routine and microscopy showed no pus cells. Liver and renal function tests were normal. ECG normal patient started on broad spectrum antibiotics. Ultrasonography did not show any evidence of retained products of conception. Wound swab report showed growth of E. coli sensitive to colistin and vancomycin. Injectable vancomycin 2 MU, four times a day was given. On day 2 of her hospital stay, patient developed progressive abdominal distension, vomiting and breathlessness. General condition deteriorated she had high grade fever of 400 celsius, pulse rate of 130 beats per minute. Patient had tachypnoea with respiratory rate of 36 per minute. On PA examination there was generalised distension and tenderness, size of uterus 24 to 26 weeks. Dressing was soaked. Per vaginal examination os was open, suture material felt in cervical canal, lochia foul smelt. Provisional diagnosis of puerperal sepsis made. Urgent X-ray abdomen was done to rule out subacute intestinal obstruction and computed tomography was also done. X ray revealed no abnormality. CT scan showed uterus sub-involved, large collection within endometrial cavity of 10.5×20×13 cm, sloughing off of the left uterine wall with communication with collections outside. Diagnosis of rupture was given by CT scan report In view of above findings decision of exploratory laparotomy was taken.

Obstetric hysterectomy was performed. Post operatively patient received two unit of packed cell volume, continued on injection colistin. Everyday patient had a fever spikes of 39-40 0 celsius, WBC count of 32000 per cubic mm, blood culture showed no growth. On day 5 of obstetric hysterectomy purulent discharge was seen draining from the wound .There was full length abdominal wound gape till rectus sheath .Repeat wound swab sent which showed growth of two organisms enterococcus faecium and E. coli sensitive to linezolid and colistin respectively. Along with colistin patient started on injectable linezolid 600 mg twice a day. Daily dressing continued. Patient responded to above antibiotics patient was afebrile WBC count tapered from 32000 to 16,000. On day 15 of abdominal wound gape secondary suturing done after wound swab report showed no growth. Suture removal done on day 14 of secondary suturing, wound healthy. Patient discharged on day 30 of

her hospital stay. Histopathology report showed necrosis of uterus.

## DISCUSSION

To define PPH blood loss should be of more than 500 ml after normal delivery and more 1000 ml during cesarean section and this occurs in around 5% of all deliveries.<sup>5</sup> It is a potentially dangerous obstetric complication and is associated with risk of morbidity and mortality. Atonic uterus is the most common and preventable cause of postpartum hemorrhage constituting around 80% which usually responds to uterotonic drugs.<sup>6</sup> However few patients may require surgical intervention, second-line therapy includes packing of the uterine cavity, selective ligation of the uterine vasculature or referral to interventional radiologist for embolization of the major blood vessels.<sup>7,8</sup> B-Lynch sutures and its modifications are new surgical modality in patients with PPH.

B-Lynch and colleagues in 1997, described this surgical technique for atonic uterus. In this, pair of vertical brace sutures is secured around the uterus with no 2 chromic catgut. This suture works by compressing the anterior and posterior wall placental bed thus reducing the uterine blood loss the objective of this surgical technique is to compress uterus without occluding uterine arteries. The success rate of this suture is 86.4% in avoiding obstetric hysterectomy and thus this suture are widely recommended for atonic PPH.<sup>4</sup> Successful pregnancies have been reported after B-Lynch suture. These uterine compression sutures can cause complication like hematometra, pyometra, asherman's syndrome, uterine necrosis. Cases of uterine necrosis presenting several weeks postpartum may present with sepsis ultimately requiring total or subtotal hysterectomy have been reported. Hematometra presents with amenorrhea and pyometra presents with abdominal pain and fever. Several case report have reported uterine ischemic necrosis as complication after B-Lynch sutures (Gottlieb, Joshi, Ochoa, Treloar, and all their colleagues).<sup>8-11</sup> Compression of an already ischemic uterus due to excessive blood loss and prolonged labour may further aggravate necrosis and infection. Cases of uterine infection presenting several days after delivery require obstetric hysterectomy. Modification of B-Lynch technique have been described by Cho B, Ghezzi, Hayman, Pereira and all their colleagues, to treat cases of atonic PPH in absence of incision on the uterus or after it is sutured.<sup>12-16</sup> B-Lynch suture requires skilled surgeon and un sutured lower segment incision in comparison to its modification, which is time consuming and associated with increased blood loss. The combination of compression sutures and uterine artery ligation are more likely to cause ischemia resulting in necrosis and inflammation, but no mortality has been reported as yet in association with these compression sutures. Our patient had undergone bilateral uterine artery ligation before attempting B-Lynch suture. And hence developed uterine

necrosis which required hysterectomy otherwise she would have landed up with sepsis and mortality.

## CONCLUSION

With intractable uterine atony unresponsive to the medical measures, surgical intervention can be lifesaving. Brace sutures like B-Lynch and its modification can help preserve the child bearing function. However this procedure is associated with own risks, hence timely decision and appropriate patient selection is of utmost importance.

*Funding: No funding sources*

*Conflict of interest: None declared*

*Ethical approval: Not required*

## REFERENCES

1. Kwast BE. Postpartum haemorrhage: its contribution to maternal mortality. *Midwifery.* 1991;7:64-70.
2. Ghodake VB, Pandit SN, Umbardand SM. Role of modified B-lynch suture in modern day management of atonic postpartum haemorrhage. *Bombay Hospital Journal.* 2008;50(2):205-11.
3. World health organisation. *Maternal mortality: a global factbook.* Geneva, WHO; 1991.
4. Sentilhes L, Gromez A, Razzouk K, Resch B, Verspyck E, Marpeau L. B-Lynch suture for massive persistent postpartum hemorrhage following stepwise uterine devascularization. *Acta Obstet Gynec Scand.* 2008;87(10):1020-6.
5. Arduini M, Epicoco G, Clerici G, Bottaccioli E, Arena S, Affronti G. B-Lynch suture, intrauterine balloon, and endouterine hemostatic suture for the management of postpartum hemorrhage due to placenta previa accreta. *Int J Gynaecol Obstet.* 2010;108:191-3.
6. *Obstetric haemorrhage Williams obstetrics 22<sup>nd</sup> edition,* McGraw-Hill Medical Publication division; 2005:823-24.
7. Condous GS, Arulkumaran S. Medical and conservative surgical management of postpartum hemorrhage. *J Obstet Gynaecol Can.* 2003;25:931-6.
8. B-Lynch C, Coker A, Lawal AH, Abu J, Cowen MJ. The B-Lynch surgical technique for the control of massive postpartum haemorrhage: an alternative to hysterectomy? Five cases reported. *Br J Obstet Gynaecol.* 1997;104:372-5.
9. Joshi VM, Shrivastava M. Partial ischemic necrosis of the uterus following a uterine brace compression suture. *BJOG.* 2004;111:279-80.
10. Ochoa M, Allaire AD, Stitely ML. Pyometria after hemostatic square suture technique. *Obstet Gynecol.* 2002;99:506-9.
11. Treloar EJ, Anderson RS, Andrews HS, Bailey JL. Uterine necrosis following B-Lynch suture for primary postpartum haemorrhage. *BJOG.* 2006;113:486-8.

12. Bhal K, Bhal N, Mulik V, Shankar L. The uterine compression suture a valuable approach to control major haemorrhage at lower segment caesarean section. *J Obstet Gynaecol.* 2005;25:10-4.
13. Cho JH, Jun HS, Lee CN. Hemostatic suturing technique for uterine bleeding during cesarean delivery. *Obstet Gynecol.* 2000;96:129-31.
14. Ghezzi F, Cromi A, Uccella S, Raio L, Bolis P, Surbek D. The Hayman technique: a simple method to treat postpartum haemorrhage. *BJOG.* 2007;114:362-5.
15. Hayman RG, Arulkumaran S, Steer PJ. Uterine compression sutures: surgical management of postpartum hemorrhage. *Obstet Gynecol.* 2002;99:502-6.
16. Pereira A, Nunes F, Pedroso S, Saraiva J, Retto H, Meirinho M. Compressive uterine sutures to treat postpartum bleeding secondary to uterine atony. *Obstet Gynecol.* 2005;106:569-72.

**Cite this article as:** Satia MN, More VS. Uterine necrosis in a case of B-Lynch brace suture. *Int J Reprod Contracept Obstet Gynecol* 2016;5: 2466-9.