

DOI: <http://dx.doi.org/10.18203/2320-1770.ijrcog20175844>

Original Research Article

Abnormal uterine bleeding in perimenopausal age group women: a study on clinicopathological evaluation and management

Sreelakshmi U.*, Tushara Bindu V., Subhashini T.

Department of Obstetrics and Gynecology, Mallareddy Medical College for Women and Hospital, Hyderabad, Telangana, India

Received: 23 October 2017

Accepted: 17 November 2017

***Correspondence:**

Dr. Sreelakshmi U.,

E-mail: dr.sreelakshmi@yahoo.com

Copyright: © the author(s), publisher and licensee Medip Academy. This is an open-access article distributed under the terms of the Creative Commons Attribution Non-Commercial License, which permits unrestricted non-commercial use, distribution, and reproduction in any medium, provided the original work is properly cited.

ABSTRACT

Background: Abnormal uterine bleeding is the most common and frequent presenting complaint in Gynaecology Outpatient Department in all age groups, especially in perimenopausal women. Objective of present study was clinicopathological evaluation and management of abnormal uterine bleeding in perimenopausal age group women.

Methods: The present study was prospective analytical study conducted at Mallareddy Narayana Multi-speciality Hospital, reputed teaching hospital, in Obstetrics and gynaecology department in association with department of pathology from January 2015 to December 2016. Perimenopausal women in age group 45-55 years included in this study. Other age groups with abnormal uterine bleeding, isolated cervical or vaginal pathology, bleeding diathesis, and pregnancy related causes of bleeding excluded from this study. Endometrial tissue collected by sampling procedure such as dilatation and curettage. Proper counselling about management was given to all women related to medical and surgical interventional approaches.

Results: A total of 135 women with abnormal uterine bleeding in perimenopausal age were examined after fulfilling criteria during study period of 2 years. The age of participants in mean±SD was 46.68±2.03 years (min 45 years and max 55 years). Maximum number of patients with abnormal uterine bleeding presented in age group of 45-50 years. The most common symptoms were heavy menstrual bleeding (83.7%), followed by frequent menstrual bleeding (26.6%). Proliferative endometrium was the most common histopathological (30.3%) study followed by secretory endometrium (27.4%). Surgical management was given to 94 patients.

Conclusions: Heavy menstrual bleeding and frequent menstrual bleeding were mostly correlated with abnormal endometrial histopathological findings in this study. Gynaecologists should pay attention towards these abnormal bleeding patterns along with the evaluation of endometrial tissue for histopathological findings, which will help us to plan for successful management.

Keywords: Abnormal uterine bleeding, Menstrual pattern, Perimenopausal

INTRODUCTION

Abnormal uterine bleeding is the most common and frequent presenting complaint in Gynaecology Outpatient Department in all age groups, especially in perimenopausal women.¹ Abnormal uterine bleeding may be defined as a bleeding pattern that differs in frequency,

duration and amount from a pattern observed during a normal menstrual cycle or after menopause. In the perimenopausal age variation in normal cyclical pattern may be due to physiological hormonal changes or pathological. Ultrasonography is an appropriate relevant radiological diagnostic tool to identify structural abnormalities in uterus and adnexae.² Hysteroscopy

guided endometrial biopsy is the preferred diagnostic technique to detect endometrial pathology, but lack of affordability endometrial biopsy obtained by Dilatation and Curettage (D&C) in developing countries. Accurate diagnosis of the causative factor of abnormal uterine bleeding (AUB) in this age group is of utmost importance so that appropriate management can be established.

Table 1: PALM- COEIN Classification of AUB.

Structural	Non Structural
Polyps	Coagulopathy
Adenomyosis	Ovulatory dysfunction
Leiomyomas	Endometrial (Primary disorders of Mechanism regulating local endometrial haemostasis).
Malignancy	Iatrogenic
Hyperplasia	Not yet specified

An international expert consensus from the International Federation of Gynecology and Obstetrics (FIGO) Menstrual Disorders working group has proposed a standardized classification system for AUB to facilitate greater appreciation of the complexities of this clinical entity.³ FIGO classification allows the detection of more than one causative factor in the same patient. There are 9 main categories within the classification system named for the acronym PALM-COEIN. The PALM side of the classification refers to structural causes that could be evaluated and diagnosed on imaging and or biopsy. The COEIN side allows consideration of underlying medical disturbances that could result in AUB (Table 1). Hence based on FIGO classification our study aim was to evaluate clinicopathological abnormalities and in turn to categorize methods to management of abnormal uterine bleeding in perimenopausal age group women.

METHODS

The present study was prospective analytical study conducted at Mallareddy Narayana Multi-speciality Hospital, reputed teaching hospital, in Obstetrics and gynaecology department in association with department of pathology from January 2015 to December 2016. Perimenopausal women in age group 45-55 years were included in this study. Other age groups with abnormal uterine bleeding, isolated cervical or vaginal pathology, bleeding diathesis, and pregnancy related causes of bleeding were excluded from this study.

After obtaining informed consent, detailed history was taken from all study participants such as age, parity, menstrual symptoms, detailed history regarding amount, duration and pattern of bleeding, use of exogenous hormones, and other associated gynaecological problems were noted. Thorough physical and systemic examination was done; baseline investigations and pelvic ultrasound were done. Appropriate and relevant investigations were offered to all study participants. Endometrial tissue collected by sampling procedures such as dilatation and

curettage and endometrial biopsy, which had been sent to the pathology laboratory for evaluation. Histopathological diagnosis was made, and further categorization was done for all cases.

Proper counselling about management was given to all women related to medical and surgical interventional approaches. Hysterectomy specimens subjected to histopathology examination such as endometrial, myometrial, and cervical findings were correlated well with endometrial biopsy reports, and results were analyzed. If patients opted for medical management need of regular follow up visits explained. The proper institutional ethical clearance was taken for this study.

RESULTS

A total of 135 women with abnormal uterine bleeding in perimenopausal age were examined after fulfilling criteria during study period of 2 years. The mean age of participants was 46.68 ± 2.03 years (age range of 45-55 years). Maximum number of patients with abnormal uterine bleeding presented in age group 45-50 years. All the study subjects were undergoing endometrial biopsy and submitted for histopathological examination. Majority of the cases 122 (90.37%) had history of tubal sterilization. Only 5 (3.7%) cases were seen with nulligravida. Majority of women were belonged to low socio-economic status (Table 2).

Table 2: Demographic characteristics of study participants.

Characteristics	No. of cases (n=135)	Percentage
Age (years)		
45-50	127	94.07
51-55	8	5.92
Socio-economic class		
Lower class	50	37.03
Lower middle	42	31.11
Upper middle	28	20.74
Higher class	15	11.11
Parity		
Nulligravida	5	3.70
Para-1	5	3.70
Para-2	70	51.85
Para-3	39	28.88
Para-4	12	8.88
Para-5	4	2.96

Of the participants most common menstrual pattern presented was with history of heavy menstrual bleeding (83.7%) and frequent menstrual bleeding (26.6%). Majority of the participants had more than one abnormal menstrual pattern (Table 3).

Duration of the symptoms in study participants were 3 months to 4 years. Comorbidities associated with AUB

were obesity, hypertension, hyperthyroidism, diabetes mellitus and heart disease (Table 4).

Table 3: Menstrual pattern of study subjects.

Menstrual pattern	No. of cases (n)	Percentage
Heavy menstrual bleeding	113	83.7
Frequent menstrual bleeding	36	26.6
Intermenstrual bleeding	6	4
Dysmenorrhea	12	8.8
Amenorrhoea followed by heavy bleeding	3	2.2
Hypomenorrhoea	1	1.4

Table 4: Frequency of background diseases among participants.

Medical illness	No. of cases, n=57	Percentage
Diabetes mellitus	3	5.26
Hypertension	15	26.31
Heart disease	1	1.75
Hypothyroidism	15	26.31
Obesity	23	40.35

Menstrual bleeding pattern was correlated with abnormal endometrial histopathological findings in perimenopausal women, showed in Figure 1.

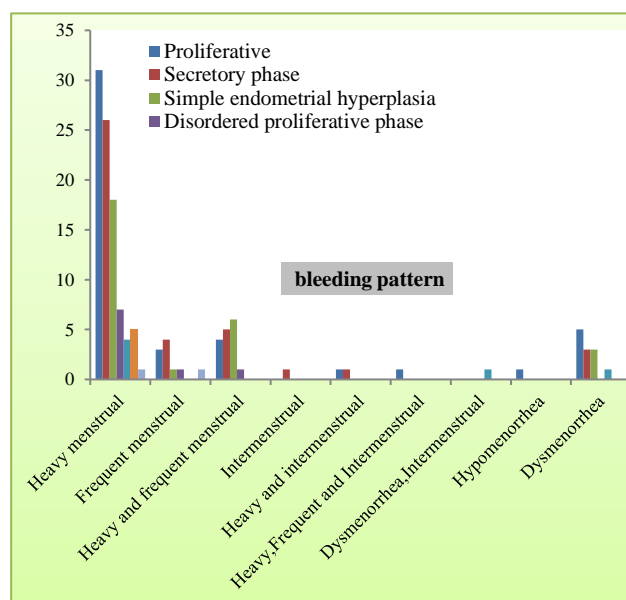


Figure 1: Correlation of menstrual pattern with histopathological findings of AUB patients.

Regarding the prevalence results of pathological findings in the study participants, the most common findings were proliferative endometrium (30.3%), secretory endometrium (27.4%) followed by hyperplastic endometrium (18.5%) (Table 5).

Table 5: Histopathological findings of study subjects.

Histopathological findings of endometrium	No. of cases (n=135)	%
Proliferative endometrium	41	30.3
Secretory endometrium	37	27.4
Simple endometrial hyperplasia without atypia	25	18.5
Disordered proliferative phase	9	6.6
Cystic glandular hyperplasia	5	3.7
Atrophic endometrium	5	3.7
Complex hyperplasia without atypia	2	1.4
Irregular ripening	2	1.4
Irregular shedding	1	0.7
Menstruating endometrium	1	0.7
Adenomyosis with proliferation	1	0.7
Endometriotic cyst	1	0.7
Adenomatous endometritis	1	0.7
Decidual cast	1	0.7
Endometrial cancer	1	0.7
Adenomatous polyps	1	0.7
Scanty material	1	0.7

Majority of cases were anaemic and their haemoglobin was improved by oral/injectable haematinics and blood transfusion according to requirement of the participants. Medical management in the form of hormonal and symptomatic treatment was advised to 106 patients and regular follow up was mandatory. However, only few cases were continued medical management. For remaining cases surgical management was offered due to lack of regular follow up or not getting symptomatic relief or surgery indicated itself. Eventually, surgical management was given to 94 patients (Table 6).

Table 6: Surgical management of study participants.

Surgical management	No. of cases (n=94)	Percentage
TAH	44	46.80
TAH+BSO	35	37.23
TAH+RSO	8	8.51
TAH+LSO	7	7.44

TAH- Total abdominal hysterectomy, BSO - Bilateral salpingo-oophorectomy, RSO- Right salpingo-oophorectomy, LSO - Left salpingo-oophorectomy.

DISCUSSION

Evaluation of AUB in perimenopausal age is a crucial step, since excessive or prolonged bleeding may cause disruption of women's daily activities, provoke serious medical consequences or exacerbate anaemia and in a certain percentage of cases may eventually be life threatening if left untreated.¹ AUB was the commonest problem in the perimenopausal age with highest incidence in many more studies like Gopalan U et al,

study (54.7%), Doraiswami S et al, Damle P et al, Muzaffar M et al.^{4,7} In perimenopausal women abnormal uterine bleeding may display in different menstrual patterns, these are heavy menstrual bleeding, frequent menstrual cycles, inter-menstrual bleeding, dysmenorrhoea and amenorrhoea followed by continuous heavy bleeding.

In present study majority of the cases were between 45 - 50 years age group, with mean age 46.68. The mean age of participants was 44.09 years in Ghanbarzadeh N et al study.⁸ The majority of study subjects belonged to low socio-economic status and prevalence of abnormal uterine bleeding increased with parity and a fewer cases were seen in grand multiparous group as their relative frequency has decreased in recent years due to small family norm. The most common symptoms were heavy menstrual bleeding (83.7%), followed by frequent menstrual bleeding (26.6%) in this present study. In Gupta A et al, study commonest symptoms were heavy menstrual bleeding 72% followed by heavy and frequent bleeding 13%.⁹

Dilatation and curettage is a useful and cost-effective method of detecting intrauterine pathologies and very few lesions escape detection. It is commonly used in developing countries with limited resources. Dilatation and curettage is a diagnostic as well as therapeutic procedure. The sensitivity of endometrial biopsy for the detection of endometrial abnormalities and for detection of cancer has been reported to be as high as 96% with 2-6% false negative rates.¹⁰ However, hysteroscopy guided biopsy is the gold standard both for screening as well as diagnostic purposes and can be performed as office procedure.

Nulliparity, early menarche, late menopause, unopposed endogenous and exogenous oestrogens, chronic anovulation and Tamoxifen therapy have all been proven to be risk factors for the development of endometrial hyperplasia and carcinoma.¹¹ In this study nulliparity was seen in 3.7% of women, among them endometrial biopsy showing proliferative, disordered proliferative, endometrial carcinoma.

ACOG recommends endometrial tissue assessment to rule out cancer in women 35 years or older with suspected anovulatory bleeding, and women unresponsive to medical therapy. An endometrial biopsy is a safe and efficient office-based procedure for sampling the endometrium in a patient presenting with abnormal uterine bleeding.¹²

In this study proliferative endometrium was the most common histopathological study followed by secretory endometrium. Proliferative endometrium was observed in (30.3%) of cases which was similar to studies reported by Damle RP et al (35.09%) and Bhatta S and Sinha AK (29.16%).^{6,13} While, higher incidence was found in Khan S et al (46.6%) and Sheetal et al (42%).^{14,15}

Abdulla and Bondaji found secretory endometrium was the most common histopathological diagnosis (24.9%) followed by proliferative endometrium 21.7%.¹⁶ Secretory endometrium was observed in 27.4% of cases in this study, similar to Jain M et al (28.9) study.¹⁷ But, lowest incidence was reported by Damle RP (7.95%) and Selvi A et al (10.77%).^{6,18}

Disordered proliferative pattern of the endometrium is somewhat difficult to define; it refers to a proliferative phase endometrium due to persistent oestrogen stimulation. It occupies the lower end of spectrum which passes through the hyperplasia to endometrial carcinoma on the other end. Early diagnosis of the lesion will prevent further disease progression. In the present study it was seen in 6.6% patients, similar incidence was seen in Gopalan U study.⁴ Hoxhaj O, Gjoni M (12.2%) studies observed higher incidence in perimenopausal age.^{9,19}

Endometrial hyperplasia is a common histopathological finding in perimenopausal women often causing symptoms of irregular or prolonged bleeding. Heavy bleeding is secondary to sustained level of oestrogens. The overgrowth not only affects glands and stroma but there is also abnormal vascularisation. Endometrial hyperplasia found in 18.5% of cases in this study. Doraiswami S et al (68%), Khare et al (36.2%) observed high incidence of endometrial hyperplasia.^{5,20} Endometrial hyperplasia is one of the risk factor for the development of endometrial carcinoma, early diagnosis and initiation of treatment is very important. So, perimenopausal women with heavy or irregular menstrual bleeding are often advised to have an endometrial sample taken to exclude endometrial disease.²¹

Degenerative process of corpus luteum is sluggish in irregular shedding of the endometrium which leads to prolonged menstrual cycle to the waning effect of progesterone seen in 1.4% of cases. The exact cause of bleeding in atrophic endometrium is not known it is thought to be due to anatomic vascular variation or defective local haemostatic mechanism. It is observed in 3.7% of cases in our study. Adenomatous changes observed in 0.7% of cases, but in Talukdar et al study showing highest incidence 20.37%.²¹

Chronic endometritis in the present study was found in only 0.7 % of patients while it was seen with a higher incidence in a study by Damle RP et al (5.68%), Jain M, Gorania N (6.1%), Khare et al (6.4 %).^{6,17,21} Endometrial polyp was found in 0.7 % cases in present study. A similar incidence was found by Gopalan U (1.1%), Muzaffar M et al (1.2%), Khan S et al (0.6%), and (1.3%) Baral R et al.^{4,7,14,22}

We encountered 1 case (0.7%) of endometrial carcinoma above the age of 45 years similar results were also reported by Khare et al²¹ and Dangal G.²³ Inadequate samples are reported when no specimen is obtained, or the quality is insufficient for assessment. Management of

abnormal uterine bleeding is not complete without tissue diagnosis, especially in perimenopausal and post-menopausal women.

Abnormal Uterine Bleeding is the main reason women are referred to gynaecologists. There is little consensus on specific treatment regimens for anovulatory uterine bleeding. ACOG recommends treatment with combination oral contraceptives or cyclic progestin. Progestin therapy and oral contraceptives induce routine withdrawal bleeding, decrease the risk of hyperplasia or cancer, and correct any related excessive menstrual bleeding.²⁴ Medical management was offered to majority of patients. AUB is one of the main gynecological reasons of hysterectomy and accounts for two thirds of all hysterectomies.²⁵ Hysterectomy was done those who were not attending for regular follow up visits and even with medical treatment not getting symptomatic relief. In this study majority of women with uterine fibroids associated with heavy bleeding and frequent menstrual cycles were treated by hysterectomy. Hysterectomy still remains the widely used treatment modality even in developed countries. However, it is necessary to be studied in different cohort groups with larger populations.

CONCLUSION

Abnormal uterine bleeding is one of the commonest reasons for women to seek medical help in all age groups, especially in perimenopausal age. Abnormal uterine bleeding with different menstrual patterns has significant effect on women's health, quality of life and ultimately social assimilation suggest that need of proper evaluation and initiation of treatment should be given a privileged priority. The present study revealed high prevalence of heavy menstrual bleeding in perimenopausal age with highest prevalence between the ages of 45-50 years. All women having abnormal menstrual bleeding should be subjected to dilatation and curettage to rule out endometrial pathology. Heavy menstrual bleeding and frequent menstrual bleeding were mostly correlated with abnormal endometrial histopathological findings in this study. Gynaecologists should pay attention towards these abnormal bleeding patterns along with the evaluation of endometrial tissue for histopathological findings. Histopathological study of the endometrium in these cases reveals a wide variety of abnormalities, evaluation of which will help us to plan for successful management. However, hysterectomy remained the commonest method of intervention in peripheries of India; clinicians should encourage early evaluation AUB and implementation of alternative procedures to avoid radical surgeries so that women receive maximum benefits with least morbidity.

ACKNOWLEDGMENTS

Authors would like to thank Department of Obstetrics and Gynecology and Department of Pathology, Mallareddy medical College for women and Hospital, Hyderabad, Telangana state, India.

Funding: No funding sources

Conflict of interest: None declared

Ethical approval: The study was approved by the Institutional Ethics Committee

REFERENCES

1. Mahajan N, Aggarwal M, Bagga A. Health issues of menopausal women in North India. *J Midlife Health.* 2012;3:84-7.
2. Kumar P, Malhotra N. Clinical types of abnormal uterine bleeding. In: Kumar P, editor. *Jeffcoate's Principle of Gynecology.* 7th ed. New Delhi: Jaypee Brothers Medical Publishers (P) Ltd.;2008:599.
3. Munro MG, Critchley HO, Fraser IS. The FIGO systems for nomenclature and classification of causes of abnormal uterine bleeding in the reproductive years: Who needs them? *Am J Obstet Gynecol.* 2012;207:259-65.
4. Gopalan U, Rajendiran S, Karnaboopathy R. Study of endometrial histopathology in women with abnormal uterine bleeding. *Int J Reprod Contracept Obstet Gynecol.* 2017;6(3):824-8.
5. Doraiswami S, Johnson T, Rao S, Rajkumar A, Vijayaraghavan J, Panicker VK. Study of endometrial pathology in abnormal uterine bleeding. *J Obstet Gynecol India.* 2011;61(4):426-30.
6. Damle RP, Dravid NV, Suryawanshi KH, Gadre AS, Bagale PS, Ahire N. Clinicopathological spectrum of endometrial changes in perimenopausal and menopausal uterine bleeding. *J Clin Diagnos Res.* 2013;7(12):2774-6.
7. Muzaffar M, Akhtar KAK, Yasmin S, Rahman M, Iqbal W, Khan MA. Menstrual irregularities with excessive blood loss: A Clinico-Pathological Correlation. *J Pak Med Assoc.* 2005;55:486-9.
8. Ghanbarzadeh N, Haghighi F, Semnani FN, Semnani AN, Sa'adatpoor E. Pathological patterns of endometrial curettage samples in women referred with abnormal uterine bleeding: A descriptive study. *J Surg Trauma.* 2015;3(3-4):39-45.
9. Gupta A, Rathore AM, Manaktala U, Rudingwa. Evaluation and histopathological correlation of abnormal uterine bleeding in peimenopausal women. *Int J Biomed Adv Res.* 2013;4(8):509-13.
10. Albers JR, Hull SK, Wesley RM. Abnormal uterine bleeding. *J Am Fam Phys.* 2004;69:1915-26.
11. Farquhar Cm, Lethaby A, Sowter M, Verry J, Banyai J. An evaluation of risk factors for endometrial hyperplasia in premenopausal women with abnormal menstrual bleeding. *Am J Obstet Gynecol.* 1999;181:525-9.
12. Sweet MG, Schmidt-Dalton TA, Weiss PM, Madsen KP. Evaluation and management of abnormal uterine bleeding in premenopausal women. *Am Fam Physician.* 2012;85(1):35-43.
13. Bhatta S, Sinha AK. Histopathological study of endometrium in abnormal uterine bleeding. *J Pathol Nepal.* 2012;2(4):297-300.

14. Khan S, Hameed S, Umber A. Histopathological pattern of endometrium on diagnostic D and C in patients with abnormal uterine bleeding. *Annals King Edward Medical Univ.* 2011;17(2):166-70.
15. Sheetal GP, Bhute SB, Inamdar SA, Acharya NS, Shrivastava DS. Role of diagnostic hysteroscopy in abnormal uterine bleeding and its histopathological correlation. *J Endosc Surg.* 2009;1(2):98-104.
16. Abdulla LS, Bondagji NS. Histopathological pattern of Endometrial Sampling performed for Abnormal Uterine Bleeding. *Bahrain Med Bull.* 2011;33(4):1-6.
17. Jain M, Gorania N. Abnormal uterine bleeding: a study of menstrual patterns and histopathological patterns in perimenopausal females. *Int J Reprod Contracept Obstet Gynecol.* 2015;4(1):109-12.
18. Salvi A, Mital P, Hooja N, Batar A, Soni P, Beniwal R. Spectrum of endometrial histopathology in women presenting with abnormal uterine bleeding. *Sch J App Med Sci.* 2015;3(1A):1-4.
19. Hoxhaj O, Gjoni M. Histopathological pattern of endometrium in abnormal uterine bleeding. *Int J Sci Res.* 2015;4(11):1783-5.
20. Khare A, Bansal R, Sharma P, Elhence N. Morphological spectrum of endometrium in patients presenting with Dysfunctional uterine bleeding. *People's J Scientific Res.* 2012;5:13-16.
21. Talukdar B, Mahela S. Abnormal uterine bleeding in perimenopausal women: Correlation with sonographic findings and histopathological examination of hysterectomy specimens. *J Midlife Health.* 2016;7(2):73-77.
22. Baral R, Pudasaini S. Histopathological pattern of endometrial samples in abnormal uterine bleeding. *J Pathol Nepal.* 2011;1:13-6.
23. Dangal G. A study of endometrium in patients with abnormal uterine bleeding at Chitwan valley. *Kathmandu Univ Med J.* 2003;1(2):110-2.
24. Kotagasti T. Prevalence of different menstrual irregularities in women with abnormal uterine bleeding: an observational study. *Int J Cur Res Rev.* 2015;7(10):66-70.
25. Telner DE, Jakubovicz D. Approach to diagnosis and management of abnormal uterine bleeding. *Can Fam Physician.* 2007;53:58-64.

Cite this article as: Sreelakshmi U, Bindu VT, Subhashini T. Abnormal uterine bleeding in perimenopausal age group women: a study on clinicopathological evaluation and management. *Int J Reprod Contracept Obstet Gynecol* 2018;7:192-7.