

DOI: <https://dx.doi.org/10.18203/2320-1770.ijrcog20213500>

Case Report

Diagnosis of caesarean section scar niche causing chronic pelvic pain

Papa Dasari*

Department of Obstetrics and Gynecology, JIPMER, Puducherry, India

Received: 07 July 2021

Accepted: 31 July 2021

***Correspondence:**

Dr. Papa Dasari,

E-mail: dasaripapa@gmail.com

Copyright: © the author(s), publisher and licensee Medip Academy. This is an open-access article distributed under the terms of the Creative Commons Attribution Non-Commercial License, which permits unrestricted non-commercial use, distribution, and reproduction in any medium, provided the original work is properly cited.

ABSTRACT

The common causes of chronic pelvic pain include chronic pelvic inflammatory disease, endometriosis, inflammatory bowel disease etc. Caesarean scar defect is recently recognized as a cause for chronic pelvic pain. A 33 years old para 2 with previous 2 caesarean sections, whose last child birth was 18 months back consulted for rectal pain of 4 months duration. She was treated with progesterones with a provisional diagnosis of endometriosis without much relief. She developed congestive dysmenorrhea and dyspareunia after last child birth. Her clinical examination revealed retroverted uterus with left forniceal tenderness. USG evaluation confirmed the clinical findings and evaluation of uterine scar was not undertaken as the possibility of caesarean scar defect (CSD) was not thought of as a cause for chronic pelvic pain. MRI pelvis reported semicircular myometrial defect at LSCS scar site and this was confirmed by hystero-laparoscopy and she was counselled to undergo repair of CSD. The case illustrated the clinical picture and diagnosis of CSD as a cause for chronic pelvic pain.

Keywords: Dysmennorrhea, Dyspareunia, Rectal pain, Previous 2 caesarean section, Caesarean scar defect

INTRODUCTION

The common causes of chronic pelvic pain include various gynaecological disorders like chronic pelvic inflammatory disease, endometriosis, adhesions following surgery on uterus or adnexa and inflammatory bowel diseases etc. Recently caesarean scar defects have emerged as a cause of menorrhagia and chronic pelvic pain. One such case is presented here for its delayed diagnosis or misdiagnosis as endometriosis.

CASE REPORT

A 33 years old staff nurse by occupation, married since, 8 years, para 2 MTP1 consulted for rectal pain of 4 months duration. She was diagnosed elsewhere to have endometriosis and was treated with tablet primolut N and dienogest for 2 months without much relief. She also consulted a general surgeon for the symptoms and was told by not to have any gastrointestinal cause.

Her menstrual history was that she attained menarche at 13 years of age and cycles were regular occurring once in 28-30 days and lasting for 3 days and there was no dysmenorrhea. After the last childbirth her cycles are irregular and there is severe congestive dysmenorrhea. She was attributing the rectal pain due to the surgical procedure of laparoscopic Ovarian drilling which she underwent 5 years ago for secondary infertility after first childbirth

Her obstetric history is that she conceived soon after marriage and underwent medical abortion during first trimester for unwanted pregnancy (2014). She conceived soon after and delivered normally in 2015 and the baby had duodenal atresia for which surgery was done and presently the child is healthy and doing well. In 2018, she was investigated elsewhere for secondary infertility and underwent laparoscopic ovarian drilling and was treated with ATT for 3 months though histopathology of endometrium did not show any evidence of tuberculosis. In 2019 she underwent elective LSCS with tubectomy

elsewhere at maternal request and the baby is healthy. Her marital history revealed dyspareunia for the past 2 years. She could only reveal this after pelvic examination and on repeated probing.

There was no family history of tuberculosis, congenital malformation, diabetes or hypertension. No history of sexually transmitted diseases in her or in her spouse. On examination she was moderately built well nourished. BMI 22 kg/m². Breasts and thyroid were normal. Cardiovascular and respiratory systems were normal. Abdominal examination showed pfannensteil scar which healed by primary intention and there was no hernia. There was no mass or tenderness in abdomen. Per-speculum examination showed healthy cervix and vagina. Per vaginal examination revealed bulky retroverted uterus and left fornix was tender. Per rectal examination revealed only tenderness anteriorly and there was no mass lesion.

A provisional clinical diagnosis of chronic pelvic pain was made. Trans vaginal scan revealed retroverted uterus which measured 5.1×4.2 cm. Right ovary measured 2.6×2.8×2.7 cm, volume 8 cm³. Left ovary volume was 5.2 cm³. There was minimal free fluid in pelvis and there was tenderness with vaginal probe in left fornix. Caesarean scar defect was not suspected and hence it was not evaluated on USG. MRI was advised to rule out tuberculosis or mild endometriosis. Her mantoux was 2 mm. X-ray chest P/A was normal.

Her haemogram showed haemoglobin of 12.4 g/dl; WBC-6760; DLC-N=40; L=46; M=5; platelets 2.8 lakhs; blood urea 16 mg/dl creatinine- 0.54 mg/dl; blood sugar fasting 83 mg/dl; postprandial 90 mg/dl; urine culture was sterile; Pap test- no malignant cells. MRI pelvis revealed retroverted uterus with a focal semi-circular disruption of the ventral myometrium at the LSCS scar site extending through the serosa with tethering of the endometrium towards the scar site suggestive of chronic incomplete scar

rupture. Few GER hypointensities are noted in the scar site suggestive of old blood clots (Figure 1).

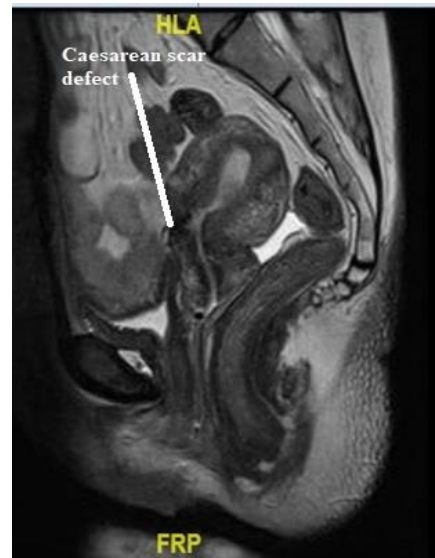

Figure 1: MRI pelvis (contrast)- retroverted uterus with a focal semicircular disruption of the ventral myometrium at the LSCS scar site extending through the serosa with tethering of the endometrium towards the scar site.

Hysterolaparoscopy was done on 7/11/2020. Hysteroscopy revealed bilateral normal tubal ostia. On left anterolateral wall of lower uterine cavity, gutter of the scar of one cm in length was seen with endometriotic spot on the superior aspect. Laparoscopy showed 6 weeks size uterus which was retroverted. Bladder densely adherent to lower segment and supravaginal cervix not seen (Figure 2). Both tubes and ovaries and POD normal. There were no findings suggestive of endometriosis or tuberculosis. She was advised to undergo niche repair at a later date post-menstrually.

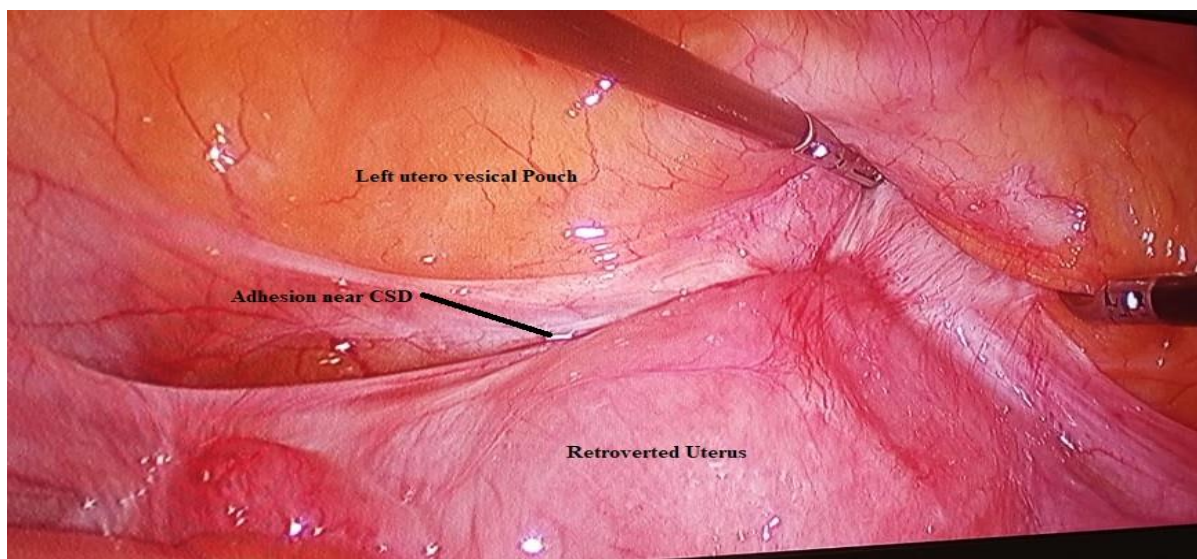


Figure 2: Laparoscopic picture- retroverted uterus with bladder adhesion in left uterovesical pouch.

DISCUSSION

Discontinuation of myometrium at the site of uterine scar by at least 2 mm in depth as seen by USG is termed as 'niche'. The sequelae due to niche reported are abnormal uterine bleeding usually perimenstrual, due to accumulation of blood in the pouch formed by the defect, dysmenorrhea and dyspareunia are also reported due to this. There can be infertility due to impact of the collected blood on the cervical mucus as well as on sperm motility.¹ All these symptoms were present in the current lady. Her main complaint at present was constant back pain and pain during defecation. There was no fissure-in-ano or haemorrhoids and no mass on per rectal examination as these are the main causes for rectalgia or proctalgia. Endometriosis was suspected in this lady as a cause for rectalgia or proctalgia as deep infiltrating endometriosis (DIE) of rectovaginal septum can cause rectal pain. The pain in DIE may be cyclical initially radiating to sacrococcygeal region and later may become dyschezia.² Clinically the nodules will be felt on per-rectal examination and this is not present in this lady.

The reason why niche develop after caesarean was hypothesised by AJM Vervoot and it revolves around impaired wound healing. The factors include (a) incision lower down in the lower segment on the cervical tissues including the mucus glands that cause impaired wound healing; (b) imperfect closure of the uterine incision because of single layer closure or interlocking sutures that result in omission of deeper myometrial layer resulting in defective approximation and healing; (c) adhesion formation to the abdominal wall can pull the myometrial scar tissue and result in pressure on the surgical wound and leads to pouch formation; (d) individual's predisposition to impaired wound healing due to defective inflammatory responses because of haematological, connective tissue and genetic disorders.³

For diagnosis of uterine niche, a high index of suspicion is necessary. The modalities include 2D/3D USG, MRI and Hysteroscopy. In 2018 guidance regarding evaluation of niche by USG in nonpregnant women was published by Jordans et al. Modified Delphi method was used to arrive at the USG planes and measurements to be taken. The measurements taken are length of niche, breadth, residual myometrial thickness (RMT), adjacent myometrial thickness (AMT), branches or irregularities of niche and their measurement, Niche and UV fold distance and Niche external os distance. Additional tools like doppler, saline/gel sonography may be used but are not mandatory. Niche are classified as simple Niche, simple niche with one branch and complex niche with more than one branch.⁴ A study which compared Transvaginal sonography (TVS) with Gel instillation sonography (GIS) detected the niche to be more prevalent and deeper with GIS than TVS assessed after 6 to 12 weeks of caesarean section in a large cohort of 263 women. Post-menstrual spotting is the main complaint in women who had a RMT to AMT ratio of <0.5

and most of the niche detected by GIS were semi-circular in shape.⁵

MRI is another non-invasive technique to diagnose niche and a defect (anechoic area) of at least one mm in depth is necessary on T2 weighted sagittal plane. Depth of niche is the vertical distance between the base and apex and width is the distance of base in millimetres. The myometrial thinning is the measurement from the apex of the niche to the serosal surface. Total myometrial thickness is measured adjacent to the niche up to the base of the niche. Wong et al analysed 158 women by MRI by using criteria developed by Vaate et al and reported the shape of the niche as triangular in 60%, linear in 30% and irregular and rectangular in 10%.^{6,7} They commented that "MRI scans as requested by gynecologists often failed by radiologists to look for and make a diagnosis of this emerging condition of CSD". But in the present case it was duly recognised as blood clots in the caesarean scar though not diagnosed as CSD and we could subject the patient to hysterolaparoscopy and confirm it and offer definitive treatment.

At hysteroscopy the most common finding is increased vascularisation (74%), abnormal vasculature in the form of oozing spots (47.4%) and presence of old blood in the defect.⁸ The correlation between hysteroscopic diagnosis and transvaginal sonographic diagnosis was reported to be 100% in diagnosing CSD and hence it was concluded that TVS is cheaper and non-invasive technique that is adequate for diagnosis of CSD.⁹ To define the extent of the defect prior to repair 'Halloween sign' was described on a combined hysterolaparoscopic approach which involves trans illumination through hysteroscope and visualisation of the extent by laparoscope and recognition of lateral bands.¹⁰

CONCLUSION

In women with history of previous caesarean section with symptoms of lower abdominal pain or dysmenorrhea or dyspareunia or rectal pain, it is essential to evaluate the uterine scar by transvaginal sonography or MRI to diagnose CSD so that optimal management can be instituted.

Funding: No funding sources

Conflict of interest: None declared

Ethical approval: Not required

REFERENCES

1. Wozniak A, Pyra K, Tinto HR, Wozniak S. Ultrasonographic criteria of cesarean scar defect evaluation. *J Ultrason.* 2018;18(73):162-5.
2. Anaf V, Simon P, Nakadi I, Fayt I, Buxant F, Simonart T, et al. Relationship between endometriotic foci and nerves in rectovaginal endometriotic nodules. *Hum Reprod.* 2000;15(8):1744-50.

3. Vervoort AJ, Uittenbogaard LB, Hehenkamp WJ, Brolmann HA, Mol BW, Huirne JA. Why do niches develop in Caesarean uterine scars? Hypotheses on the aetiology of niche development. *Hum Reprod.* 2015;30(12):2695-702.
4. Jordans IPM, Leeuw RA, Stegwee SI, Amso NN, Soldevila PN, Bosch T, et al. Sonographic examination of uterine niche in non-pregnant women: a modified Delphi procedure. *Ultrasound Obstet Gynecol.* 2019;53(1):107-15.
5. Voet LF, Vaate AM, Veersema S, Brolmann HA, Huirne JA. Long-term complications of caesarean section. The niche in the scar: a prospective cohort study on niche prevalence and its relation to abnormal uterine bleeding. *BJOG.* 2014;121(2):236-44.
6. Wong WSF, Fung WT. Magnetic Resonance Imaging in the Evaluation of Cesarean Scar Defect. *Gynecol Minim Invasive Ther.* 2018;7(3):104-7.
7. Vaate AJ, Brolmann HA, Voet LF, Slikke JW, Veersema S, et al. Ultrasound evaluation of the Cesarean scar: relation between a niche and postmenstrual spotting. *Ultrasound Obstet Gynecol.* 2011;37(1):93-9.
8. Chen YY, Tsai CC, Kung FT, Lan KC, Ou YC. Association between hysteroscopic findings of previous cesarean delivery scar defects and abnormal uterine bleeding. *Taiwan J Obstet Gynecol.* 2019;58(4):541-4.
9. Fabres C, Aviles G, Jara C, Escalona J, Munoz JF, Mackenna A, et al. The cesarean delivery scar pouch: clinical implications and diagnostic correlation between transvaginal sonography and hysteroscopy. *J Ultrasound Med.* 2003;22(7):695-700.
10. Rao ST, Lambert N, Ghosh B, Chang T. Defining the limits of caesarean scar niche repair: new anatomical landmarks. *Gynecolog Surg.* 2021;18(1):1-2.

Cite this article as: Dasari P. Diagnosis of caesarean section scar niche causing chronic pelvic pain. *Int J Reprod Contracept Obstet Gynecol* 2021;10:3623-6.