

DOI: <http://dx.doi.org/10.18203/2320-1770.ijrcog20203336>

## Original Research Article

# An observational study of abnormal findings in fetus during 11-13+6 weeks and targeted imaging for fetal anomalies ultrasonography

Amrita D. Patel<sup>1\*</sup>, Janki B. Shingadia<sup>1</sup>, Devang Patel<sup>2</sup>

<sup>1</sup>Department of Obstetrics and Gynecology, B. J. Medical College, Ahmedabad, Gujarat, India

<sup>2</sup>Consultant at Gujarat Fetal Medicine Centre, Perinatology and High Risk Pregnancy, Ahmedabad, Gujarat, India

**Received:** 16 June 2020

**Accepted:** 08 July 2020

### \*Correspondence:

Dr. Amrita D. Patel,

E-mail: amritadevangpatel05@gmail.com

**Copyright:** © the author(s), publisher and licensee Medip Academy. This is an open-access article distributed under the terms of the Creative Commons Attribution Non-Commercial License, which permits unrestricted non-commercial use, distribution, and reproduction in any medium, provided the original work is properly cited.

### ABSTRACT

**Background:** Congenital anomalies are responsible for a of 14.2% of perinatal mortality in India. This study focuses on incidence of structural fetal abnormalities detected during 1<sup>st</sup> and 2<sup>nd</sup> trimester sonography. Aim of this study was to evaluate the need for targeted fetal scans.

**Methods:** This study is an observational study conducted at Gujarat fetal medicine Centre, Ahmedabad, Gujarat, super specialty antenatal radiology centre where exclusively antenatal USGs and prenatal procedures are performed. All pregnant female coming for 1<sup>st</sup> and 2<sup>nd</sup> trimester USG were included. All fetal abnormalities in form of soft markers and structural abnormality were included.

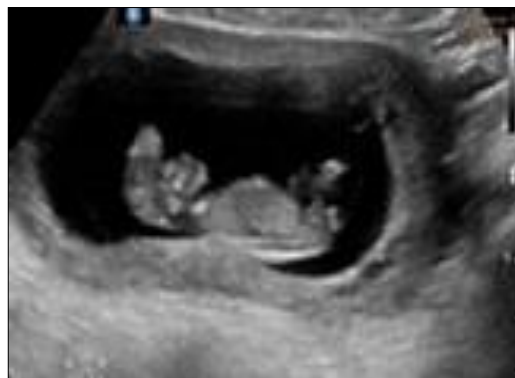**Results:** Out of 2122 total ANC scans, 183 cases (8.6%) had structural abnormality and 235 cases (11%) had significant soft markers. 1185 cases (55.84%) came in late 2<sup>nd</sup> trimester for TIFFA scan and 468 (22%) were seen in 1<sup>st</sup> trimester scan. The incidence of fetal anomaly in this study was higher than general population as it is an exclusively fetal medicine centre and majority of patients were diagnosed with anomaly in late 2<sup>nd</sup> trimester.

**Conclusions:** There is immense need for early diagnosis and timely intervention before 20 weeks in case of prenatal detection of fetal abnormality.

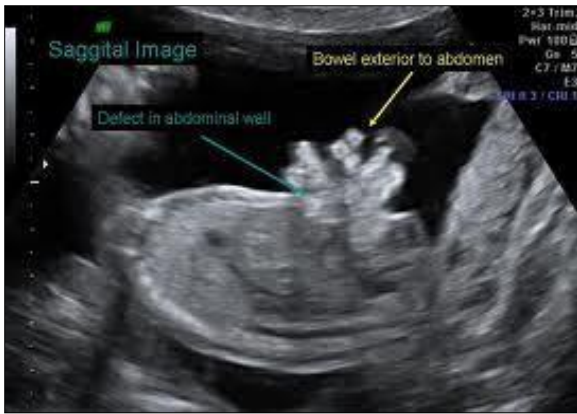
**Keywords:** Prenatal, Soft markers, Structural fetal anomalies, Targeted imaging for fetal anomalies scan

### INTRODUCTION

Congenital anomalies are responsible for a of 14.2% of perinatal mortality in India.<sup>1</sup> Advancement in imaging technology and increased expertise in field of fetal medicine has tremendously improved detection of fetal abnormalities.<sup>2</sup> Routine basic antenatal care includes 1<sup>st</sup> trimester scan at 11-13+6 weeks scan and 2<sup>nd</sup> trimester scan at standard time 18-22 weeks of gestation. Besides abnormal nuchal translucency and paranasal triangle, a range of CNS (Figure 1), CVS, GIT (Figure 2), GUT and skeletal abnormalities can be detected in 11-13+6 weeks scan. The clear benefit of early detection is relatively easier pregnancy termination if required.<sup>3</sup>



**Figure 1: Anencephaly.**



**Figure 2: Gastroschisis in sagittal section.**

Henceforth the study assessed the prevalence of fetal malformations detected during 1<sup>st</sup> and 2<sup>nd</sup> trimester scans.

**METHODS**

This is a retrospective observational study conducted at an exclusively fetal medicine centre, over a period of 2 years and 6 months from October 2017 to May 2020, where pregnant mothers are referred for 1<sup>st</sup> and 2<sup>nd</sup> trimester scans.

**Inclusion criteria**

- All cases with soft markers like, raised NT, NFT, absent/hypoplastic nasal bone, intracardiac echogenic foci, tricuspid regurgitation, aberrant right subclavian artery, echogenic bowel, single umbilical artery, etc. Structural abnormality in brain, GIT, cardiovascular, skeletal, kidney and other organs were included.

**Exclusion criteria**

- Ancillary findings and multiple pregnancy for fetal reduction were excluded.

All couples with significant and multiple soft markers were counselled for confirmatory tests like karyotype, QFPCR by CVS/amniocentesis and cases with structural fetal abnormality were counselled accordingly for association with chromosomal abnormalities by invasive tests.

**RESULTS**

A total of 2122 pregnant mothers came for antenatal ultrasonography at this centre. Amongst them 468 (22.05%) were 1<sup>st</sup> trimester scans and 1654 (77.94%) were 2<sup>nd</sup> trimester scan. Significant structural fetal abnormality was found in 183 cases (8.57%) and 232 cases (11%) had significant and nonsignificant soft markers. Intracardiac echogenic foci being the most common one (57%). Majority of cases of structural

anomaly was contributed by CNS i.e., 49 cases (26.29%) followed by GUT and CVS anomaly with 44 cases (24.04%) and 41 cases (22.42%) respectively.

**Table 1: Total number of antenatal scans according to time of gestation at referral.**

Timing of scan	Number	Percentage (n=2122)
11-13+6 weeks scan (NT scan)	468	22%
18-22 weeks scan (TIFFA)	1654	78%

\*NT: Nuchal translucency, \*\*TIFFA: targeted imaging of fetal anatomy.

**Table 2: Classification of fetal malformation according to system involved (1<sup>st</sup> +2<sup>nd</sup> trimester scan).**

	Number of cases	Percentage (n=183)
Central nervous system	49	26.7%
Genitourinary	44	24.04%
Cardiovascular	41	22.4%
Gastrointestinal	21	11.4%
Skeletal	20	10.9%
Others	8	4.37%
<i>Sacroccoccygeal teratoma</i>	1	
<i>Rhabdomyoma</i>	1	
<i>Cystic hygroma</i>	3	
<i>Facial abnormality</i>	2	
<i>Body stalk abnormality</i>	1	

Though the scan is named NT scan but it includes detailed fetal anatomy other fetal parameters also. For TIFA scan, the standard time is 18-20 weeks but most of the cases were referred after 20 weeks. Delay in antenatal registration, delay in seeking medical advice, unawareness of 1<sup>st</sup> trimester 11-13+6 weeks scans and time consumed in several second opinion was factor in late reporting.

**Table 3: Classification of soft marker abnormalities in 1<sup>st</sup> + 2<sup>nd</sup> trimester scans.**

Soft marker	Number of cases	Percentage (n=232)
Intracardiac echogenic foci	136	58.62%
Single umbilical artery	30	12.9%
Hypoplastic / absent NB	27	11.6%
Echogenic bowel	16	6.8%
Tricuspid regurgitation	11	4.7%
Raised NT	8	3.4%
ARSA	2	0.86%
Raised NFT	1	
Reversal "a" wave in ductus venosus	1	12.9%

NB: nasal bone, NT: nuchal translucency, NFT: nuchal fold thickness, ARSA: aberrant right subclavian artery.

The cases here include all structural fetal anomalies detected during 1<sup>st</sup> and 2<sup>nd</sup> trimester. 49 cases of CNS anomaly were found to be ventriculomegaly, anencephaly (2), choroid plexus cyst (18), neural tube defect (9), exencephaly (1), small CSP (1), corpus callosum agenesis (2), hydrocephalous (3), posterior fossa anomaly (3), microcephaly (1), holoprosencephaly (1). 44 cases of genitourinary anomalies included multicystic dysplastic kidney (6), renal agenesis (3), renal pelviectasis (23), pelvic/ectopic kidney (4), megacystis (3) hydronephrosis (3) cloacal malformation (1) and ureterocele (1). 41 cases of Cardiovascular pathology were double outlet right ventricle(6), rhythm abnormality (9), ventricular septal defect(5), tetralogy of fallots (4), coarctation of aorta (2), situs inversus (2), ventriculomegaly (1), acardiac twin (1), ductus venosus agenesis (2), Transposition of great vessels (1), dilated SVC (1) and hypoplastic left heart syndrome (4), tricuspid dysplasia (2) and persistent right umbilical vein (1) (note; figures in bracket denotes number of cases).

Gastrointestinal anomalies detected were diaphragmatic hernia, dilated bowel, esophageal atresia, abdominal cysts, anterior abdominal wall defect. Skeletal anomalies detected were achondroplasia, absent limb, CTEV, skeletal dysplasia, hemivertebrae, cleft palate. 2 cases of fetal tumor, rhabdomyoma and sacrococcygeal teratoma and 1 case of placental tumour were also detected.

Out of 2122 total scans, 232 (11%) showed significant as well nonsignificant soft markers as enumerated in above Table 3. All the cases with soft markers with high likelihood ratio and multiple soft markers were counselled for NIPS (non-invasive prenatal screening) and confirmatory tests like CVS, amniocentesis. but only 34 cases forwarded with tests. 30 cases of amniocentesis and 4 cases of chorionic villous sampling were performed, out of these 34 cases only 1 case of unossified nasal bone with bilateral ventriculomegaly turned out to be positive for trisomy 21.

## DISCUSSION

The overall incidence of fetal malformation in this study was 8.6%, higher than the reported for general population (3-5%) as study was conducted at a referral centre for fetal scan. This study calculated that majority of fetal anomalies were contributed by CNS abnormalities (26.9%). The concept of pre-conceptional folic acid intake is still not commonly practiced in study population.<sup>4</sup> Authors realized that half the cases detected with major abnormality had 1<sup>st</sup> trimester scan reports as normal i.e., missed diagnosis and other half came beyond 20 weeks. It reflects unawareness and lack of knowledge in general population and also basic antenatal care. Most of the anomalies diagnoses were amenable to be detected in first trimester like anencephaly, gastroschisis, holoprocenphaly.<sup>5</sup> It is also expected that late development of some organs and it is also expected that late development of some organs and hence detection of

their abnormality is delayed, posterior fossa anomalies, duodenal atresia, renal anomalies.<sup>6</sup> Comparing to Iliescu et al 2 year study over 5472 pregnant females, 76.3% had major structural defect, 90% had cardiac defect and 69.5% had CNS involvement.<sup>7</sup>

The most important implication of early diagnosis is safe termination and avoiding forced termination at substandard centres leading to threat to life.<sup>8</sup> Whereas overdiagnosis can lead to expensive and sometimes iatrogenic medical interventions.<sup>9,10</sup> On contrary high sensitivity of scan in 2<sup>nd</sup> trimester scan but late reporting for anomaly scan shows the lacunae which needs to be filled.

## CONCLUSION

Fetal scanning in 1<sup>st</sup> trimester scan had high sensitivity and low specificity whereas 2<sup>nd</sup> trimester scan had high sensitivity and high specificity. There is immense need for inclusion of first trimester and second trimester in routine antenatal care even in developing countries like India to give a management plan and guidance to couple for optimal care in fetal and neonatal life.

## ACKNOWLEDGMENTS

Authors would like to thank Dr. Devang Patel, (high-risk pregnancy and perinatology), consultant, Gujarat Fetal Medicine Centre, Ahmedabad, Gujarat, India.

*Funding: No funding sources*

*Conflict of interest: None declared*

*Ethical approval: The study was approved by the Institutional Ethics Committee*

## REFERENCES

1. Goel S, Mukherjee SB. Urinary tract infection, a tale of 50 years. *Indian Pediatr.* 2016;53(1):57-8.
2. Economides DL, Whitlow BJ, Braithwaite JM. Ultrasonography in the detection of fetal anomalies in early pregnancy. *Inter J Obstet Gynaecol.* 1999;106(6):516-23.
3. Medical termination of pregnancy act, 2002, ministry of health and family welfare, government of India. Available at: <https://mohfw.nic.in>. Accessed on 10<sup>th</sup> May 2020.
4. Običan SG, Finnell RH, Mills JL, Shaw GM, Scialli AR. Folic acid in early pregnancy: a public health success story. *The FASEB J.* 2010;24(11):4167-74.
5. Garne E, Dolk H, Loane M. EUROCAT, website, data on prenatal detection rates of congenital anomalies. *J Med Screen.* 2010;17:97-98.
6. Yagel S, Cohen SM, Porat S, Daum H, Lipschuetz M, Amsalem H, et al. Detailed transabdominal fetal anatomic scanning in the late first trimester versus the early second trimester of pregnancy. *J Ultrasound Med.* 2015;34(1):143-9.

7. Iliescu D, Tudorache S, Comanescu A, Antsaklis P, Cotarcea S, Novac L, et al. Improved detection rate of structural abnormalities in the first trimester using an extended examination protocol. *Ultras Obstet Gynecol.* 2013;42(3):300-9.
8. Grossman D, Blanchard K, Blumenthal P. Complications after second trimester surgical and medical abortion. *Reprod Health Matters.* 2008;16(sup31):173-82.
9. Reitter A, Stücker AU, Buxmann H, Herrmann E, Haberl AE, Schlößer R, et al. Prenatal ultrasound screening for fetal anomalies and outcomes in high-risk pregnancies due to maternal HIV infection: a retrospective study. *Infect Dis Obstet Gynecol.* 2013;2013.
10. Coleman PK. Diagnosis of fetal anomaly and the increased maternal psychological toll associated with pregnancy termination. *Issues L Med.* 2015;30:3.

**Cite this article as:** Patel AD, Shingadia JB, Patel D. An observational study of abnormal findings in fetus during 11-13+6 weeks and targeted imaging for fetal anomalies ultrasonography. *Int J Reprod Contracept Obstet Gynecol* 2020;9:3428-31.