

DOI: <https://dx.doi.org/10.18203/2320-1770.ijrcog20211541>

Case Report

Case report of venous air embolism in complete placenta previa in a case of lower segment caesarean section

Korichi Noureddine*, Lakshmi Ramanathan, Aboobaker Thode,
Vipin Reghunatan Vijyakumari

Department of Anesthesia, Pain Management, SICU and Peri Operative Medicine, Doha, Qatar

Received: 07 February 2021

Received: 17 March 2021

Accepted: 25 March 2021

*Correspondence:

Dr. Korichi Noureddine,

E-mail: noureddine_korichi@yahoo.fr

Copyright: © the author(s), publisher and licensee Medip Academy. This is an open-access article distributed under the terms of the Creative Commons Attribution Non-Commercial License, which permits unrestricted non-commercial use, distribution, and reproduction in any medium, provided the original work is properly cited.

ABSTRACT

Thromboembolic episodes in the pregnant and postpartum period in patients remain rare but fatal causes of maternal morbidity and mortality. They can be either venous air embolism, venous thrombo-embolism which include deep vein thrombosis and pulmonary embolism and last but not the least amniotic fluid embolism. The incidence of embolic episodes is more in LSCS patients than in patients coming for normal vaginal deliveries for all the type of embolisms, ranging from 10-97% for air embolisms depending on the surgical position and diagnostic tools with a potential for life threatening events, for venous thromboembolism (VTE) it is 0.5-2.2% patients per 1000 deliveries and increased 5-10-fold in pregnancy and 15-35% in postpartum period as compared to the non-pregnant women, the highest being during the 1st 3-6 weeks postpartum. After that the risk declines rapidly, although a small risk increase persists up to 12 weeks. After delivery, incidence of pulmonary embolism ranges from 0.11-0.73% per 1000 deliveries. It is rare, unpredictable, and unpreventable life-threatening complication of pregnancy. According to the International Cooperative Pulmonary Embolism registry, the death rate from massive PE among hemodynamically unstable patients is 52%. Last but not the least, incidence of amniotic fluid embolism ranges from 1/8000 to 1/15000. Delayed diagnosis, delayed treatment or inadequate treatment and inadequate thromboprophylaxis account for many of these deaths. Hence, early detection and proper management helps to prevent maternal mortality and morbidity in our patients. Also, thrombotic prophylaxis helps in preventing the fatal outcome and morbidity and mortality in our patients. Here, we report a case of a patient with complete placenta Previa scheduled for elective Lower segment caesarean section who developed venous air embolism (VAE) but with prompt detection and treatment a fatal outcome was prevented.

Keywords: Venous thromboembolism, Venous air embolism, Lower segment caesarean section, Diagnosis, Treatment, prognosis, Thromboprophylaxis

INTRODUCTION

This is a case report of a patient with complete placenta previa scheduled for elective LSCS under general anesthesia who developed venous air embolism during LSCS but with early detection and prompt treatment a fatal outcome and mortality and morbidity was prevented.

Venous embolisms are rare but severe complication of pregnancy and puerperium. They occur in the pregnant and

post-partum period and are one of the fatal causes of maternal mortality and morbidity.¹ There is a higher incidence in pregnancy and in post-partum period due to the physiological, hormonal and haemostatic changes during pregnancy. Moreover, the embolic episodes are higher with LSCS than with normal vaginal deliveries. In particular, surgical birth via abdominal route is burdened with a higher risk as compared to spontaneous birth.² Major predisposing factors include increasing maternal age, operative delivery, immobilization, obesity, heart

disease, malignancy, Caucasian descent, pre-eclampsia, a history of thrombosis, thrombophilia and familial thrombosis.³

Incidence of air embolism (entrapment of air/medical gases from ruptured veins to the central venous system producing embolism of right heart or pulmonary artery) in LSCS is around 10-97% depending on the surgical position and diagnostic tools used with potential life-threatening events.⁴ Medical gases such as CO₂, N₂O, N₂, helium can aggravate this condition.

The first fatal case of air embolism associated with pregnancy was reported in 1850 by Cormack. In 1947, Durant et al. indicated for the first time that uterine sinuses are theoretically vulnerable to the entrance of air, especially in the presence of placenta previa or during manual extraction of the placenta.⁴

Venous thrombo-embolism may manifest as pulmonary embolism or deep vein thrombosis, an important cause of maternal morbidity is a serious and potentially fatal condition. Incidence is about 0.5-2.2 per 1000 deliveries.⁵ The incidence increases 5-10-fold in pregnant women as compared to non-pregnant women of comparable age. It is increased 15-35-fold during the post-partum period and is highest during the first 3-6 weeks postpartum and subsequently decreases rapidly. A small risk may persist for up to 12 weeks post-partum.⁵

The embolism occurs due to hemodynamic, hormonal and haematological changes which cause hypercoagulability as a secondary condition.² Treatment and prevention of obstetric related venous thrombo-embolism is complicated by the need to consider both fetal and maternal wellbeing while making management decisions.⁶

It is important that anti thrombotic prophylaxis with heparin should be administered. Although this has various collateral effects like haemorrhage, platelet deficiency, osteoporosis, it protects the women from the fatal thrombo-embolic episodes if in the patient, an LSCS is performed or if there is a positive personal and family history for this pathology.²

Amniotic fluid embolism is a rare but fatal obstetric emergency which causes dyspnea, sudden cardiovascular collapse or respiratory arrest, altered mentation, DIC, a combination of events that leads to maternal morbidity and mortality but in this case the prediction of treatment is difficult.

It was first described in 1926 and as a disease entity in 1941. It has varying incidence of 1/8000 to 1/15000 and causes hypotension, fetal distress, DIC and cardiac arrest.⁷ Major factors related are anaphylaxis, vascular occlusion by particulate matters, vasoconstriction by prostaglandins or others and DIC.

Diagnosis is usually clinical and other diseases that should be differentially diagnosed need to be basically excluded. Early Detection and treatment and thromboprophylaxis are a key to successful outcome.^{6,7}

CASE REPORT

Our patient was a 40-year-old, Gravida 6 para 5, 36 weeks and 1 day with complete placenta previa with transverse lie of the foetus. She had 5 previous vaginal deliveries which were uneventful. She was posted for elective LSCS at the present time. Blood investigations and coagulation profiles were within normal limits.

The third trimester ultrasound showed the following findings-3rd trimester single viable intra-uterine fetus with cephalic presentation. Left lateral placenta, vascular structures related to the internal OS and covering the internal OS completely should be correlated clinically.

Considering her multiparity and her present condition of a complete placenta previa and anticipating a PPH, 2 units of packed red blood cells were cross matched and kept ready.

After discussion and planning to give a general anaesthesia and consent being taken accordingly, the necessary preparations were made. She was premedicated with sodium citrate 30 ml orally and antibiotic cefazolin 2000 mg given IV. The patient was shifted to the obstetric theatre and 2 large bores intravenous canulae were inserted (18 G) and the medications were prepared. The patient was connected to the basic monitors like ECG to monitor heart rate, NIBP to measure the BP every 5 min and pulse oximeter to monitor the SPO₂. Also measures to prevent aspiration risk and to prevent hypothermia were ready in place. The patient was wearing anti thrombotic stockings when she was shifted from the ward in order to prevent VTE. Temperature probe and n-capnometer were also kept ready. The anesthesia machine was calibrated and kept ready.

The patient was first preoxygenated with 100% O₂ for 3 minutes. She was induced with propofol 2 mg/kg (200 mg) and suxamethonium 1 mg/kg (100 mg). A rapid sequence intubation was done using sustained cricoid pressure. The patient was intubated with size 7.5 cuffed endotracheal tube. Air entry checked bilaterally, and the tube fixed. Patient was maintained on O₂+air with 50% FiO₂, Sevoflurane, and Rocuronium. Initial dose of Rocuronium 30 mg was given to maintain prolonged relaxation. Temperature monitoring was also done using a nasopharyngeal temperature probe.

A baby boy 2704 gms was delivered uneventfully of weight 2704 gms with an Apgar of 8/9. The baby was accessed after cutting through the placenta and baby was delivered with a part of placenta cut through and both baby and part of placenta were delivered simultaneously. The remaining placenta was delivered in bits and pieces.

At that time, the anesthesiologists noticed a sudden drop in end tidal CO₂ from 38-19 and then to 12. The airway pressures increased from 32 to 42.

SPO₂ dropped to 69% and heart rate dropped from 101/min to 46/min. The blood pressures also dropped, and pulse was very feeble and BP became not recordable.

Immediately, the FiO₂ was increased to 100% O₂ and hand ventilation was done and patient was hyperventilated with 100% O₂. Also, other maneuvers like Trendelenburg's position and flooding the surgical field with saline was done. Intravenous fluids were pushed using pressure bag. Depth of anaesthesia was increased with a repeat dose of rocuronium 20 mg and increasing the MAC of Sevoflurane delivered and Fentanyl 100 mcg was given. Hand ventilation was continued and an ABG was sent atropine 0.5 mg and ephedrine 9 mg IV was also given.

With all these maneuvers the heart rate increased to 159/min and later stabilized to 100-120/min. The blood pressures improved from 82/53 mmHg to later stabilizing to 115/85 mmHg. The ETCO₂ increased from 12-21 and then after 5-7 min was showing 29-31 on the capnogram. Airway pressures also normalized to 23. The SPO₂ improved to 88% and then with continued ventilation improved to 97%. The FiO₂ was subsequently and gradually reduced to 60%, when HR-112/min, BP-120/88 mmHg, SPO₂-97% and ETCO₂-32.

After baby delivery uterotonics were started with a bolus of 5 units syntocinon, and 40 units synto 2 as 125 ml/hr. infusion. Methergine was also given 0.2 mg IM.

Gelatin 500 ml given rapidly using pressure bag. 1-unit PRBC was given other medications given were antiemetics- ondansetron 4 mg, dexamethasone 8 mg, and hydrocortisone 100 mg, paracetamol 1000 mg and morphine 15 mg IV given in incremental doses to counter post-operative pain.

Total IV fluids were 1850 ml ringer lactate, gelatin 500 ml, and 1-unit PRBC. Total estimated blood loss was 1630 ml and urine output was 200 ml during the duration of surgery. The patient was adequately reversed with sugammadex and extubated.

Patient was shifted to surgical Intensive Care Unit in v/o further evaluation for embolism and to rule out pulmonary embolism and for continuous monitoring in the post-operative period and in v/o further management to prevent any untoward event or outcome to prevent maternal morbidity and mortality.

The patient was managed in the ICU with O₂ mask with reservoir bag 5-6 l/min, serial ABG done and fentanyl and morphine for post-operative analgesia.

Drain output was 200 ml and adequate urine output. After patient improved, she was successfully transferred to the

ward in 24 hours and was discharged home safely after 3 days.

Post-operative ECG showed normal sinus rhythm and no abnormal ST-T changes. Also, the echocardiogram was normal and did not show any e/o pulmonary embolism. The Chest X-Ray was also normal.

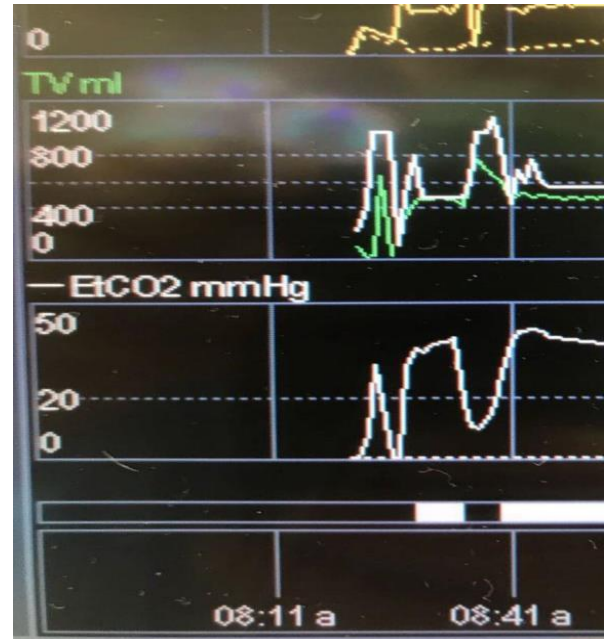


Figure 1: The steep fall in ETCO₂ tracing during surgery.

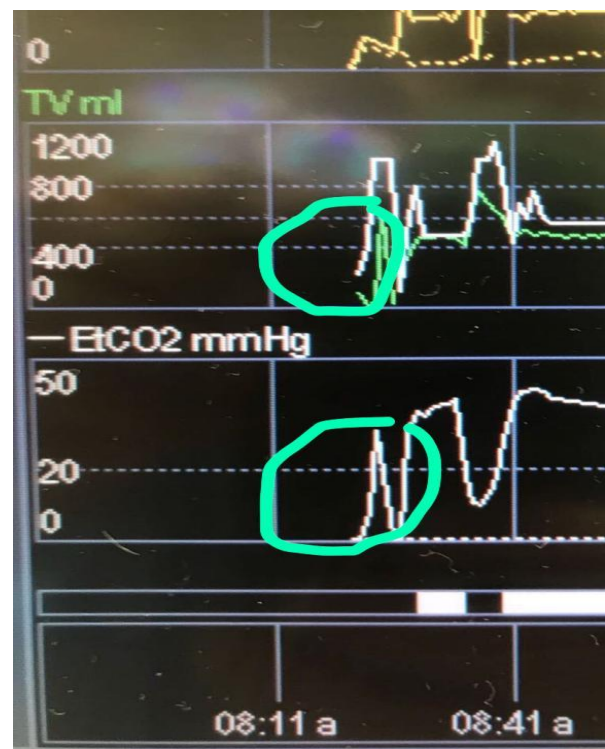

Figure 2: The sudden drop in ETCO₂ during the procedure.

DISCUSSION

Embolism are of 3 types- Venous air embolisms, VTE (PE and DVT) and amniotic fluid embolism. Each of these conditions have varying incidences in pregnant women when compared to non-pregnant women. Also, the incidence is higher in patients undergoing LSCS as compared to patients undergoing spontaneous vaginal delivery. It can also occur with a higher incidence about 15-35-fold in the first 3-6 weeks post-partum period and decreases rapidly over 12 weeks postpartum.⁵

Early diagnosis and treatment is very important and plays a vital role in these cases to make a differential diagnosis of the different types of embolisms. Early and prompt treatment is essential to decrease the mortality and morbidity in such a patient or else it would lead to a fatal outcome.

Anti-thrombotic prophylaxis with heparin is also vital in reducing the incidence of embolism in pregnancy especially those patients going for LSCS.² Thrombotic prophylaxis is a very essential component in preventing postpartum VTE following caesarean sections and is very important in reducing the incidence of associated maternal mortality and morbidity. The treatment and prevention of venous thromboembolism is complicated in this patient population by the needs to consider fetal and maternal well-being when making management decisions.²

Thromboprophylaxis seems widely underutilized in patients undergoing LSCS as compared with patients undergoing other surgeries. Only about 25% patients wear anti-thrombotic stockings and only about 3% patients are given heparin. (The women wearing these stockings are the patients mainly posted for elective LSCS whereas about 75% of the patients especially those coming for emergency LSCS or those following LSCS do not receive any prophylaxis wherein the incidence of embolism could be higher. Also, this incidence could be higher in emergency LSCS as compared to the elective cases.⁸

Important diagnostic tools are D dimer studies (increasing D dimer levels, greater in the postpartum period in those after caesarean delivery as compared to those following vaginal deliveries due to greater activation of coagulation,⁸ FEN₂(increasing levels of FEN₂) and Doppler studies to rule out any history of embolism,⁹ decreasing ETCO₂ levels.⁴

Transesophageal echocardiography and pulmonary artery catheter are relatively sensitive and efficacious but invasive methods of monitoring which are not routinely used as it is expensive and requires expertise for its usage.⁴ Measures to reduce the size and effect of air emboli should be applied routinely in all patients.⁹ Early recognition of PE and early identification of patients who are to be treated with anticoagulants are the keys to a successful outcome. The use of ECMO system to support and stabilize the patients with PE until the definite diagnosis is made is also

documented. Treatment with anticoagulants should start immediately and continue until the diagnosis of thromboembolism is eliminated.¹⁰ Also, the use of thromboprophylaxis and intermittent pneumatic stockings used during LSCS and in post-partum period routinely for patients who are at high risk of developing the thromboembolic episodes prevents the fatal outcome and maternal morbidity and mortality in obstetric patients.¹¹ There have been case reports of placenta previa patient coming for LSCS, which were managed by giving regional anesthesia and who developed embolism during the surgical procedure as depicted by cardiac arrest which developed after baby delivery and which have led to fatal outcome.¹² There have also been case reports where in prompt treatment has prevented the fatal outcome and maternal morbidity and mortality.

In our case, it was discussed earlier by the anesthesiologist and obstetrician and a general anesthesia was preferred and given in v/o complete placenta previa anticipating the blood loss and taking into consideration the multiparity and the condition of the placenta. Also, blood as ready in the theatre at the time of giving anesthesia even before the surgery started. Moreover, the event that occurred during the surgery at the time of baby delivery was very promptly detected by our team of anesthesiologist and appropriate measures were taken and maneuvers to correct the hemodynamic and airway changes in order to prevent any untoward outcome. Fluids were rushed intravenously, surgical site flooded with saline along with hyperventilation with 100% O₂ and medications to improve the hemodynamics of the patient and thereby prevent any untoward outcome. By using the various techniques, a fatal event was prevented. After the surgery, the patient was successfully extubated and shifted to the ICU for further monitoring and to rule out any pulmonary embolism and also to prevent any fatal outcome. Further investigations in the ICU ruled out any pulmonary embolism and amniotic fluid embolism as her ECHO, ECG and X-Ray of Chest were normal and also her coagulation profile postoperative which ruled out any DIC. Her investigations ruled out any fatal outcome.

So, we could come to a conclusion of a final diagnosis of transient venous air embolism in a case of complete placenta previa posted for LSCS which was promptly detected and immediately treated and a fatal outcome was avoided.

CONCLUSION

Thromboembolic episodes are rare but fatal complications during pregnancy and postpartum period, more common in LSCS as compared to spontaneous deliveries. Early detection using diagnostic tools and treatment can help avert a fatal outcome. Also, routine use of thromboprophylaxis especially in high risk patients will help in reducing the mortality and morbidity of this group of patients. Guidelines on the use of thromboprophylaxis have reduced deaths after caesarean delivery.

Funding: No funding sources

Conflict of interest: None declared

Ethical approval: Not required

REFERENCES

1. Ducloy Bouthors AS, Baldini A, Abdul-Kadir R, Nizard J. ESA VTE Guidelines Task Force. European guidelines on perioperative venous thromboembolism prophylaxis: Surgery during pregnancy and the immediate postpartum period. *Eur J Anaesthesiol.* 2018;35(2):130-3.
2. Corosu R, Vizzaccaro F, Moretti S. Incidence of thromboembolic complications in cesarean sections and heparin prophylaxis. *Minerva Ginecol.* 1999;51(5):173-6.
3. Lindqvist PG, Torsson J, Almqvist A, Björgell O. Postpartum thromboembolism: severe events might be preventable using a new risk score model. *Vasc Health Risk Manag.* 2008;4(5):1081-7.
4. Kim CS, Liu J, Kwon JY, Shin SK, Kim KJ. Venous air embolism during surgery, especially cesarean delivery. *J Korean Med Sci.* 2008;23(5):753-61.
5. Bates SM, Middeldorp S, Rodger M, James AH, Greer I. Guidance for the treatment and prevention of obstetric-associated venous thromboembolism. *J Thromb Thrombolysis.* 2016;41(1):92-128.
6. Devis P, Knuttinen MG. Deep venous thrombosis in pregnancy: incidence, pathogenesis and endovascular management. *Cardiovasc Diagn Ther.* 2017;7(S3):309-19.
7. Lee JH, Yang HJ, Kim JH, Lee SY, Gill HJ, Kim BK, Kim MG. Amniotic fluid embolism that took place during an emergent Cesarean section -A case report-. *Korean J Anesthesiol.* 2010;59S:158-62.
8. Blondon M, Casini A, Hoppe KK, Boehlen F, Righini M, Smith NL. Risks of Venous Thromboembolism After Cesarean Sections: A Meta-Analysis. *Chest.* 2016;150(3):572-96.
9. Lew TW, Tay DH, Thomas E. Venous air embolism during cesarean section: more common than previously thought. *Anesth Analg.* 1993;77(3):448-52.
10. Ho YK, Wang CP, Wu YL, Lee TH, Ying TH, Lee MS. Pulmonary embolism after cesarean section and successful treatment with early application of extracorporeal membrane oxygenation system and anticoagulant agents. *Taiwan J Obstet Gynecol.* 2014;53(2):273-5.
11. Casele H, Grobman WA. Cost-effectiveness of thromboprophylaxis with intermittent pneumatic compression at cesarean delivery. *Obstet Gynecol.* 2006;108(3 Pt 1):535-40.
12. Kostash MA, Mensink F. Lethal air embolism during cesarean delivery for placenta previa. *Anesthesiology.* 2002;96(3):753-4.

Cite this article as: Korichi Noureddine, Lakshmi Ramanathan, Aboobaker Thode, Vijyakumari V. Case report of venous air embolism in complete placenta previa in a case of lower segment caesarean section. *Int J Reprod Contracept Obstet Gynecol* 2021;10:2067-71.