

DOI: <https://dx.doi.org/10.18203/2320-1770.ijrcog20211170>

Case Report

Transmigration of copper T presenting as abdominal wall mass: a case report

T. Ramani Devi*, S. Shameema Banu, T. Harini, P. Kanimozhi

Department of Obstetrics and Gynecology, Ramakrishna Medical Centre LLP, Trichy, Tamil Nadu, India

Received: 19 December 2020

Accepted: 26 February 2021

***Correspondence:**

Dr. T. Ramani Devi,

E-mail: ramanidevidr@yahoo.co.in

Copyright: © the author(s), publisher and licensee Medip Academy. This is an open-access article distributed under the terms of the Creative Commons Attribution Non-Commercial License, which permits unrestricted non-commercial use, distribution, and reproduction in any medium, provided the original work is properly cited.

ABSTRACT

Copper T is one of the widely used intra uterine contraceptive devices due to its safe, effective and reversible nature. It has also been widely used as it is cost effective too. Copper T is usually inserted immediate post-partum, post abortal, during the proliferative phase of any menstrual cycle or 6 to 8 weeks following post-partum. Complications associated with use of Copper T include heavy menstrual bleeding, pelvic inflammatory disease, uterine perforation, displacement and rarely, transmigration. Post-insertion of copper T, women need to have regular follow up visits to prevent such complications. Patients should be advised to check for the presence of threads periodically. Considerable number of patients with transmigration of copper T has been reported in literature. Sites into which transmigration has been reported include broad ligament, ovarian fossa, urinary bladder, sigmoid colon, rectum, peritoneum, omentum, pouch of douglas, retro peritoneal space, iliac veins, ovaries, appendix and rarely in the abdominal wall. Transmigrated copper T may be diagnosed with ultrasonogram, X-ray and CT scan. Copper containing intra-uterine devices are known to provoke inflammatory reactions and symptoms depending upon the sites to which they have been transmigrated. Hence, we should resort to early intervention and remove the misplaced copper IUCD at the earliest. Here, we are reporting a rare case of transmigration of copper T into the anterior abdominal wall elaborating on various facets of copper T including its advent, incidence of use, efficient diagnosis and well-planned retrieval.

Keywords: Anterior abdominal wall, Displacement of copper T, Transmigration of IUCD, Retrieval of copper T.

INTRODUCTION

Copper T is a commonly used effective, reversible, economic and safe method of contraception since its introduction in the year 1965. It leads to sterile, inflammatory changes in the endometrium preventing implantation, while hormone releasing IUD causes atrophy of the endometrium, cervical mucous impermeability to the sperms and impairs the ciliary motility in the fallopian tubes providing contraception.¹⁻³ Copper T is usually inserted immediate post-partum, post abortal, during the proliferative phase of any menstrual cycle or 6 to 8 weeks following post-partum.

Worldwide, 20% women of reproductive age group use IUCD as the preferred mode of contraception. Whereas, in India it is only 3-5%.⁴ Furthermore, in Tamil Nadu, the reported incidence is around 1% only.

Perforation and transmigration are likely to occur in 1 in 350, 1 in 2500 insertions.⁵ Sites into which transmigration has been reported include broad ligament, ovarian fossa, urinary bladder, sigmoid colon, rectum, peritoneum, omentum, pouch of Douglas, retro peritoneal space, iliac veins, ovaries, appendix and rarely in the abdominal wall.⁶⁻¹³ Transmigration into the bladder can lead to calculus formation.¹⁴

First case of transmigration of Copper T IUCD to the anterior abdominal wall has been reported by Moulana Mohamed Ansari in 2009; since then, sparse literature evidence regarding the same are available.¹⁵ 15 cases of acute appendicitis due to transmigration of IUCD has also been reported in the literature.¹⁶

Depending upon the site of transmigration, it may be symptomless or may cause severe symptoms.

Possible serious complications restrict the utilisation of intrauterine device as a contraceptive method in general population. Complications of copper T IUCDs are heavy menstrual bleeding, pelvic inflammatory disease, uterine perforation, displacement and trans migration of the device.¹ Displacement is seen to occur in 5% of the patients.¹⁷ As a result of displacement, patient can conceive and the other symptoms depend upon the location to which it has been displaced.

Usually, the diagnosis is made clinically when there is failure to locate the copper T threads either by self-palpation or by examination. X-ray can be used to localise the IUCD anywhere in the abdominal cavity.¹⁸⁻²¹ Ultrasound imaging can help to a certain extent in diagnosing the migrated location. Partial migration can be picked up and retrieved by hysteroscopy.^{1,17,22,23} Once the location is identified retrieval is either through endoscopy or laparotomy depending upon the expertise of the surgeon, facilities available and the location of migration.²⁴

CASE REPORT

A 30-year old female presented to us with complaints of pain and swelling over the para-umbilical region for the past 1 week.

Menstrual history

She gave history of regular cycles with no dysmenorrhea or menorrhagia with a recent LMP.

Medical history

Nil relevant.

Obstetric history

She is married for 10 years. She landed with intra-uterine death at term in her first pregnancy, which she delivered spontaneously, one year after marriage. Next pregnancy was uneventful and she delivered by LSCS at our hospital the following year. Third pregnancy was a repeat LSCS at our hospital, 3 years after the second baby. She had IUCD inserted 60 days after the second caesarean under Ultrasound Guidance which is a routine practice in our clinical setup. 6 months later, she came for review and ultrasound showed IUCD in situ. 10 months after copper

T insertion, she came with a history of 40 days of amenorrhea.

Ultrasound examination showed presence of gestational sac and IUCD was not seen. Hence, we thought that the patient would have expelled the IUCD. She was not keen on continuing the pregnancy and hence it was terminated by medical means. Cavity was found to be empty by USG after a week. That time, she was advised laparoscopic sterilisation. Two years later, she came to us with complaints of pain and swelling over the right para-umbilical region for the past 1 week. On clinical examination, she was found to have a tender mass of 3x3cm on the right paraumbilical region. It was found to be superficial and had evidence of inflammation. She underwent ultrasound examination of the abdomen and pelvis. To our surprise, there was a presence of linear echogenic shadow in the subcutaneous plane on the right para umbilical region with a fluid collection around it, which was suggestive of IUCD surrounded by inflammation. Intra peritoneal organs were found to be normal. On the same day, she had an x-ray of the abdomen, both antero-posterior and lateral views, which showed Copper T at the sub cutaneous plane of anterior abdominal wall at the level of L3 and L4. Patient was admitted for removal of the copper T and concurrent laparoscopic sterilisation.

Intra operative findings

Under general anaesthesia, laparoscopy was inserted by two ports; which showed an absolutely clean pelvis with no evidence of omental adhesions. The peritoneal surface of right para umbilical region was absolutely normal. Anterior wall of the uterus showed a small area of weakness when the uterine sound was passed. Bilateral sterilisation was done as per the patient's request. Next, the incision was made over the swelling. In the subcutaneous plane, there was a cavity which drained 5-7ml of pus. The cavity was explored and found to have the copper T, which was entangled by the inflammatory tissue. Copper T along with the inflamed subcutaneous tissue was removed. Rectus sheath was found to be intact. Saline and betadine lavage was given. Skin closed with a drain. Patient was continued with antibiotics for five days.

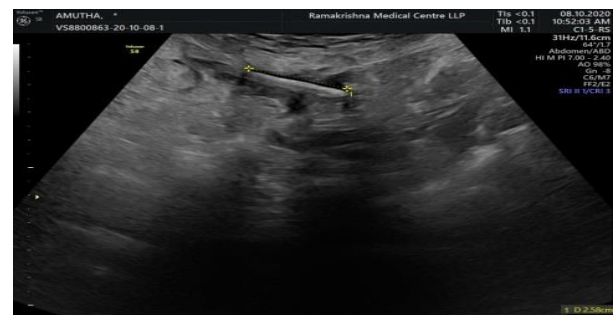


Figure 1: Ultrasound image depicting transmigrated copper T.

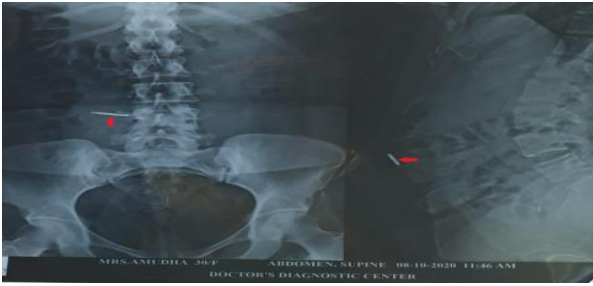

Figure 2: X-ray of the abdomen, antero-posterior and lateral views showing copper T.

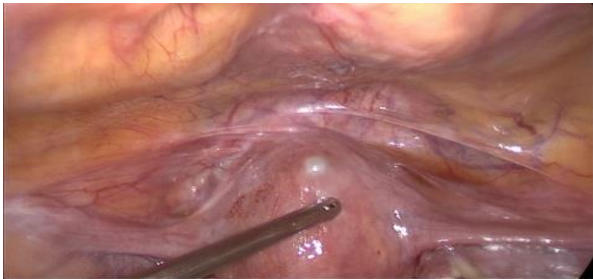

Figure 3: Laparoscopic Image showing the weak spot in the anterior wall.

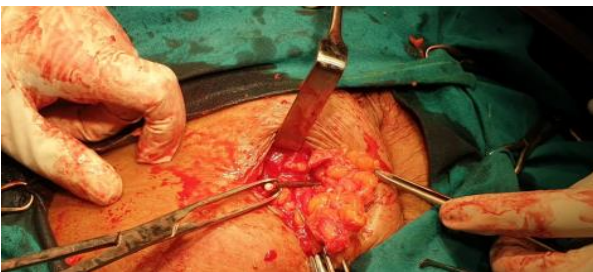


Figure 4: Operative picture showing retrieval of copper T.

DISCUSSION

In developing countries, intra uterine contraceptive devices are one of the most preferable family planning methods. As it is very cost effective and it can be used long-term, various copper containing devices like copper T 200, 220C, 380A multi load 250, 375 are available. Transmigration of copper T is one of the rarest but known complications. The copper content can provoke inflammation when there is transmigration when compared to inert IUCDs.²¹ Migration is found to be high in immediate post-partal insertions which can be incomplete (within the myometrium) or complete (intra peritoneum).

The risk factors for transmigration are, nullipara, post-partum, post abortal IUCD placement or faulty technique of insertion and irregular follow up.²⁵ Other possible causes for transmigration are contraction of the urinary bladder, gut peristalsis and movement of the peritoneal fluid.²⁶

Chang and colleagues emphasised that the following factors influence the transmigration like time of insertion, parity, type of IUCD, experience of the operator and position of the uterus.¹⁶ Transmigration of copper T is known to occur in lactating mothers similar to our case; where the soft uterus during the lactational period can be the predisposing factor.²⁷

Displacement of the IUCD can be totally asymptomatic or it may present with features of dysuria, abdominal pain and inflammatory swelling which depends upon the site of transmigration. Though transmigration is possible within the pelvis due to perforation and the peristalsis which happens; it is very rare to see transmigration in remote places like stomach, veins, colon and abdominal wall. There has been reported case of transmigration of IUCD into the stomach by Kumari et al which has been successfully removed through laparoscopy. Complications of IUCD usage are dysmenorrhea, pelvic inflammatory disease, ectopic pregnancy, septic abortions and hydrosalpinx. The possible reason for perforation is due to fragile uterine wall in the immediate post-partum or post abortal period.

Perforation could be at the time of insertion or it could be secondary to uterine contractions. Perforations on the time of insertion can be avoided by insertion under ultrasound guidance.²³ Sometimes, patient can conceive with IUCD in situ which can be removed safely when thread is seen without affecting the gestational sac or it could be done using hysteroscopy also.²⁸ Occasionally, babies have been born at term with implanted IUCD in the placenta.

Ultrasound is a useful tool in detecting the presence or absence of IUCD. Displaced IUCDs can be safely retrieved through laparoscopy if it is intraperitoneal or through laparotomy if it is extra peritoneal.^{20,29,30} If there is partial implantation into the myometrium it could be removed through hysteroscopy.^{22,28} Translocated IUDs can provoke severe fibroblastic reaction which will prevent its visualisation in the ultrasound. Even in laparoscopy, it may be difficult to identify the migrated copper T as it will be found entangled by the omentum. Plain X-ray is a very simple, cost effective, diagnostic measure which is often forgotten in the era of ultrasound and CT. Computed tomography can be used to identify the exact location if it cannot be picked up by the ultrasound or X-ray abdomen.

Transmigration in to the abdominal wall may also be associated with actinomycotic infection. Whenever there is history of missing IUCD, we have to think about transmigration and expulsion. Simple abdominal X-ray and ultrasound will be of diagnostic value in differentiating the two. Surgical removal is a must in transmigrated IUCDs.

Patients should be counselled regarding self-examination to identify the copper T thread and should have a

consultation with the gynaecologist if there is a missing thread. Even asymptomatic migrated copper T should be retrieved to prevent future complications as the patients are also psychologically upset.³¹

CONCLUSION

Migration of IUCD secondary to uterine perforation very often goes unnoticed. Regular self-examination of missing threads supplemented with clinical and radiological evaluation can detect the migration. Emphasis should be made on the simple diagnostic tool i.e., plain X-ray of abdomen. Migrated copper T should be removed at the earliest to avoid serious complications.

Funding: No funding sources

Conflict of interest: None declared

Ethical approval: Not required

REFERENCES

1. Elahi N, Koukab H. Diagnosis and management of lost intrauterine contraceptive device. *J Pak Med Assoc.* 2002;52(1):18-20.
2. Bednarek PH, Creinin MD, Reeves MF, Cwiak C, Espey E, Jensen JT. Immediate versus delayed IUD insertion after uterine aspiration. *N Engl J Med.* 2011;364(23):2208-17.
3. Rivera R, Yacobson I, Grimes D. The mechanism of action of hormonal contraceptives and intrauterine contraceptive devices. *Am J Obstet Gynecol.* 1999; 181(5):1263-9.
4. Sharma M, Joshi S, Nagar O, Sharma A. Determinants of intrauterine contraceptive device discontinuation among Indian women. *J Obstet Gynecol India.* 2014;64(3):208-11.
5. Ohana E, Sheiner E, Leron E, Mazor M. Appendix perforation by an intrauterine contraceptive device. *Eur J Obstet Gynecol Reprod Biol.* 2000;88(2):129-31.
6. Sasidharan K, Chally R. Intravesical migration of Lippes loop with stone formation. *Brit J Urol.* 1988;61(4):363.
7. Laxmi M, Hemlata J, Rani LP. An unusual case of copper-T in the rectum. *J Obstet Gynecol India.* 2005;55(1):79-80.
8. Browning JJ, Bigrigg MA: Recovery of the intrauterine contraceptive device from the sigmoid colon. Three case reports. *Br J Obstet Gynaecol* 1988;95:530-2.
9. Mansoor T, Aslam M, Rizwi S, Haseen M. Copper-T causing perforation of sigmoid colon. *Surg.* 2006;13(1).
10. Kassab B, Audra P. The migrating intrauterine device. Case report and review of the literature. *Gynecol Obstet Fertil.* 1999;27(10):696-700.
11. Sarkar P. Translocation of a copper 7 intra-uterine contraceptive device with subsequent penetration of the caecum: case report and review. *BMJ Sexual Reprod Health.* 2000;26(3):161-8.
12. Silva PD, Larson KM. Laparoscopic removal of a perforated intrauterine device from the perirectal fat. *JSLs.* 2000;4(2):159.
13. Roy KK, Banerjee N, Sinha A. Laparoscopic removal of translocated retroperitoneal IUD. *Int J Gynecol Obstet.* 2000;71(3):241-3.
14. Demirci D, Ekmekçioğlu O, Demirtaş A, Gülmez İ. Big bladder stones around an intravesical migrated intrauterine device. *Int Urol Nephrol.* 2003;35(4): 495-6.
15. Ansari MM, Harris SH, Haleem S, Fareed R, Khan MF. Foreign body granuloma in the anterior abdominal wall mimicking an acute appendicular lump and induced by a translocated copper-T intrauterine contraceptive device: a case report. *J Med Case Reports.* 2009;3(1):1-3.
16. Chang HM, Chen TW, Hsieh CB, Chen CJ, Yu JC, Liu YC, Shen KL, Chan DC. Intrauterine contraceptive device appendicitis: a case report. *World J Gastroenterol.* 2005;11(34):5414.
17. Hasanain FH. The misplaced IUD. *Int J Gynaecol Obstet.* 2002;78(3):251-2.
18. Yilmaz Y, Bayraklı H, Cecen K, Güneş M. An unusual foreign body in the bladder. *Eastern J Med.* 2002;7(2):43-4.
19. Aghaways I, Wahid SA, Ali RH, Sabir F, Kakamad FH. Migration of an intrauterine device to the left inguinal region, the first reported case. *Int J Surg Case Rep.* 2016;28:68-70.
20. Chell KI, Lipscomb GH. Abdominal wall abscess presenting 35 years after insertion of an intrauterine contraceptive device. *Obstet Gynecol.* 2010;115(2): 458-9.
21. Singhal SR, Marwah DS, Paul A, Singhal SK. Missed intra uterine device: a rare indication for appendicectomy-case report with review of literature. *East Cent Afr J Surg.* 2010;15(2):156-8.
22. Arif SH, Mohammed AA. Migrated intrauterine device presented as anterior abdominal wall abscess. *J Surg Case Rep.* 2019;2019(6):rjz174.
23. Li-li H. X.-l. S., Shao-hua LLW. The clinical role of ultrasound in inserting intrauterine device and diagnosing IUD abnormal position. *China Med Herald* 2008;5:55.
24. Koo HR, Oh YT, Kim YT, Kim SW, Kang JH, Kim KW. Intrauterine device found in an ovarian carcinoma. *J Comput Assist Tomogr.* 2008;32(1):69-71.
25. Moulay A, Zahi M. Abdominal migration of intrauterine-devices-a report of 4 cases removed by laparoscopy. *Semaine des hopitaux.* 1983;59(42): 2905-9.
26. Eke N, Okpani AO. Extrauterine translocated contraceptive device: a presentation of five cases and revisit of the enigmatic issues of iatrogenic perforation and migration. *Afr J Reprod Health.* 2003;52:117-23.
27. Mittal S, Gupta I, Lata P, Mahajan U, Gupta AN. Management of translocated and incarcerated

- intrauterine contraceptive devices. ANZ J Obstet Gynaecol. 1986;26(3):232-4.
28. Assaf A, El Tagy A, El Kady A, El Agezy H. Hysteroscopic removal of copper-containing intrauterine devices with missing tails during pregnancy. Adv contraception. 1988;4(2):131-5.
29. El-Hefnawy AS, El-Nahas AR, Osman Y, Bazeed MA. Urinary complications of migrated intrauterine contraceptive device. Int Urogynecol J. 2008;19(2):241-5.
30. Ozgun MT, Batukan C, Serin IS, Ozcelik B, Basbug M, Dolanbay M. Surgical management of intra-abdominal mislocated intrauterine devices. Contraception. 2007;75(2):96-100.
31. Otolorin EO. Management of the lost IUD. Afr J Med Med Sci. 1985;14(3-4):125-9.

Cite this article as: Devi TR, Banu SS, Harini T, Kanimozhi P. Transmigration of copper T presenting as abdominal wall mass: a case report. Int J Reprod Contracept Obstet Gynecol 2021;10:1729-33.