

DOI: <http://dx.doi.org/10.18203/2320-1770.ijrcog20180211>

Case Report

A rare case of post-partum cerebral venous sinus thrombosis

Akhileshwar Singh, Sanjay Singh*, Shakti Vardhan

Department of Obstetrics and Gynecology, Armed Forces Medical College, Pune, Maharashtra, India

Received: 13 December 2017

Accepted: 08 January 2018

***Correspondence:**

Dr. Sanjay Singh,

E-mail: drsanjaysingh@gmail.com

Copyright: © the author(s), publisher and licensee Medip Academy. This is an open-access article distributed under the terms of the Creative Commons Attribution Non-Commercial License, which permits unrestricted non-commercial use, distribution, and reproduction in any medium, provided the original work is properly cited.

ABSTRACT

Cerebral venous sinus thrombosis is a rare neurologic emergency during pregnancy. Life threatening complications can be prevented if it is detected and treated well in time. A 24 years P2L3A2 lady, who had undergone elective caesarean delivery developed sudden onset severe episodic parieto-occipital headache and bilateral diminution of vision on 4th post-partum day. She had no known risk factors for thrombosis. There was no history suggestive of sepsis or pre-eclampsia. On clinical examination her blood pressure was found to be very high (164-180/104-110 mm Hg). There was no sensory or motor deficit. Relevant haematological and biochemical investigations were within normal limits. Urinary protein was negative. With a provisional diagnosis of imminent eclampsia, she was put on antihypertensive and Magnesium Sulphate. However, in view of persistence of the symptoms even after 24 hours, contrast-enhanced computed tomography (CECT) was done, which revealed venous infarction in occipital cortex and subcortical white matter. Magnetic resonance (MR) venography confirmed thrombus in left transverse and sigmoid sinuses. Thus, definitive treatment in the form of heparin in therapeutic doses was started. Antihypertensive was continued and prophylactic anticonvulsant was added in view of presence of the infarction. Patient responded well. Vision improved, and headache resolved completely. The patient was discharged on antihypertensive, anticonvulsant and vitamin K antagonist (Warfarin sodium) with an advice of regular follow-up. Cerebral venous thrombosis (CVT) is an uncommon entity and a high index of suspicion is needed to diagnose it at an earlier stage for timely initiation of treatment and prevention of complications. Prognosis in pregnant cases is better than that during a non-pregnant state.

Keywords: Cerebral venous sinus thrombosis, Heparin, Magnetic resonance venography, Pregnancy, Preeclampsia

INTRODUCTION

Pregnancy is a thrombogenic state that puts a pregnant mother at risk of pulmonary thromboembolism (PTE), deep venous thrombosis (DVT) and stroke during antenatal period and more commonly during puerperium.¹ Cerebral venous sinus thrombosis (CVT) is one such known but rare neurologic complication as a result of this during pregnancy. The patient presents with severe headache, neurological deficits and seizures. Superior and lateral sinuses are commonly involved. A high index of suspicion is needed to diagnose this so as to treat and prevent life threatening complications.² Magnetic Resonance (MR) venography is the gold standard for

diagnosis. Prompt treatment of cerebral venous thrombosis during pregnancy with anticoagulants in therapeutic doses leads to reversal of symptoms in most of the cases. Here, we present a rare case of CVT who was initially confused with imminent eclampsia, but was diagnosed in time and thus was successfully managed with a favourable outcome.

CASE REPORT

24 years old, P2L3A2 lady, with no known risk factors for thrombosis, underwent elective caesarean delivery at 37 weeks period of gestation at a peripheral hospital. The indication was twin gestation with breech presentation of

the first twin. Intrapartum and immediate post-partum period were uneventful. She was discharged from the hospital on 3rd post-operative day. However, on 4th post-operative day she developed severe sudden onset episodic parieto-occipital headache and bilateral diminution of vision. For this she was symptomatically treated with analgesics by a local doctor.

Since she did not get any relief, she reported to our institute for further management. Apart from headache and diminution of vision there was no h/o pain abdomen, vomiting, fainting attacks or convulsion, abnormal uterine bleeding and fever. On clinical examination at admission, she was found to have very high BP record (164-180/104-110 mm Hg) with normal pulse and respiratory rate. There was no pedal oedema. The respiratory and cardiovascular system examination was essentially normal. On abdominal examination, uterus was appropriately involuted and vaginal examination showed healthy lochia. On central nervous system examination there was no sensory or motor deficit. Cranial nerve examination and all peripheral reflexes except right sided plantar reflex were normal. Kernig's sign was negative. Plantar response on the right side was extensor. Distant vision was reduced to finger counting at 3 meters. However, fundoscopy revealed no papilloedema. Colour and near vision were normal. Clinically diagnosed as a case of imminent eclampsia, relevant blood investigations were sent, that showed a normal complete blood count with haemoglobin 10g/dl and normal renal, hepatic, and coagulation profiles. Ultrasound abdomen and pelvis revealed normal postpartum uterus without any pelvic collection.

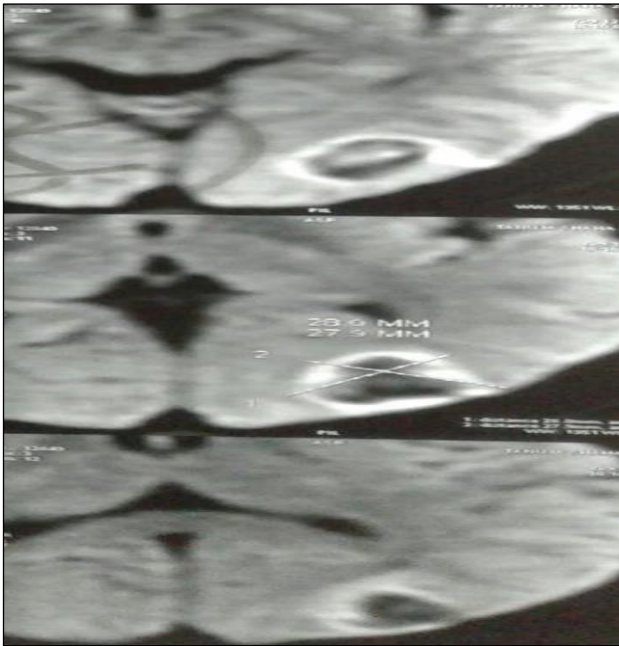


Figure 1: Contrast enhanced computerised tomography (CECT) image (coronal view) showing infarction in left occipital cortex and subcortical white matter.

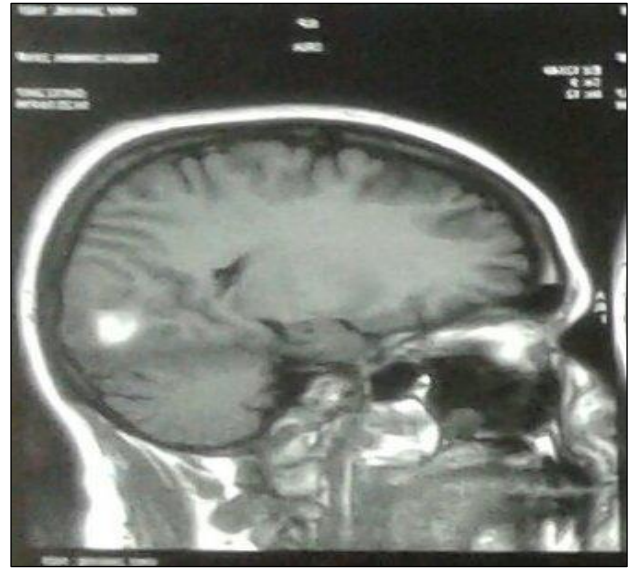


Figure 2: Contrast enhanced computerised tomography (CECT) image (sagittal view) showing infarction in left occipital cortex and subcortical white matter.

Though the imminent eclampsia was our first differential diagnosis, since she had presented late in puerperal period, possibility of migraine, cerebral venous sinus thrombosis, cerebro-vascular accident, meningitis and posterior reversible encephalopathy syndrome (PRES) was also considered. Thus, she was initially treated as a case of imminent eclampsia with injection Labetalol for control of blood pressure and Magnesium Sulphate as per Zuspan regimen for prevention of convulsions. However, patient continued to be symptomatic even after 24 hours of treatment.

In view of above, opinion of a neurophysician was taken and contrast enhanced computerised tomography (CECT) brain was done which showed a venous infarction involving left occipital cortex and subcortical white matter corresponding to visual area (Figure 1, 2). MR venography done in order to find out the cause of this infarction, revealed thrombosis in left sided transverse sinus, sigmoid sinus and jugular vein (Figure 3). Colour Doppler of bilateral lower limbs was also performed that revealed right sided deep vein thrombosis at distal femoral vein and popliteal veins. After arriving to a conclusive diagnosis of Cerebral Venous Sinus Thrombosis, she was managed by team of gynaecologist, neurophysician, cardiologist and haematologist. She was put on Inj. Heparin in therapeutic doses to treat thrombosis. She was also started with prophylactic anticonvulsant in view of presence of the venous infarct. Antihypertensive was continued for control of blood pressure. She responded well and symptomatically improved in terms of headache and diminution of vision. Blood pressure remained in the range of 126-134/84-94 mm Hg. She was put on tablet Warfarin 5 mg once a day after initial therapy to achieve a target INR of 2.0-3.0. The patient was discharged on 21st day of admission with

an advice to continue the same treatment (antihypertensive, antiepileptic and anticoagulation) and report for regular follow-up. She was also stressed upon the need of preconception counselling before planning for the next pregnancy.

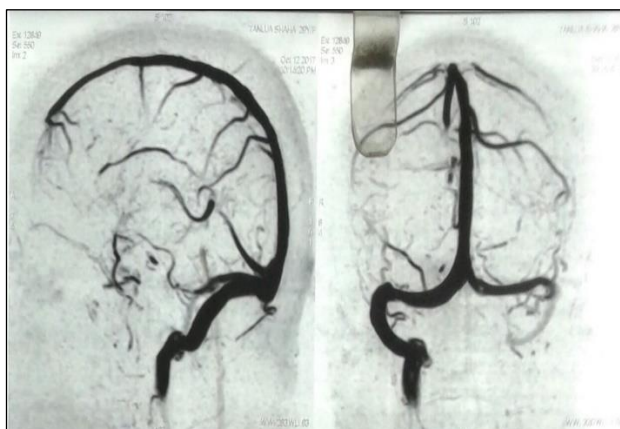

Figure 3: Magnetic resonance (MR) venography image showing thrombus in distal part of left transverse and sigmoid sinuses. Left Jugular vein not visualised.

DISCUSSION

Cerebral venous sinus thrombosis (CVT) is a rare but potentially fatal neurological complication.³ Approximately 7 percent of cerebral venous thromboses are associated with pregnancy.⁴ Its incidence varies between 1 in 11000 to 1 in 45000 pregnancies. It is very rare in developed world.⁵ Superior and lateral sinuses are commonly involved.

Virchow described a triad of inciting factors for venous thrombosis, namely hypercoagulability, venous stasis and vascular damage and all of them occur in pregnancy.⁶ Moreover, there are increased circulating levels of several clotting factors in pregnancy. The incidence of venous thrombo-embolism during pregnancy and the puerperal period has been estimated to be 5.5-6 times higher than in the general female population of child bearing age. Pregnancy associated cerebral venous thromboses is more common in puerperal period as was there in our case followed by late pregnancy.

Risk factors identified for development of cerebral venous sinus thrombosis include age over 40 years, obesity, smoking, congenital or acquired thrombophilias, immobility, malignancy and chronic hypertension.^{6,7} Pregnancy related risk factors include sepsis, pre-eclampsia, thrombophilias and delivery by caesarean section. It is more common in those patients who have inherited thrombophilias, lupus anticoagulant, or antiphospholipid antibodies. Risk factors in our patient were caesarean delivery and hypertension. Thrombophilia profile of the index case was kept pending for a later date, as physiological changes during pregnancy may malign

the report. Moreover, there is a very limited value of testing in the acute setting or in patients taking warfarin.⁸

Headache is the commonest presenting symptom, making it difficult initially to differentiate this rare entity from several common diagnoses such as eclampsia, like in our case. 30% of the patients have convulsions. Neurological deficits are also commonly seen.^{4,9} The specific presentation depends on location and extent of the thrombosis and the presence of associated cortical lesions like the diminution of vision noted in our patient were because of venous infarction involving left occipital cortex and subcortical white matter corresponding to visual area. MR Venography is the diagnostic modality of choice for the diagnosis of CVT in pregnant women.⁸

Our case highlights the importance of keeping a high index of suspicion to differentiate CVT from its several important differential diagnoses like severe pre-eclampsia with premonitory symptoms, cerebrovascular accidents, migraine and post-dural puncture headache, meningitis and PRES.

This case also highlights the importance of multidisciplinary team approach in provisioning of optimal care to the patient. Anticoagulants in therapeutic doses, antihypertensives to optimise blood pressure and anticonvulsant for seizures help preventing life threatening complications in most of the cases. As per American Heart Association (AHA)/American Stroke Association (ASA)- 2011, for patients with CVT, initial anticoagulation with adjusted-dose UFH or weight-based LMWH in full anticoagulant doses is reasonable, followed by vitamin K antagonists, regardless of the presence of ICH.⁸ Antimicrobials are indicated in cases have septic thrombophlebitis. Fibrinolytic therapy is used only in those women who don't respond to systemic anticoagulation.

AHA and ASA (2011) recommends that the vitamin k antagonists may be continued for 3 to 6 months, with a target INR of 2.0 to 3.0, in patients with provoked CVT (associated with a transient risk factor) and for 6 to 12 months in patients with unprovoked CVT. For patients with recurrent CVT, VTE after CVT or first CVT with severe thrombophilia, indefinite anticoagulation may be considered, with a target INR of 2.0 to 3.0.⁸

The prognosis of venous thrombosis in pregnancy is better than in non-pregnant cases. As per McCaulley et al the mortality rate is less than 10%.¹⁰ The recurrence rate in subsequent pregnancy as per Mehraein et al is 1%-2%.¹¹ This underlies the importance of regular follow up of these cases and judicious preconception counselling prior to planning for next pregnancy.

CONCLUSION

Hypercoagulable state of pregnancy makes a female more prone to develop CVT during antepartum and more so

during post-partum period. It may be difficult initially to differentiate this rare entity from several common diagnoses such as eclampsia. However, timely recognition of this problem by keeping a high index of suspicion and early initiation of treatment result in favourable outcome. This case also highlights the importance of multidisciplinary team approach in provisioning of optimal care to the patient.

Funding: No funding sources

Conflict of interest: None declared

Ethical approval: Not required

REFERENCES

1. James AH, Bushnell CD, Jamison MG, Myers ER. Incidence and risk factors for stroke in pregnancy and the puerperium. *Obstet Gynecol.* 2005;106:509-16
2. Cantú C, Barinagarrementeria F. Cerebral venous thrombosis associated with pregnancy and puerperium: review of 67 cases. *Stroke.* 1993;24:1880-4.
3. Lanska DJ, Kryscio RJ. Risk factors for peripartum and postpartum stroke and intracranial venous thrombosis. *Stroke.* 2000;31:1274-82.
4. Wasay M, Bakshi R, Bobustuc G, Kojan S, Sheikh Z, Dai A, et al. Cerebral venous thrombosis: analysis of a multicenter cohort from the United States. *J Stroke Cerebrovasc Dis.* 2008;17(2):49-54.
5. Lanska DJ, Kryscio RJ. Peripartum stroke and intracranial venous thrombosis in the National Hospital Discharge Survey. *Obstet Gynecol.* 1997;89(3):413-8.
6. de Freitas GR, Bogousslavsky J. Risk factors of cerebral vein and sinus thrombosis. In: *Handbook on Cerebral Venous Thrombosis.* Karger Publishers; 2008;23:23-54.
7. Dentali F, Crowther M, Ageno W. Thrombophilic abnormalities, oral contraceptives, and risk of cerebral vein thrombosis: a meta-analysis. *Blood.* 2006;107:2766-73.
8. Saposnik G, Barinagarrementeria F, Brown RD, Bushnell CD, Cucchiara B, Cushman M, et al. Diagnosis and management of CVT (AHA/American stroke association scientific statement) *Stroke* April 2011;STR-0b013e31820a8364.
9. Digre KB. Headaches during pregnancy. *Clin obstet Gynecol.* 2013;56:317.
10. McCaulley JA, Pates JA. Postpartum cerebral venous thrombosis. *Obstet Gynecol.* 2011;118(2):423-5.
11. Mehraein S, Ortwein H, Busch M. Risk of recurrence of cerebral venous and sinus thrombosis during subsequent pregnancy and puerperium. *J Neurol Neurosurg Psychiatry.* 2003;74:814.

Cite this article as: Singh A, Singh S, Vardhan S. A rare case of post-partum cerebral venous sinus thrombosis. *Int J Reprod Contracept Obstet Gynecol* 2018;7:762-5.