

**High dose steroid and acute visual loss: case report and discussion on acute central serous chorioretinopathy in elderly**

Ayesha M. Zain, Norshamsiah M. Din, M. Mushawiahti\*

Department of  
Ophthalmology, Universiti  
Kebangsaan Malaysia Medical  
Centre, Kuala Lumpur,  
Malaysia

**Received:** 08 September 2015**Accepted:** 21 October 2015**\*Correspondence to:**

Dr. M. Mushawiahti

Email: drmusha@gmail.com

**Copyright:** © the author(s), publisher and licensee Medip Academy. This is an open-access article distributed under the terms of the Creative Commons Attribution Non-Commercial License, which permits unrestricted non-commercial use, distribution, and reproduction in any medium, provided the original work is properly cited.

**ABSTRACT**

Central serous chorioretinopathy (CSCR) is one of sight-threatening side effects of systemic steroids. Although it is uncommon, CSCR seriously threatens the patient's vision and it has the potential for permanent visual morbidity. This article reports about a 54-year-old Malay gentleman who developed central vision loss after received a course of oral prednisolone 50 mg/day for a month period for the treatment of multifocal motor neuropathy. His vision recovered 1 year after cessation of steroid as the CSCR resolved. However, subjectively the visual quality is poor. Steroids in any route of administration can induce CSCR and it must be used with precaution especially in the elderly. Although resolutions are usually spontaneous after cessation of steroid, chronic and recurrent CSCR can lead to irreversible visual impairment. Judicious use of systemic steroids, early detection and prompt co-management with the treating physician can help prevent permanent visual disturbance.

**Keywords:** Central serous chorioretinopathy, Steroids, Retinal detachment**INTRODUCTION**

Oral steroids are widely used in the treatment of immune-mediated diseases and are often prescribed for a long period of time. The common side effects of systemic steroids include osteoporosis, suppression of the hypothalamus-pituitary-adrenal axis, weight gain, and hyperglycemia.<sup>1</sup> Ocular complications are also common and include glaucoma, cataract, reactivation of viral infection and central serous chorioretinopathy (CSCR), which is the least common side effect. CSCR is a condition that seriously threatens the patient's vision, and it has the potential for long-term morbidity. Various routes of corticosteroid administration, including intravenous, oral, intranasal, epidural and topical application, have been associated with CSCR.<sup>2</sup>

Non-steroid-related idiopathic CSCR is commonly encountered by ophthalmologists, but steroid-induced CSCR is less frequent. The incidence of CSCR in Cushing

syndrome was reported to be 5%, which is higher than the incidence of idiopathic CSCR.<sup>3</sup> Idiopathic CSCR commonly occurs in young men and is frequently related to stress hormones, whereas CSCR in the elderly is usually related to secondary causes.<sup>4</sup> Due to its rare incidence, steroid-induced CSCR is often reported as a single case report, and very few case series have been reported so far.<sup>5</sup>

CSCR is a retinal disease characterized by detachment of the neurosensory retina from the retinal pigment epithelial (RPE) layer. A circumscribed area of retinal detachment is formed in the macula as a result of the accumulation of subretinal fluid in the macular region.<sup>6</sup> Single episodes of idiopathic acute CSCR resolve spontaneously with the restoration of normal vision. However, in chronic and recurrent CSCR, there is a high-risk for permanent damage to the RPE, causing residual reduction in contrast sensitivity, persistent metamorphopsia (distorted images), central visual scotoma, and mild color vision defect.<sup>7</sup>

This article reports a case of secondary CSCR in an elderly patient who had residual visual disturbance even after the resolution of CSCR.

## CASE REPORT

A 54-year-old man presented to the neurology clinic with a history of recurrent episodes of limb weakness. He was diagnosed with recurrent multifocal motor neuropathy (MMN). His symptoms improved with every cycle of intravenous immunoglobulin (IVIG) treatment. However, due to the high cost of the IVIG treatment, during his most recent relapse, he was given oral prednisolone at a dosage of 50 mg daily for 1 month. After 1 month of using the high-dose steroid, he complained of sudden blurring of vision in the left eye for 2 weeks. He was therefore referred to the ophthalmology clinic for assessment. According to the patient, his central vision was most affected. Metamorphopsia, which is commonly described as distortion of images, is a typical presentation in patients with macular disease; however, this was not observed in our patient.

His best-corrected visual acuity was 6/60 for the left eye and 6/9 for the right eye. Pupillary light reaction was normal. The cornea appeared normal, and cataract was not present. Intraocular pressure was also normal in both eyes. Examination of the macula revealed the presence of a large central serous retinal detachment commonly known as CSCR, which involved almost the entire macula; it was three times the diameter of the optic disc (approximately 4.5 mm). The optic discs and retinal vessels appeared normal otherwise (Figure 1). Features of autoimmune involvement such as vasculitis and alteration of the RPE were not observed. Optical coherent tomography (OCT), revealed a large neurosensory separation in the macular region (Figure 2).

The patient was diagnosed with steroid-induced CSCR of the left eye. After consultation with the physician, the oral prednisolone dose was tapered quickly and discontinued. The patient then underwent another cycle of IVIG for completion of the MMN treatment. The CSCR gradually resolved. However, complete resolution was attained after almost 1 year after cessation of the steroid. The patient's vision improved to 6/9; despite this, the patient subjectively assessed the quality of images seen with his left eye as being poor. This is consistent with the OCT changes documented, which indicated hyporeflective changes at the junction of the inner/outer segment of the photoreceptor layer (Figure 3).

## DISCUSSION

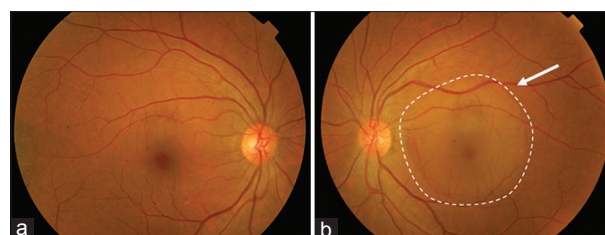
The development of CSCR during steroid treatment of ocular inflammatory diseases or other systemic immune-mediated diseases as described in this case can lead to treatment dilemma. However, steroid-induced CSCR is a rarely reported condition that has serious consequences.<sup>5</sup>

The diagnosis of CSCR is mainly based on clinical findings. However, a recently introduced OCT allows for better imaging of the retinal layers. The latest version of OCT does not only help to describe and quantify changes in the subretinal fluid, but it also helps to demonstrate minute changes in a grossly normal looking retina.<sup>8</sup> In this case, in particular, the abnormal hyporeflective changes observed have not been reported before in other cases of CSCR. Further evaluation of such changes in this particular layer will be highly useful in larger case series.

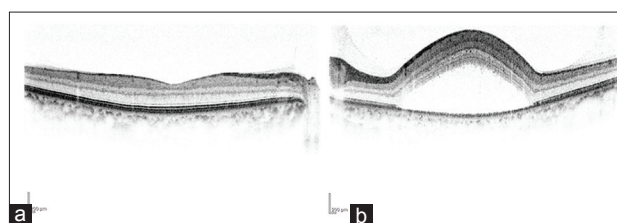
Poor choroidal autoregulation is believed to be associated with CSCR. It is believed that steroids cause impairment of the autonomic function of the choroidal vessels, which leads to focal spasm of the vessels.<sup>9</sup> These changes may lead to focal choroidal ischemia and hypermeability, allowing exudation of plasma protein and fluid separating the retinal layer.<sup>10,11</sup>

The daily dose of steroids has a greater influence on the development of CSCR rather than the cumulative dose.<sup>12</sup> Interestingly, Koyama et al., observed that even a small dose of corticosteroid (5-10 mg/day) may cause CSCR, especially in the elderly.<sup>14</sup>

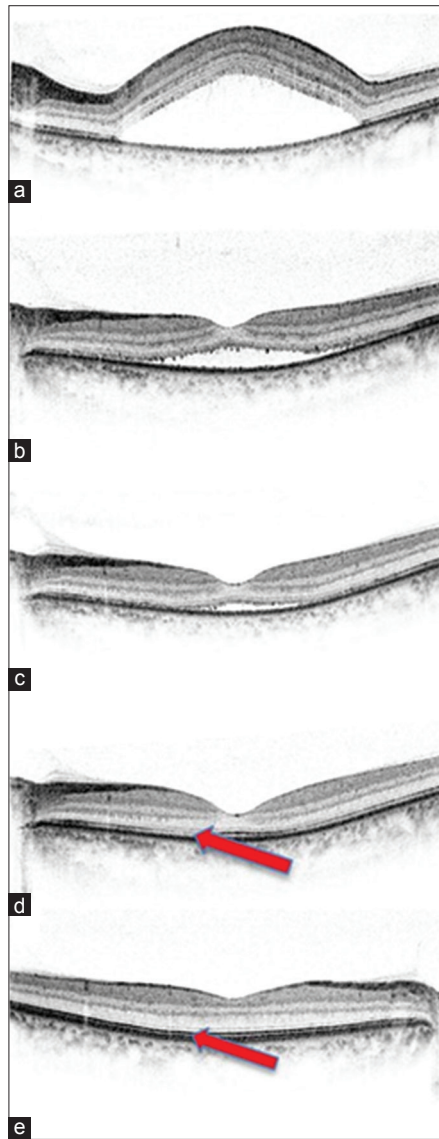
Single episodes of idiopathic CSCR tend to resolve spontaneously after 8 weeks with almost complete recovery of vision.<sup>2</sup> However, chronic separation of the neurosensory layer and delay in the resolution of the causative disease increase the risk of residual damage to the RPE layer.<sup>14</sup> An interesting feature highlighted in this case is the delayed



**Figure 1: (a) Image of the normal fundus (right eye) with good foveal reflex, (b) fundus of the left eye: loss of foveal reflex and presence of a large central serous chorioretinopathy at the macular region (transparent blister-like appearance, [out-lined in dotted line]).**



**Figure 2: Optical coherent tomography images. (a) The right eye showed normal configuration of the retinal layers with normal foveal contour, (b) the left eye showed a large area of detachment of the neurosensory retina from the retinal pigment epithelial.**



**Figure 3: (a-e) Optical coherent tomography images of the left eye. (a) At presentation, (b) 3 months after cessation of the steroid, (c) 10 months after cessation of the steroid, (d) 1 year after cessation of the steroid (despite normalization of the foveal contour, there is evidence of abnormal hyporefective changes [arrow] at the photoreceptor layer compared to the normal right eye (e).**

resorption of subretinal fluid for almost 1 year despite a dramatic improvement in vision within 3 months. Even though clinically the macula appeared normal at 1 year after cessation of the steroid, the cause of the poor quality of vision was only apparent on the OCT images. Therefore, careful monitoring, preferably using OCT, is highly recommended when following up such cases.

This case highlights the importance of assessing ocular side effects in patients prescribed with long-term high-dose steroids. A simple evaluation of visual acuity in patients at risk of developing ocular complications will help to identify such cases. However, diagnosis of CSCR

is not easy using the monocular techniques of the direct ophthalmoscope. Nonetheless, if loss of foveal reflex is found with an ophthalmoscopic examination in a patient on high-dose steroids, it should be considered as a probable diagnosis of CSCR. Binocular examination using the slit lamp or indirect ophthalmoscope will clearly delineate the elevated lesion.

With regard to ophthalmologists, steroids as the causative factor need to be ruled out before the patient is diagnosed with idiopathic CSCR. It is, therefore, important to obtain a detailed history to rule out secondary causes of CSCR, as patients do not voluntarily provide information about steroid use.

### CONCLUSION

CSCR is a sight-threatening complication associated with steroid use. Although the visual recovery is generally good, chronic and recurrent CSCR may cause significant permanent visual loss. Therefore, judicious use of corticosteroids and monitoring of its adverse effects are important, especially in the elderly patients. Early detection and prompt co-management with the treating physician can help prevent chronic changes and permanent visual damage.

*Funding: No funding sources*

*Conflict of interest: None declared*

*Ethical approval: The study was approved by the Institutional Ethics Committee*

### REFERENCES

1. Liu D, Ahmet A, Ward L, Krishnamoorthy P, Mandelcorn ED, Leigh R, et al. A practical guide to the monitoring and management of the complications of systemic corticosteroid therapy. *Allergy Asthma Clin Immunol.* 2013;9(1):30.
2. Nicholson B, Noble J, Forooghian F, Meyerle C. Central serous chorioretinopathy: update on pathophysiology and treatment. *Surv Ophthalmol.* 2013;58(2):103-26.
3. Bouzas EA, Scott MH, Mastorakos G, Chrousos GP, Kaiser-Kupfer MI. Central serous chorioretinopathy in endogenous hypercortisolism. *Arch Ophthalmol.* 1993;111(9):1229-33.
4. Allibhai ZA, Gale JS, Sheidow TS. Central serous chorioretinopathy in a patient taking sildenafil citrate. *Ophthalmic Surg Lasers Imaging.* 2004;35(2):165-7.
5. Hardwig PW, Silva AO, Pulido JS. Forgotten exogenous corticosteroid as a cause of central serous chorioretinopathy. *Clin Ophthalmol.* 2008;2(1):199-201.
6. Bouzas EA, Karadimas P, Pournaras CJ. Central serous chorioretinopathy and glucocorticoids. *Surv Ophthalmol.* 2002;47(5):431-48.
7. Wang M, Munch IC, Hasler PW, Prunte C, Larsen M. Central serous chorioretinopathy. *Acta Ophthalmol.* 2008;86(2):126-45.
8. Teke MY, Elgin U, Nalcacioglu-Yuksekkaya P, Sen E, Ozdal P, Ozturk F. Comparison of autofluorescence and optical coherence tomography findings in acute and chronic central serous chorioretinopathy. *Int J Ophthalmol.* 2014;7(2):350-4.

9. Tewari HK, Gadia R, Kumar D, Venkatesh P, Garg SP. Sympathetic-parasympathetic activity and reactivity in central serous chorioretinopathy: a case-control study. *Invest Ophthalmol Vis Sci.* 2006;47(8):3474-8.
10. Spitznas M. Pathogenesis of central serous retinopathy: a new working hypothesis. *Graefes Arch Clin Exp Ophthalmol.* 1986;224(4):321-4.
11. Marmor MF. New hypotheses on the pathogenesis and treatment of serous retinal detachment. *Graefes Arch Clin Exp Ophthalmol.* 1988;226(6):548-52.
12. Wakakura M, Song E, Ishikawa S. Corticosteroid-induced central serous chorioretinopathy. *Jpn J Ophthalmol.* 1997;41(3):180-5.
13. Koyama M, Mizota A, Igarashi Y, Adachi-Utsami E. Seventeen cases of central serous chorioretinopathy associated with systemic corticosteroid therapy. *Ophthalmologica.* 2004;218(2):107-10.
14. Kitzmann AS, Pulido JS, Diehl NN, Hodge DO, Burke JP. The incidence of central serous chorioretinopathy in Olmsted County, Minnesota, 1980-2002. *Ophthalmology.* 2008;115(1):169-73.

**Cite this article as:** Zain AM, Norshamsiah MD, Mushawiahti M. High dose steroid and acute visual loss: case report and discussion on acute central serous chorioretinopathy in elderly. *Int J Basic Clin Pharmacol* 2015;4:1305-8.