

Evaluation of the effects of *Aegle marmelos* and *Punica granatum* in an experimental model of gastrointestinal barrier dysfunction

Harshveer Singh M. Malhi, Sandhya K. Kamat*, Akash R. Deogharkar, Nirmala N. Rege

Department of Pharmacology and Therapeutics, Seth G.S. Medical College and KEM Hospital, Mumbai, India

Received: 10 September 2016

Accepted: 16 September 2016

***Correspondence to:**

Dr. Sandhya K. Kamat,
Email: drsandhyakamat@gmail.com

Copyright: © the author(s), publisher and licensee Medip Academy. This is an open-access article distributed under the terms of the Creative Commons Attribution Non-Commercial License, which permits unrestricted non-commercial use, distribution, and reproduction in any medium, provided the original work is properly cited.

ABSTRACT

Background: The study was conducted to evaluate the effects of *Aegle marmelos* and *Punica granatum* in an experimental model of gastrointestinal barrier dysfunction induced by common bile duct ligation.

Methods: Institutional animal ethics committee approval was obtained. Forty two Wistar rats (either sex, 150-250 gms) divided into seven groups (n=six/group), were subjected to sham operation (group 1) or bile duct ligation (groups 2-7) and treated with distilled water (groups 1 and 2); 0.75mg/kg glutamine (group 3); 0.27 g/kg and 0.54 g/kg of *A. marmelos* (groups 4 and 5); 3.6 g/kg and 7.2 g/kg *P. granatum* (groups 6 and 7) orally once daily for 10 days. On Day 11, animals were sacrificed and samples of the jejunum, ileum and mesenteric lymph nodes were obtained to study jejunal and ileal villous morphology, villous heights, jejunal mucosal sucrase enzyme activity and bacterial translocation to mesenteric lymph nodes.

Results: Glutamine prevented blunting of the intestinal villi, bacterial translocation and a fall in the sucrase enzyme activity. Both the plant drugs prevented blunting of the villi (except low dose *A. marmelos* for ileal villi) and a fall in the villous heights (except low dose *P. granatum* for jejunal villi), decreased the bacterial translocation (except low dose *A. marmelos*), and prevented a fall in the sucrase enzyme activity when compared to the disease control. The high doses of both *A. marmelos* and *P. granatum* were comparable to glutamine for all the variables tested.

Conclusions: Both *A. marmelos* and *P. granatum* maintained the gastrointestinal barrier function in this model.

Keywords: Bacterial translocation, Obstructive jaundice, Disaccharidase, Sucrose, Villi

INTRODUCTION

The gut barrier is a selective barrier that serves two critical functions: first it allows the passage of selective solutes that are beneficial to the host and second it prevents harmful luminal entities such as microorganisms, antigens, and pro-inflammatory factors from entering into the systemic circulation. Thus it serves as the first line of defence against a hostile environment within the intestinal lumen and helps in maintaining the health of an individual.¹

Several factors such as modifications in the enteric microflora, alterations in the mucosal layer, and damage to the epithelium can alter the functioning of the gut barrier and increase intestinal permeability, allowing the

luminal contents to traverse the inner layer of intestinal wall.² An association between intestinal barrier dysfunction and the development of a wide range of diseases is now established. Gut barrier failure has been found to occur in gastrointestinal disorders such as inflammatory bowel disease, celiac disease, irritable bowel syndrome, in collagen vascular disorders, dermatological disorders, critical illness, alcoholic liver disease and obstructive jaundice, and in obesity and associated metabolic diseases such as non-alcoholic fatty liver disease, diabetes mellitus.^{3,4}

A variety of agents have been evaluated in both experimental as well as clinical studies for the treatment of gut barrier failure and have been found to modulate the intestinal permeability. Among these, corticosteroids, anti

TNF- α , 5-aminosalicylic acid, gelatin tannate, glutamine, prebiotics and probiotics have shown promising results.^{4,5} However, no drug has succeeded convincingly to be included as the standard of care in the treatment of gut barrier failure. The limited efficacy of currently available drugs warrants the search for newer agents that restore barrier normality and integrity.

Ayurveda, our traditional system of medicine, describes certain plants as having 'Balya' property meaning that they offer strength to the tissue or increase its resistance against any onslaught of disease. *Aegle marmelos* (Linn.) known as 'bael' and *Punica granatum* (Linn.) known as 'anar', are two such plant drugs used in Ayurveda for the treatment of diarrhea and various gastrointestinal disorders.⁶ The unripe fruit of *A. marmelos* and the fruit rind of *P. granatum* have been studied by researchers for the prevention of diarrhoeal disorders.^{7,8} However no scientific reports demonstrating the effect of these agents on the gastrointestinal barrier are available. We therefore planned the current study to investigate the effects of *A. marmelos* and *P. granatum* in an experimental model of gastrointestinal barrier dysfunction. The animal model of obstructive jaundice induced by common bile duct ligation was used as it is widely used to study the effects of drugs on the intestinal mucosal barrier. Glutamine, a non-essential amino acid and a primary fuel source for enterocytes was used as the comparator as it has shown beneficial effects on the gut barrier in several experimental and clinical studies.⁹

METHODS

Drugs and chemicals

Authenticated aqueous extracts of the unripe fruit of *A. marmelos* (extractive value 17%) and the fruit rind of *P. granatum* (extractive value 8%) were used for the study and were procured from natural remedies, Bengaluru. The doses for *A. Marmelos* (0.27 and 0.54 g/kg) and *P. Granatum* (3.6 and 7.2 g/kg) were extrapolated from the doses used in ayurveda.⁶ Glutamine (Spectrochem Pvt. Ltd, India) was used in the dose of 0.75 g/kg.¹⁰ McConkey's broth and agar were purchased from HiMedia Ltd., India and glucose reagent was purchased from Transasia Bio-Medicals Ltd, India.

Animals

Adult wistar rats (n=42) of either sex weighing 150-200g were used for the study and procured from the centre for animal studies of the Seth GS Medical College and KEM Hospital, Mumbai, India. The rats were housed in polypropylene cages with paddy husk as bedding and maintained under standard conditions (Temp: 22 \pm 2^oC; Relative humidity: 50-70%; 12 hour light/dark cycles). They were fed standard rodent pellet feed (chakan oil mills, Maharashtra, India) and filtered and ultra-violet purified water was provided ad libitum. The study was approved by the Institutional animal ethics committee

and all experimental procedures were performed in accordance with the guidelines laid down by the committee for the purpose of control and supervision of experiments on animals (CPCSEA).

Experimental procedure

The forty two rats were randomly allocated to 7 groups of 6 rats each. On day 0, the rats were anaesthetized with an intramuscular injection of 70 mg/kg of ketamine hydrochloride and 5 mg/kg of xylazine and midline laparotomies were performed under sterile conditions. In group 1 (sham operated), the common bile duct was identified, freed from the surrounding soft tissue and manipulated without carrying out ligation and transection. In groups 2-7, the common bile duct was dissected and double-ligated with 6/0 silk and sectioned between the ligatures according to the procedure described by Lee et al.¹¹ All abdominal incisions were closed in 2 layers using 4/0 chromic catgut. After surgery, the rats were allowed to recover from anaesthesia following which each rat was housed in an individual cage with free access to food and water. Rats in all the groups were treated with the vehicle or study drugs orally once daily from day 1 to day 10 as follows: Group 1 (sham control) and group 2 (disease control) received distilled water, group 3 received glutamine (0.75 g/kg), groups 4 and 5 received the lower (0.27 g/kg) and higher (0.54 g/kg) doses of *A. marmelos* respectively and groups 6 and 7 received the lower (3.6 g/kg) and higher (7.2 g/kg) doses of *P. granatum* respectively. Following drug administration on day 10, the rats were kept fasting for 24 hours and on day 11 they were sacrificed by giving a high dose of ketamine (100mg/kg). Samples of the jejunum, ileum and the mesenteric lymph nodes, were obtained for assessment of the following variables.

Villous morphology and villous heights

Tissue samples from the proximal jejunum and terminal ileum were obtained from all animals. Before taking the sample, the intestinal lumen was carefully cannulated and gently washed in normal saline with help of a pipette taking care to avoid any mucosal damage. The samples were fixed in 10% neutral formalin, embedded in paraffin and stained with haematoxylin eosin. For the morphometric analysis, the mucosal regions of the jejunum and ileum of each rat were traced using a light microscope with a magnification of 10X and the morphology of 20 well-preserved villi/slide/rat was observed. The villi were classified according to Lee and Toner's classification into finger-like villi, leaf-like villi, blunted/ ridged villi.¹² The number of villi belonging to each class was calculated. In addition, the heights of 20 well-preserved villi/slide/rat were measured using a trinocular microscope with an image analyzer Image-Pro® Plus Version 6.2 for Windows™ (Media Cybernetics, MA, USA) and the mean villous height was calculated.

Bacterial translocation

The mesenteric lymph nodes were excised under aseptic conditions and transferred to 5 ml sterile McConkey's broth. The tissues were homogenized under sterile conditions and the homogenates were inoculated on McConkey's agar plates. The plates were incubated at 37°C for 24 hours and examined for bacterial growth.

Intestinal mucosal sucrase enzyme activity

The sucrose enzyme activity of jejunum was assessed by the method described by Dhalqvist et al.¹³ In brief, 20 cm of jejunum was dissected and the mucosa was scraped off and weighed. The mucosal homogenates were centrifuged and the supernatants were diluted with distilled water. 100 µl of the homogenate was incubated with 0.056 M sucrose maleate buffer in a water bath at 37°C for 1h. Following this, the homogenate was immediately transferred to a boiling water bath for 2 min to denature the remaining disaccharidases. The test tubes were cooled and incubated with glucose oxidase reagent. The concentration of glucose was determined spectrophotometrically to estimate the sucrase enzyme activity which was expressed as IU/g of mucosa.

Statistical analysis

Statistical analysis was performed using the Graphpad Instat version 3.06 for Windows. A value of $p < 0.05$ was considered to be statistically significant. For bacterial translocation, Fisher's exact test was used. Villous morphology was evaluated using Chi square test. Villous heights and sucrase enzyme activity and were analysed using One way ANOVA followed by post-hoc Tukey's test.

RESULTS

Villous morphology: Jejunum and ileum

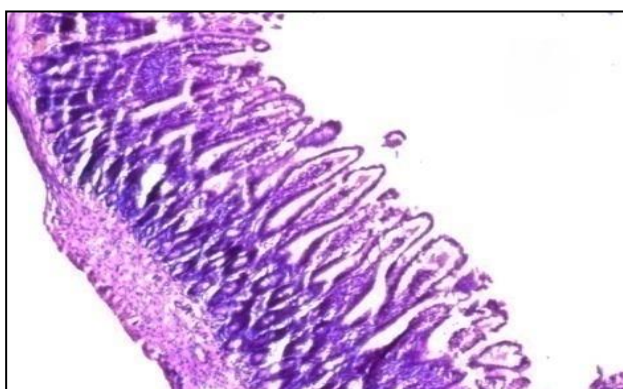


Figure 1a: Villous morphology (jejunum) in the sham control groups (10X).

The disease control animals showed a significant increase in the number of blunted or ridged villi in the jejunum and

ileum ($p < 0.05$) as compared to the sham control animals (Table 1). Glutamine and both the doses of the two plant drugs significantly prevented the blunting of villi in the jejunum ($p < 0.001$) as compared to the disease control groups (Figure 1a-g). Similar results were seen in the ileum wherein glutamine and the plant drugs (except the low dose of *A. marmelos*) prevented the blunting of villi ($p < 0.05$). No significant difference was observed between glutamine and the plant-drug treated groups (Table 1).

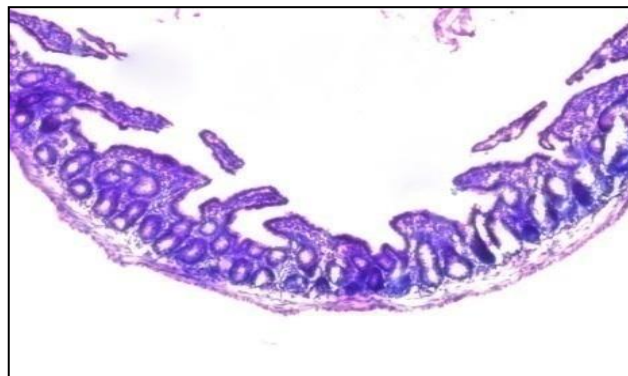


Figure 1b: Villous morphology (jejunum) in the disease control group (10X).

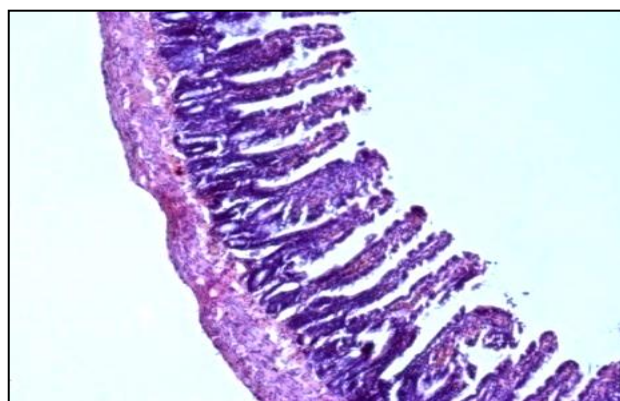


Figure 1c: Villous morphology (jejunum) in the glutamine-0.75 mg/kg/day group (10X).

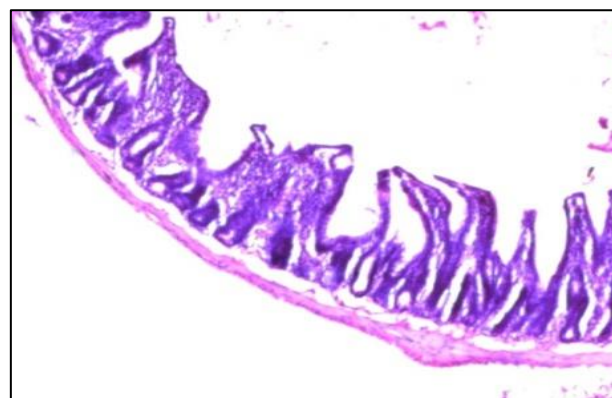


Figure 1d: Villous morphology (jejunum) in the *Aegle marmelos*-0.27 g/kg/day group (10X).

Table 1: Villous morphology in the various experimental groups.

Groups	Treatment (p. o)	Jejunum			Ileum		
		F	L	B/R	F	L	B/R
1	Sham control (distilled water)	83	27	10	76	25	19
2	Disease control (distilled water)	46 [#]	24	50 [#]	57 [#]	25	38 [#]
3	Glutamine (0.75mg/kg/day)	67*	31	22**	71	33	16*
4	<i>A. marmelos</i> (0.27 g/kg/day)	46	49*	25**	47	46*	27
5	<i>A. marmelos</i> (0.54 g/kg/day)	71*	30	19**	70	32	18*
6	<i>P. granatum</i> (3.6 g/kg/day)	68*	29	23**	69	36	15*
7	<i>P. granatum</i> (7.2 g/kg/day)	80**	27	13**	66	43*	11**

F: Finger-like villi, L: Leaf-like villi, B/R: Blunted/ridged villi.; p.o: per oral; Results expressed as number of villi out of 120 villi per group (n=20 jejunal/ileal villi per rat); [#] p < 0.05 vs. sham control; * p < 0.05, **p < 0.001 vs. disease control using the Chi square test

Villous heights: jejunum and ileum

The mean heights of jejunal and ileal villi in the disease control animals were significantly less as compared to heights of villi in the sham control animals (Table 2). Administration of glutamine significantly prevented the decrease in jejunal villous height (p < 0.001). Both the lower (p < 0.05) as well as the higher dose (p < 0.001) of *A. marmelos* significantly prevented the decrease in jejunal villous height in a dose dependent manner. However, only the higher dose of *P. granatum*

significantly prevented the decrease in the jejunal villous height (p < 0.001). When the effect on ileal villous heights was observed it was found that both the doses of the two plant drugs protected against the decrease in ileal villous heights. The jejunal and ileal villous heights of groups receiving the higher doses of *Aegle marmelos* and *Punica granatum* were not significant when compared to glutamine whereas the villous heights of the animals receiving lower doses of both the plant drugs were significantly less than that observed with glutamine (Table 2).

Table 2: Villous heights in the various experimental groups.

Groups	Treatment (p.o)	Villous heights (µm)	
		Jejunum	Ileum
1	Sham control (distilled water)	506.23±121.31	453.68±106.34
2	Disease control (distilled water)	357.07±130.30 [#]	251.10±109.01 [#]
3	Glutamine (0.75 mg/kg/day)	494.68±168.02**	430.78±161.79**
4	<i>A. marmelos</i> (0.27 g/kg/day)	416.82±133.61 [@]	325.19±125.78 [@]
5	<i>A. marmelos</i> (0.54 g/kg/day)	457.08±138.21**	396.24±132.66**
6	<i>P. granatum</i> (3.6 g/kg/day)	403.93±144.71 [@]	341.01±101.57 [@]
7	<i>P. granatum</i> (7.2 g/kg/day)	459.52±134.08**	429.04±96.82**

Results expressed as Mean±S.D. of 120 villi per group (n=20 jejunal/ileal villi per rat); p.o.: per oral; [#] p < 0.001 vs. sham control; * p < 0.05, **p < 0.001 vs. disease control; [@] p < 0.001 vs. glutamine using One way ANOVA with post hoc Tukey's test

Table 3: Bacterial translocation to the mesenteric lymph nodes and jejunal sucrase enzyme activity in the experimental groups.

Groups (n = 6/gp)	Treatment (p.o.)	Incidence of bacterial translocation	Sucrase enzyme activity in jejunum (IU/g of mucosa)
1	Sham control (Distilled water)	0 / 6	5.89±0.69
2	Disease control (Distilled water)	5 / 6 [#]	2.94±0.80 [#]
3	Glutamine (0.75mg/kg/day)	0 / 6 [*]	5.75±0.61 ^{**}
4	<i>Aegle marmelos</i> (0.27 g/kg/day)	2 / 6 ^{NS, NS1}	3.95±0.38 [@]
5	<i>Aegle marmelos</i> (0.54 g/kg/day)	1 / 6 ^{*, NS1}	5.12±0.26 ^{** NS2}
6	<i>Punica granatum</i> (3.6 g/kg/day)	1 / 6 ^{*, NS1}	3.87±0.28 [@]
7	<i>Punica granatum</i> (7.2 g/kg/day)	1 / 6 ^{*, NS1}	4.96±0.34 ^{** NS2}

Bacterial translocation: Numerator in each ratio represents the number in which translocation occurred out of the entire group; p.o: per oral; [#] p<0.05 vs. sham control; * p<0.05, NS - Not significant vs. disease control; NS1 - Not significant vs. Glutamine using Fisher's exact test. **Results expressed as mean±S.D. for sucrase enzyme activity;** [#] p < 0.001 versus Sham Control; *p < 0.05, **p < 0.001 vs. disease control; [@] p < 0.001, NS2 – Not significant vs. glutamine using one way ANOVA with post hoc Tukey's test.

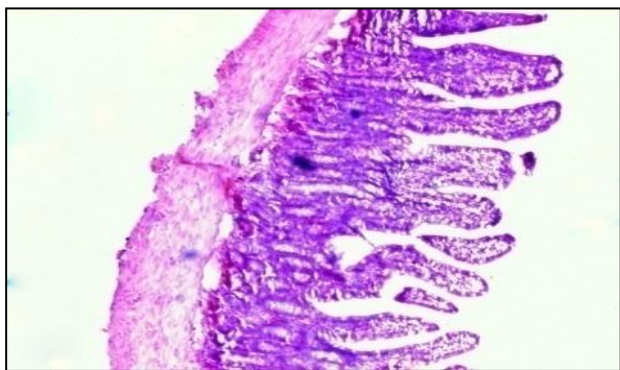


Figure 1e: Villous morphology (jejunum) in the Aegle marmelos-0.54 g/kg/day group (10X).

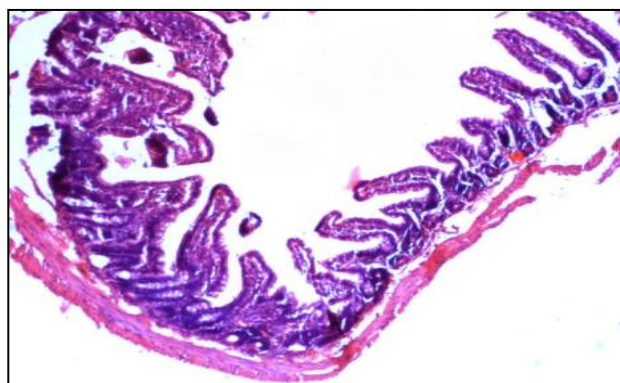


Figure 1f: Villous morphology (jejunum) in the Punica granatum-3.6 g/kg/day group (10X).

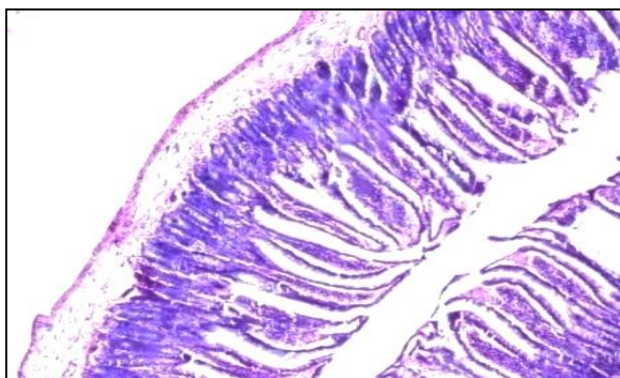


Figure 1g: Villous morphology (jejunum) in the Punica granatum-7.2 g/kg/day group (10X).

Bacterial translocation

The results of bacterial translocation are summarized in Table 3, none of the sham control rats showed bacterial translocation whereas bacterial translocation was recorded in 5/6 rats in the disease control group. Glutamine prevented the bacterial translocation to the mesenteric lymph nodes ($p < 0.05$). Both the doses of *Punica granatum* and the high dose of *Aegle marmelos* significantly decreased the translocation of bacteria ($p < 0.05$) as compared to the disease control group. When

compared to glutamine the decrease in translocation was not significant.

Intestinal mucosal sucrase enzyme activity

The jejunal sucrase enzyme activity in group 2 animals (disease control) was significantly less ($p < 0.001$) than that of animals in group 1 (Table 3). The fall in the enzyme activity was prevented by glutamine and high doses of both the plant drugs ($p < 0.001$) and their low doses ($p < 0.05$). The enzyme activity observed with the higher doses of *Aegle marmelos* and *Punica granatum* was not found to be significantly different as compared to glutamine while the enzyme activity seen with the lower doses of both the plants drugs was significantly less than that observed with glutamine.

DISCUSSION

The present study was conducted to evaluate whether the aqueous extracts of the unripe fruit of *A. marmelos* and fruit rind of *P. granatum* protected against intestinal mucosal barrier disruption in rats with bile duct ligation. The variables selected were intestinal villous morphology including villous heights, bacterial translocation and intestinal mucosal sucrase enzyme activity.

Bile has a trophic effect on the intestinal mucosa and absence of intraluminal bile leads to intestinal mucosal atrophy.¹⁴ Hence various researchers have assessed villous morphology including villous heights to evaluate the effect of the test drugs in the model of common bile duct ligation.^{15,16} In our study, *A. marmelos* and *P. granatum* significantly prevented the blunting of villi and maintained the villous heights and the higher doses were comparable to glutamine. The exact mechanism by which *A. marmelos* and *P. granatum* prevented the damage to the intestinal mucosa is not known. It has been reported that the intestinal cell damage induced by bile duct ligation occurs due to lipid peroxidation and hence it is possible that the antioxidants present in the plant drugs are responsible for the protective effect.¹⁷ Das et al have demonstrated the antioxidant property of *A. marmelos* in an experimental study of aspirin-induced gastroduodenal ulcers and have attributed the protection to the vitamin E, β -carotene, flavanols and flavonoids in the *A. marmelos* extract.¹⁸ Similarly, phenolics extracted from the peel of *P. granatum* have been reported to exhibit a potent antioxidant activity.¹⁹ The gallic acid present in *P. granatum*, may also play a part in the regeneration of the intestinal epithelium. Murthy et al have reported that the epithelial cells from the excision wound of skin are stimulated by the methanolic extract of *P. granatum* which contain high levels of gallic acid.²⁰

Bacterial translocation is the migration of bacteria from the intestinal lumen to extraintestinal sites. The identification of intestinal bacteria in the normally sterile mesenteric lymph nodes is a direct evidence of bacterial translocation and a marker of the loss of gut integrity.

Mechanisms that promote bacterial translocation are bacterial overgrowth in the small intestine, deficiencies in host immune defences and damage to the intestinal mucosa.²¹ The higher dose of *A. marmelos* and both the doses of *P. granatum* prevented BT to the mesenteric lymph nodes and were comparable to glutamine. Brijesh et al have studied the antidiarrhoeal activity of *A. marmelos* and have suggested that its antimicrobial activity is due to the presence of tannins and flavonoids.⁷ The *in-vitro* bactericidal activity of *P. granatum* peels has been reported by several researchers.^{22,23} Clinical trials have also been conducted with *P. granatum* extracts but have mainly focused on oral bacteria.²⁴ It is possible that the antimicrobial activity of the plant drugs prevented the overgrowth of enteric bacteria thereby reducing the bacterial translocation. However, in the present study, since the intestinal microbial content was not assessed, we could not determine whether it was the antimicrobial activity of the plant drugs that caused a reduction in bacterial translocation. Thus, the protective effects of the plants on the intestinal mucosa as well as their antimicrobial effects may have played a part in decreasing the bacterial translocation.

The intestinal mucosal disaccharidase activity represents the functional ability of the intestinal villi for carbohydrate digestion. Damage to the intestinal morphology such as that due to intestinal reperfusion causes a decrease in the intestinal disaccharidase activity injury.²⁵ Although our literature search did not reveal any study wherein the disaccharidase levels were assessed in obstructive jaundice, we felt it would be interesting to measure the jejunal mucosal sucrase levels, as an objective means to study the effect of the plant drugs. In our study, both the doses of *A. marmelos* and *P. granatum* averted the fall in sucrase levels caused by bile duct ligation but only the higher doses were comparable to glutamine. A decrease in disaccharidase activity has also been reported due to infections.²⁶ Thus, prevention of the fall in sucrase activity, observed with the plant drugs can be ascribed not only to the fact that they preserved the overall morphology of intestinal villi but also to their antimicrobial activity. No study has measured the intestinal sucrase levels in a model of bile duct ligation and hence we could not compare our results to other studies.

To conclude, the effects of both *A. marmelos* and *P. granatum* observed in this preliminary study point out to the potential of these plants in maintaining the gastrointestinal barrier function. One of the strengths of this study is that the objective variables used by us to study the effects of these plant drugs, have not been used by the other researchers who have evaluated these plants. However, further studies need to be carried out to determine the exact mechanism/s of action of the plant drugs as also the active constituent/s which are responsible for strengthening of the gastrointestinal barrier. As mentioned earlier, various other researchers in studies to gut barrier dysfunction have shown that these

plant drugs have stimulatory effects on the epithelial cell growth, antioxidant activity and possess antimicrobial effects. How these effects contribute to the maintenance of gut barrier structure and function in the model of bile duct ligation remains to be investigated.

ACKNOWLEDGMENTS

Authors are grateful to the following members of the Department of Pharmacology and Therapeutics, Seth GS Medical College and KEM Hospital: Dr. Dinesh Uchil, Scientific Officer, who provided insight and expertise that greatly assisted the research and Dr. Sanket Raut, Assistant Professor, for critically reviewing the article.

Funding: No funding sources

Conflict of interest: None declared

Ethical approval: The study was approved by the Institutional Ethics Committee

REFERENCES

1. Blikslager AT, Moeser AJ, Gookin JL, Jones SL, Odle J. Restoration of barrier function in injured intestinal mucosa. *Physio Rev.* 2007;87(2):545-64.
2. Lopetuso LR, Scaldaferrri F, Bruno G, Petito V, Franceschi F, Gasbarrini A. The therapeutic management of gut barrier leaking: the emerging role for mucosal barrier protectors. *Eur Rev Med Pharmacol Sci.* 2015;19(6):1068-76.
3. Farhadi A, Banan A, Fields J, Keshavarzian A. Intestinal barrier: an interface between health and disease. *J Gastroenterol Hepatol.* 2003;18(5):479-97.
4. Bischoff SC, Barbara G, Buurman W, Ockhuizen T, Schulzke JD, Serino M, et al. Intestinal permeability a new target for disease prevention and therapy. *BMC gastroenterology.* 2014;14(1):1.
5. Scaldaferrri F, Pizzoferrato M, Gerardi V, Lopetuso L, Gasbarrini A. The gut barrier: new acquisitions and therapeutic approaches. *J Clin Gastroenterol.* 2012;46:12-7.
6. Gogte VM. Medicinal Plants. In: *Ayurvedic Pharmacology and Therapeutic Uses of Medicinal Plants (Dravyagunavignyan)*. 1st English edition. Mumbai: Bharatiya Vidya Bhavan; 2000:392-442.
7. Brijesh S, Daswani P, Tetali P, Antia N, Birdi T. Studies on the antidiarrhoeal activity of *Aegle marmelos* unripe fruit: validating its traditional usage. *BMC Complement Altern Med.* 2009;9:47.
8. Qnais EY, Elokda AS, Abu Ghalyun YY, Abdulla FA. Antidiarrheal activity of the aqueous extract of *Punica granatum* (Pomegranate) Peels. *Pharmaceutical Bio.* 2007;45(9):715-20.
9. Wang B, Wu G, Zhou Z, Dai Z, Sun Y, Ji Y, et al. Glutamine and intestinal barrier function. *Amino Acids.* 2015;47(10):2143-54.
10. Xue H, Sawyer MB, Field CJ, Dieleman LA, Murray D, Baracos VE. Bolus oral glutamine protects rats against CPT-11-induced diarrhea and differentially activates cytoprotective mechanisms in

- host intestine but not tumor. J Nutr. 2008;138(4):740-6.
11. Lee E. The effect of obstructive jaundice on the migration of reticulo-endothelial cells and fibroblasts into early experimental granulomata. Br J Surg. 1972;59(11):875-7.
 12. Lee FD, Toner PG. The normal intestinal mucosa. In: Lee FD, Toner PG Eds. Biopsy Pathology of small intestine. London; Champal and Hall: 1977; 19-31.
 13. Dahlqvist A. Assay of intestinal disaccharidases. Anal Biochem. 1968;22(1):99-107.
 14. Perrone EE, Liu L, Turner DJ, Strauch ED. Bile salts increase epithelial cell proliferation through HuR-induced c-Myc expression. J Surg Res. 2012;178(1):155-64.
 15. Gencay C, Kilicoglu SS, Kismet K, Kilicoglu B, Erel S, Muratoglu S, et al. Effect of honey on bacterial translocation and intestinal morphology in obstructive jaundice. World J Gastroenterol. 2008;14(21):3410-5.
 16. Geyik MF, Aldemir M, Hosoglu S, Ayaz C, Satilmis S, Buyukbayram H, et al. The effects of *Saccharomyces boulardii* on bacterial translocation in rats with obstructive jaundice. Ann R Coll Surg Engl. 2006;88(2):176-80.
 17. Assimakopoulos SF, Scopa CD, Vagianos CE. Pathophysiology of increased intestinal permeability in obstructive jaundice. World J Gastroenterol. 2007;13(48):6458-64.
 18. Das SK, Roy C. The protective role of *Aegle marmelos* on aspirin-induced gastro-duodenal ulceration in albino rat model: a possible involvement of antioxidants. Saudi J Gastroenterol. 2012;18(3):188.
 19. Shibani MS, Al MM, Al NS. Antioxidant activity of pomegranate (*Punica granatum* L.) fruit peels. Food Nutrition Sci. 2012;3(7):991.
 20. Murthy K, Reddy V, Veigas J, Murthy U. Study on wound healing activity of *Punica granatum* peel. J Med Food. 2004;7(2):256-9.
 21. Berg RD. Bacterial translocation from the gastrointestinal tract. Trends Microbiol. 1995;3(4):149-54.
 22. Pai V, Chanu TR, Chakraborty R, Raju B, Lobo R, Ballal M. Evaluation of the antimicrobial activity of *Punica granatum* peel against the enteric pathogens: an *in vitro* study. Asian J Plant Sci Res. 2011;1(2):57-62.
 23. Betanzos CG, Montes PY, Fabela HE, Belefant MH, Cancino DJC. Antibacterial activity of fresh pomegranate juice against clinical strains of *Staphylococcus epidermidis*. Food Nutrition Res. 2015;59:27620.
 24. Prasad D, Kunnaiah R. *Punica granatum*: A review on its potential role in treating periodontal disease. J Indian Society Periodontology. 2014;18(4):428.
 25. Varga J, Toth Jr S, Toth S, Tomeckova V, Gregova K, Vesela J. The relationship between morphology and disaccharidase activity in ischemia-reperfusion injured intestine. Acta Biochim Pol. 2012;59(4):631-8.
 26. Mohammadi S, Sagar S. Host Immunity and pathogen strain contribute to intestinal disaccharidase impairment following gut impairment. J Immunol. 2011;187(7):3769-75.

Cite this article as: Malhi HSM, Kamat SK, Deogharkar AR, Rege NN. Evaluation of the effects of *Aegle marmelos* and *Punica granatum* in an experimental model of gastrointestinal barrier dysfunction. Int J Basic Clin Pharmacol 2016;5:1881-7.