

Case report

**Intravenous cyclophosphamide treatment for
systemic lupus erythematosus with severe autonomic disorders
confirmed by head-up tilt table test: A case series**

*Masataka Umeda MD, PhD^{1,2,3}, Hiroaki Kawano MD, PhD⁴, Yushiro Endo MD, PhD¹,
Ayuko Takatani MD¹, Tomohiro Koga MD, PhD¹, Kunihiro Ichinose MD, PhD¹, Hideki
Nakamura MD, PhD¹, Akihiro Mukaino MD, PhD⁵, Osamu Higuchi PhD⁶, Shunya
Nakane MD, PhD⁵, Takahiro Maeda MD PhD³, and Atsushi Kawakami MD, PhD¹

¹Department of Immunology and Rheumatology, Nagasaki University Graduate School
of Biomedical Sciences, 1-7-1 Sakamoto, Nagasaki, Japan

²Medical Education Development Center, Nagasaki University Hospital, 1-7-1
Sakamoto, Nagasaki, Japan

³Department of General Medicine, Nagasaki University Graduate School of Biomedical
Sciences, Nagasaki, Japan

⁴Department of Cardiovascular Medicine, Nagasaki University Graduate School of
Biomedical Sciences, 1-7-1 Sakamoto, Nagasaki, Japan

⁵Department of Molecular Neurology and Therapeutics, Kumamoto University
Hospital, 1 Chome-1-1 Honjo, Chuo Ward, Kumamoto, Japan

⁶Department of Clinical Research, Nagasaki Kawatana Medical Center, 2005-1,
Shimogumigo, Kawatana, Japan

No. of text pages: 15, no. of figures: 2, no. of tables: 0

***Corresponding author:** Dr. Masataka Umeda, Department of Immunology and
Rheumatology, Nagasaki University Graduate School of Biomedical Sciences, 1-7-1
Sakamoto, Nagasaki 852-8501, Japan. Tel.: +81-95-819-7262; Fax: +81-95-849-7270.
Email: masatakau0807@gmail.com

Abstract

Autonomic disorders are common in patients with SLE, but the therapeutic strategy and methods for evaluating the effects of therapy have not been established. We describe the three cases of SLE patients who developed severe autonomic disorders as demonstrated by the head-up tilt table test (HUT). All three patients were treated by intensive immunosuppressive treatments including cyclophosphamide (IVCY); their HUT results all became negative. Our cases suggest that IVCY treatment can be a good therapeutic option for severe autonomic disorders in SLE patients. The HUT is a useful objective method for the diagnosis of and the evaluation of longitudinal therapeutic effects on autonomic disorders in SLE patients with orthostatic intolerance.

Key Words: autonomic disorder, cyclophosphamide, head-up tilt table test, plasmablasts, systemic lupus erythematosus

Introduction

Systemic lupus erythematosus (SLE) is a systemic autoimmune disease caused by a reduction of tolerance to nuclear antigens [1]. Neuropsychiatric lupus (NPSLE) manifestations can affect various nervous systems, and it is associated with a poor prognosis and significantly impaired quality of life [2, 3]. Autonomic disorders are one of the neuropsychiatric syndromes observed in SLE according to the criteria of the American College of Rheumatology 1999 [4]. Over the past few decades, numerous studies have shown that autonomic disorders are common in patients with SLE [5, 6], but the optimal therapeutic approaches and methods for evaluating the effects of therapies for SLE patients with autonomic disorders have not been established. We herein describe the cases of three patients with SLE in whom severe autonomic disorders were objectively confirmed by the head-up tilt table test (HUT), and we describe how intensive immunosuppressive treatments including intravenous cyclophosphamide (IVCY) significantly improved these autonomic disorders.

Case presentation

Patient 1

A 55-year-old female who had been treated for SLE with prednisolone and tacrolimus for 10 months was admitted due to fever, malar rash, persistent headache, orthostatic intolerance, early satiety, and urinary retention as bladder dysfunction. She also had been treated for rheumatoid arthritis with methotrexate for 14 years. She didn't have any conditions which affect autonomic functions (pregnancy, diabetes, uraemia, alcoholism or on medication that influences blood pressure and heart rate). At the time of her admission, anti-nuclear antibodies were positive with a speckled pattern, and anti-

ds DNA antibodies were 55.7 IU/mL. Lupus anticoagulant was positive. Anti- β 2 GPI antibodies, anti-cardiolipin antibody, anti-ribosomal P antibody, and anti-ganglionic acetylcholine receptor (gAChR) antibodies (nearly half of patients with autoimmune autonomic ganglionopathy show the positivity of anti-gAChR antibodies [7]) were all negative. Complements were normal except for C4 (C3 83.7 mg/dL, C4 11.7 mg/dL, CH50 33.1 U/mL). The results of a cerebrospinal fluid (CSF) analysis were normal.

Magnetic resonance imaging (MRI) and single-photon emission computed tomography (SPECT) imaging of the patient's brain did not show any abnormalities suggesting NPSLE. A nerve conduction velocity (NCV) test revealed a decreased amplitude of sensory nerve action potentials and decreased sensory nerve conduction velocity in the left medial plantar nerve. The analysis of the coefficient of variation of the R-R interval (CVR-R) was normal (2.84%). To rule out Parkinson's disease, we performed MIBG (metaiodobenzylguanidine) myocardial scintigraphy and found a normal MIBG accumulation. A heart rate variability (HRV) analysis using 24-hr Holter monitor revealed the sympathetic hypertonia state as the following: the high-frequency (HF) value reflecting parasympathetic functions was 86.85 (age mean \pm standard deviation [SD]: 514.5 ± 99.7) and the low-frequency/high-frequency (LF/HF) ratio reflecting sympathetic functions was 3.47 (age mean \pm SD: 1.39 ± 0.14) (Fig. 1A, left).

The result of a HUT showed neurally mediated syncope (mixed type) (Fig. 1A, left). Based on these results, we speculated that the patient's orthostatic intolerance was caused by autonomic disorder associated with SLE. We initiated treatment with methylprednisolone (mPSL) pulse therapy (1,000 mg/day for 3 days, twice) and then increased the dose of oral prednisolone (15 mg to 40 mg). These treatments were effective against the patient's symptoms including, fever, malar rash, persistent

headache, orthostatic intolerance, early satiety, and urinary retention within 2 weeks. In addition, the HUT result became negative, but the increase in the level of noradrenaline as the response to the tilt was not observed, and the sympathetic hypertonia state in HRV was still observed in another HRV analysis (Fig. 1A, right). The patient's orthostatic intolerance had recovered to a level at which she could perform housekeeping.

However, 3 years after her discharge, the patient was admitted to our hospital again due to an exacerbation of the orthostatic intolerance. At the time of the second admission, the results of testing for complements, anti-dsDNA antibodies, the CSF analysis, and brain MRI were normal. Brain SPECT revealed bilateral hypoperfusion of the parietal lobes. An HRV analysis using 24-hr Holter monitor revealed a decreased HF value and an increased LF/HF ratio again (129.0 and 2.94, respectively) (Fig. 1B, left). The HUT result was similar to the previous test at the patient's 1st admission (Fig. 1B, left).

Based the SPECT results, we speculated that the patient had developed NPSLE, and we administered IVCY treatment (750 mg/month, three times) and mPSL pulse therapy (1,000 mg/day for 3 days, once). The HUT result returned to the normal range again, an increase in noradrenaline as the response to the tilt was recovered, sympathetic hypertonia was resolved in another HRV analysis (Fig. 1B, right). The patient's orthostatic intolerance symptom had also recovered within a month. Hydroxychloroquine was also administered, and the flares of SLE and autonomic disorders have been inhibited for 4 years.

Patient 2

A 23-year-old female who had been treated for SLE and Sjögren's syndrome with prednisolone for 4 years admitted due to fever, malar rash, persistent headache, orthostatic intolerance, and early satiety. She didn't have any conditions which affect autonomic functions. At the time of admission, anti-nuclear antibodies were positive with a speckled pattern, but anti-dsDNA antibodies were negative. Anti-U1 RNP antibodies were 204.8 IU/ml. Anti-gAChR antibodies were negative. Complements were at normal levels. The CSF contained 22 white blood cells/ μ l (Lymphocytes 82%, monocytes 18%). The protein content of the CSF was 83 mg/dl, and the IgG index was 0.63. The IL-6 level of CSF was high (56.0 pg/ml). Brain MRI showed no abnormalities suggesting NPSLE, but SPECT revealed hypoperfusion of the right parietal lobe and the bilateral occipital lobes. The NCV test revealed a decreased amplitude in the left peroneal motor nerve. The analysis of the patient's CVR-R showed a decline (2.12%, the lower limit at her age: 2.46%) and the disappearance of respiratory-induced variations. MIBG myocardial scintigraphy showed normal MIBG accumulation.

The HRV analysis using 24-hr Holter monitor revealed the sympathetic hypertonia state as follows: an HF value was 127.0 (age mean \pm SD: 860.4 ± 207.3) and the LF/HF ratio was 4.87 (age mean \pm SD: 2.84 ± 0.44) (Fig. 2, left). The HUT result (Fig. 1C, left) fulfilled the definition of postural orthostatic tachycardia syndrome (POTS). POTS is defined by a heart rate increase of ≥ 30 beats/min within 10 min of head-up tilt in the absence of orthostatic hypotension; the standing heart rate is often ≥ 120 beats/min [8].

Based on these results, we speculated that the patient had developed NPSLE and that her orthostatic intolerance was caused by autonomic disorder associated with SLE. We initiated treatment with mPSL pulse therapy (1,000 mg/day for 3 days, once) and

then increased the dose of oral prednisolone (7 mg to 20 mg), and we also administered IVCY treatment (750 mg/month, 6 times). These treatments were effective against the patient's symptoms including the malar rash, persistent headache, orthostatic intolerance, and early satiety.

The CSF analysis after treatment showed that the cell count, protein level, and IL-6 level turned to the normal levels. The HUT result also became negative, the increase in noradrenaline as the response to a tilt was recovered, sympathetic hypertonia state was resolved in HRV analysis (Fig. 2, right). The patient's orthostatic intolerance symptom gradually improved 2 months after starting treatment and finally had recovered to a level at which she could return to her job as an office worker. Her early satiety was also improved 1 month after starting treatment. Hydroxychloroquine was also administered, and the flare of SLE and autonomic disorders have been inhibited for 6 years.

Patient 3

A 46-year-old female who had been treated for SLE for 16 years was admitted due to persistent headache, orthostatic intolerance, and early satiety. She didn't have any conditions which affect autonomic functions. At the time of admission, anti-nuclear antibodies were positive with a speckled pattern. Anti-dsDNA antibodies were negative. Anti-U1 RNP antibodies were 35.4 IU/ml. Anti-gAChR antibodies were negative. Complements were at normal levels. The white blood cells in CSF were at a normal level. The protein content of the CSF was 56 mg/dl, and the IgG index was 0.53. The IL-6 level of CSF was high (18.4 pg/ml). NCV testing revealed a decreased amplitude in the left peroneal motor nerve. The analysis of the CVR-R had a normal result. MIBG

myocardial scintigraphy showed normal MIBG accumulation. The HRV analysis using 24-hr Holter monitor revealed the following: HF value at 186.8 (age mean \pm SD: 493.5 ± 79.7) and LF/HF ratio of 4.87 (age mean \pm SD: 2.01 ± 0.19) (Fig. 1D, left). The HUT result indicated POTS (Fig. 3, left).

Based on these results, we speculated that the patient had developed NPSLE and that her orthostatic intolerance was caused by autonomic disorders associated with SLE. We initiated treatment with IVCY (750 mg/month, 6 times) without increasing the dose of corticosteroid because the patient refused to do this. This treatment was effective against the symptoms including persistent headache, orthostatic intolerance, and early satiety. The CSF analysis after treatment showed that the protein and IL-6 values had returned to normal levels. The HUT result became negative, an increase of noradrenaline as the response to a tilt was observed, sympathetic hypertonia state was resolved in HRV analysis (Fig. 3, right). The patient's orthostatic intolerance symptom gradually improved 3 months after starting treatment and finally had recovered to a level at which she could return to her job as a caregiver. Her constipation was also improved 5 months after starting treatment. Hydroxychloroquine was then administered, and the flare of SLE and autonomic disorders have been inhibited for 6 years.

Discussion

Autonomic disorders in SLE show a wide variety of symptoms such as orthostatic hypotension, palpitation, dry/running nose, gastrointestinal symptoms, burning feet, warm/cold extremities, sweating disturbances, bladder dysfunction, and sexual dysfunction [9, 10]. The reported incidence of autonomic disorders in individuals with SLE ranges from 6% to 93% [5, 9, 11, 12]. This broad range may have been

observed because the method of evaluating autonomic disorders is different in each of these studies, and tests for detecting autonomic disorders are relatively uncommon in daily clinical practice for patients with SLE.

Most of the prior investigations reported that autonomic disorders were observed in percentages of SLE patients that are in the range of dozens; therefore autonomic disorders could be considered common symptoms in SLE. Of note, one study used a comprehensive questionnaire and reported that even though 37.2% of the SLE patients exhibited at least one autonomic symptom and 12% of the patients exhibited at least one severe autonomic symptom, none of the treating physicians had recorded/paid attention to any of these symptoms [9]. In this study, the percentage rate of each autonomic symptoms was reported as follows; dry/running nose (15.7%), headache/migraine (15.7%), gastrointestinal symptoms (9.8%), burning feet (7.8%), warm/cold extremities 5.9% sweating disturbances (5.9%), impotence (5.9%), and feeling too hot/cold (4%). Thus, although SLE patients frequently suffer from symptoms of autonomic disorders that can significantly impair their quality of life, these symptoms may have been ignored or considered unimportant.

Numerous methods such as measurement of the sympathetic skin response, R-R interval variation tests, pupillometric techniques, and hepatobiliary scintigraphy are reported to be useful to detect autonomic abnormalities in patients with SLE [5, 10, 11, 13]. Several reports have described the utility of the HUT for the diagnosis of autonomic disorders in SLE patients. The neurally mediated hypotension was detected in 47.9 % of SLE patients by using the HUT [14]. SLE patients show reduced systolic blood pressure at 5 min on the head-up tilt [15].

In the context of longitudinal evaluations of autonomic disorders in SLE, there are no established methods. One report reported no significant differences in 24-hr Holter-based HRV parameters after 7 months of therapy with chloroquine [16]. However, there were some tendencies toward a decrease in the mean of the standard deviations of all NN intervals for all 5-min segments of the entire recording (SDNNI), the square root of the mean of the sum of the squares of differences between adjacent NN intervals (rMSSD), and ultralow frequency (ULF) ($p=0.05$, 0.06 , and 0.06 , respectively). Another study used short-term HRV at two patient visits, and no significant differences were observed between the baseline and follow-up values for the majority of HRV parameters [17]. To the best of our knowledge, the present report is the first to note that the HUT was useful to objectively reveal the reversibility of autonomic disorders in SLE patients by treatment.

The appropriate therapeutic approach for autonomic disorders that are associated with SLE has not been established. Individuals with autoimmune diseases such as Sjögren's syndrome, rheumatoid arthritis, ankylosing spondylitis, Behçet's disease, and systemic sclerosis also develop autonomic disorders, and some immunotherapies have been reported to be beneficial for these conditions [18-21]; some reports have also described beneficial effects of IVCY [20, 21]. The combination of mPSL and IVCY is the only one strategy for acute and severe NPSLE as evidenced by a randomized controlled clinical trial which found that the treatment response was higher in the combination group compared to the mPSL monotherapy group [22]. There is only one report that IVCY treatment is beneficial for SLE patients who developed corticosteroid-refractory acute pan-dysautonomia including urination disorder and syncope due to orthostatic hypotension [10].

All three of the present patients showed the improvement of autonomic disorders with the resumption of the adrenaline response for the tilt and the resolution of the sympathetic hypertonia state by IVCY treatment. Of note, even though patient 1 showed the flare of autonomic disorder after the mPSL monotherapy, IVCY and mPSL combination therapy successfully controlled her autonomic disorder. At the time of induction of IVCY, all three patients were also diagnosed with NPSLE. There is the possibility that the development of severe autonomic disorders may be relevant to the conditions of NPSLE. Taken together, our present results suggest that intensive immunosuppressive therapy including IVCY can be a good treatment strategy for refractory autonomic disorders in SLE patients.

In sum, the clinical approaches for autonomic disorders in SLE patients are still a great challenge because of the complicated clinical manifestations and the difficulties in the evaluation of therapeutic effects. The findings drawn from the present patients indicate that: (1) IVCY treatment can be a good therapeutic option for severe autonomic disorders in SLE patients. (2) The HUT is a useful objective method for the diagnosis of and the evaluation of longitudinal therapeutic effects on autonomic disorders in SLE patients with orthostatic intolerance. We have presented the cases of only three patients, and thus further prospective studies with larger numbers of patients are needed in order to test our insights.

Patient consent

Written consent was obtained from the patient for publication of this manuscript.

Ethical approval

Not applicable.

Conflict of interest statement

None.

References

1. Tsokos GC. Systemic lupus erythematosus. *N Engl J Med*. 2011;365:2110-21.
2. Hanly JG, Urowitz MB, Sanchez-Guerrero J, Bae SC, Gordon C, Wallace DJ, et al. Neuropsychiatric events at the time of diagnosis of systemic lupus erythematosus: an international inception cohort study. *Arthritis Rheum*. 2007;56:265-73.
3. Sibley JT, Olszynski WP, Decoteau WE, Sundaram MB. The incidence and prognosis of central nervous system disease in systemic lupus erythematosus. *J Rheumatol*. 1992;19:47-52.
4. The American College of Rheumatology nomenclature and case definitions for neuropsychiatric lupus syndromes. *Arthritis Rheum*. 1999;42:599-608.
5. Matusik PS, Matusik PT, Stein PK. Heart rate variability in patients with systemic lupus erythematosus: a systematic review and methodological considerations. *Lupus*. 2018;27:1225-39.
6. Stojanovich L, Milovanovich B, de Luka SR, Popovich-Kuzmanovich D, Bisenich V, Djukanovich B, et al. Cardiovascular autonomic dysfunction in systemic lupus, rheumatoid arthritis, primary Sjogren syndrome and other autoimmune diseases. *Lupus*. 2007;16:181-5.
7. Nakane S, Higuchi O, Koga M, Kanda T, Murata K, Suzuki T, et al. Clinical features of autoimmune autonomic ganglionopathy and the detection of subunit-specific autoantibodies to the ganglionic acetylcholine receptor in Japanese patients. *PLoS One*. 2015;10:e0118312.
8. Freeman R, Wieling W, Axelrod FB, Benditt DG, Benarroch E, Biaggioni I, et al. Consensus statement on the definition of orthostatic hypotension, neurally mediated syncope and the postural tachycardia syndrome. *Clin Auton Res*. 2011;21:69-72.
9. Shalimar, Handa R, Deepak KK, Bhatia M, Aggarwal P, Pandey RM. Autonomic dysfunction in systemic lupus erythematosus. *Rheumatol Int*. 2006;26:837-40.
10. Yukawa S, Tahara K, Shoji A, Hayashi H, Tsuboi N. Acute pan-dysautonomia as well as central nervous system involvement and peripheral neuropathies in a patient with systemic lupus erythematosus. *Mod Rheumatol*. 2008;18:516-21.
11. Straub RH, Zeuner M, Lock G, Rath H, Hein R, Scholmerich J, et al. Autonomic and sensorimotor neuropathy in patients with systemic lupus erythematosus and systemic sclerosis. *J Rheumatol*. 1996;23:87-92.
12. Alam MM, Das P, Ghosh P, Zaman MS, Boro M, Sadhu M, et al. Cardiovascular Autonomic Neuropathy in Systemic Lupus Erythematosus. *Indian J Physiol Pharmacol*. 2015;59:155-61.
13. Fathalla M, El-Badawy M. Upper extremity subclinical autonomic and peripheral

- neuropathy in systemic lupus erythematosus. *Egyptian Rheumatology and Rehabilitation*. 2015;42:87-93.
14. Tang S, Calkins H, Petri M. Neurally mediated hypotension in systemic lupus erythematosus patients with fibromyalgia. *Rheumatology (Oxford)*. 2004;43:609-14.
 15. Hogarth MB, Judd L, Mathias CJ, Ritchie J, Stephens D, Rees RG. Cardiovascular autonomic function in systemic lupus erythematosus. *Lupus*. 2002;11:308-12.
 16. Wozniacka A, Cygankiewicz I, Chudzik M, Sysa-Jedrzejowska A, Wranicz JK. The cardiac safety of chloroquine phosphate treatment in patients with systemic lupus erythematosus: the influence on arrhythmia, heart rate variability and repolarization parameters. *Lupus*. 2006;15:521-5.
 17. Thanou A, Stavrakis S, Dyer JW, Munroe ME, James JA, Merrill JT. Impact of heart rate variability, a marker for cardiac health, on lupus disease activity. *Arthritis Res Ther*. 2016;18:197.
 18. Goodman BP, Crepeau A, Dhawan PS, Khoury JA, Harris LA. Spectrum of Autonomic Nervous System Impairment in Sjogren Syndrome. *Neurologist*. 2017;22:127-30.
 19. Syngle A, Verma I, Krishan P, Garg N, Syngle V. Disease-modifying anti-rheumatic drugs improve autonomic neuropathy in arthritis: DIANA study. *Clin Rheumatol*. 2015;34:1233-41.
 20. Casale R, Generini S, Luppi F, Pignone A, Matucci-Cerinic M. Pulse cyclophosphamide decreases sympathetic postganglionic activity, controls alveolitis, and normalizes vascular tone dysfunction (Raynaud's phenomenon) in a case of early systemic sclerosis. *Arthritis Rheum*. 2004;51:665-9.
 21. Gono T, Murata M, Kawaguchi Y, Wakasugi D, Soejima M, Yamanaka H, et al. Successful treatment for sympathetic storms in a patient with neuro-Behcet's disease. *Clin Rheumatol*. 2009;28:357-9.
 22. Barile-Fabris L, Ariza-Andraca R, Olguin-Ortega L, Jara LJ, Fraga-Mouret A, Miranda-Limon JM, et al. Controlled clinical trial of IV cyclophosphamide versus IV methylprednisolone in severe neurological manifestations in systemic lupus erythematosus. *Ann Rheum Dis*. 2005;64:620-5.

Figure legends

Fig. 1. Autonomic disorders with an abnormal head-up tilt table test (HUT) result and the heart rate variability (HRV) analysis findings obtained by 24-hr Holter monitoring were reversible by treatment. **A:** At the first admission, an increase in the heart rate (≥ 30 beats/min) with nausea developed within 5 min after tilting at 70° . At 20 min post-tilting, syncope with hypotension and bradycardia were observed. Due to the syncope, the HUT was immediately discontinued, and these symptoms recovered. Based on this result, neurally mediated syncope (mixed type) was diagnosed. After treatment with methylprednisolone (mPSL) pulse, changes in the heart rate (≥ 30 beats/min), hypotension, syncope, and nausea were not observed after a new HUT session with tilting. **B:** At the second admission, the positive result was similar to the first admission. After treatments including mPSL and intravenous cyclophosphamide (IVCY), the result turned to negative again. At this point, the increase in the level of noradrenaline as the response to a tilt was recovered and the sympathetic hypertonia state by HRV analysis was resolved. HF: High-frequency. LF: Low-frequency.

Fig 2. An increase in the heart rate (≥ 30 beats/min) with nausea and palpitations developed just after tilting. At 10 min post-tilting, the HUT was discontinued due to the severe nausea. Based on this result, postural orthostatic tachycardia syndrome (POTS) was diagnosed. After treatments with mPSL pulse and IVCY, the result became negative (change in the heart rate: < 30 beats/min). The increase in the noradrenaline value as the response to a tilt was recovered, and sympathetic hypertonia state was resolved in HRV analysis.

Fig 3: An increase in the heart rate (≥ 30 beats/min) with hyperventilation developed just after tilting. Based on this result, POTS was diagnosed. After treatment, the result became negative (change in the heart rate: < 30 beats/min). The increase in noradrenaline as the response to a tilt was recovered, and sympathetic hypertonia state was resolved in HRV analysis.

Figure.1

A Patient 1: First admission

B Patient 1: Second admission

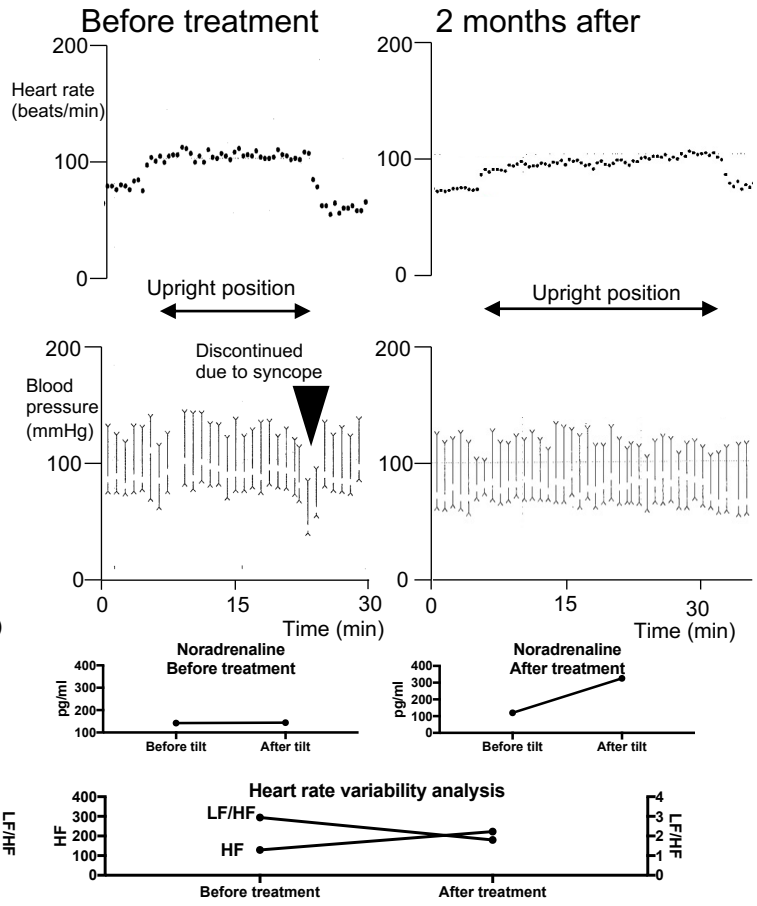
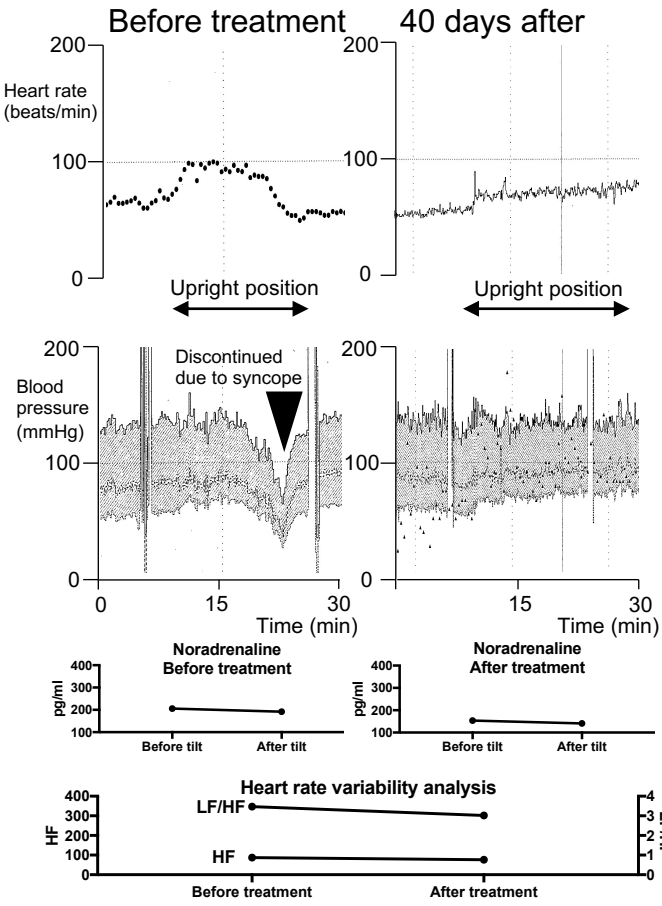


Figure.2

Patient 2

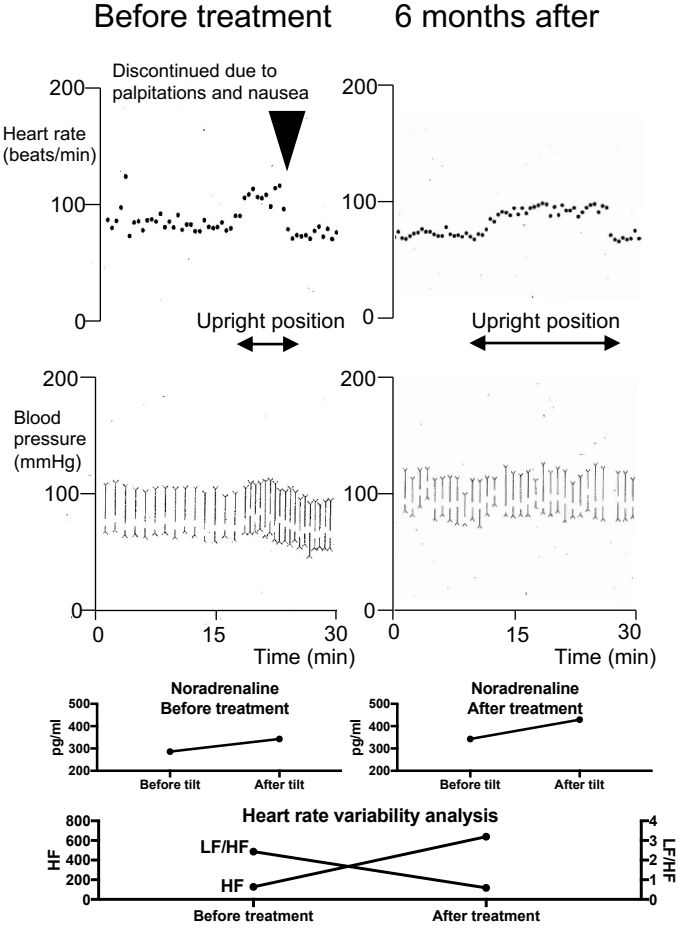


Figure.3

Patient 3

