



Complicated acute diverticulitis: a clinical case report

Bruna Mattos¹, Cibele Alexandra Ferro², Danilo Prandi de Carvalho², Enzo Prandi de Carvalho³, Fernanda Magni Cadamuro⁴, Hugo Guerra Rozani², João Pedro Pataro Domingos², Marilia Siqueira Procopio de Oliveira³, Sidney Moreno Gil², Bruno Ziade Gil^{2*}

¹ UNILAGO - União das Faculdades dos Grandes Lagos (Union of Great Lakes Colleges), Medicine course, São José do Rio Preto, São Paulo, Brazil.

² FAMECA - Faculty of Medicine of Catanduva/Centro Universitário Padre Albino (UNIFIPA), Catanduva, São Paulo, Brazil.

³ General Surgery, Hospital São Domingos, Catanduva, São Paulo, Brazil.

⁴ General Surgery, Hospital Padre Albino, Catanduva, São Paulo, Brazil.

*Corresponding author: Dr. Bruno Ziade Gil, FAMECA - Faculty of Medicine of Catanduva/Centro Universitário Padre Albino (UNIFIPA), Catanduva, São Paulo, Brazil. E-mail: bzgil@hotmail.com

DOI: <https://doi.org/10.54448/mdnt22403>

Received: 05-22-2022; Revised: 08-28-2022; Accepted: 09-21-2022; Published: 10-13-2022; MedNEXT-id: e22403

Abstract

Diverticular disease is a benign disease, with a good response to clinical treatment, based on changes in eating habits, greater fiber consumption, potent antibiotic therapy in the simplest inflammatory processes, and the use of interventional radiology in abscesses. A surgical indication is restricted to failure of clinical therapy and more severe forms of the disease, such as strictures, abscesses, and perforations. The present study aimed to present a clinical case report on acute diverticulosis of the left colon that progressed to a reconstruction of the intestinal transit.

Keywords: Diverticular Disease. Acute diverticulosis. Diverticulitis. Surgery.

Introduction

Acute diverticulosis of the left colon is common in Western countries, with its prevalence increasing worldwide, probably due to lifestyle changes [1,2]. Although left colonic diverticulosis remains more common among elderly patients, a dramatic increase in its incidence has been observed in younger age groups in recent years [3].

Acute diverticulosis of the left colon is a common problem encountered by Western surgeons in the acute setting. The sigmoid colon is usually the most commonly involved part, while acute right-sided diverticulitis is rarer but much more common in non-Western populations [2].

Imaging tests play a crucial role in the proper

management of Computer Aided Design (CAD). Among them, computed tomography (CT) is considered the method of choice by the protocols of the American Society of Coloproctology, as it allows rapid diagnosis, with an accuracy greater than 90% [4,5]. In 1978, Hinchey et al. described a four-stage classification for acute diverticulitis. In stage I the abscess is only pericolonic and in stage II it extends to the pelvis. In stage III, purulent peritonitis occurs, and in stage IV, peritoneal fecal dissemination occurs, secondary to a large loop perforation (Table 1) [6].

Table 1. Hinchey Classification.

I. Pericolonic or phlegmon abscess
II. Intra-abdominal or retroperitoneal abscess
III. purulent peritonitis
IV. fecal peritonitis

The most recent classifications divide CAD into two groups: complicated and uncomplicated. The latter is characterized only by the thickening of the wall of the diverticula, with an increase in the density of pericolonic fat. Complicated CAD is divided into stages. In stage 1A, pericolonic air bubbles are noted, with little fluid, and no abscess. In stage 1B the abscess is smaller than 4 cm and in stage 2A the abscess is larger than 4 cm. In stage 2B there may be distant air more than 5 cm from the inflamed loop, in stage 3 there is diffuse fluid without distant free air and in stage 4 air is present at a distance [7].

Therefore, the present study aimed to present a case report on acute diverticulosis of the left colon that

progressed to intestinal transit reconstruction.

Methods

Study Design

The present study was elaborated according to the rules of the CARE case report (<https://www.care-statement.org/>). A descriptive literature review was also carried out to provide sufficient scientific data for the theoretical basis of this study. The patient's medical record was analyzed, and who authorized access to it and signed the Free and Informed Consent Term, together with those involved in this work. This patient underwent treatment and medical follow-up with the supervisor of this work. A thorough evaluation of the aspects inherent to the physical examination, complementary exams, and surgical technique was carried out, to correlate with the literature cited in the bibliography. Data collection and analysis of the patient's medical records were performed at Hospital Unimed São Domingos Catanduva, Sao Paulo.

Ethical Approval

This study was analyzed and approved with the number 5.653.776 by the Research Ethics Committee from the FAMECA / UNIFIPA, Catanduva, Brazil, and obtaining the Informed Consent Form according to CNS/CONEP Resolution 466/12.

Case report

Patient Information and Clinical Findings, Timeline, Diagnostic Assessment, Therapeutic Intervention, and Follow-up

A 34-year-old male patient was admitted to the emergency department at Hospital Unimed São Domingos in Catanduva-SP on 12/13/2021 with pain in the left iliac fossa region (LIF) for 2 days. He denied allergies and comorbidities. On physical examination: good general condition (GGC), ruddy/hydrated/anicteric/acyanotic/afebrile (RHAAA), with a heart rate (HR) of 100 bpm. Abdomen: globular, flaccid on palpation, bowel sounds (HRA) present, pain on palpation in LIF, and positive sudden decompression (SD) in LIF. Conduct: admission to a ward bed for investigation of the case, zero diets, prescription of antibiotics and symptomatic.

Contrast-enhanced computed tomography of the abdomen was performed, with the following findings: isolated diverticula in the descending colon, perivesical fat blurring in the left iliac fossa topography, small volume pneumoperitoneum in the left iliac fossa topography, a small amount of fluid in the left iliac fossa.

Tomographic stage 1 A.

On 12/14/2021, the patient reported improvement in pain in LIF. On physical examination: GGC, RHAAA, HR: 85bpm. Abdomen: globose, flaccid on palpation, RHA+, pain on palpation in LIF, SD+. Conduct: VO liquid diet is allowed.

On 12/15/2021, the patient maintained the same clinical condition, eliminating flatus.

On 12/16/21, the patient reported worsening pain in LIF, with 2 fever peaks (37.8°C). Abdomen: globose, pain in LIF, SD+. Contrast Computed Tomography of the abdomen was performed with the following findings: diverticula through the descending colon, parietal thickening, and blurring of its perivisceral fat, fluid in the topography of the left iliac fossa and pelvis, pneumoperitoneum in the topography of the left iliac fossa. Conduct: the need for surgery is explained to the patient and family, which is scheduled for the next day.

On 12/17/2021, proposed surgery: laparoscopic rectosigmoidectomy plus ileostomy plus pelvic abscess drainage plus umbilical hernia repair.

Intraoperatively, it was found: purulent fluid in the LIF and pelvis, with the presence of blockage of the sigmoid colon in the abdominal wall and small bowel loops. A follow-up of a thickened sigmoid colon with an intense inflammatory process and perforation was identified. Rectosigmoidectomy plus ileostomy was performed.

On 12/18/2021, the patient felt well. He did not walk, non-functioning ileostomy, and presented 1 (one) episode of vomiting. Physical examination: GGC, RHAAA, dehydrated, HR 100bpm. Abdomen: globose, flaccid on palpation, distended, RH absent. Conduct: hydration increase, ambulation stimulation, motor/respiratory physiotherapy, and blood tests for the next day.

On 12/19/2021, pct reports episodes of vomiting after releasing water intake. Wandering, ileostomy with a dark flow of 15mL. Drain with an output of 390 mL of serosanguineous secretion. Ex. Physical: GGC, RHAAA, slightly dehydrated. Abdomen: globose, hypertympanic, distended, RH-, painless on palpation. The proposed conduct was ambulation, respiratory and motor physiotherapy, and zero diets.

Day 12/20/2021, pct without vomiting, without complications. Drain with little output of serosanguineous secretion and ileostomy with little output of blackish secretion. Ex. Physical: GGC, RHAAA, eupneic. Abdomen: flaccid on palpation, SD-RH+.

Conduct: prescription maintained.

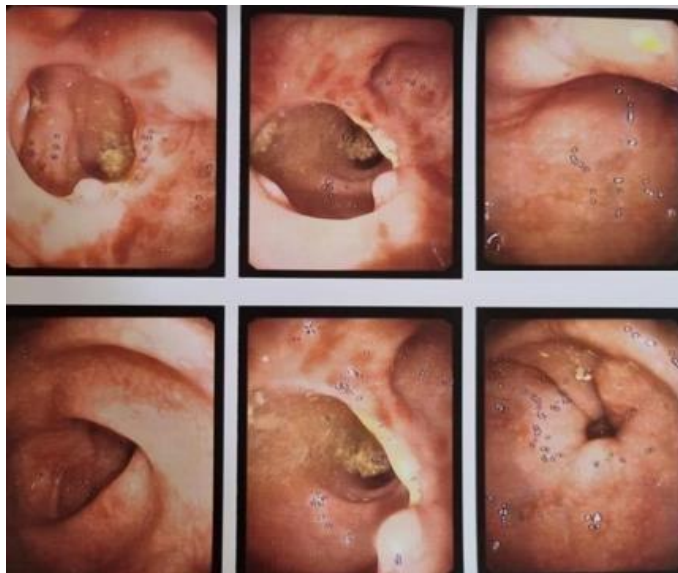
Day 12/21/2021, pct well, report the beginning of the feeling of hunger. Drain and ileostomy with a little number of secretions. Conduct: the same prescription was maintained.

Day 12/22/2021, maintaining the same evolution. Pct is discharged from the hospital.

On 02/07/2022, internal pct to prepare for a colonoscopy the next day. A colonoscopy was performed on 02/08/2022 with the following findings:

- Observation of the ileocecal valve, transposition through it up to 8 cm to 10 cm from the distal ileum, which is found with the mucosa of normal appearance.
- Cecum with normal shape, caliber, peristalsis and mucosa, and visible appendix ostium, and without lesion.
- The ascending, transverse and descending, and sigmoid colons have normal shape, caliber, and peristalsis (**Table 1**).
- The mucosa meets with a soft anastomosis 35 cm from the anal border.

Figure 1. Colonoscopy image of the patient in question.



Intestinal transit reconstruction surgery was scheduled for 03/25/2022. On 03/25/2022, the patient underwent surgery to reconstruct the intestinal transit, with the closure of the colostomy. Under general anesthesia, anastomosis was performed with 2 loads of 75 of the linear stapler and reinforcement with Vicryl 3.0.

The patient evolved with significant improvement in the postoperative period.

Discussion

The radiological imaging techniques that are used to diagnose left-sided colonic diverticulitis in the emergency setting are US and CT. Currently, CT is the established method of choice when compared to the US and most guidelines cite the high accuracy and other advantages of CT. This approach is the gold standard

for both diagnosis and staging of patients with left-sided colonic diverticulitis due to its excellent sensitivity and specificity [9-11]. CT scans can also rule out other diagnoses, such as ovarian pathology or leaking aortic or iliac aneurysm.

Conclusion

Acute diverticulitis can cause damage to the patient from obstructions to perforations and can lead to death. For the ideal treatment, this must be identified in its initial stage, causing less morbidity to the patient. Diverticula are often found in colorectal cancer screening with colonoscopy. Once discovered, the patient should be guided about food, precautions, and symptoms, in case it complicates.

Acknowledgement

Not applicable.

Funding

Not applicable.

Ethics approval

This study was analyzed and approved with the number 5.653.776 by the Research Ethics Committee from the FAMECA / UNIFIPA, Catanduva, Brazil, and obtaining the Informed Consent Form according to CNS/CONEP Resolution 466/12.

Informed consent

Was applied.

Data sharing statement

No additional data are available.

Conflict of interest

The authors declare no conflict of interest.

Similarity check

It was applied by Ithenticate@.

About the License

© The authors (s) 2022. The text of this article is open access and licensed under a Creative Commons Attribution 4.0 International License.

References

1. Alvarez, Guines Antunes e Mazzurana, Mônica Diverticulite aguda complicada tratada por cirurgia laparoscópica assistida com a mão (Hals): descrição da técnica e revisão da literatura.

- Revista Brasileira de Coloproctologia [online]. 2006, v. 26, n. 3.
2. Weizman AV, Nguyen GC. Doença diverticular: epidemiologia tratamento. *Pode J Gastroenterol.* 2011;25:385–9.
 3. Schoetz DJ. Doença diverticular do cólon: um problema centenário. *Dis cólon reto.* 1999;42:703–9.
 4. Tiferes DA, Jayanthi SK, Liguori AAL. Cólon, reto e apêndice. In: D'Ippolito G, Caldana RP, editores. *Gastrointestinal. Série CBR.* 1a ed. Rio de Janeiro: Editora Sarvier; 2011. p. 203–52.
 5. Andeweg CS, Mulder IM, Felt-Bersma RJ, et al. Guidelines of diagnosis and treatment of acute left-sided colonic diverticulitis. *Dig Surg.* 2013;30:278–92.
 6. Klarenbeek BR, de Korte N, van der Peet DL, et al. Review of current classifications for diverticular disease and a translation into clinical practice. *Int J Colorectal Dis.* 2012;27:207–14.
 7. Sartelli M, Moore FA, Ansaloni L, et al. A proposal for a CT driven classification of left colon acute diverticulitis. *World J Emerg Surg.* 2015;10:3.
 8. Naves AA, D'Ippolito G, Souza LRMF, Borges SP, Fernandes GM. O que o radiologista deve saber na avaliação tomográfica da diverticulite aguda dos cólons. *Radiol Bras.* 2017 Mar/Abr;50(2):126–131.
 9. Laméris W, van Randen A, Bipat S, Bossuyt PM, Boermeester MA, Stoker J. Ultrassonografia de compressão graduada e tomografia computadorizada na diverticulite colônica aguda: meta-análise da acurácia do teste. *Eur Radiol.* 2008;18:2498–511.
 10. Liljegren G, Chabok A, Wickbom M, Smedh K, Nilsson K. diverticulite colônica aguda: uma revisão sistemática de acurácia diagnóstica. *Cor Des.* 2007;9:480–8.
 11. Ambrosetti P, Jenny A, Becker C, Terrier TF, Morel P. Diverticulite aguda do cólon esquerdo – comparado ao desempenho de tomografia computadorizada e enema de contraste solúvel em água: avaliação prospectiva de 420 pacientes. *Dis cólon reto.* 2000;43:1363-7.