



## Incidence and major clinical approaches of aneurismatic bone cysts: a concise systematic review

Amanda de Paula Vasconcelos<sup>1</sup>, Izabela Bryane Pereira Enderle Bannak<sup>1</sup>, Isabella Rodrigues Gomes Dias Naves<sup>1</sup>, Renato Gomes Azevedo<sup>1,2</sup>, Gestter Willian Lattari Tessarin<sup>1,2\*</sup>

<sup>1</sup> UNORTE - University Center of Northern São Paulo, Dentistry department, São José do Rio Preto, São Paulo, Brazil.

<sup>2</sup> UNIPOS - Post graduate and continuing education, Dentistry department, São José do Rio Preto, São Paulo, Brazil.

\*Corresponding author: Prof. Dr. Gestter Willian Lattari Tessarin. Unorte/Unipos – Graduate and Postgraduate education, Dentistry department, São José do Rio Preto, São Paulo, Brazil. E-mail: gestter@unorp.br

DOI: <https://doi.org/10.54448/mdnt22S603>

Received: 03-22-2022; Revised: 06-17-2022; Accepted: 08-18-2022; Published: 09-30-2022; MedNEXT-id: e22S603

### Abstract

**Introduction:** Aneurysmal bone cysts (ABC) are pseudocysts expansive lesions. The World Health Organization (WHO) categorizes primary ABCs as cystic neoplasms that contain fibrous septa separating numerous blood-filled spaces. Approximately 70% of ABC cases are primary, while 30% are secondary.

**Objective:** The present study aimed to carry out a concise systematic review of the main clinical findings of aneurysmal bone cysts, highlighting the incidence and prevalence, as well as the main forms of treatment.

**Methods:** The rules of the Systematic Review-PRISMA Platform were followed. The research was carried out from May 2022 to July 2022 and developed based on Scopus, PubMed, Science Direct, Scielo, and Google Scholar. The quality of the studies was based on the GRADE instrument and the risk of bias was analyzed according to the Cochrane instrument. **Results:** A total of 143 articles were found. In total, 73 articles were evaluated and 10 were included and evaluated in the systematic review. The symmetric funnel plot does not suggest a risk of bias. After prospecting the main literary findings, it was generally evidenced that the aneurysmal bone cyst (ABC) is a rare lesion that is more frequently found in young adults and children. It may have unpredictable behavior, with a high recurrence rate after treatment. Standard treatment consists of curettage plus local adjuvants and bone grafting to fill the void. In anatomic sites with difficult surgical access, percutaneous procedures are used (injection of sclerosing agents, radiofrequency thermal ablation, or selective arterial embolization. Medical management with bisphosphonates or denosumab has also been

advocated. **Conclusion:** Primary ABCs involving the maxillofacial region are extremely rare and even more in patients with advanced age. Next-generation sequencing confirmed the presence of a USP6-CDH11 fusion gene, consistent with classification as a primary aneurysmal bone cyst. Sclerotherapy provided an effective and minimally invasive treatment for aneurysmal bone cysts and is particularly useful for deep injuries, challenging surgical access, and potentially injurious vital structures.

**Keywords:** Aneurysmal bone cyst. Tumors. Incidence. Treatments. Maxillofacial.

### Introduction

Aneurysmal bone cysts (ABC) are pseudocyst expansive lesions and were first reported by Jaffe and Lichenstein in the 1940s [1,2]. ABC form 1% of primary bone tumors [3]. The World Health Organization (WHO) categorizes primary ABC as cystic neoplasms that contain fibrous septa separating numerous blood-filled spaces [2].

In this context, ABCs have different proposed pathogenic mechanisms and can occur as primary neoplastic lesions or secondary reactive lesions [3]. The mesenchymal neoplastic nature of primary ABC is characterized by genetic abnormalities in the osteoblast cadherin 11 gene (CDH11) that result in the upregulation of the ubiquitin protease USP6 gene transcription [4,5]. Secondary ABC of the jaws occurs most commonly in the setting of cement-ossifying fibromas or central giant cell granulomas [6-8].

Still, studies on retrognathic ABC seem to be more

common [9-12]. The authors Richardson et al. [6] published a complete review of the literature on primary and secondary ABC involving the head and neck region. Other ABC studies have documented variable clinical presentations, eccentric bone location, and atypical radiological features [9,13-15]. The ABC typically presents as a blood-soaked sponge intraoperatively. The surgical treatment of ABC by enucleation and curettage is associated with significant bleeding, requiring resection of the lesion [3,6]. Preoperative embolization can help in the management of excessive bleeding found intraoperatively [16,17].

In radiographic examinations, ABC is characterized by ballooned cortical expansion from unilocular to multilocular radiolucent lesions [10]. Histopathologically, ABC is characterized by blood-filled spaces separated by fibrous septa containing osteoclast-like giant cells [10]. The lesion develops de novo as a true mesenchymal neoplasm, termed "primary ABC", or secondary to a pre-existing bone lesion, termed "secondary ABC". [11,12]. Secondary ABC demonstrate similar pathological features to primary ABC but have additional histological findings indicating the presence of an additional, coexisting lesion. Approximately 70% of ABC cases are primary, while 30% are secondary [12,13].

Non-epithelial cysts occasionally occur together with various bone lesions, mainly fibrous dysplasia, giant cell tumor, chondroblastoma, ossifying fibroma, benign osteoblastoma, fibrous histiocytoma, and fibrosarcoma. These cysts include ABC, simple bone cyst, and nonspecific cystic degeneration [14].

Therefore, the present study aimed to carry out a concise systematic review of the main clinical findings of aneurysmal bone cysts, highlighting the incidence and prevalence, as well as the main forms of treatment.

## Methods

### Study Design

The rules of the Systematic Review-PRISMA Platform (Transparent reporting of systematic reviews and meta-analysis-[HTTP://www.prisma-statement.org/](http://www.prisma-statement.org/)) were followed.

### Data sources and research strategy

The search strategies for this systematic review were based on the keywords (MeSH Terms): "Aneurysmal bone cyst. Tumors. Incidence. Treatments. Maxillofacial". The research was carried out in May 2022 to July 2022 and developed based on Scopus, PubMed, Science Direct, Scielo, and Google Scholar. Also, a combination of the keywords with the

booleans "OR", "AND", and the operator "NOT" were used to target the scientific articles of interest.

### Study Quality and Bias Risk

The quality of the studies was based on the GRADE instrument and the risk of bias was analyzed according to the Cochrane instrument.

## Results and Discussion

A total of 143 articles were found. Initially, duplication of articles was excluded. After this process, the abstracts were evaluated and a new exclusion was performed, removing the articles that did not address the theme of this article. In total, 73 articles were evaluated and 10 were included and evaluated in the systematic review (Figure 1).

**Figure 1.** Flow Chart (Studies included in the Systematic Review).

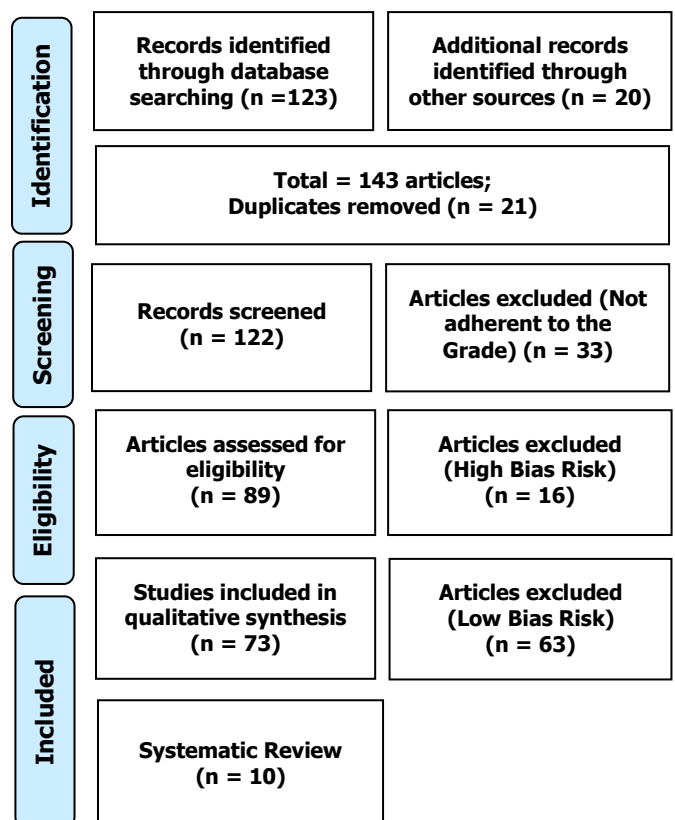
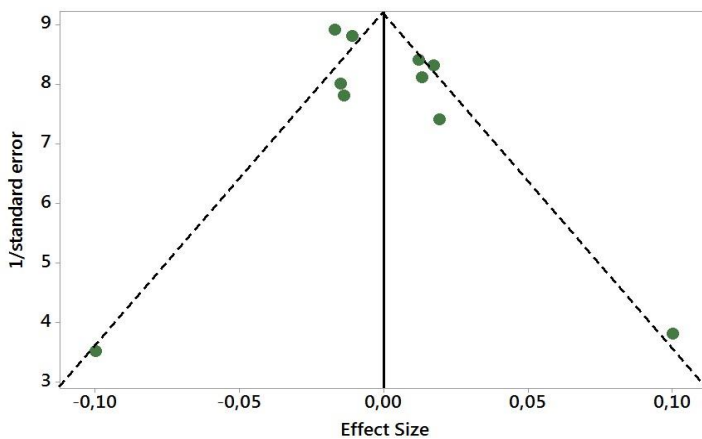


Figure 2 presents the results of the risk of bias in the studies using the Funnel Plot, through the calculation of the Effect Size (Cohen's Test). The sample size was determined indirectly by the inverse of the standard error. The number of clinical studies evaluated was n=10. The graph showed symmetric behavior, not suggesting a significant risk of bias in studies with small sample sizes, which are shown at the bottom of the graph.

**Figure 2.** The symmetric funnel plot does not suggest a risk of bias between the small sample size studies that are shown at the bottom of the graph (N = 10 clinical studies).



After prospecting the main literary findings, it was generally evidenced that the aneurysmal bone cyst (ABC) is a rare lesion that is more frequently found in young adults and children. It may have unpredictable behavior, with a high recurrence rate after treatment. Treatment is based on personal and institutional experience and preferences. Standard treatment consists of curettage (manual and high-speed motor drill) plus local adjuvants and bone grafting to fill the void. In anatomic sites with difficult surgical access, percutaneous procedures are used (injection of sclerosing agents, radiofrequency thermal ablation, or selective arterial embolization. Medical management with bisphosphonates or denosumab has also been advocated. Minimally invasive surgical procedures such as "curopsy" and grafting of Percutaneous demineralized bone matrix and/or autologous bone marrow concentrate graft have also been proposed. Selective arterial embolization is used as a preoperative procedure to reduce intraoperative bleeding in large lesions and as a primary treatment for spinal cord injuries [18].

In addition, a study analyzed the demographic, clinical, and radiological characteristics of primary ABC involving the maxillofacial region. A total of 31 primary ABC cases were included. An almost equal distribution of males to females was observed, with ABC occurring in males at an earlier age compared to females. Localized edema was the main clinical presentation. The ABC had mandibular predominance, mainly in the posterior regions. All ABC presented as expansive and well-demarcated radiolucent lesions, with most presenting a multilocular appearance. The cortical expansion was observed in 91% of cases, with loss of cortical integrity being common (78%). Therefore, primary ABC involving the maxillofacial region are

extremely rare [19].

In addition, a case report presented an 11-year-old boy with the progressive gradual enlargement of his right zygomatic bone over 4 years before presentation. Computed tomography revealed a lesion with a central bone area with a ground-glass appearance surrounded by a well-delimited expansive lesion with internal septations. An incisional biopsy was performed which suggested a fibro-osseous lesion. Resection was performed, followed by immediate reconstruction with an autogenous bone graft from the iliac crest. Histopathological examination revealed irregularly shaped trabeculae comprising immature bone tissue in a stroma rich in fibroblast cells. Blood-filled sinusoidal spaces lined by fibrous septa containing scattered multinucleated giant cells were observed peripherally. These findings were compatible with concomitant fibro-osseous injury and ABC. The patient was disease-free at the time of his 10-month follow-up [20].

In addition, concomitant cement-osseous dysplasia (COD) and ABC are rare in the head and neck region. A case report presented a 32-year-old female patient who was referred from a private dental clinic due to a cystic lesion below the lower right first molar. She had no pain or significant systemic illness. After performing panoramic radiography and cone-beam computed tomography, the imaging diagnosis was COD with cystic lesions such as ABC or solitary bone cyst. An excisional biopsy was performed, which revealed concomitant COD and ABC [21].

Another article presented a rare case report in an elderly person, highlighting the challenge of establishing a presumptive etiological diagnosis when unilocular or multilocular radiolucencies are identified in the jaws of an elderly patient. A mandibular cyst-like lesion was identified in a 73-year-old patient. The therapeutic decision was enucleation of the cyst and grafting of the bone defect [22].

Besides, a case report described a 27-year-old male presenting with long-standing leftsided facial asymmetry. Multidetector computed tomography demonstrated a large expansive lesion positioned on the left condyle head. The lesion was biopsied and resected. The specimen showed a cystic neoplasm rich in giant cells, with fibrous tissue covered by multinucleated giant cells. Next-generation sequencing confirmed the presence of a USP6-CDH11 fusion gene, consistent with classification as primary ABC [23].

In this scenario, the WHO designates the ABC as benign, but locally destructive and rapidly growing masses. ABC can be diagnosed clinically as a malignant tumor. Thus, a case report of a 12-year-old female patient who presented to a maxillofacial outpatient clinic complaining of massive edema of the mandible for the

past 3 months. Few cases reported in the English literature describe ABC presented with a huge, rapidly growing mass causing a destructive bone lesion that was clinically mimicking a sarcoma, which initiates this case report [24].

Although surgical treatment of ABC is the most common option, it is associated with high rates of morbidity. A case of a sizable aneurysmal bone cyst in a 27-year-old male patient presented a conservative surgical approach with preservation of dental structures in the mandible to limit aesthetic and functional side effects. A two-year clinical follow-up was performed without evidence of recurrence [25].

In this context, sclerotherapy offers an alternative to surgery to treat an ABC. One study evaluated the radiological efficacy of sclerotherapy in the healing of the cyst cavity secondary to biopsy-proven ABC and X-rays, evaluating the clinical efficacy in pain, recurrence, and complications. Twenty-six patients (12 women, 14 men) with biopsy-proven ABC and treated by sclerotherapy were included. Ossification was complete in 24 (92.3%) patients and partial in two (7.7%) patients. Eighteen patients (70%) were pain-free at the end of three months. There was an improvement in the VAS score and, clinically, there was a significant reduction in pain and edema. Two patients evolved with recurrence in two years of follow-up, successfully treated by reapplication of intralesional 3% polidocanol. Therefore, sclerotherapy has provided an effective and minimally invasive treatment for ABC and is particularly useful for deep injuries, challenging access to surgery, and potentially injurious vital structures. The use of 3% percutaneous polidocanol under fluoroscopic control appeared to improve the risk/benefit ratio [26].

Finally, a systematic review study describing patient demographics, clinical features, management, and outcomes with ABC of craniofacial bones. We identified 127 patients from 116 studies. The age ranged from 8 months to 90 years, with a mean of 19.0 years. The most commonly affected craniofacial locations were the mandible (n = 31, 24.4%), temporal bone (n = 21, 16.5%) and occipital bone (n = 14, 11.0%). The most common presenting symptoms included a painless mass (n = 51, 40.2%), a painful mass (n = 31, 24.4%) and generalized headache (n = 30, 23.6%). Imaging modalities included computed tomography (CT) and magnetic resonance imaging (MRI) (n = 77, 60.6%), CT alone (n = 31, 24.4%) and MRI alone (n = 8, 6.2%). All patients underwent surgical resection, with 1 patient requiring adjuvant radiation in addition to surgery. In total, 121 patients were disease-free and symptom-free with no evidence of recurrence (17.4 months median follow-up, 5.4 months median time to the first recurrence) [27].

## Conclusion

It was concluded that an aneurysmal bone cyst is a rare lesion that is more frequently found in young adults and children. It may have unpredictable behavior, with a high recurrence rate after treatment. Next-generation sequencing confirmed the presence of a USP6-CDH11 fusion gene, consistent with classification as a primary aneurysmal bone cyst. Sclerotherapy has provided an effective and minimally invasive treatment for aneurysmal bone cysts and is particularly useful for deep injuries, challenging surgical access, and potentially injurious vital structures.

## Acknowledgement

Not applicable.

## Funding

Not applicable.

## Ethics approval

Not applicable.

## Informed consent

Not applicable.

## Data sharing statement

No additional data are available.

## Conflict of interest

The authors declare no conflict of interest.

## Similarity check

It was applied by Ithenticate@.

## About the License

© The authors (s) 2022. The text of this article is open access and licensed under a Creative Commons Attribution 4.0 International License.

## References

1. Jaffe HL, Lichtenstein L. Solitary unicameral bone cyst: with emphasis on the roentgen picture, the pathologic appearance and the pathogenesis. *Arch Surgery* 1942; 44: 1004–10025.
2. Jordan RC, Koutlas I, Raubenheimer EJ. et al. Aneurysmal bone cyst. In: El-Naggar AK, John KCC, Grandis JR, et al., eds. *WHO Classification of Head and Neck Tumours*. 4th ed. Lyon: IARC; 2017, pp. 258–59.
3. Rajasekaran S, Aiyer SN, Shetty AP, Kanna R, Maheswaran A. Aneurysmal bone cyst of C2



- treated with novel anterior reconstruction and stabilization. *Eur Spine J.* 2019 Feb;28(2):270-278. doi: 10.1007/s00586-016-4518-0. Epub 2016 Mar 23. PMID: 27007865.
4. Oliveira AM, Perez- Atayde AR, Inwards CY, Medeiros F, Derr V, Hsi B- L, et al. USP6 and CDH11 oncogenes identify the neoplastic cell in primary aneurysmal bone cysts and are absent in so- called secondary aneurysmal bone cysts. *Am J Pathol* 2004; 165: 1773–80. [https://doi.org/10.1016/S0002-9440\(10\)63432-3](https://doi.org/10.1016/S0002-9440(10)63432-3)
  5. Hiemcke-Jiwa LS, van Gorp JM, Fisher C, Creytens D, van Diest PJ, Flucke U. USP6-associated neoplasms: A rapidly expanding family of lesions. *Int J Surg Pathol* 2020; 28: 816–25. <https://doi.org/10.1177/1066896920938878>
  6. Richardson J, Litman E, Stanbouly D, Lee KC, Philipone E. Aneurysmal bone cyst of the head & neck: A review of reported cases in the literature. *J Stomatol Oral Maxillofac Surg* 2022; 123: 59–63. <https://doi.org/10.1016/j.jormas.2021.01.014>
  7. Applebaum D, Calo O, Neville K. Implementation of quiet time for noise reduction on a medical-surgical unit. *J Nurs Adm* 2016; 46: 669–74. <https://doi.org/10.1097/NNA.0000000000000424>
  8. Motamedi MHK, Navi F, Eshkevari PS, Jafari SM, Shams MG, Taheri M, et al. Variable presentations of aneurysmal bone cysts of the jaws: 51 cases treated during a 30- year period. *J Oral Maxillofac Surg* 2008; 66: 2098–2103. <https://doi.org/10.1016/j.joms.2008.05.364>.
  9. Brooks PJ, Chadwick JW, Caminiti M, Dickson B, Leong I. Primary aneurysmal bone cyst of the mandibular condyle with USP6-CDH11 fusion. *Pathol Res Pract.* 2019 Mar;215(3):607-610. doi: 10.1016/j.prp.2018.10.038. Epub 2018 Nov 2. PMID: 30401581.
  10. Sun Z- J, Zhao Y- F, Yang R- L, Zwahlen RA. Aneurysmal bone cysts of the jaws: analysis of 17 cases. *J Oral Maxillofac Surg* 2010; 68: 2122–28. <https://doi.org/10.1016/j.joms.2009.07.111>.
  11. Smith AJ, Choby G, Van Gompel JJ, Link MJ, Van Abel KM. Aneurysmal bone cysts of the paranasal sinuses. *The Mayo Clinic Experience and Review of the Literature Laryngoscope* 2021; 131: 2525–33.
  12. Cottalorda J, Bourelle S. Modern concepts of primary aneu-rysmal bone cyst. *Arch Orthop Trauma Surg* 2007; 127: 105–14. <https://doi.org/10.1007/s00402-0060223-5>.
  13. Mahnken AH, Nolte- Ernsting CCA, Wildberger JE, Heussen N, Adam G, Wirtz DC, et al. Aneurysmal bone cyst: value of MR imaging and conventional radiography. *Eur Radiol* 2003; 13: 1118–24. <https://doi.org/10.1007/s00330-002-1668-8>.
  14. Fennessy BG, Vargas SO, Silvera MV, Ohlms LA, McGill TJ, Healy GB, et al. Paediatric aneurysmal bone cysts of the head and neck. *J Laryngol Otol* 2009; 123: 635–41. <https://doi.org/10.1017/S002221510800337X>.
  15. Senol U, Karaali K, Akyüz M, Gelen T, Tuncer R, Lüleci E. Aneu-rysmal bone cyst of the orbit. *AJNR Am J Neuroradiol* 2002; 23: 319–21.
  16. Asaumi J, Konouchi H, Hisatomi M, Matsuzaki H, Shigehara H, Honda Y, et al. MR features of aneurysmal bone cyst of the mandible and characteristics distinguishing it from other lesions. *Eur J Radiol* 2003; 45: 108–12. [https://doi.org/10.1016/s0720-048x\(02\)00008-6](https://doi.org/10.1016/s0720-048x(02)00008-6).
  17. Segall L, Cohen- Kerem R, Ngan BY, Forte V. Aneurysmal bone cysts of the head and neck in pediatric patients: A case series. *Int J Pediatr Otorhinolaryngol* 2008; 72: 977–83.
  18. Muratori F, Mondanelli N, Rizzo AR, Beltrami G, Giannotti S, Capanna R, Campanacci DA. Aneurysmal Bone Cyst: A Review of Management. *Surg Technol Int.* 2019 Nov 10;35:325-335. PMID: 31476792.
  19. Smit C, Robinson L, Roman Tager E, Roza ALOC, Rocha AC, Santos-Silva AR, Vargas PA, Romañach MJ, Fonseca FP, Carlos R, van Heerden WF. Clinicoradiological spectrum of primary aneurysmal bone cysts of the maxillofacial region: A series of 31 cases. *Dentomaxillofac Radiol.* 2022 Jul 1;51(5):20220071. doi: 10.1259/dmfr.20220071. Epub 2022 May 23. PMID: 35522705.
  20. Rau LH, Reinheimer A, Meurer MI, Marodin AL, Espezim CS, Klüppel LE, Dos Santos Vaz Fernandes PC, Rivero ERC. Fibrous dysplasia with secondary aneurysmal bone cyst-a rare case report and literature review. *Oral Maxillofac Surg.* 2019 Mar;23(1):101107. doi: 10.1007/s10006-019-00741-w. Epub 2019 Feb 13. PMID: 30758737.
  21. Yeom HG, Yoon JH. Concomitant cemento-osseous dysplasia and aneurysmal bone cyst of the mandible: a rare case report with literature review. *BMC Oral Health.* 2020 Oct 9;20(1):276. doi: 10.1186/s12903-020-01264-7. PMID: 33036586; PMCID: PMC7547449.
  22. Rațiu C, Ilea A, Gal FA, Ruxanda F, Boșca BA, Miclăuș V. Mandibular aneurysmal bone cyst in an elderly patient: Case report. *Gerodontology.* 2018 Jun;35(2):143-146. doi: 10.1111/ger.12325.

PMID: 29733532.

- 23.** Brooks PJ, Chadwick JW, Caminiti M, Dickson B, Leong I. Primary aneurysmal bone cyst of the mandibular condyle with USP6-CDH11 fusion. *Pathol Res Pract*. 2019 Mar;215(3):607-610. doi: 10.1016/j.prp.2018.10.038. Epub 2018 Nov 2. PMID: 30401581.
- 24.** Al-Maghrabi H, Verne S, Al-Maghrabi B, Almutawa O, Al-Maghrabi J. Atypical Presentation of Giant Mandibular Aneurysmal Bone Cyst with Cemento-Ossifying Fibroma Mimicking Sarcoma. *Case Rep Otolaryngol*. 2019 Aug 27;2019:1493702. doi: 10.1155/2019/1493702. PMID: 31534810; PMCID: PMC6732594.
- 25.** Álvarez-Martínez EC, Posso-Zapata MV, Flórez-Arango VA, Lopera-Valle JS, Ardila CM. Aneurysmal bone cyst of the mandible with conservative surgical management: A case report. *J Clin Exp Dent*. 2019 Jun 1;11(6):e561-e564. doi: 10.4317/jced.55771. PMID: 31346378; PMCID: PMC6645265.
- 26.** Kumar D, Kumar S, Kumar D, Patel BM, Kumar A, Kumar S, Waliullah S. Sclerotherapy for Aneurysmal Bone Cyst: A Single-Center Experience. *Cureus*. 2021 Oct 4;13(10):e18469. doi: 10.7759/cureus.18469. PMID: 34754635; PMCID: PMC8564749.
- 27.** Rehman R, Dekhou A, Osto M, Agemy J, Chaaban A, Yuhan B, Thorpe E. Aneurysmal Bone Cysts of the Craniofacial Origin: A Systematic Review. *OTO Open*. 2021 Oct 24;5(4):2473974X211052950. doi: 10.1177/2473974X211052950. PMID: 34723050; PMCID: PMC8549472.