



Orthognathic surgery and fat injection for corrective liposculpture: a systematic review

Paulo Rodrigo Albino Lucchese^{1,2}, Rogério Clayton Bisetto^{1,2}, Fabio Alarcon Idalgo^{1,2}, Silvio Antonio dos Santos Pereira^{1,2}, Alexandre Gomes Nunes^{1,2}, Elias Naim Kassis^{1,2}, Álvaro José Cicareli^{1,2*}

¹ UNORTE - University Center of Northern São Paulo, Dentistry department, São José do Rio Preto, São Paulo, Brazil.

² UNIPOS - Post graduate and continuing education, Dentistry department, São José do Rio Preto, São Paulo, Brazil.

*Corresponding author: Prof. Dr. Álvaro José Cicareli.
Unorte/Unipos – Graduate and Postgraduate education,
Dentistry department, São José do Rio Preto, São
Paulo, Brazil. E-mail: alvarocicareli@gmail.com

DOI: <https://doi.org/10.54448/mdnt22S604>

Received: 05-20-2022; Revised: 08-24-2022; Accepted: 09-25-2022; Published: 10-14-2022; MedNEXT-id: e22S604

Abstract

Introduction: Orthognathic Surgery (OS) aims to correct deformities of the bones of the maxilla and mandible. In this scenario, fat grafting is a powerful tool for corrections and also for facial aesthetic improvement together or after OS. The benefits of fat grafting during orthognathic surgery; to maximize aesthetic results, minimize swelling and optimize wound healing.

Objective: To analyze the main clinical studies on the benefits and risks of facial fat grafting in orthognathic surgery, to know the current state of the art. **Methods:**

It followed a systematic literature review model on the main clinical findings of orthognathic surgery and fat grafting, according to the rules of PRISMA. The research was carried out from July to September 2022 and developed based on Google Scholar, Scopus, PubMed, Ovid, Scielo, and Cochrane Library, using scientific articles from 1986 to 2022. The quality of the studies was based on the GRADE instrument and the risk of bias was analyzed according to the Cochrane instrument.

Results: 123 studies were analyzed, with only 32 medium and high-quality studies selected, according to GRADE rules, and with risks of bias that do not compromise scientific development, based on the Cochrane instrument. Studies have shown that OS aims to establish harmonious facial esthetics, excellent functional occlusion, and improved airway conditions. As an important adjunct to OS, fat grafting is becoming more and more common due to its antiinflammatory role and effects on facial swelling. High patient satisfaction with the results. Postoperative swelling resolved at week 12 in the fat graft group and persistent edema. The edema decrease over time, with almost complete

resolution within 1 year, improvement in facial morphology, function, quality, and skin texture in most of their patients. The use of assisted lipo transfers containing mesenchymal stem cells derived from adipose tissue, enables improvement in skin quality, smoothing of wrinkles, pore size, and attenuation of pigmentation and resolution of scars. Furthermore, enrichment of the lipoaspirate with stem cells derived from adipose tissue increases graft retention.

Conclusion: Most of the studies analyzed in this review study showed that fat grafting in orthognathic surgery is a safe and effective tool to improve wound healing, improve aesthetic results, present an anti-inflammatory effect and reduce edema.

Keywords: Orthognathic surgery. Lipografting. Fat grafting. Facial symmetry. Aesthetics.

Introduction

Orthognathic Surgery (OS) aims to correct deformities of the bones of the maxilla and mandible [1,2]. In this context, the facial deformity has a negative impact, resulting in social and psychological disadvantages [3-6]. The technique has undergone great evolution in the last two decades and has been growing continuously. The records of the first surgeries to correct dentofacial deformities date back to the mid-19th century and were initially limited to mandibular surgeries [7-9].

Author Simon P. Hullihen in 1849 in the United States was the first to perform this surgery. The most significant development in this period took place in Europe, especially in Switzerland, Austria, and

Germany, with Obwegeser, Trauner, and Wassmund, respectively, as the main names [10,11].

In this context, malocclusion has as one of the main etiological factors the pattern of facial growth [12,13]. Facial deformity, with destructive psychological and social potential, has a negative impact, resulting in social and psychological disadvantages. Thus, the goals of the patient with dentofacial deformity are also psychosocial, seeking to solve these problems by improving their appearance through surgical correction [14].

In this sense, OS intervenes in patients with moderate and severe dentofacial deformities of the face, with the main objective of centralizing the achievement of functional balance and harmony in facial aesthetics [15]. Patients with anatomical abnormalities that contribute to the narrowing or obstruction of the pharyngeal air space during sleep benefit from orthognathic surgery to normalize the soft and hard tissues of the face [16]. Thus, OS takes care of patients with moderate and severe facial deformities [17].

In this scenario, fat grafting is a powerful tool for corrections and also for facial aesthetic improvement together or after OS. The evolution of this technique is fascinating and has been described extensively [12]. At present, general standards of procedural practice are derived from the work of Sydney Coleman [14-18]. The benefits of fat grafting during orthognathic surgery; to maximize aesthetic results, minimize edema and optimize wound healing [12].

Also, Coleman defends the atraumatic collection and injection of adipose tissue, thus preserving the lip architecture. Such meticulous attention to the technique allows a better assessment of the grafted fat. The senior author implements these well-defined parameters for facial fat grafting in his practice. The authors claim that adipose tissue autotransplantation can be considered safe. The only study with the proper design, follow-up, and sample size to assess the safety of facial fat grafting claimed an infection rate of 4.8 percent and an overall complication rate of 13.6 percent [14,15]. A Cochrane systematic review suggested an expected infection rate of less than 2 percent in clean surgery [19].

Based on this information, this study aimed to analyze the main clinical studies on the benefits and risks of facial fat grafting in orthognathic surgery, to understand the current state of the art.

Methods

Study Design

This was followed by a systematic literature review model on the main clinical findings of mandible

fractures, according to the PRISMA rules [20].

Data sources and research strategy

The literary search process was carried out from July to September 2022 and was developed based on Scopus, PubMed, Science Direct, Scielo, and Google Scholar, using scientific articles from 1986 to 2022, using the descriptors (MeSH Terms): "*Orthognathic surgery. Lipografting. Fat grafting. Facial symmetry. Aesthetics*", and using the Booleans "and" between the descriptors (MeSH Terms) and "or" between the historical findings.

Study quality and risk of bias

The quality of the studies was based on the GRADE instrument [21], with randomized controlled clinical studies, prospective controlled clinical studies, and studies of systematic review and meta-analysis listed as the studies with the greatest scientific evidence. The risk of bias was analyzed according to the Cochrane instrument [22].

Results and Discussion

Quantitative and Qualitative of the findings and General Results

After the selectivity of articles and literary findings through the following descriptors orthognathic surgery, lipografting, fat grafting, facial symmetry, aesthetics, 123 studies were analyzed, with only 32 medium and high-quality studies selected, according to GRADE rules, and with risks of bias that do not compromise scientific development, based on the Cochrane instrument (Figure 1).

As a corollary to the exploration of the 32 studies, the treatment of dentofacial deformities is currently one of the most discussed fields in the area of Maxillofacial and Craniomaxillofacial Surgery, covering biological, pathophysiological, surgical, and anesthetic techniques, pre-and postoperative management, as well as craniofacial growth and development, facial harmony and aesthetics [23,24].

Figure 2 presents the results of the risk of bias in the studies using the Funnel Plot, through the calculation of the Effect Size (Cohen's Test). The sample size was determined indirectly by the inverse of the standard error. The number of clinical studies evaluated was n=32. The graph showed symmetric behavior, not suggesting a significant risk of bias in studies with small sample sizes, which are shown at the bottom of the graph.

Figure 1. Selection of studies.

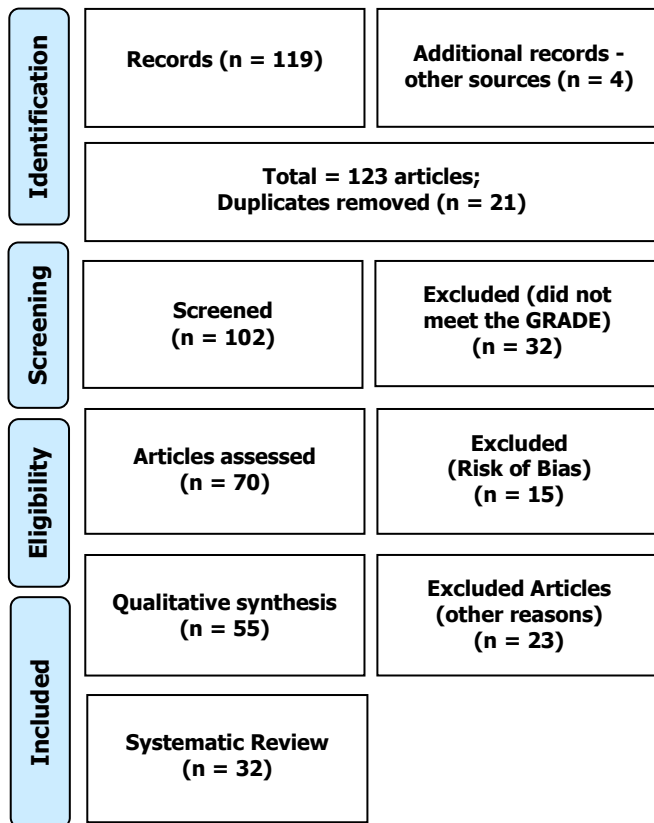
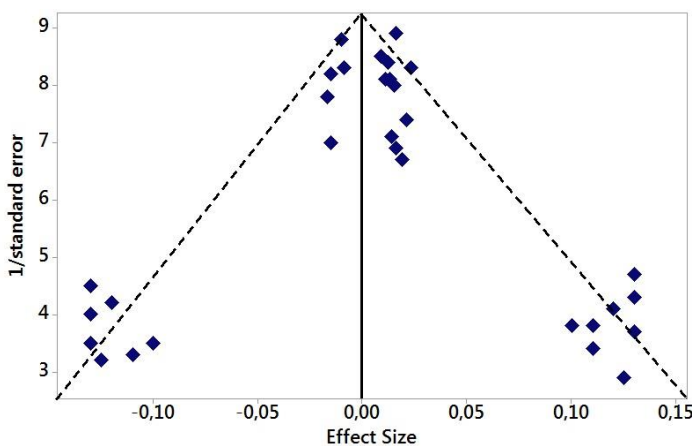


Figure 2. The symmetric funnel plot does not suggest a risk of bias between the small sample size studies that are shown at the bottom of the graph (N=32 studies).



In this sense, OS aims to establish harmonious facial aesthetics, excellent functional occlusion, and improvement in airway conditions. The correct diagnosis of malocclusion associated with skeletal deformity is essential for the indication of treatment, leading to multidisciplinary planning, which leads to an aesthetic and functional correction of the case, providing the patient with functional occlusion and facial harmony [12]. Still, maxillomandibular advancement surgery promotes anteroposterior, vertical, and lateral-lateral movement, due to the displacement of the bone bases to a new position, generating tension in the soft tissues

of the region, which can present significant changes in the facial appearance and pharyngeal space [25].

Therefore, the high prevalence of maxillary and mandibular joint deformities and a large number of combined surgeries of the maxilla and mandible seem to demonstrate the severity of the dentofacial deformities operated [26]. Individuals with class III dentofacial deformities are the ones who usually present greater aesthetic and functional impact, therefore they are the ones who most seek treatment [27]. Furthermore, more extensive surgical procedures generally carry a higher risk of complications and greater potential for healing and recovery [26,27].

In this context, and as an important adjuvant of OS, fat grafting is becoming more and more common due to its anti-inflammatory role and effects on facial volume increase. The results of one study showed that an average of 13.1 ccs of fat, which was collected from the lower abdomen or medial thigh, was injected into the patients' facial region, showing that none of the patients experienced complications in the area or wound healing and all patients reported high satisfaction with the results [12].

Fat volume can be efficiently harvested from most patients with a wide range of BMI using the atraumatic and economical techniques described above. Fat grafting after

OS is important to attenuate edema, as it hinders recovery [28-30]. Thus, one study looked at the use of fat graft, which was aspirated from the medial thigh or lower abdomen using the Coleman cannula in a 10 cc syringe, in a retrospective cohort of patients with fat graft versus patients without fat who underwent a bilateral Le Fort I sagittal split osteotomies [28,29]. Postoperative swelling resolved at week 12 in the fat graft group and persistent edema of 10.2%. Paracrine anti-inflammatory factors may contribute to these clinical outcomes [31].

Another publication from this same group examined the use of fat grafting in a cohort of patients with rhinoplasty for attenuation of postoperative edema [32], with a follow-up of up to 1 year. This cohort of 40 patients provided quantitative evidence to predict edema decrease over time, with nearly complete resolution within 1 year.

Still, other centers have shown similar results with fat grafting in patients undergoing OS, observing an improvement in the final aesthetic results and patient satisfaction [33,34]. There are also important results reported in the literature on fat grafting in cleft lip repair [35,36]. Furthermore, Clauser et al documented the aesthetic and functional benefits of facial fat grafting in patients who underwent OS or reconstruction due to facial trauma, facial burns, or congenital conditions

(cleft lip /Treacher Collins) [37-41], noting improvement in facial morphology, function, quality and skin texture in the majority of his patients.

In care and observation, not every fat graft is the same, and it is necessary to balance the efficiency of time and the effectiveness of the technique [42]. Emerging data on adipose biology suggest that there may be an optimal fat lobe size to maximize fat graft absorption, as well as a balance between preservation of vascular stromal fraction elements in small grafts and impaired diffusion with possible central necrosis in grafts larger warrant further study. Other authors advocate the use of cell-assisted lipotransfer containing adipose tissue-derived mesenchymal stem cells [43].

Still, other works show that the enrichment of fat grafts with autologous adipose stem cells improves the adherence and the size of the fat graft 121 days after implantation, being confirmed by magnetic resonance [44]. In this context, it is notorious to know that the lower abdomen and inner thigh may have higher liposuction processed adult mesenchymal stem cell concentrations [45].

In this sense, the best facial aesthetic results in the regenerative potential of stem cells derived from adipose tissue. Studies indicate that there are about 35 to 40% of stem cells are derived from adipose tissue per gram of fat [12]. In adipose liposuction, these stem cells are mixed with several other cell types, including pericytes, fibroblasts, endothelial cells, and preadipocytes as part of the vascular stroma fractions [46]. As such, Coleman has written extensively on the benefits of fat grafting, including improved skin quality, softening wrinkles, pore size, and attenuation of pigmentation and scar resolution [47,48]. Authors also analyzed through a study in the literature that the enrichment of liposuction with stem cells derived from the adipose tissue itself increases graft retention [49,50].

In this scenario, it is important to emphasize that they should include an accurate volumetric assessment of the skull and soft tissue before OS. When choosing a surgical strategy, the surgeon must consider not only traditional osteotomies but also soft-tissue improvement procedures such as lipofilling. Preoperative surgical planning systems, such as the virtual surgical planning protocol, are primarily based on predicting skeletal movement. Thus, a study described a new volumetric analysis process based on computed tomography (CT) for the quantification of autologous adipose tissue injected in patients who underwent simultaneous orthognathic and lipofilling procedures. Sixteen female patients were included in the study (mean age 24.5 years). The mean difference between the injected adipose tissue and that quantified after the operation

was 6.01 cm. All patients had clinically satisfactory facial convexity, with complete restoration of the contour of the cheekbones within 3 months [51].

Another retrospective cohort study with three-dimensional photos evaluated the effect of fat grafting on postoperative edema in OS, and also considered the impact of age and BMI. 130 postoperative three-dimensional photos of 31 patients were analyzed. The mixed linear model demonstrated that injected fat, age, and BMI are significant factors in postoperative volume. Age and BMI increase postoperative edema by 3.63 cm per year and 14.60 cm per kg/m, respectively. The injected fat reduces postoperative edema by 8.72 cm per 1 cc injected, accelerating the return to a steady-state [52].

Besides, another retrospective cohort study analyzed the effects of fat grafting on facial edema (magnitude, duration, and rate of decrease) in OS. One hundred and sixteen sets of pre-and post-operative three-dimensional photographic data were included. The sample included 29 subjects. Facial volume was analyzed in general and comparing each subgroup (orthognathic x orthognathic group + fat grafting). The increase in postoperative facial volume averaged 23.7% for the entire cohort. By week 12, the swelling had gone down to about 62% from baseline. In all patients, there was a significant decrease in facial volume over time. In the fat grafting group, despite adding volume, facial volume was the same as in the non-fat grafting group at week 1, but the rate of reduction was faster up to week 12 [53].

Also, authors evaluated, through a retrospective study, the effect of combining OS with autologous fat transfer in the treatment of patients with facial asymmetry. A total of 15 consecutive adults underwent combined OS and autologous fat transfer. Lower facial symmetry was greatly improved with the combination of OS and autologous fat injection. Therefore, the combined use of OS and autologous fat transfer is a promising technique to improve facial symmetry in patients [54].

Furthermore, a systematic review evaluated the effectiveness of autologous fat grafting on skin quality. Outcomes of interest were skin texture, color, and elasticity, in addition to histological outcomes and the number of complications. Nine studies were included, with 301 patients treated in total. Eight studies reported increased skin elasticity, improved skin texture, and a more homogeneous skin color after treatment with fat grafting, cellular stromal vascular fraction, or nano fat. Histological improvement was observed after fat grafting and injections of stromal cells derived from adipose tissue. No serious complications have been reported [55].

More authors with a retrospective cohort study described a series of consecutive patients undergoing OS with fat grafting. A total of fifty-three OS patients with concomitant fat grafting were reviewed. The cohort consisted of 20 men (37.7%) and 33 women (62.3%). Thirty-three patients (62.3%) underwent Le Fort I operations in conjunction with genioplasty and/or bilateral sagittal division osteotomies. Twenty-eight patients (52.8%) underwent second operations involving additional fat grafting. Most of these patients (15/28, 53.6%) received additional fat grafting during rhinoplasty. There were no complications in the donor area. The average amount of injected fat was 13.1 cc (5-25 cc). Follow-up was 1 year. Therefore, benefits in wound healing, better aesthetic results, and an anti-inflammatory effect were observed [12].

Conclusion

Most of the studies analyzed in this review study showed that fat grafting in orthognathic surgery is a safe and effective tool to improve wound healing, improve aesthetic results, present an anti-inflammatory effect and reduce edema.

Acknowledgement

Not applicable.

Funding

Not applicable.

Data sharing statement

No additional data are available.

Conflict of interest

The authors declare no conflict of interest.

Similarity check

It was applied by Ithenticate@.

About the License

© The authors (s) 2021. The text of this article is open access and licensed under a Creative Commons Attribution 4.0 International License.

References

1. Khojasteh A, Mohaghegh S. Orthognathic Surgery for Management of Gummy Smile. *Dent Clin North Am.* 2022 Jul;66(3):385-398. doi: 10.1016/j.cden.2022.02.003.
2. Zhang W, Yang H. Orthognathic Surgery in Invisalign Patients. *J Craniofac Surg.* 2022 Mar-Apr 01;33(2):e112-e113. doi: 10.1097/SCS.0000000000007968.
3. Seo HJ, Choi YK. Current trends in orthognathic surgery. *Arch Craniofac Surg.* 2021 Dec;22(6):287-295. doi: 10.7181/acfs.2021.00598. Epub 2021 Dec 20. PMID: 34974683; PMCID: PMC8721433.
4. Shaeran TAT, Samsudin AR. Temporomandibular Joint Ankylosis Leading to Obstructive Sleep Apnea. *J Craniofac Surg.* 2019 Jun 28. doi: 10.1097/SCS.0000000000005689.
5. Susarla SM, Mundinger GS, Kapadia H, Fisher M, Smartt J, Derderian C, Dorafshar A, Hopper RA. Subcranial and orthognathic surgery for obstructive sleep apnea in achondroplasia. *J Craniomaxillofac Surg.* 2017 Dec;45(12):2028-2034. doi: 10.1016/j.jcms.2017.09.028.
6. Jeong WS, Kim YC, Chung YS, Lee CY, Choi JW. Change in Posterior Pharyngeal Space After Counterclockwise Rotational Orthognathic Surgery for Class II Dentofacial Deformity Diagnosed With Obstructive Sleep Apnea Based on Cephalometric Analysis. *J Craniofac Surg.* 2017 Jul;28(5):e488-e491. doi: 10.1097/SCS.0000000000003761.
7. Ishida T, Manabe A, Yang SS, Watakabe K, Abe Y, Ono T. An orthodontic orthognathic patient with obstructive sleep apnea treated with Le Fort I osteotomy advancement and alar cinch suture combined with a muco-musculo-periosteal VY closure to minimize nose deformity. *Angle Orthod.* 2019 Jan 30. doi: 10.2319/052818-406.1.
8. American Association of Oral and Maxillofacial Surgeons (AAOMS). Clinical Paper. Criteria for Orthognathic Surgery. 2015. Available at: http://www.aaoms.org/images/uploads/pdfs/ortho_criteria.pdf Accessed January 5, 2017.
9. American Cleft Palate-Craniofacial Association. Parameters for evaluation and treatment of patients with cleft lip/palate or other craniofacial anomalies. March 1993. Revised November 2009. Available at: http://www.acpacpf.org/uploads/site/Parameters_Rev_2009.pdf Accessed in September 19, 2022.
11. Powell NB. Contemporary surgery for obstructive sleep apnea syndrome. *Clin Exp Otorhinolaryngol.* 2009 Sep;2(3):107-14.
12. Sato, F. R. L.; Mannarino, F. S.; Asprino, L.; De Moraes, M. Prevalence and treatment of dentofacial deformities on a multiethnic population: a retrospective study. *Oral and Maxillofacial Surgery*, 2014, v.18, p. 173-179.
13. Iyengar RJ, Gabrick K, Bruckman K, Steinbacher DM. Fat Grafting in Orthognathic Surgery. *J*

- Craniofac Surg. 2019 May/Jun;30(3):639-643. doi: 10.1097/SCS.0000000000005362. PMID: 30817538.
14. Foyatier JL, Mojallal A, Voulliaume D, et al. [Clinical evaluation of structural fat tissue graft (Lipostructure) in volumetric facial restoration with face-lift. About 100 cases]. *Ann Chir Plast Esthet* 2004;49: 437–455.
 15. Coleman SR. Structural fat grafting: more than a permanent filler. *Plast Reconstr Surg* 2006;118(3 suppl):108S–120S.
 16. Coleman SR. Structural fat grafts: the ideal filler? *Clin Plast Surg* 2001;28:111–119.
 17. Coleman SR. Long-term survival of fat transplants: controlled demonstrations. *Aesthetic Plast Surg* 1995;19:421–425.
 18. Illouz YG. The fat cell “graft”: a new technique to fill depressions. *Plast Reconstr Surg* 1986;78:122–123.
 19. Gir P, Brown SA, Oni G, et al. Fat grafting: evidence-based review on autologous fat harvesting, processing, reinjection, and storage. *Plast Reconstr Surg* 2012;130:249–258.
 20. Valente DS, Zanella RK. The Effects of Facial Lipografting on Skin Quality: A Systematic Review. *Plast Reconstr Surg*. 2020 Jul;146(1):92e-93e. doi: 10.1097/PRS.0000000000006941. PMID: 32590669.
 21. Moher D, Liberati A, Tetzlaff J, Altman DG, The PRISMA Group (2009) Preferred Reporting Items for Systematic Reviews and Meta-Analyses: The PRISMA Statement. *PLoS Med* 6(7): e1000097. <https://doi.org/10.1371/journal.pmed.1000097>.
 22. Balshem H et al. Grade guidelines: 3 rating the quality of evidence. *Journal of Clinical Epidemiology*, Maryland Heights, 2011, v. 64, n. 4, p. 401-406.
 23. Higgins J, Green S. *Cochrane Handbook for Systematic Reviews of Interventions*. Version 5.1.0 [updated March 2011]. The Cochrane Collaboration; 2011.
 24. Samman, N.; Tong, A. C.; Cheung, D. L.; Tideman, H. Analysis of 300 dentofacial deformities in Hong Kong. *The International Journal Of Adult Orthodontics And Orthognathic Surgery*, 1991, v. 7, n. 3, p. 181-185.
 25. Steinhäuser, E. W. Historical development of orthognathic surgery. *Journal of Cranio-Maxillofacial Surgery: official publication of the European Association for Cranio-Maxillofacial Surgery*, 1996, v. 24, n. 4, p. 195-204.
 26. Dyer, P. V. Experimental study of fractures of the upper jaw: a critique of the original papers published by Rene Le Fort. *Trauma*, 1999, v. 1, n. 1, p. 81-84.
 27. O'brien, K.; Wright, J.; Conboy, F.; et al. Prospective, multi-center study of the effectiveness of orthodontic/orthognathic surgery care in the United Kingdom. *American Journal of Orthodontics and Dentofacial Orthopedics*, 2009, v. 135, n. 6, p. 709-714.
 28. Bailey, L. J.; Proffit, W. R.; White, R. J. Assessment of patients for orthognathic surgery. *Seminars in Orthodontics*, 1999, v. 5, n. 4, p. 209-222.
 29. Phillips C, Blakey G 3rd, Jaskolka M. Recovery after orthognathic surgery: shortterm health-related quality of life outcomes. *J Oral Maxillofac Surg* 2008;66:2110–2115.
 30. Cabrejo R, DeSesa CR, Sawh-Martinez R, et al. Does fat grafting influence postoperative edema in orthognathic surgery? *J Craniofac Surg* 2017;28:1906– 1910.
 31. Cabrejo R S-MR, Steinbacher DM. Effect of fat grafting on postoperative edema after orthognathic surgery. *Plast Reconstr Surg*. 2019.
 32. Shih YC, Lee PY, Cheng H, et al. Adipose-derived stem cells exhibit antioxidative and antiapoptotic properties to rescue ischemic acute kidney injury in rats. *Plast Reconstr Surg* 2013;132:940e–951e.
 33. Pavri S, Zhu VZ, Steinbacher DM. Postoperative edema resolution following rhinoplasty: a three-dimensional morphometric assessment. *Plast Reconstr Surg* 2016;138:973e–979e.
 34. Raffaini M, Tremolada C. Micro fractured and purified adipose tissue graft (Lipogems()) can improve the orthognathic surgery outcomes both aesthetically and in postoperative healing. *CellR4* 2014;2:e1118.
 35. Raffaini M, Pisani C. Orthognathic surgery with or without autologous fat micrograft injection: preliminary report on aesthetic outcomes and patient satisfaction. *Int J Oral Maxillofac Surg* 2015;44:362–370.
 36. Zellner EG, Pfaff MJ, Steinbacher DM. Fat grafting in primary cleft lip repair. *Plast Reconstr Surg* 2015;135:1449–1453.
 37. Balkin DM, Samra S, Steinbacher DM. Immediate fat grafting in primary cleft lip repair. *J Plast Reconstr Aesthet Surg* 2014;67: 1644–1650.
 38. Clauser L, Polito J, Mandrioli S, et al. Structural fat grafting in complex reconstructive surgery. *J Craniofac Surg* 2008;19:187–191.
 39. Clauser LC, Consorti G, Elia G, et al. Three-dimensional volumetric restoration by structural fat grafting. *Craniofacial Trauma Reconstr* 2014;7:63–70.

- 40.** Clauser LC, Tieghi R, Consorti G. Parry-Romberg syndrome: volumetric regeneration by structural fat grafting technique. *J Craniofac Surg* 2010;38:605–609.
- 41.** Clauser LC, Tieghi R, Galie M, et al. Structural fat grafting: facial volumetric restoration in complex reconstructive surgery. *J Craniofac Surg* 2011;22:1695–1701.
- 42.** Consorti G, Tieghi R, Clauser LC. Frontal linear scleroderma: long-term result in volumetric restoration of the fronto-orbital area by structural fat grafting. *J Craniofac Surg* 2012;23:e263–265.
- 43.** Del Vecchio D, Rohrich RJ. A classification of clinical fat grafting: different problems, different solutions. *Plast Reconstr Surg* 2012;130:511–522.
- 44.** Yoshimura K, Sato K, Aoi N, et al. Cell-assisted lipotransfer for facial lipoatrophy: efficacy of clinical use of adipose-derived stem cells. *Dermatol Surg* 2008;34:1178–1185.
- 45.** Kolle SF, Fischer-Nielsen A, Mathiasen AB, et al. Enrichment of autologous fat grafts with ex-vivo expanded adipose tissue-derived stem cells for graft survival: a randomised placebo-controlled trial. *Lancet* 2013;382:1113–1120.
- 46.** Padoin AV, Braga-Silva J, Martins P, et al. Sources of processed lipoaspirate cells: influence of donor site on cell concentration. *Plast Reconstr Surg* 2008;122:614–618.
- 47.** Bellini E, Grieco MP, Raposio E. The science behind autologous fat grafting. *Ann Med Surg (Lond)* 2017;24:65–73.
- 48.** Brown SA, Levi B, Lequeux C, et al. Basic science review on adipose tissue for clinicians. *Plast Reconstr Surg* 2010;126:1936–1946.
- 49.** Rigotti G, Marchi A, Galie M, et al. Clinical treatment of radiotherapy tissue damage by lipoaspirate transplant: a healing process mediated by adipose-derived adult stem cells. *Plast Reconstr Surg* 2007;119:1409–1422.
- 50.** Zielins ER, Brett EA, Longaker MT, et al. Autologous fat grafting: the science behind the surgery. *Aesthet Surg J* 2016;36:488–496.
- 51.** Atashroo D, Raphel J, Chung MT, et al. Studies in fat grafting: Part II. Effects of injection mechanics on material properties of fat. *Plast Reconstr Surg* 2014;134:39–46.
- 52.** Lazzarotto A, Franz L, Stella E, Tel A, Sembronio S, Costa F, Bertossi D, Nocini R, Robiony M. Volumetric Analysis of Fat Injection by Computerized Tomography in Orthognathic Surgery: Preliminary Report on a Novel Volumetric Analysis Process for the Quantification of Aesthetic Results. *J Craniofac Surg*. 2019 May/Jun;30(3):771-776. doi: 10.1097/SCS.0000000000005305. PMID: 30807469.
- 53.** Cabrejo R, Sawh-Martinez R, Steinbacher DM. Effect of Fat Grafting on Postoperative Edema After Orthognathic Surgery. *J Craniofac Surg*. 2019 May/Jun;30(3):698-702. doi: 10.1097/SCS.0000000000005287. PMID: 30807474.
- 54.** Cabrejo R, DeSesa CR, Sawh-Martinez R, Steinbacher DM. Does Fat Grafting Influence Postoperative Edema in Orthognathic Surgery? *J Craniofac Surg*. 2017 Nov;28(8):1906-1910. doi: 10.1097/SCS.0000000000003821. PMID: 28906330.
- 55.** Wang YC, Wallace CG, Pai BC, Chen HL, Lee YT, Hsiao YC, Chang CS, Liao YF, Chen PK, Chen YR. Orthognathic Surgery with Simultaneous Autologous Fat Transfer for Correction of Facial Asymmetry. *Plast Reconstr Surg*. 2017 Mar;139(3):693-700. doi: 10.1097/PRS.0000000000003113.
- 56.** Van Dongen JA, Langeveld M, van de Lande LS, Harmsen MC, Stevens HP, van der Lei B. The Effects of Facial Lipografting on Skin Quality: A Systematic Review. *Plast Reconstr Surg*. 2019 Nov;144(5):784e-797e. doi: 10.1097/PRS.0000000000006147.

