

Cytarabine-related lung infiltrates on high resolution computerized tomography: a possible complication with benign outcome in leukemic patients

Potentially fatal lung toxicity occurs in 12-20% of leukemic patients treated with cytarabine especially at intermediate to high doses, usually presenting as noncardiogenic pulmonary edema (NCPE). Anecdotally the association between cytarabine and the onset of bronchiolitis obliterans organizing pneumonia (BOOP) has been reported. We describe here three cases of patients affected by acute myeloid leukemia (AML) treated with chemotherapeutic regimens including high dose cytarabine, who developed early onset of fever, mild dyspnea, moderate hypoxemia on arterial blood gas analysis and lung infiltrates documented by high-resolution computerized tomography (HRCT), with a more indolent behaviour and a benign clinical outcome, compared with similar cases previously reported in the literature. Our cases widen the spectrum of clinical features of cytarabine-related toxicity in leukemic patients.

Haematologica 2007; 92:(9)e85-e90 DOI: 10.3324/haematol.11697

Cytosine arabinoside, a pyrimidine nucleoside analogue introduced into clinical regimens for cancer therapy in 1964, is still one of the most effective drugs for the treatment of adult acute leukemia. The toxicity of cytarabine can be represented by either minor side effects like exanthema, fever and elevation of hepatic enzymes, that are relatively frequent, but rarely represent therapeutic problems or by major adverse effects, including myelosuppression, oral and gastrointestinal mucosal damage, keratoconjunctivitis and neurotoxicity, that can determine serious clinical problems, sometimes requiring the definitive interruption of treatment.^{1,2}

Several cancer therapeutic drugs are known to induce lung toxicity, which may result in a broad spectrum of clinico-pathologic syndromes with minor to severe consequences for the patient. Potentially fatal lung toxicity has been described in leukemia patients treated with cytarabine, especially at intermediate to high doses: this clinical entity, occurring in about 12-20% of patients, a median of 1-2 weeks (range 1-21 days) after chemotherapy, usually at initial course, has been defined as noncardiogenic pulmonary edema (NCPE).³⁻¹¹ It typically presents as a sub-acute syndrome characterised by severe dyspnea, cough, tachypnea, low grade fever, severe hypoxemia, crackles on thorax auscultation, and confluent alveolar consolidation on standard chest X-ray. Diagnosis of this drug-induced respiratory distress, also called acute lung injury, requires the exclusion of heart dysfunction and any infectious, metabolic or cancer-related causes.³⁻¹¹ Anecdotally, the association between administration of cytarabine and the onset of bronchiolitis obliterans organizing pneumonia (BOOP), has been reported. BOOP is an uncommon fibrotic diffuse lung disorder, histopathologically defined as granulation tissue plugging into the lumens of small airways, extending, in a continuous fashion,

into alveolar ducts and alveoli. It is generally characterised by subacute onset of respiratory symptoms resolving in the majority of cases (65-80%) with administration of steroids, but in other cases it may persist, with chronic and disabling cough and dyspnea, and may be life threatening, especially in the case of recurrence.¹²⁻¹⁶

We report here three cases of patients affected by acute myeloid leukemia (AML), treated with chemotherapeutic regimens including high dose cytarabine, who developed early onset of fever, mild dyspnea, moderate hypoxemia on arterial blood gas analysis, and lung infiltrates documented by high-resolution computerized tomography (HRCT). Issues of diagnosis and management of cytarabine related lung toxicity are discussed and differences in the clinical features between such cases and those reported in the literature are reviewed.

Case reports

A 53-year old female patient (case 1) was diagnosed as having AML M4 to cytochemical FAB classification and at intermediate risk for normal karyotype to WHO classification;^{17,18} she was randomized, according to GIMEMA (Gruppo Italiano Malattie Ematologiche dell'Adulto) AML-12 protocol (Arm 2) to receive high dose cytarabine (3 g/m² every 12 hours on days +1, +3, +5, +7) combined with daunorubicin (50 mg/m² on days +1, +3, +5), and etoposide (50 mg/m² on days +1 to +5) as a remission induction chemotherapeutic regimen. On day +2, after starting chemotherapy, the patient became febrile and presented dry cough; the chest X-ray was negative and the arterial blood gas analysis performed in room air was normal (pO₂ 74 mmHg), but an empirical antibiotic therapy with piperacillin-tazobactam was introduced because of severe leukopenia, being the WBC count 0.6x10⁹/L. Fever persisted up to day +6, raising to 40°C (Figure 1a), but the patient was asymptomatic and physical examination and vital signs were normal; though she had not dyspnea, a blood gas analysis was performed on day +6, consistent with moderate hypoxemia (pO₂ 57 mmHg). Thus, on the same day, she underwent HRCT, that showed bilateral pleural effusions and areas of patchy consolidations, prevalently on the left side (Figure 2a). Chemotherapy administration was stopped and a second line antibiotic therapy with meropenem and vancomycin was introduced, even though serological, cultural and molecular examinations (SCME) of biologic fluids (namely blood, urine, feces cultures, CMV and Aspergillus antigenemia, urinary Legionella antigen) did not disclose any infectious agent. Only 24 hours later, the patient became afebrile (Figure 1a), with a significant improvement of blood gas analysis (pO₂ 87 mmHg). The HRCT performed 72 hours after discontinuation of chemotherapy showed complete resolution of the pathological features described above (Figure 2b). The two last doses of cytarabine were not administered.

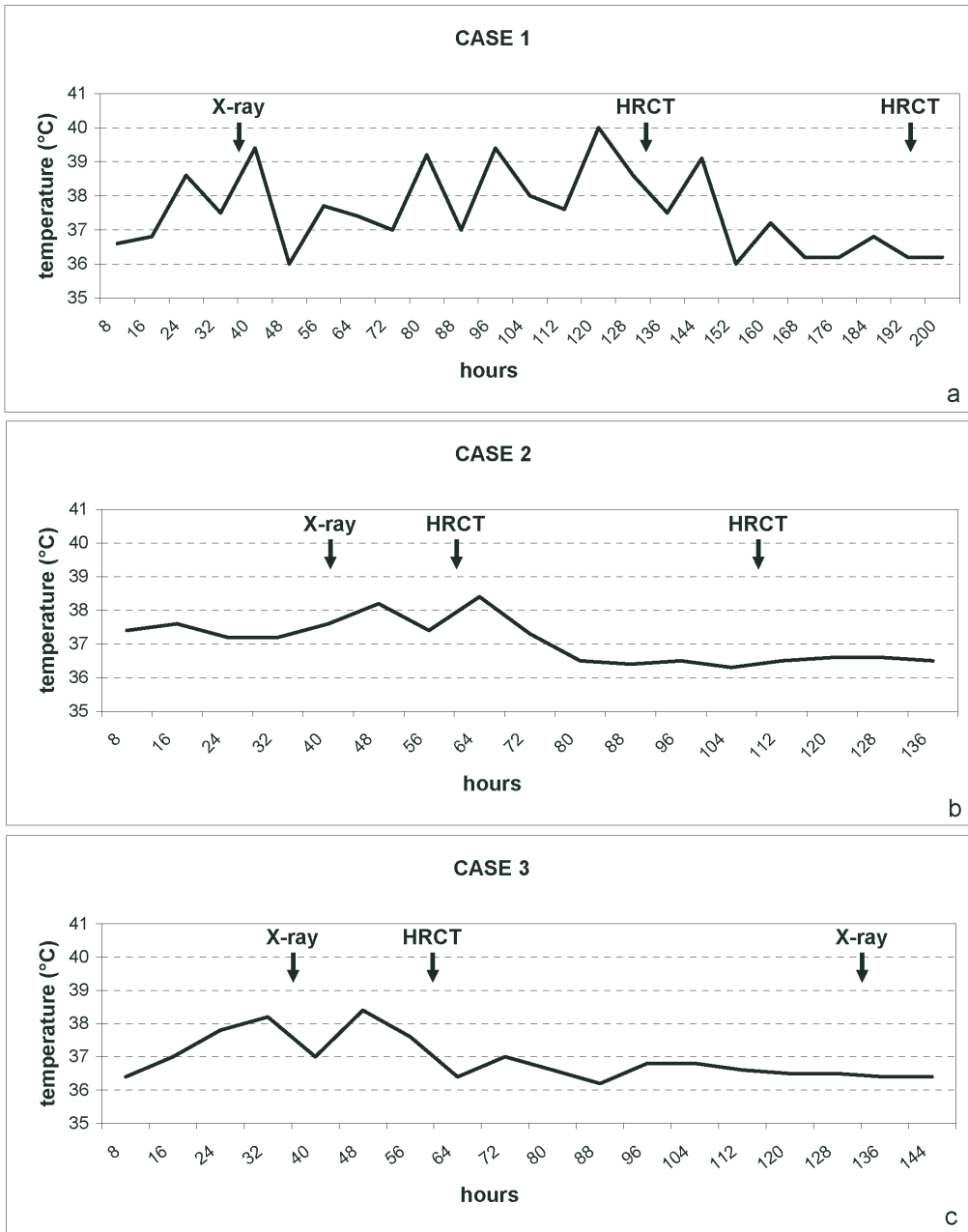


Figure 1. Fever charts of the three leukemic patients treated with high dose cytarabine. Graphs show onset and subsequent resolution of fever and the timing of radiological examinations (X-ray and HRCT), indicated by arrows (a,b,c). 0 hours indicate the start of administration of chemotherapy.

A 51-year old male patient (case 2), affected by AML M6 to FAB classification and at high risk for complex karyotype and multilineage dysplasia following the WHO classification,^{17,18} underwent remission induction chemotherapeutic regimen according to the same protocol previously reported, with high dose cytarabine at identical schedule. On day +2 after starting chemotherapy, he became febrile (temperature 38,4°C) (Figure 1b); he was asymptomatic and chest auscultation resulted normal but arterial blood gas analysis on room air showed mild hypoxemia (pO₂ 67 mmHg) and a small consolidation area in right para-hilar side was documented on chest X-ray examination. An empirical antibiotic therapy with piperacillin-tazobactam was introduced because of mild neutropenia being the neutrophil count

1.3x10⁹/L at onset of fever and, on day +3, a HRCT was performed, showing moderate bilateral pleural effusion, bilateral patchy consolidations and a nodular process in right para-hilar side, surrounded by ground-glass opacity (Figure 2c). Based upon these features, chemotherapy administration was temporarily stopped. Twenty four hours later, the patient became afebrile (Figure 1b) and the re-evaluation on HRCT, performed 48 hours after the discontinuation of chemotherapy (on day +5), showed a slight improvement of the pre-existing features, with the disappearance of pleural effusions and right basal patchy consolidation, and size reduction of the other lesions (Figure 2d). Since the radiological and clinical improvement, with negativity of SCME of biologic fluids (namely blood, urine, feces cultures, CMV and Aspergillus anti-

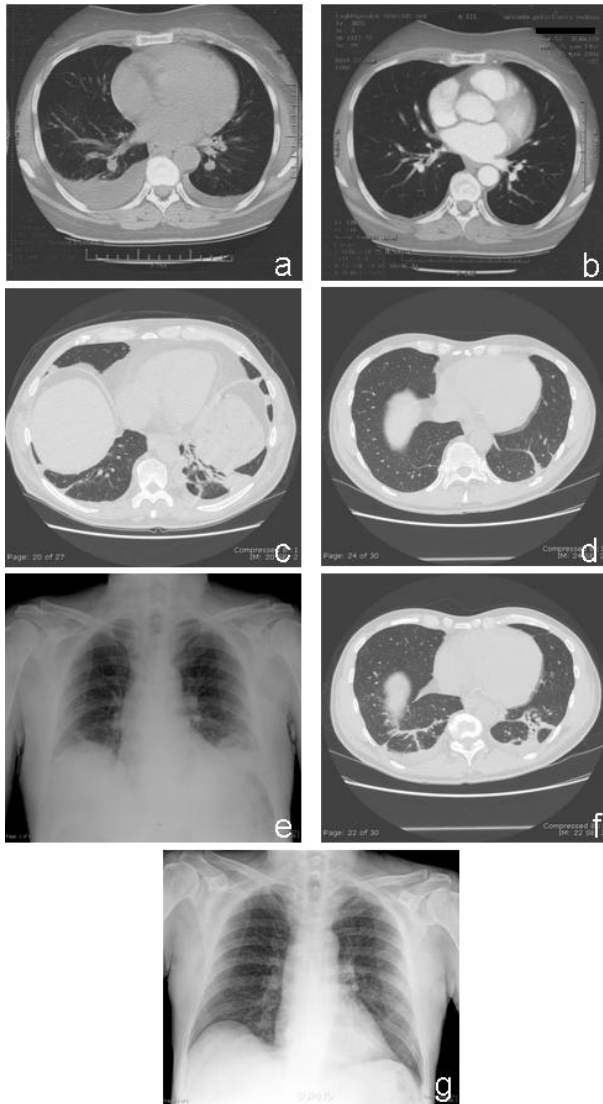


Figure 2. Radiological examinations in the three leukemic patients receiving high dose cytarabine. Early lung infiltrates in leukemic patients characterised by chest X-ray and/or HRCT (a,c,e,f); complete and spontaneous resolution in 48-72 hours (b,d,g).

genemia), chemotherapy administration was restarted on day +6, with pre-medication consisting of low dose dexamethasone (4 mg i.v.) prior to the administration of high dose cytarabine. The patient completed the chemotherapy cycle without either fever or respiratory symptoms.

A 66-year old male patient (case 3), receiving prophylaxis with isoniazide for a latent Tuberculosis infection documented by Quantiferon-TB serologic test, previously treated for AML with myelodysplastic features according to WHO classification,¹⁸ relapsed five months after autologous bone marrow transplantation. The patient was admitted to our Department in order to undergo a salvage chemotherapeutic regimen (FLAG) consisting of cytarabine (2 g/m² on days +1 to +5), fludarabine (30 mg/m² on days +1 to +3), G-CSF (5 mcg/kg/day from day

-1 to day +5). On day +1 the patient showed mild dyspnea and bilateral inspiratory crackles on chest auscultation, despite normal pO₂ on blood gas analysis. On day +2 after starting chemotherapy, he became febrile (temperature 38,4°C) (Figure 1c). Blood tests were consistent with a self-limiting disseminated intravascular coagulation in the absence of bleeding, probably due to leukemic cell lysis; blood gas analysis on room air documented moderate hypoxemia (pO₂ 62 mmHg) and chest X-ray showed a patchy consolidation in the left lower lobe and bilateral pleural effusions especially on the left side (Figure 2e). These features were confirmed by HRCT on day +3 (Figure 2f). An empirical antibiotic therapy with piperacillin-tazobactam was started, even though the patient was not neutropenic, being neutrophils 4.6x10⁹/L. SCME of biologic fluids (namely blood, urine, feces cultures, CMV and Aspergillus antigenemia) did not disclose any infectious agent. Furthermore the patient underwent bronchoscopy with bronchoalveolar lavage (BAL) but SCME resulted negative also on BAL samples, including tests for Mycobacterial infection. From day +3 the patient became afebrile (Figure 1c) and asymptomatic, without stopping administration of chemotherapy and a chest X-ray, performed 72 hours later, showed complete resolution of the radiological features described above (Figure 2g). The treatment protocols have been approved by our Institutional Ethics Committee, and all three patients have given written informed consent.

Discussion

We report here three patients, affected by AML, who developed fever, mild dyspnea, moderate hypoxemia on blood gas analysis, lung infiltrates, consisting of patchy consolidation areas and pleural effusions, documented either by chest X-ray or by HRCT, 24 hours after the administration of high dose cytarabine. The disappearance of symptoms and the complete resolution of radiological signs documented by HRCT were obtained in 48-72 hours, while drug administration was continued in one case, but delayed by 72 hours and stopped before the last dose in the two others, respectively. Cytarabine-induced lung toxicity is probably related to a cytokine-mediated mechanism involving tumor necrosis factor- α and platelet activating factor, which determine inflammatory response with alveolar damage and increased vascular permeability.¹⁹ Diagnosis of cytarabine-induced lung toxicity is an exercise of exclusion of several other causes of lung infiltrates, such as heart failure and metabolic dysfunctions (*renal failure, hypoalbuminemia, pancreatitis*),¹¹ leukemic infiltrates, even in absence of leukocytosis or peripheral blastosis,²⁰ and infectious causes,²¹ including bacterial and fungal agents, *Pneumocystis carinii*, and, although rarely, also viral infections.²² In our series, the above mentioned causes were excluded, and no infectious agents were disclosed by biologic fluid SCME (Table 1). On the other hand, the

prompt resolution of the febrile condition as well as the very early and complete disappearance of the radiological findings, as documented by HRCT, cannot be ascribed to the few day empirical antibiotic therapy.

The radiological signs in our three cases resemble

those typically detected in both NCPE and BOOP, which can be characterised by signs of alveolar or interstitial opacification, surrounded, sometimes, by ground glass areas, and pleural effusions. The real difference between our cases and those reported in the literature is in the

Table 1. Clinical evaluation of possible causes of lung infiltrates (cardiac or metabolic dysfunctions, infectious agents) other than cytarabine, in our three leukemic patients.

PATIENTS	Scme on biologic fluids	Echocardiogram before starting chemotherapy (EF %)	Ecg at presentation of symptoms	Renal function at presentation of symptoms Creatinine (mg/dL)	Albuminemia on the day before starting chemotherapy (g/dL)	Pancreatic enzymes (U/L)
Pt 1	Negative	Normal (70%)	Normal	Normal (0,84)	Normal (4,5)	Amilase 56, Lipase NA
Pt 2	Negative	Normal (60%)	Normal	Normal (0,85)	Normal (3,6)	Amilase 38 Lipase 18
Pt 3	Negative*	Normal (55%)	Normal	Normal (0,80)	Normal (3,9)	Amilase 16 Lipase NA

SCME indicates serological, cultural and molecular examination of biologic fluids (blood, urine, feces cultures, CMV and *Aspergillus* antigenemia). *These tests have been performed also on BAL specimens in Pt 3. EF %: ejection fraction. ECG: electrocardiogram. NA: Not Available. Normal values in Our Laboratory: Creatinine 0,6-1,4 mg/dL for male, 0,6-1,2 mg/dL for female; Albumine 3,5-5 g/dL; Amilase 1-100 U/L; Lipase 1-60 U/L.

Table 2. Revision of the clinical data available from cases of cytarabine-related lung toxicity, previously reported in the literature.

Reference	Patients presenting toxicity (N)	Median age (years) of patients (range)	Status of hematologic disease (N)	Cytarabine dosage	Median time (days) of onset of symptoms from start of chemotherapy (range)	Clinical outcome (N)
Haupt et al. 1981	10 early; 18 late occurrence	39 (1-85)	28 REL	Intermediate (7,5-30 mg/kg/day)	0-3; 4-30	28 deaths (autoptic data)
Andersson et al. 1985	16	35 (16-68)	16 REL	High (3 g/m ² every 12 hours for 4-12 doses)	16 (2-21)	15 recoveries, 1 death.*
Andersson et al. 1990	14	39 (22-66)	14 REL	High (3 g/m ² every 6 to 12 hours for 6 to 12 doses OR 3 g/m ² every 12 hours for 2 doses, followed by 1,5 g/m ² over 24 hours for 3-4 days)	8 (1-29)	4 recoveries, 10 deaths
Salvucci et al. 2000	2	14, 31	1 PR1 REL	High (4 g/day for 5 days)	1, 7	2 recoveries.*
Tham et al. 1987	15	29(15-57)	15 first line therapy	Intermediate (1 every 3 g/m ² 12 hours for 6 days) High (3 g/m ² every 12 hours for 4 days)	16 (8-20)	13 recoveries, 2 deaths.*
Jehn et al. 1988	7	40 (17-64)	7 REL/REF	Intermediate (1 g/m ² every 12 hours for 6 days) High (3 g/m ² every 12 hours for 4 days)	NA (1-14)	3 recoveries, 4 deaths
Shearer et al. 1994	5	NA (4-12)	5 REL	Intermediate/High (1.0-1.5 g/m ² over 24 hours for 5 days)	8 (3-38**)	2 recoveries, 3 deaths
Our cases 2007	3	53, 51, 66	2 first line therapy, 1 REL	High (3 g/m ² every 12 hours on day 1, 3, 5, 7 or 2 for g/m ² 5 days)	1	3 recoveries.*

*indicates that some patients of the series received corticosteroids. **indicate that one patient presented respiratory symptoms 38 days after the first course of cytarabine, but a second course had been already administered just before the onset of symptoms. N: number of cases; PR: partial remission; REL: relapsed; REF: refractory; NA: not available.

clinical features.^{11,14} All our patients developed a sudden onset of symptoms after starting receiving the drug, but, despite the severity of radiological findings, the symptoms have been quite smouldering, with mild dyspnea and moderate hypoxemia on blood gas analysis. Lung toxicity appeared self limiting, neither requiring the drug discontinuation nor the corticosteroid infusion in case 3, while only low dose dexamethasone was administered to prevent fever in case 2. This clinical behaviour clearly differs from the clinical course in cases of NCPE, a potentially fatal lung toxicity, with abrupt onset of severe symptoms and which, if not fatal, can be reversed only with discontinuation of the administration of cytarabine and immediate start of intensive support treatment, including high dose systemic steroids, mechanical ventilation and pressure support.¹¹ On the other hand, the clinical course in our cases also differs from that in cases of BOOP, in which spontaneous, slow improvement occurs occasionally, but often corticosteroid treatment is required. In the latter instance the response to corticosteroids is impressive, because clinical manifestations improve within 48 hours, but complete resolution of radiographic pulmonary infiltrates takes several weeks.¹⁴⁻¹⁶

There are no evident epidemiologic differences between our three patients and the previously reported patients in the literature regarding either age or dosage of cytarabine. Most of the reported patients were affected with relapsed leukemia (Table 2), so that we cannot exclude that heavily pre-treated patients could be more exposed to a possibly severe lung toxicity. From the review of the literature, it appears that cytarabine-related lung toxicity occurs more frequently in patients with relapsed leukemia (72 out of 90 reported cases), than in patients with *de novo* leukemia (18 out of 90 patients). In the former patient group, a more severe, often fatal, course is observed (46 out of 72 patients); in the latter group, only 2 out of 18 patients died from lung toxicity. Of note, while most of the reported patients underwent standard chest X-ray examinations, our patients underwent HRCT at a very early phase, which probably allowed us to better characterise severe radiological findings, in the absence of a corresponding severity of clinical symptoms. Thus, the incidence of cytarabine-related lung infiltrates may be underestimated, so that we recommend the early performance of HRCT in leukemic patients treated with intermediate to high dose cytarabine at onset of respiratory symptoms, even if of mild entity. As far as the therapeutic approach to patients with cytarabine-related lung toxicity is concerned, it is not possible to define a formal management guideline, simply based on our observations and on the revised data from the literature. Decisions about definitive discontinuation of cytarabine or introduction of systemic steroid therapy, that could determine dramatic improvement and favorable outcome, also in the most critical patients,^{11,23} should be based upon a careful evaluation of the clinical status (respiratory symptoms, fever, blood

gas analysis and state of hematologic disease). The role of corticosteroids or any other therapeutic support in this clinical setting should be evaluated in clinical trials. However, the reported high incidence of cytarabine-related lung toxicity in relapsed leukaemia patients, may suggest to introduce pre-medication with low dose dexamethasone in this patient subgroup.

In conclusion, cytarabine-related toxicity should be considered among the possible causes of lung infiltrates in patients with leukemia, also in neutropenic phase.^{7,9,10} The clinical entity we report in our three patients is characterised by a more indolent behaviour and a benign clinical outcome, compared with previously reported similar cases. Our case descriptions widen the spectrum of clinical features of cytarabine-related toxicity which might be encountered in leukemic patients.

F. Forghieri, M. Luppi *, M. Morselli, L. Potenza, F. Volzone, G. Riva, A. Imovilli, E. Rivolti, G. Torelli

Department of Oncology and Hematology, Section of Hematology, University of Modena and Reggio Emilia, Modena, Italy

Correspondence: M. Luppi, Department of Oncology and Hematology, Policlinico, Modena, Italy. Tel: +39.059.4224641; Fax: +39.059.4224549. E-mail: mluppi@unimore.it

Acknowledgements. We are indebted to Dr Patrizia Barozzi, for her precious support in preparing figures and assembling the paper.

Key words: cytarabine, lung infiltrates, leukemia, HRCT

References

- Barrios NJ, Tebby CK, Freeman AI, Brecher ML. Toxicity of high dose Ara-C in children and adolescents. *Cancer* 1987; 60:165-9.
- Stentoft J. The toxicity of cytarabine. *Drug Saf* 1990; 5:7-27.
- Haupt HM, Hutchins GM, Moore GW. Ara-C lung: non cardiogenic pulmonary edema complicating cytosine arabinoside therapy of leukemia. *Am J Med* 1981; 70:256-61.
- Andersson BS, Cogan BM, Keating MJ, Estey EH, McCredie KB, Freireich EJ. Subacute pulmonary failure complicating therapy with high-dose Ara-C in acute leukemia. *Cancer* 1985; 56:2181-4.
- Andersson BS, Luna MA, Yee C, Hui KK, Keating MJ, McCredie KB. Fatal pulmonary failure complicating high-dose cytosine arabinoside therapy in acute leukemia. *Cancer* 1990; 65:1079-84.
- Kopterides P, Lignos M, Mentzelopoulos S, Armaganidis A, Pappa V. Cytarabine-induced lung injury: case report. *Anticancer Drugs* 2005; 16:743-5.
- Salvucci M, Zanchini R, Molinari AL, Zuffa E, Poletti V, Poletti G, et al. Lung toxicity following fludarabine, cytosine arabinoside and mitoxantrone (FLAN) treatment for acute leukemia. *Haematologica* 2000; 85:769-70.
- Tham RT, Peters WG, de Bruine FT, Willemze R. Pulmonary complications of cytosine-arabinoside therapy: radiographic findings. *Am J Roentgenol* 1987; 149:23-7.
- Jehn U, Goldel N, Rienmuller R, Wilmanns W. Non-cardiogenic pulmonary edema complicating intermediate and high-dose Ara C treatment for relapsed acute leukemia. *Med Oncol Tumor Pharmacother* 1988; 5:41-7.
- Shearer P, Katz J, Bozeman P, Jenkins J, Laver J, Krance R et al. Pulmonary insufficiency complicating therapy with high dose cytosine arabinoside in five pediatric patients with relapsed acute myelogenous leukemia. *Cancer* 1994; 74:1953-8.
- Briasoulis E, Pavlidis N. Noncardiogenic pulmonary edema: an unusual and serious complication of anticancer therapy. *Oncologist* 2001; 6:153-61.
- Patel M, Ezzat W, Pauw KL, Lowsky R. Bronchiolitis obliterans organizing pneumonia in a patient with chronic myelogenous leukemia developing after initiation of interferon and cytosine arabinoside. *Eur J Haematol* 2001; 67:318-21.
- Battistini E, Dini G, Savioli C, Morando A, Gandolfo A, Kotitsa Z, et al. Bronchiolitis obliterans organizing pneumonia in three children with acute leukaemias treated with cytosine

- arabinoside and anthracyclines. *Eur Respir J* 1997; 10:1187-90.
14. Cordier JF. Organizing pneumonia. *Thorax* 2005; 55:318-28.
 15. Epler GR, Colby TV, McLoud TC, Carrington CB, Gaensler EA. Bronchiolitis obliterans organizing pneumonia. *N Engl J Med* 1985; 312:152-8.
 16. King TE. Clinical Advances in the Diagnosis and Therapy of the Interstitial Lung Disease. *American Journal of Respiratory and Critical Care Medicine* 2005; 172:268-79.
 17. Grimwade D, Walker H, Oliver F, Wheatley K, Harrison C, Harrison G et al. The importance of diagnostic cytogenetics on outcome in AML: analysis of 1,612 patients entered in MRC AML 10 trial. The Medical Research Council Adult and Children's Leukemia Working Parties. *Blood* 1998; 92:2322-33.
 18. Vardiman JW, Harris NL, Brunning RD. The World Health Organization (WHO) classification of the myeloid neoplasms. *Blood* 2002; 100:2292-302.
 19. Chiche D, Pico JL, Bernaudin JF, Chouaib S, Wollman E, Arnoux A, et al. Pulmonary edema and shock after high-dose aracytine-C for lymphoma; possible role of TNF-alpha and PAF. *Eur Cytokine Netw* 1993; 4:147-51.
 20. Potenza L, Luppi M, Morselli M, Tonelli S, D'Apollo N, Facchini L, et al. Leukaemic pulmonary infiltrates in adult acute myeloid leukaemia: a high-resolution computerized tomography study. *Br J Haematol* 2003; 120:1058-61.
 21. Heussel CP, Kauczor HU, Heussel GE, Fisher B, Begerich M, Mildnerberger P, et al. Pneumonia in febrile neutropenic patients and in bone marrow and blood stem-cell transplant recipients: use of high-resolution computed tomography. *J Clin Oncol* 1999; 17:796-805.
 22. Ferrari A, Luppi M, Potenza L, Riva G, Morselli M, Imovilli A, et al. Herpes simplex virus pneumonia during standard induction chemotherapy for acute leukemia: case report and review of literature. *Leukemia* 2005; 19:2019-21.
 23. Larouche G, Denault A, Prenovault J. Corticosteroids and serious cytarabine-induced pulmonary edema. *Pharmacotherapy* 2000; 20:1396-9.