

# We are IntechOpen, the world's leading publisher of Open Access books Built by scientists, for scientists

6,100

Open access books available

149,000

International authors and editors

185M

Downloads

Our authors are among the

154

Countries delivered to

TOP 1%

most cited scientists

12.2%

Contributors from top 500 universities



WEB OF SCIENCE™

Selection of our books indexed in the Book Citation Index  
in Web of Science™ Core Collection (BKCI)

Interested in publishing with us?  
Contact [book.department@intechopen.com](mailto:book.department@intechopen.com)

Numbers displayed above are based on latest data collected.  
For more information visit [www.intechopen.com](http://www.intechopen.com)



## Chapter

# Cardiovascular Complications Related to Lower Limb Revascularization and Drug-Delivering Technology in Peripheral Arterial Disease

*Saritphat Orrapin*

## Abstract

The cardiovascular complication related to lower limb revascularization is the common cause of mortality in patients with peripheral arterial disease (PAD). The coexisting multisite atherosclerotic vascular disease is increasing risk of major adverse cardiovascular events (MACE). The minimally invasive approach for revascularization, namely, endovascular-first strategy for decreasing risk of intervention is the modern approach. The novel technology of the drug delivering device by paclitaxel, sirolimus, and other antiproliferative drug coated balloon (DCB) and drug eluting stent (DES) to increase the patency of the target artery are trending to use in patients with CLTI. However, the long-term result and safety of a drug delivering device are still controversial. The paclitaxel related to MACE and major adverse limb events (MALE) need to be investigated. The new drug coating balloon, sirolimus demonstrated the excellent short-term result. However, there are some limitations of previous randomized studies and meta-analyses to conclude the best strategy and device to perform the best result for revascularization without increasing risk of MACE and MALE in CLTI patients who candidate for revascularization. This article is summarized the pathophysiology of MACE and MALE in the patients with PAD during revascularization, paclitaxel related cardiovascular complications and sirolimus coated balloon.

**Keywords:** major adverse cardiovascular events, MACE, peripheral arterial disease, PAD, chronic limb-threatening ischemia, CLTI, drug delivering technology, drug coated balloon, DCB, drug eluting stent, DES, paclitaxel, sirolimus coated balloon

## 1. Introduction

Peripheral arterial disease (PAD) is a chronic condition in which stenosis or occlusion of the peripheral arteries [1–3]. The scopes range from the arteries that feed the brain are the carotid artery and the vertebral artery, the upper extremity arteries, the mesenteric arteries, the renal arteries, and the lower extremity arteries [1, 2, 4]. The PAD is primarily

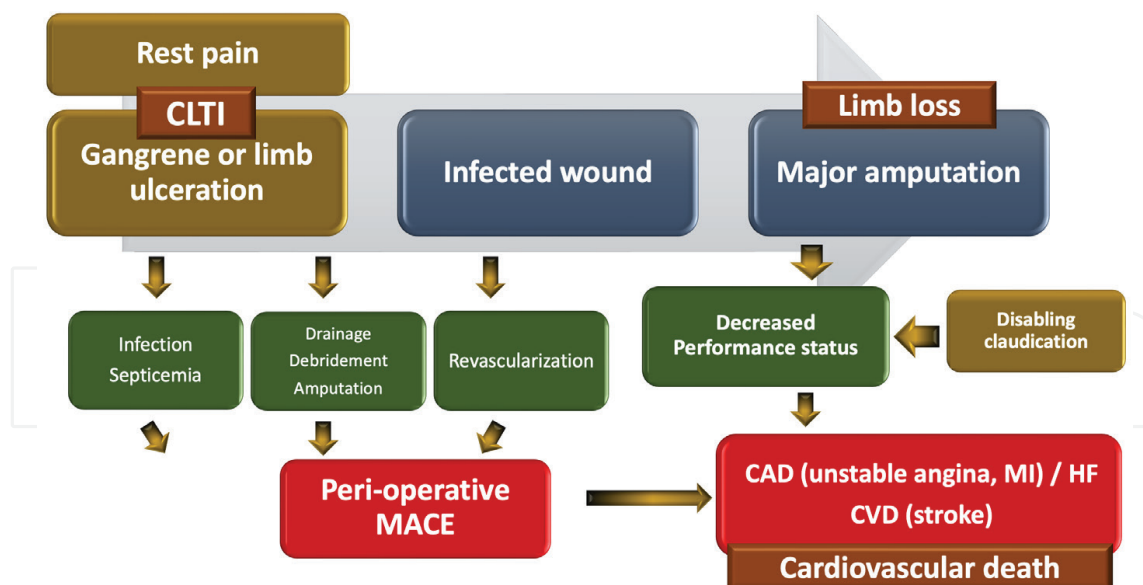
caused by the systemic atherosclerosis [5, 6]. There are other causes of PAD, such as thromboangiitis obliterans (TAO) or Buerger's disease, chronic arterial embolism, arterial entrapment, fungal arteritis, Takayasu's disease, inflammatory arterial disease from other causes such as polyarteritis nodosa (PAN) or other uncommon arteriopathies such as drug-induced arteriopathy [7], exercise-related external Iliac arteriopathy, radiation arteritis, fibromuscular dysplasia (FMD), vasculitis secondary to connective tissue diseases), such as rheumatoid arthritis, systemic lupus erythematosus (SLE), etc. [1, 8, 9].

The PAD of the lower extremity or lower extremity arterial disease (LEAD) due to atherosclerosis is a common disease in patients over the age of 60 years [2, 10, 11]. Males having a 1–2 times higher risk of developing PAD than females [1]. There have been 200 million cases of PAD worldwide, with a prevalence in 13–28%. The prevalence rate is expected to be underestimate due to a lack of screening system, which makes it impossible to document the exact number of patients in the group who have no symptoms or have minor symptoms [1–3]. In addition, a half of patients presenting with gangrene and ischemic ulcer of lower limb have no prior document of PAD [3]. According to previous publications data, the presentation of PAD is not typical. 50% of PAD patients are asymptomatic, In addition, among diabetics mellitus (DM) with PAD, have no symptoms of up to 80%. 15% of PAD patients are intermittent claudication. Only 1–3% of PAD patients are chronic limb-threatening ischemia (CLTI) which is a clinical syndrome of the PAD in combination with rest pain, gangrene or lower limb ulceration [3, 12, 13].

The major cause of death in patients with PAD is a cardiovascular disease. A cerebrovascular disease (CVD) and coronary artery disease (CAD) lead to high mortality rates for LEAD patients [14, 15]. The 5-year mortality rate of diagnosed PAD patients is 10–15%. Three-quarters of mortality group are fatal stroke and myocardial infarction (MI). For CLTI patients, the mortality rate is increasing to 25% with 4.5% of fatal stroke and 6.5% acute MI [16]. Thus, the four-point major adverse cardiovascular events (MACE) including acute MI, stroke, cardiovascular mortality, hospitalization for unstable angina or revascularization procedures is an increasingly primary outcome of interest in PAD. Recently, five-point MACE further expands on this with the inclusion of heart failure (HF) [3, 17, 18].

The PAD patients who need to revascularization of lower extremity artery include (1) CLTI which associated with increased mortality, risk of amputation, and impaired quality of life. (2) Disabling claudication patients who have limitation of daily activity and impaired quality of life due to their symptom [3, 13, 17]. All of them are risk of MACE during hospitalization for lower limb procedure such as revascularization, debridement, and amputation. MACE is rapid increasingly during perioperative period due to the stress from the foot infection or active comorbid disease and risk of the anesthesia and operation including revascularization (open vascular bypass, endovascular treatment) as well as amputation. Moreover, the poor performance status which occurred in patients who loss of ambulatory state due to non-functional limb, amputation, limb ulceration, gangrene, rest pain or disabling claudication are increased risk of MACE (**Figure 1**). The Society for Vascular Surgery (SVS) Objective Performance Goals (OPGs) established standardized tools for report benchmark of perioperative outcome including MACE and major adverse limb events (MALE) after revascularization procedures in patients with CLTI. The major adverse limb events (MALE) include major amputation of the revascularized limb and reintervention [19, 20].

Over the past decade, revascularization procedure for treating both simple and complex lower extremity arterial occlusive disease in a minimally invasive fashion



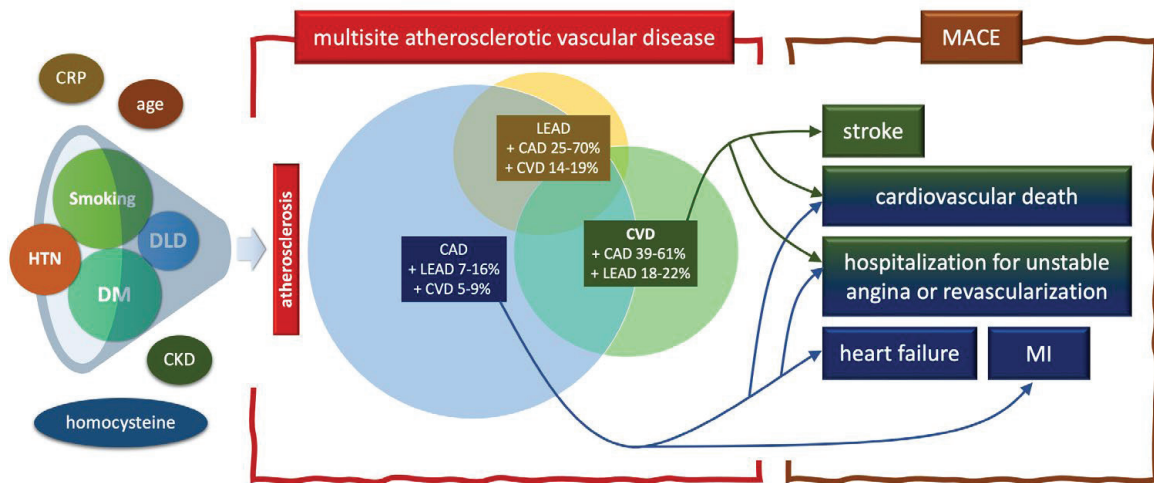
**Figure 1.** The pathologic process of amputation and MACE during hospitalization in patients with PAD. CAD, coronary artery disease; CLTI, chronic limb-threatening ischemia; CVD, cerebrovascular disease; HF, heart failure; MACE, major cardiovascular events; MI, myocardial infarction; PAD, peripheral arterial disease.

have increased significantly and induce some to support an “endovascular-first strategy” for most patients with PAD who candidate for revascularization [3, 13]. Most of the endovascular treatment (ET) in CLTI is a minimally invasive intervention which can perform under local anesthesia, which decreased the risk of general anesthesia, especially in multiple co-morbidities patients who cannot tolerate the major operation. In addition, ET can avoid the surgical wound complication and adjacent tissue injury. The length of hospital stay is also decreased in CLTI patients who performed ET when compare with open vascular bypass procedures.

Recently, the novel technology developed the antiproliferative agent -coated and -eluting device which can deliver the drugs to the vessel wall to limit the neointimal growth within de novo vascular system and stent [21–26]. However, some literatures report the MACE, aneurysmal degeneration, vascular fibrinoid necrosis, small vessel inflammation, and budget impact after drug technology device including drug coated balloon (DCB) and drug eluting stent (DES) in patients with ET [27–31]. The long-term MACE after DCB and DES device usage in patients with CLTI is still controversy [30, 32, 33]. This chapter describes the fundamental pathophysiology of MACE related to revascularization in patients with PAD and summarizes the most current data to guide an appropriate strategic treatment with drug-delivering technology under the risk and benefit assessment for ET in CLTI patients.

## 2. Pathophysiology of MACE related to PAD and atherosclerotic risk factors

In patients with diagnosed PAD, the risk of MACE appears to be greater than patients without PAD [3, 14]. The major atherosclerotic risk factors including DM, hypertension, dyslipidemia, and smoking are increased the MACE due to the atherosclerotic involvement of arterial system in vascular beds that affect blood supply to the target organs (Figure 2).



**Figure 2.**

*The relationship between atherosclerotic risk factors and major adverse cardiovascular events with overlap in multisite atherosclerotic vascular disease. HTN, hypertension; DM, diabetes mellitus; DLD, dyslipidemia; CKD, chronic kidney disease; CRP, C-reactive protein; CAD, coronary artery disease; LEAD, lower extremity arterial disease; CVD, cerebrovascular disease; MACE, major cardiovascular events; MI, myocardial infarction.*

The metabolic abnormality in patients with DM lead to hyperglycemia, insulin resistance, and increasing of free fatty acid. Three fundamental dysmetabolism process led to endothelial dysfunction and atherosclerosis [34]. Hyperglycemia increases the oxidative stress by increasing of reactive oxygen species (ROS). In addition, the cellular mitogenic pathway activation through the mitochondrial generation of the superoxide anion including advanced glycation end products (AGEs), protein kinase C (PKC) activation, and nuclear factor kappa B (NF- $\kappa$ B) are induced by high blood glucose level. In patients with long duration DM, insulin resistance cause endothelial dysfunction, decreasing of nitric oxide (NO) synthase, expression of adhesion molecules, and atherosclerotic lesions [34]. In addition, a thrombosis risk in DM is increasing though the hypercoagulation and platelet aggregation. The elevation of plasminogen activator inhibitor 1 (PAI-1), tissue factors and decreasing of NO are promoting coagulation cascade and platelet activation. Finally, insulin resistance is also promoted atherosclerotic process due to lipid metabolism disturbance such as high triglycerides (TG), high apolipoprotein B (ApoB), small and dense low-density lipoprotein (LDL), low high-density lipoprotein (HDL) cholesterol [35–37].

In early atherosclerotic process, the endothelial dysfunction is associate with hypertensive patients. A reduction in NO result in a reduced vasodilatory response, and result in an inflammation, thrombosis, and activate coagulation cascade [34, 38, 39]. The repetitive blood pressure alterations in patients with hypertension cause ongoing renin-angiotensin system activation. Angiotensin II, the product of renin-angiotensin system is a potent vasoconstrictor has an impact on the atherosclerotic lesions [35–37]. In the setting of dyslipidemia, a foam cell which is an intracellular droplets of cholesterol ester are occurred under the high LDL and low HDL in peripheral blood. The damaged endothelial of vessel wall cause the foam cells adhere and migrate into the intima layer and developed macrophages. The ongoing thickening of the intima by foam cell is developed after the vascular smooth muscle cell (VSMC) proliferates above the endothelial damaged area until the fibrous cap formation to create the atherosclerotic plaque [40].

Smoking causes an inflammation of vessel wall which related to atherosclerotic plaque formation through interleukin-6, tissue necrosis factor- $\alpha$ , interleukin-1- $\beta$ , leukocyte, C-reactive protein (CRP), and other inflammatory markers [34, 38, 39]. The endothelial dysfunction by the increasing of ROS productions through the reduction of NO, and activation of enzymes are present in smoker patients. In addition, the prothrombotic state of platelet activation and aggregation are create by increasing of thromboxane A2 (TXA2), von Willebrand factor (vWF), thrombin, fibrin and decreasing of prostacyclin, antithrombotic, and fibrinolytic substances (PAI-1) [35–37].

The atherosclerosis of lower extremity artery is systemic disease which involved other vascular beds that affect blood supply to the cardiac and brain (**Figure 2**). So, it is usually that the LEAD, CAD, and CVD commonly occur together (**Figure 2**). So, the presence of lower extremity stenosis/occlusion is associated with an increased risk of stenosis/occlusion of coronary artery, carotid and vertebrobasilar arterial system which is clinically presented by MI and stroke [3, 14]. 25–70% and 14–19% of patients who present with LEAD often coexists with CAD and CVD, respectively. Conversely, only 7–16% and 18–22% of patients with CAD and severe carotid stenosis are coexists with LEAD, respectively [35]. Patients with severe LEAD which indicate by ankle brachial index (ABI) <0.4 or severe atherosclerosis on anatomic distribution by Trans-Atlantic Inter-Society Consensus for the management of PAD (TASC II) exhibit more extensive calcified and progressive coronary atherosclerosis [14, 35]. Therefore, the MACE is categorized into two fundamental parts including CAD and CVD based on vascular bed involvement which focus on the morbidity (stroke, MI, HF) and mortality (fatal stroke and fatal MI) (**Figure 2**). Currently, updated MACE is expanded to five-point including acute MI, stroke, hospitalization for unstable angina or revascularization procedures, HF, and cardiovascular mortality [3, 4, 14, 35, 36].

The risk of ongoing development to CLTI appears to be greater in patients who have a pre-existing CAD and CVD such as history of stroke, MI or HF. Comparing with PAD, patients with CLTI have a higher risk of MACE and premature death due to cardiovascular disease. In patients with developed CLTI, the risk of amputation and mortality rate is extremely increased to 30% and 25%, respectively [3, 14, 35]. For this reason, treatment of patients with CLTI is not only revascularization to salvage a functional limb but also aggressive best medical treatment to reduce MACE. The medical management of patients with PAD including atherosclerotic risk factors modification, statin therapy and antiplatelet therapy for symptomatic PAD can decreased risk of development of CLTI and overall prognosis for patients with PAD [3, 13].

### **3. Pathophysiology of MACE related to revascularization procedure in patients with CLTI**

Almost CLTI patients need to be revascularization to salvage a functional limb and improve the quality of life [14, 35, 39]. Because the risk of perioperative MACE and other coexisting co-morbidities, some patients who indicate for limb revascularization are not candidate to perform the operation. Although, the novel medical technology including ET, medical risk optimization, the intensive care knowledge is significantly developed during the last century. The poor functional capacity and multiple co-morbidities patients are still very high risk of perioperative MACE during revascularization [3, 18, 37]. Active cardiac condition (including acute coronary syndrome including unstable angina (UA), non-ST elevation MI (NSTEMI) and

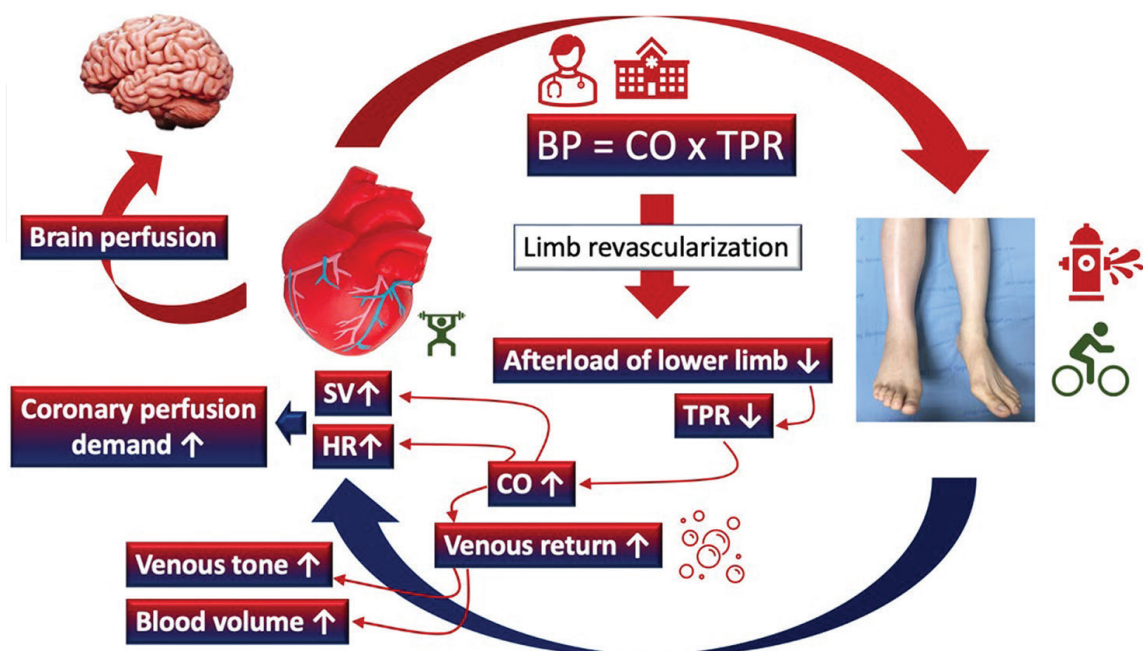
ST-elevation MI (STEMI) as well as symptomatic carotid stenosis are usually need for coronary and carotid revascularization before lower limb revascularization [3, 4, 14, 18, 35, 37, 39].

In healthy people, the systemic organs are functioning in parallel and simultaneously. The consequences of the organ functioning including (1) the stroke volume which is ejected from the heart and feeding to the various organs before entering the capillaries and venous system of the organ, (2) the arterial blood feeding each organ has the same composition, (3) the blood pressure at the entrance to each organ is the same, and (4) the blood flow to each organ can be controlled independently (local regulation of blood flow, namely, “autoregulation”) [3, 41, 42]. The autoregulation is the human body physiologic response of functional hyperemia to maintain the blood flow to the vascular bed of the vital end-organ such as brain, kidney. The responsibility of the human body physiologic alteration and autoregulation after revascularization are impact to the incidence of perioperative MACE in patients with CLTI.

Physiologic changes and the autoregulation process after revascularization procedure by decreasing afterload (peripheral vascular resistance) are the burden to cardiovascular system. The cardiac reserve and response after lower limb revascularization, the anatomic distribution and severity of lower limb arterial occlusive disease as well as the type of revascularization are determining the risk of perioperative MACE [14, 37, 43].

### 3.1 Cardiac reserve and response after lower limb revascularization related to MACE

The blood flow rate which feed to the end organs are determined by the cardiovascular system. Each organ can adjust their vascular resistance or afterload which maintaining the blood flow and pressure to their vascular bed by the autoregulation mechanisms. Therefore, revascularization procedures which result in the reduction of afterload rapidly are significantly increased blood flow to the lower



**Figure 3.** The normal physiologic changes of cardiovascular system and cardiac response after lower limb revascularization. BP, blood pressure; CO, cardiac output; TPR, total peripheral resistant; SV, stroke volume; HR, heart rate.

extremities [39, 42, 43]. The preoperative cardiac reserve and cardiac response after lower limb revascularization are the important risk factors of perioperative MACE [14, 37, 43]. The rapidly increasing of the lower limb perfusion after revascularized procedures causes the alteration of cardiac physiology and activation of autoregulation process [3, 41, 42]. The cardiac responsibility is dependent on the increasing of blood flow rate to the revascularized limb which is determined by the degree of revascularization. If the revascularization is successful, almost stenotic, or occlusive lesions are well recanalization by endovascular therapy or open vascular bypass procedure which is cross all vascular lesions from the good inflow to the good run-off vessel, the after load of the lower limb are decreasing rapidly. The decreasing afterload leads to the reduction of total peripheral resistance (TPR) (**Figure 3**).

In the normal cardiac reserve patients, the immediate cardiac response to maintain the mean arterial blood pressure (MAP) is increasing of the cardiac output (CO) by the mechanoreceptors, known as baroreceptor reflex which are in the aortic arch and carotid sinus. The baroreceptors activity is decreasing lead to the reduction of impulse toward to the cardiovascular center. The increasing of sympathetic activity and the reduction of parasympathetic activity cause the increasing of CO (Eq. (1)). The increasing of CO is performed by the increasing of stroke volume (SV) and heart rate (HR) which are regulated by an autonomic nervous system (ANS) and a hormonal system though the positive chronotropic substances in human body. (Eq. (2)) (**Figure 3**).

$$\text{MAP} = \text{CO} \times \text{TPR} \quad (1)$$

$$\text{MAP} = (\text{SV} \times \text{HR}) \times \text{TPR} \quad (2)$$

The good cardiac reserve patients with good ejection fraction (EF) are regulated the SV by increasing of cardiac contractility and venous return (Eq. (3)). The increasing of cardiac contractility is activated by the neurohormonal system through the positive inotropic substances. The venous return which is regulated by the blood volume and venous tone are increased by the renin-angiotensin-aldosterone system (RAAS) activation, antidiuretic hormone (ADH) releasing, sympathetic nervous system, and central nervous system (Eq. (4)) (**Figure 3**).

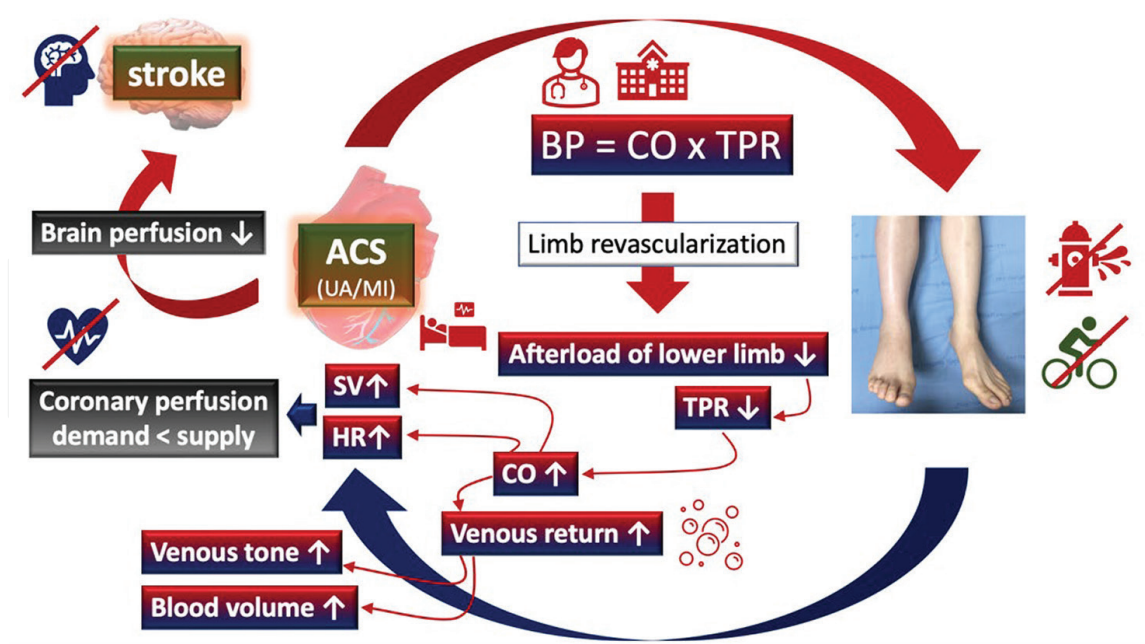
$$\text{MAP} = (\text{cardiac contraction} \times \text{venous return}) \times \text{HR} \times \text{TPR} \quad (3)$$

$$\text{MAP} = \text{cardiac contraction} \times (\text{blood volume} \times \text{venous tone}) \times \text{HR} \times \text{TPR} \quad (4)$$

During the lower limb revascularization in patients with CLTI, the cardiac response by the increasing of SV through the cardiac contractility and increasing of HR are requiring the adequate perfusion of a myocardium which is more than resting cardiac metabolic requirement in non-revascularization of lower limb patients. So, the good functional status and cardiac reserve by the coronary artery perfusion which feeding to the myocardium is very important to prevent perioperative MI. In addition, the normal cardiac response and autoregulation process are controlling the MAP to keep a constant blood flow to the other vital organ including the brain and renal to prevent perioperative stroke and acute kidney injury (AKI), respectively (**Figure 3**) [37, 41, 42].

For poor functional status and poor cardiac reserve patients, the cardiac response after revascularization though the increasing of heart rate and cardiac contractility to maintain MAP which increase the perfusion demand of myocardium are risk of acute





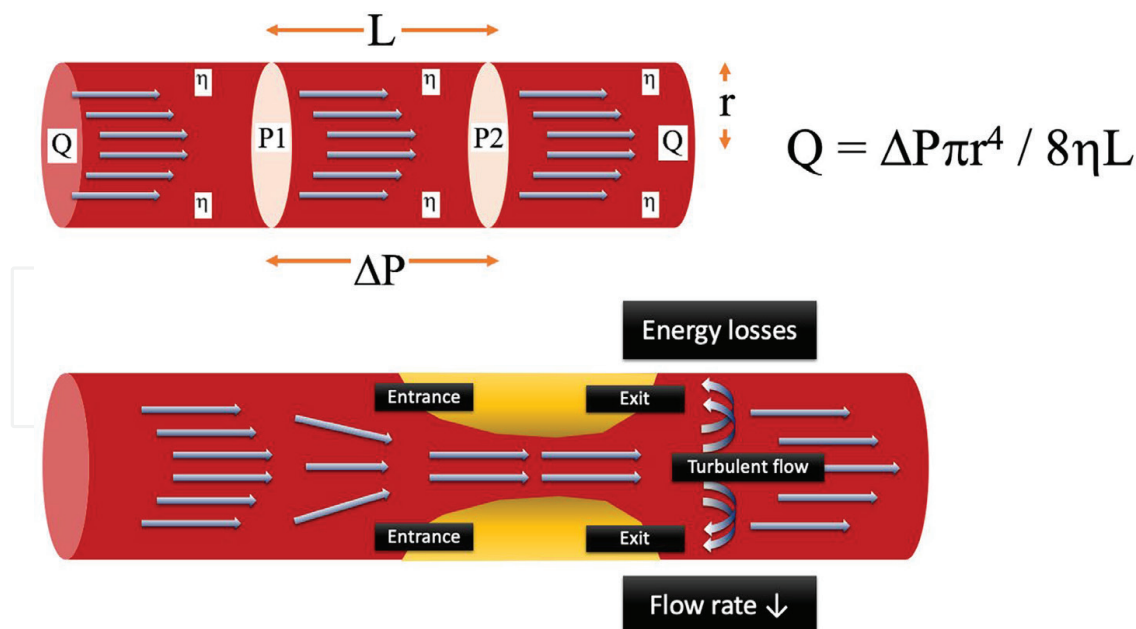
**Figure 4.** The physiologic disturbance of cardiovascular system after lower limb revascularization in patients with coexisting coronary artery disease. BP, blood pressure; CO, cardiac output; TPR, total peripheral resistant; SV, stroke volume; HR, heart rate; ACS, acute coronary syndrome; UA, unstable angina; MI, myocardial infarction.

coronary syndrome (ACS) (Eq. (3)). The coexisting CAD or HF causes the limitation of blood supply to the myocardium and poor ejection fraction (EF) cause the insufficient perfusion to the heart and other organ. Therefore, the MI and acute HF are usually precipitated during revascularization procedure in CLTI patients with cardiac comorbidities. The ACS including UA, STEMI, and NSTEMI. After the mismatch of cardiac demand–supply, the severity of myocardial ischemia can present from the UA without myocardial necrosis to the myocardial infarction (MI) which there is myocardial ischemia with detectable myonecrosis by the releasing of cardiac biomarkers such as creatine kinase, troponin, myoglobin in the systemic circulation (**Figure 4**) [41, 42].

The consequence of MI or acute HF are systemic poor perfusion and cardiogenic shock. The autoregulation process to keep the adequate perfusion to the brain is the vital role to prevent stroke for this situation. The concomitant significant arterial occlusive disease of the carotid and vertebral arterial system can precipitate the perioperative stroke after revascularization because the decompensate in cardiac responsibility and autoregulation process which lead to the failure to maintain the constant blood flow to the brain. For this reason, the concomitant CAD, HF or CVD in patient with CLTI are high risk of MACE during lower limb revascularization. The early detection, optimization of the functional status, aggressive medical treatment in the preoperative phase before lower limb revascularization should be performed intensively to decrease the risk of perioperative MACE and to increase the chance of a functional limb salvage and long-term ambulatory status which effect on quality of life and cardiovascular mortality in patients with CLTI [19, 20].

### 3.2 The anatomic distribution and severity of lower limb arterial occlusive disease related to perioperative MACE

A reduction in arterial lumen more than 75% of cross-sectional area or 50% of luminal diameter causes the significant stenosis which are limiting blood flow to



**Figure 5.**  
 The energy losses in the arterial stenotic lesion according to Poiseuille's law and the reduction in blood flow across an arterial stenosis due to the inertial energy losses by the turbulent flow in entrance and exit effects.  $Q$ , flow rate;  $\Delta P$ , pressure gradient ( $P1-P2$ );  $r$ , radius;  $L$ , length;  $\eta$ , fluid viscosity.

lower limbs [3, 35]. From the Poiseuille's law [44, 45], the flow rate ( $Q$ ) of the fluid in a hollow cylindrical shape tube is a direct variation of the fluid pressure ( $\Delta P$ ) and tube's radius ( $r$ ) whereas the tube's length ( $L$ ) and fluid viscosity ( $\eta$ ) is indirect variation of the flow rate (Eq. (5)) (Figure 5).

$$Q = \Delta P \pi r^4 / 8 \eta L \quad (5)$$

Therefore, the stenotic or occlusive arterial lesions are affecting to the decreasing of blood flow rate in the PAD of lower extremity. A severe stenosis and long length of the arterial lesions, meaning a greater decrease in blood flow and perfusion to lower limb when compare with a mild stenosis and short lesions. For the geographic pattern of stenosis. The irregular and abrupt change of arterial lumen results in more reduction of blood flow rate than a gradual tapering of the lumen (Figure 5) [37, 44, 45].

In addition, the blood flow rate is also affected by the anatomic distribution of a stenosis or occlusion. The inertial losses, an entry and exit of blood in a stenosis area which are resulting in the reduction of blood flow rate is important factors to the lower limb perfusion. The abrupt change of luminal stenosis of the entry site and expansion of the flow stream of the exit site has created the dissipation of kinetic energy in a zone of turbulence flow (Figure 3). Thus, the multiple short stenotic lesions result in more energy losses than single long stenotic lesion [37, 44, 45]. Commonly, the anatomic distribution of atherosclerosis in CLTI patients usually presents in multilevel occlusive disease [3]. The concomitant FP occlusive disease and IP arterial occlusive lesions usually occurred. The pattern of disease often presents the long occlusion or multiple severe stenosis lesions in CLTI [3, 35, 39].

In mild to moderate severity of LEAD, a stenosis vascular lesions are not influenced to lower limb perfusion at resting blood flow rates but become critical when flow rates are increased by reactive hyperemia through the vasodilatation which produce the intermittent claudication symptom during walking or exercise [12, 37, 43].

So, the revascularization strategy in patients with intermittent claudication have only increased flow rate to prevent the insufficiency perfusion during walking or exercise. In CLTI patients, the goal of lower limb revascularization is to increase the blood flow rate which is ensuring adequate straight inline to the wound or maintain resting metabolic requirement of lower limb for tissue loss and rest pain, respectively [3, 35, 43]. Therefore, the alterations of physiologic flow rate during revascularization in intermittent claudication is lower than CLTI which more extensive calcified and severe atherosclerotic stenotic or occlusive lesions. Moreover, the associated coronary and cerebrovascular disease are usually occurred and more severity in patients with extensive anatomic distribution of atherosclerotic CLTI [14, 35]. Altogether, the perioperative MACE is frequently present during revascularization in CLTI which is severe, multilevel atherosclerotic disease.

### **3.3 Type of lower limb revascularization related to MACE**

The best choice for lower limb revascularization is dependent on multiple factors which determine, by the characteristic of patients, disease, and expertise of physicians. The patient's co-morbidities, anatomic distribution and severity of disease, patient's clinical presentation or degree of tissue loss, availability of venous conduit for below the knee lesion as well as doctor's preference, and experience (doctors included vascular surgeons, interventionist, cardiologist, and angiologist) are established to the important factors to determine the type of revascularization [14, 37, 43, 46–48].

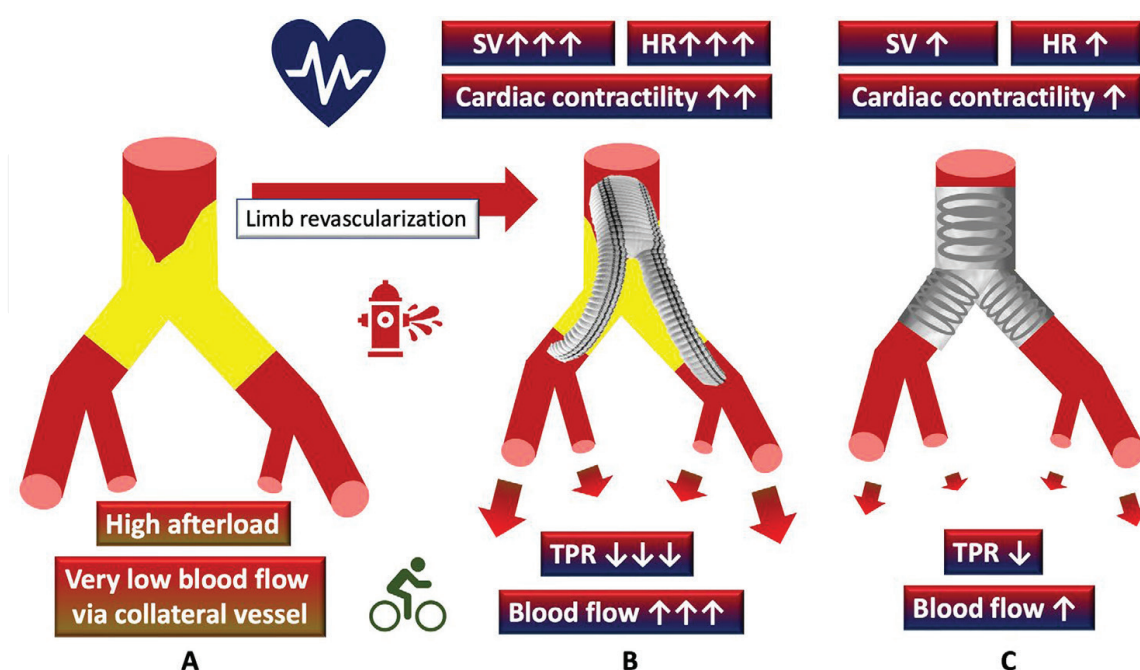
Currently, the “endovascular-first strategy” or “endovascular-first approach” for lower limb revascularization in patients with LEAD have increased significantly [46]. This minimally invasive approach is aimed to decrease the morbidity and mortality of the open vascular bypass procedure. There are a lot of publications report the ET in CLTI patients with suprainguinal disease (aortoiliac disease, AIOD) and infrainguinal disease such as FP, IP, and inframalleolar arteries segment (IM) [3, 35, 46, 47]. Complex, severe, multilevel atherosclerotic occlusive can performed revascularization by ET which is associated with amputation free survival improvement over the long-term with modest relative increased risk of reintervention [47]. CLTI patients with multiple co-morbidities, the initial surgical bypass is associated with poorer amputation-free survival compare with an endovascular-first approach due to increased severity of wounds at the time of presentation [46]. The study of CLTI in the Vascular Quality Initiative (VQI) reports the ET procedures are more offered to older and more co-morbidities patients. The patients who performed ET demonstrated the lower perioperative mortality when compare with open vascular bypass. However, the benefit of ET is not demonstrated when treating patients with few comorbidities or less advanced disease [48]. Finally, the CLTI which is the advance form of atherosclerosis of LEAD are usually involved to other vascular bed. The coexisting multiple co-morbidities due to systemic atherosclerotic disease including CAD and CVA are usually present in CLTI patients who plan for revascularization [34, 43]. Therefore, the endovascular-first strategy is still the preferred approach for the majority of CLTI patients. The open vascular bypass procedures are more likely to perform for reintervention procedures, young patients, and few comorbidities [48].

However, long term patency and freedom from reintervention rate of open vascular bypass procedures are better than ET. The selection of CLTI patients to performed open vascular bypass or ET should be considered carefully. The patient's based individual approach and risk–benefit consideration including the risk of perioperative

MACE, MALE, quality of life, morbidity, and mortality of each procedure are very important [3, 35, 43].

### 3.3.1 MACE related to open vascular bypass

The open vascular bypass procedures are significant impact of the physiological changes of the cardiovascular system by decreasing afterload which is loaded to the cardiac function [41–43]. The degree of revascularization and increasing of blood flow rate of open vascular bypass procedures are determined by the level of inflow artery, quality of distal runoff and unimpaired of foot arch arteries as well as the total length of the bypass which cross to the atherosclerotic lesion. Higher or larger arterial inflow, better quality of distal runoff and foot arch arteries, longer length of bypass are more increasing of blood flow and pressure to lower limb [37, 41–43, 49]. Example: The CLTI patients with multisegmented AIOD, FP, and IP disease who performed common iliac artery to tibial artery bypass which allow inline flow to the complete foot arch artery is a higher physiologic alteration of the cardiovascular system during revascularization than the CLTI patients who performed distal superficial femoral artery to tibial artery short bypass with incomplete foot arch artery to treat the isolated IP disease [37, 41]. The in-situ anatomical bypass procedures such as aortobifemoral bypass is a higher risk of perioperative MACE than extra-anatomical bypass such as axillobifemoral bypass due to more rapid increasing of blood flow rate, third space loss from abdominal exploration of the in-situ anatomical bypass procedures. Therefore, a complexity and planning of open vascular bypass are related to risk of perioperative MACE. Comparing with ET, the open vascular bypass procedure is a higher risk of perioperative MACE because more rapid increasing of blood flow and more alteration of the cardiovascular system (Figure 6).



**Figure 6.** The impact of revascularization in CLTI patients with TASC-D AIOD (A) open vascular bypass by vascular bifurcate graft (B) and endovascular treatment by stent graft (C) on the blood flow of lower limb and cardiovascular system. TASC, trans-Atlantic inter-society consensus; AIOD, aortoiliac occlusive disease; CLTI, chronic limb-threatening ischemia.

The risk of open vascular bypass also includes the risk of anesthesia which related to perioperative MACE. Most of the open bypass procedure needs to perform under general or spinal anesthesia which impact on the cardiovascular system [37]. Most anesthetic agent and muscle relaxant during anesthesia are negative impact on the cardiovascular system. The potential complications and morbidities of open vascular bypass procedures include surgical wound infection, bleeding, adjacent tissue/organ injury (such as nerve injury) due to the vessel dissection, and manipulation in open vascular bypass operation [37]. The surgical infection is usually present in CLTI with a history of wound infection, major tissue loss, diabetic foot ulcer, below the knee vascular bypass, redo-open vascular bypass in the previous surgical area [3, 13, 37]. All perioperative non-cardiovascular complication led to reintervention or the stress and inflammation which are precipitate the perioperative MACE.

The risk of bleeding and perianastomotic pseudoaneurysm or hematoma are a significant increase in patient who take multiple antiplatelets or anticoagulants [35]. Most of perianastomotic pseudoaneurysm requires the surgical treatment which increases the perioperative MACE due to anesthesia and bleeding during the redo operation. The CLTI patients with coexisting ACS or CVD usually take dual antiplatelet such as aspirin and clopidogrel especially in CAD patients with recent percutaneous coronary intervention (PCI) with stent [35, 37]. The cardiac arrhythmic patients need to take the oral anticoagulants to prevent intracardiac clot formation. The patients who had a history of CVD usually take an anticoagulant or antiplatelet to prevent recurrent stroke. So, the open vascular bypass procedures in CLTI patients with coexisting CAD and CVD are higher risk of bleeding and wound complications than ET. On the other hand, the discontinuation of antiplatelets or anticoagulants in high-risk MACE patients preoperatively are prohibited and increasing of the incidence of recurrent MACE during lower limb revascularization [14, 35, 37]. The appropriate post-operative care of CLTI patients who underwent open vascular bypass including wound care, ambulation training, rehabilitation, and atherosclerotic risk factors modification are decreased risk of perioperative complications, perioperative MACE, and long-term MACE [37, 42, 50].

### *3.3.2 MACE related to endovascular treatment*

The ET can decrease the risk of perioperative MACE through the two main mechanisms. (1) The risk of anesthesia, proper anesthesia is allowing safe, less complication, comfortable, and well operated of the interventions. Most of CLTI patients are classified in class III and class IV of the American Society of Anesthesiologists (ASA) physical status due to severe systemic disease such as poorly controlled DM, hypertension, HF, history of ACS or CVD, chronic kidney disease, etc. High ASA physical status is associated with perioperative morbidity and mortality, namely, perioperative MACE [37]. Most of the ET procedures are preferred under local anesthesia with adequate sedation or analgesia which decreased the risk of general and spinal anesthesia. Anesthetic agents in general and spinal anesthesia usually impacts on the cardiovascular system [37]. (2) The risk of the operation, ET procedures reported less bleeding, less surgical wound complications, and less adjacent tissue/organ injury when compare with open vascular bypass procedures. The incidence of the surgical infection such as groin wound infection, vascular graft infection is very low in CLTI patients who underwent ET. In addition, less post-operative pain due to minimally invasive procedure allow early ambulation in patients with CLTI when compare with open vascular bypass. Thus, the risk of post-operative complications due to

non-ambulatory status including deep vein thrombosis (DVT), lung atelectasis, aspiration pneumonia, urinary tract infection, and bowel ileus are decreased [37, 42, 50]. Especially in suprainguinal lesion or AIOD, the in-situ open vascular bypass procedure is needed for abdominal exploration which is significantly higher morbidity and mortality when compare with ET or hybrid operation. Because of the development of a new generation of aortoiliac stent and endograft, ET was associated with high initial technical success with equal short- to mid-term patency rate and fewer in-hospital systemic complications when compare with open vascular bypass for simple and complex AIOD [35, 37, 49].

To avoid the major operation of open vascular bypass procedures, the advance age and multiple co-morbidities usually undergo revascularized procedure by ET [48]. So, the risk of perioperative MACE during ET due to revascularization process are still present in the real-world practice because of poor cardiac reserve and multiple comorbidities such as CAD, HF and CVD. The burden to cardiovascular system depends on the degree of physiologic changes after ET because of the increasing of blood flow to the lower extremity after successful revascularization [41, 42, 48]. The high level of occlusion (such as suprainguinal disease) and single stage multisegmented revascularization are high risk of perioperative MACE due to rapidly decreasing of afterload and rapid increasing of blood flow to lower limbs (**Figure 6**) [41, 42]. In addition, the new technology of the antiproliferative agent embeds endovascular device which has increased the patency of the target arterial lesion are increasing to use in CLTI patients who undergo ET [21–26]. Some cohort study and meta-analysis report the high incidence of MACE in CLTI patients after revascularization by DCB and DES. The complication such as aneurysmal degeneration in patients with ET are reported [27–31]. Therefore, the MACE related to DCB, and DES is still debatable [30, 32]. The mechanism of drug-delivering technology and pathophysiology of MACE which may precipitated by DCB and DES, and latest evidence of the relationship between drug-delivering technology and MACE and potential complications are described under the Section 4 of this Chapter.

#### **4. Drug-delivering technology concept and their effect on the perioperative MACE**

The drug delivering technology of the paclitaxel, sirolimus, everolimus and other antiproliferative agent coated balloon and eluting stent to increase the patency of native artery and in-stent restenosis (ISR) through the aggressively inhibition of arterial damage induced neointimal hyperplasia are trending to increase for ET in patient with CLTI [21–26]. Due to the controversy of the MACE and potential complications related to DCB, and DES, the pharmacologic effect of drug-delivering technology and pathophysiology of MACE are very important to guide the individual patients-based approach and determine the strategies to offer the drug delivering technology in CLTI patients who undergo ET [30, 32, 33].

##### **4.1 Strategies for drug-delivering technology and concept in endovascular treatment**

The management of LEAD included (1) the risk modification and medical treatment to prevent MACE and MALE, (2) Revascularization procedures to improve the quality of life and salvage a functional limb with maintaining ambulatory status

for disabling intermittent claudication and CLTI, respectively [3, 13, 35, 39]. The ET is usually the first-line option in CLTI patients who are high risk for perioperative MACE [3, 46]. The fundamental steps of revascularization in ET include (1) percutaneous vascular access, (2) guidewire and catheter passage, (3) vessel preparation and, (4) definitive therapy of arterial occlusive lesion [37, 50–52]. After the vascular access approach and intraluminal passage of the wire across the stenotic or occlusive arterial lesion, the vessel preparation is the most important step to determine the definitive therapy of de novo arterial lesion which effect to the patency of the target arterial lesion in short- and long-term [51–53]. The aim of vessel preparation is modified local environment of the vessel prior to leaving something behind including stent or a non-stent anti-proliferative agent. The concept of vessel preparation included the altering residual mechanical forces in the vessel, improving luminal gain to deliver an implant and, debulking calcium or barriers to diffused of anti-proliferative agent. Thus, the vessel preparation allows an intraluminal maximal lumen diameter without thrombosis, early recoil, plaque-burden and, flow-limiting dissection is the ideal treatment for the best patency of target arterial lesion and limit the mechanism of late target vessel failure after intervention, namely, restenosis including negative vascular remodeling and intimal hyperplasia by definitive therapy [37, 50–55].

Plain balloon angioplasty (POBA) is used to dilate significant arterial stenotic or occlusive lesions with variable results. POBA can increase the luminal diameter of a target vessel by several mechanism including stretching or rupture of plaque and connective fibers in the intima and media, compression of plaque and thrombus, compression of the medial layers, redistribution of plaque or thrombus at the inner surface of an artery, and overstretching of the artery [51, 53]. The drug delivering technology which offer the best long-term patency and prevent restenosis in de novo arterial lesion which does not indicate to scaffolding or stenting after the vessel preparation process is DCB [22–25, 32, 55].

DCB is a balloon-mounted surround by an antiproliferative chemotherapeutic agent for delivering biologically active materials into the vessel wall. The paclitaxel is a majority of chemotherapeutic agent which is effects by binding to the beta subunit of tubulin, resulting in the cessation of microtubular function and the inhibition of cellular division [37, 55]. The technique of DCB in ET include (1) adequate vessel preparation by predilatation and gradually increasing diameter of the POBA to the optimal size of the target vessel diameter are achievable without the dissection or recoil, (2) transfer phase of DCB which needs to touch and press the vessel wall for agent release. The size of DCB need to be equal the last uncoated balloon or one by one ratio of the POBA:DCB diameter and, (3) The action phase of DCB, the agent should stay as long as possible as a reservoir for long-term antiproliferative effect on the vessel wall after the drug transfer [37, 55, 56]. The long-term effect on the vessel wall is needed the lipophilicity properties of the agent without any toxicity to the target arterial lesion and other vascular bed when the drug is released in the systemic circulation in minimal level. The paclitaxel is a highly lipophilic property which limits the ability to transfer into the vessel wall but long-term embedded in the vessel wall. So, the excipient co-drug is needed to facilitate absorption in transfer phase. The stable configuration during kept on the shelf, during transport and handling with minimal loss of the agents on the delivering device are very important factors which effect on the efficacy of the DCB. Several DCB for use in the peripheral vascular intervention on the market are developed currently. The main differences in each manufacturer including excipient molecules bound to the drug, nature of coating, and the concentration of drug lead to difference in the efficacy, effectiveness, and safety of DCB in real-world practice and their studies [53, 55, 56].

For FP disease, there are a lot of the studies which are reporting the results in a common theme of a significantly better patency and freedom from CD-TLR when comparing DCB to POBA [24]. Therefore, the conclusion of DCB in FP arterial occlusive disease confirm the safety and effectiveness of in both simple and complex FP lesions [25, 53–55]. On the other hand, the IP arterial occlusive disease which are significant restenosis and progression of disease after POBA are still lack of the high evidence base and long-term data to conclude the result of DCB in IP disease. Currently, DCBs are ongoing evaluation for the treatment of IP target arterial lesions. Because of the downstream risk of embolization due to the increased paclitaxel dose and crystalline conferred by the early generation of DCB, the early study result of DCB in the IP patients who undergo ET is a trend toward higher 1-year major amputation rate as compared with POBA [57]. However, the next generation stage of DCB demonstrated the favorable result of freedom from CD-TLR and major amputations at 12 months. Thus, the long-term outcome data are needed to investigate in DCB of CLTI patients with IP arterial occlusive disease before implementation with the trend to early benefit in treatment of IP arterial occlusive disease by DCB [58, 59].

If flow-limiting dissection or recoil are present after POBA, the scaffolds are necessary to maintain the luminal diameter and prevent thrombosis by the closure of the dissection area [50, 51, 53]. Over recent years, the self-expanding nitinol stents has achieved the treatment of recoil, flow-limiting dissection. In addition, there are a lot of publications reported the significantly improved clinical results after nitinol stenting for the long arterial occlusive disease. However, the very long lesions are higher risk of ISR after bare metal stenting. Drug-eluting technology including DES has also limit ISR and increase freedom from clinical driven target lesion revascularization (CD-TLR) [51].

Drug delivering technology of the stents, namely, DES has demonstrated an aggressively inhibition the neointimal hyperplasia and improve patency rates. Initial clinical practice, paclitaxel, sirolimus, and everolimus have been attached to balloon-expandable stents (BES) for coronary arteries stenting in patients who undergo PCI which has a high technical success rate and reduction in restenosis rate [37, 53, 59]. Currently, DES loaded with chemotherapeutic agents such as paclitaxel, sirolimus, and everolimus usually using polymers. However, the chemotherapeutic agents which are inhibit the intimal response cause delay stent thrombosis as high as 4% after 1 year [37]. The stent thrombosis mechanism is the exposed raw surface of the stent to the blood circulation due to a minimal incorporation and a lack of endothelialization of the DES into the arterial wall. The latest generation of DES demonstrated the better patency freedom from CD-TLR when compare with bare metal stent in both FP and IP occlusive diseases [24, 26, 37, 60–62].

The FP disease which indicates for the stent deployment due to flow-limiting dissection or recoil, the first generation of DES, including sirolimus and everolimus coated self-expanding stent (SES) does not demonstrate the benefit for long-term patency and restenosis between DES and bare metal stents [63]. The next generation of DES which is a polymer-free paclitaxel coated SES demonstrates a sustained 2-year benefit for decreased target lesion revascularization and improve patency with 2% of stent thrombosis and less than 2% of stent fracture in FP occlusive disease. A polymer-free DESs release 95% of the antiproliferative within the first 24 hours. For long-term follow up, the relative risk reduction of 5-year reintervention or restenosis are greater than 40% in DES when compare with POBA and bare metal stent in FP occlusive disease [64–66]. The latest generation of DES in FP disease are elute the paclitaxel using a fluoropolymer coating which release 40% of the paclitaxel within



the first 30 days and continue to release a drug over time with an estimated 90% eluted at 12 months. So, the sustaining of paclitaxel levels in the arterial wall of the fluoropolymer coating DES are longer periods than the previous version polymer-free DES [26, 37, 53, 67, 68]. The latest ongoing clinical trial demonstrate the better initial 1-year outcome of the primary patency of latest DES when compare with bare metal stent [60]. In addition, the ongoing trial demonstrate the comparable result of the all-cause death and target-limb major amputation between the DES and bare metal stent at 12 months [60].

For IP disease, the POBA with bailout stenting is still the standard treatment for revascularization. Because of the similarity in size between the coronary and IP arteries, the IP arterial occlusive disease which needs to be stenting due to the significant dissection or recoil are treated by the coronary stent. The off-label use of fluoropolymer with everolimus eluting BES which use in the coronary artery system are reported in RCTs and the real-world practice studies [61, 62]. The DES in focal IP disease significantly inhibit vascular restenosis and improve primary patency, decrease reintervention, and improve wound healing in patients with CLTI [61]. In addition, DES of IP disease may decrease risk of CD-TLR, restenosis rate and, amputation rate without any impact on mortality [62].

Heavy calcifications of the vessel wall which are usually present in CLTI patients with DM, advance age and chronic kidney disease remain the risk of early restenosis, thrombosis, and high CD-TLR [51]. The mechanism of the poor patency of target arterial lesion in calcification of the vessel wall includes (1) The mechanical effect of the vessel wall calcification act as the barrier to optimal dilatation of POBA and stenting. The calcific arterial lesions are increased risk of flow limiting dissection, recoil, and other angiographic complications [51, 53]. In addition, an inadequate vessel preparation due to retain plaque burden lesion and calcified lesion are still limiting the maximal luminal gain, stent apposition and stent expansion which effect to the long-term patency and increased risk of ISR in both bare metal stent and DES. (2) The pharmacological effect, the drug absorption of drug delivering device including DCB and DES are decrease in high calcific lesions [53, 54]. So, the plaque modifying device such as focal pressure balloon, cutting balloon, scoring balloon, serranator balloon, and lithoplasty device are developed for achieving of the vessel preparation in plaque burden and calcified arterial lesion. For heavy and circumferential severe atherosclerotic plaque and calcification, there are several atherectomy devices on the market currently which can debulking the calcification to increase the drug uptake to the vessel wall by the DCB and DES [53, 55, 69, 70]. The atherectomy include directional atherectomy, rotational atherectomy, orbital atherectomy, and laser atherectomy. The best choice for plaque modifying device and atherectomy are still debate and beyond the scope of this article. The result of DCB combined techniques with the atherectomy trend toward better outcomes in severely calcified long segment lesions and chronic total occlusion (CTO). However, the recent randomized control trial (RCT) and real-world practice study result are a debate in the risk of dissection and bailout stenting result with limited 1-year patency benefit in the combination of DCB with atherectomy as compared to DCB alone [69, 70].

For the ISR lesion, the characteristic of the restenosis lesion is different from the de novo arterial lesion. The “sandwich” structure including (1) a cell-dense neointimal hyperplasia within the stent struts which has ingrain and elastic consistency and (2) a cell-poor layer with a fibrous matrix which is embedded in the intimal layer at the outer margin of the stent struts results in a rubbery consistency of the lesions which poor response to POBA. Therefore, the significant recurrent stenosis of the ISR

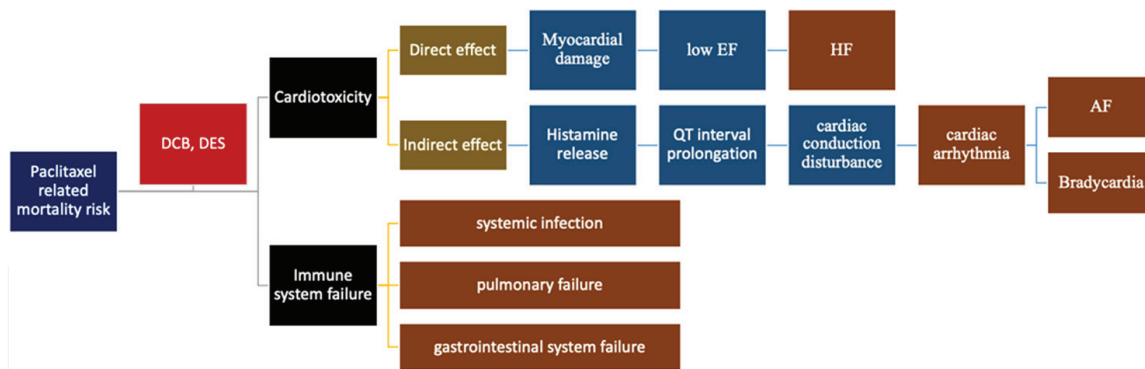
lesions usually presents after POBA without any specialty device [51, 53]. The DCB appears to be a significant benefit to treating ISR as opposed to POBA [21, 56, 71]. The combination of DCB with atherectomy devices is offered to increase the patency in patients with ISR. However, the results of these combinations for ISR have a little benefit when compare with DCB alone [53, 72].

#### **4.2 Pharmacologic effect and pathophysiology of drug-delivering technology related to MACE**

The healing response of vascular endothelium after POBA and stent placement which induce vascular endothelial injury is the activation of a local inflammatory response and the proliferation of smooth muscle cells (SMC) as well as migration of SMC into the neointima leading to significant restenosis [73, 74]. Paclitaxel and sirolimus coating devices directly inhibit the proliferation and migration of SMC which cause neointimal hyperplasia inhibition [31].

The paclitaxel is a diterpenoid antineoplastic agent which inhibits the cell proliferation. The oncologist used the paclitaxel as the chemotherapy to treat cancers, including gastric, ovarian, endometrial, breast, non-small cell lung cancer, and other cancers. The antiproliferative effect of paclitaxel can prevent the restenosis of the LEAD by the inhibition of the intimal hyperplasia [31, 75]. In normal human body physiology, microtubules are maintained cell shape and intracellular transport function, signaling, protein secretion, and motility function. The antimicrotubule effect of paclitaxel causes the formation of stable dysfunctional microtubules by binding to intracellular tubulin and interfering with spindle formation. The mitotic cell division is inhibited by the prevention of tubulin depolymerization through the irreversible of paclitaxel-tubulin binding. The prevention of tubulin depolymerization led to a microtubular dynamics disruption and cell death. The inhibition of cytokine response, migration, and secretion of matrix metalloproteinases (MMP) are the main mechanism to prevent the intimal hyperplasia after ET [31]. Consequently, the SMC proliferation and migration are inhibited which prevent neointimal hyperplasia of the vessel wall [31, 73, 74]. After DCB treatment, the paclitaxel particles are localized in fibroblast and SMC layers to inhibit the neointimal hyperplasia [73, 74]. Following DCB inflation in post-vessel preparation artery, the tissue absorption of the paclitaxel is occurring. Because of the low solubility and solid state of the paclitaxel is lower than tissue metabolic clearance rate, the paclitaxel accumulated in the target arterial lesion and cause durable effect on intimal hyperplasia [30, 55]. Overall, the pharmacokinetics of paclitaxel which is multiphasic and non-linear cause long lasting tissue accumulation of paclitaxel. The prevention of intimal hyperplasia is effective in long-term period with unknown long-term biological side effects [76, 77].

The pathophysiology and mechanism of the cardiac side effect of paclitaxel is not well established. The current studies concluded that the paclitaxel is one of cardiotoxicity chemotherapeutic agents. Some studies report the severe reduction in EF and cardiac arrhythmia [77, 78]. Theoretically, paclitaxel-induced cardiotoxicity can be occurred by the two main mechanisms: (1) direct effect of the myocardial damage which reduce in EF and precipitate HF through a subcellular organelle disturbance, (2) indirect effect of the releasing of histamine and QT interval prolongation which disturbed the cardiac electrical conduction led to cardiac arrhythmia such as atrial fibrillation (AF) and bradycardia (**Figure 7**). There are a lot of literatures report the cardiac side effects which is the most serious adverse effects of chemotherapy in malignancy patients. The early cardiac side effect of paclitaxel in chemotherapeutic



**Figure 7.** Pathophysiology of paclitaxel-induced cardiotoxicity related to mortality risk. DCB, drug coated balloon; drug eluting balloon. DES; EF, ejection fraction; HF, heart failure; AF, atrial fibrillation.

dose can occur in first month including ACS, myocardial dysfunction, reversible cardiac arrhythmias, ventricular repolarization abnormality, QT interval prolongation on electrocardiogram, and pericardial reaction. Long-term cardiac adverse events include cardiac dysfunction, which lead to HF and other MACE [77, 78]. However, most malignancy patients who have a paclitaxel-induced cardiotoxicity usually to be asymptomatic or mild severity. Under carefully monitoring of cardiac function, the safely use of paclitaxel as a chemotherapy in malignancy patients with cardiac co-morbidities including the UA, HF, and AF have been reported [76].

For the paclitaxel in ET, the dosage of paclitaxel in drug delivering technology including DCB and DES is less than 1% of chemotherapy in malignancy patients. Only asymptomatic bradycardia is seen in CLTI patients who perform ET with paclitaxel agent use [31, 55]. The other early cardiotoxicity of paclitaxel is unlikely to be from the direct effect of myocardial damage [77, 78]. However, the sustained retention of the drug in the vessel wall due to the crystalline form with a paclitaxel spacer may create the ongoing distal embolization of the paclitaxel in the systemic circulation which may relate to the increasing risk of MACE and MALE including the increasing of amputation rate [25, 27, 30]. In addition, the anti-neoplastic effect of paclitaxel causes the toxicity to the immune system (**Figure 7**). The human body immune system is inhibited by the paclitaxel which increased risk of non-cardiac deaths including systemic infection, pulmonary and gastrointestinal system failure.

The potential complications due to local toxicity of the paclitaxel which report in the literatures include aneurysmal degeneration, vascular fibrinoid necrosis, small vessel inflammation, and downstream muscle necrosis. The inhibition of intimal hyperplasia after balloon angioplasty causes the post-angioplasty injured artery dilatation and aneurysmal formation in long-term period. The paclitaxel particles which insoluble cause downstream embolization led to ischemia and repetitive inflammation of the small vessel. The primary hypothesis of downstream paclitaxel particulate showers is concordant to the higher amputation rate and MALE of the DCB when compare with POBA in CLTI patients with IP arterial occlusive disease [25, 27, 30, 62]. However, there are some studies report no significant adverse effects related to distal paclitaxel crystalline embolization. The early result of recent study demonstrated the promising safety and efficacy of paclitaxel coated balloon in CLTI patients with IP arterial occlusive disease [58, 62]. Thus, large well RCT and real-world registry are needed to investigate the long-term safety and efficacy of DCB for treatment of PAD.

For the DES, the total dose of the paclitaxel is lower than DCB. The release kinetic of DCB via the transfer and action (releasing) phase of paclitaxel after balloon angioplasty are use the concept “the greater injury, the greater penetration of the drug” in injured vessel after balloon angioplasty. The large amount of paclitaxel on DCB which delivery to the vessel wall has a high rate of distal embolization. On the other hand, the release kinetic of DES is a polymer controlled sustained release process. Thus, the downstream paclitaxel showers are not occurred when the DES is used in CLTI patients with IP arterial occlusive disease. Previous studies report the non-significant distal embolization in coronary polymer coated paclitaxel eluting stents of IP arteries. Therefore, the DES is significant reducing of CD-TLR, MALE and major amputations in 5-year and 10-year period when compare with POBA and DCB. The DCB has no obvious advantage in the treatment of IP arterial occlusive disease [23, 57, 62].

Because of the pathophysiology of cardiotoxicity associated with paclitaxel used to not be well understood, the pathophysiology of the MACE related to drug delivering technology is not well determined [33, 77, 78]. However, previous study report high-risk features which associated with paclitaxel-induced cardiotoxicity including age >60 years, DM, hypertension, Eastern Cooperative Oncology Group (ECOG) Performance Status (PS) scale 2, and chest radiotherapy [76, 77]. The patients with CLTI usually have multiple co-morbidities including DM, hypertension, old age and poor ECOG PS scale [3, 35, 39]. Thus, closed monitoring of cardiac function after paclitaxel treatment is still required in CLTI patients who have high-risk features. Therefore, long-term result of paclitaxel related MACE and MALE needs to be more investigated [3, 22].

Because of the hypothesis of the paclitaxel delivering device related MACE in CLTI patients and some evidence of the paclitaxel related MALE through the particulate embolization induced slow flow or no-flow phenomenon especially in CLTI patients with the IP arterial occlusive disease [25, 27, 30, 62]. The sirolimus coated balloons to prevent the intimal hyperplasia are investigated. The sirolimus, also known as rapamycin, is a macrocyclic lactone antibiotic which produced by bacteria *Streptomyces hygroscopicus*. The sirolimus is isolated from the Easter Island soil which use as an antifungal medication especially in Candidiasis. The potent anti-neoplastic effect through the inhibition of the mammalian target of rapamycin (mTOR) of the sirolimus is investigated. Currently, the sirolimus is an immunosuppressive agent for prevention of organ transplant rejections and antineoplastic agent for treatment of lymphangioliomyomatosis, and perivascular epithelioid cell tumors. The pathophysiology of the inhibition of neointimal hyperplasia has been less well studied. There are a lot of recent publications suggested excellent 6-month primary patency and encouraging 12-month freedom from CD-TLR, amputation-free survival rate, and limb salvage rates without early safety concerns [79]. In addition, particulate embolization due to downstream showers of drug particle and less found in the sirolimus coated balloon when compare with paclitaxel coated balloons. Comparing with paclitaxel coated balloon, the slow flow or no-flow phenomenon induced CD-TLR and MALE are less present in sirolimus coated balloon in patients with CLTI patients [80]. Thus, the sirolimus coated balloon may have a benefit to prevent restenosis of the target artery without significant MACE and MALE in ET in CLTI patients who candidate for revascularization. The further large randomized and real-world registry study in both short-term and long-term safety and efficacy is required to establish the result of sirolimus coated balloon in CLTI patients [81].

## **5. Summary and update of the best evidence of drug-delivering technology related to MACE in PAD**

The drug delivering device have been extensively investigated to inhibit arterial restenosis and ISR to improve clinical outcomes, patency, CD-TLR, amputation free survival rate after revascularization by ET. Because the positive results of drug delivering technology from several industry-sponsored studies which demonstrated the improvement in the primary patency and reduction of CD-TLR in CLTI patients FP arterial occlusive disease, the DCB and DES are widely used for ET in CLTI patients who indicate for revascularization [25, 58, 60, 65, 68]. Both FP and IP arterial occlusive disease are investigated the limb, morbidity and mortality outcome including MALE and MACE [3, 23–25, 27, 30, 31, 33, 54, 56, 57, 59, 61, 62, 74, 75]. Concerns about a long-term mortality in PAD patients who use the paclitaxel delivering device are first reported by a meta-analysis in 2018 that described the increasing of mortality rate in comparison to POBA or bare metal stent beginning at 2 years after ET [33]. In addition, the concerning of paclitaxel related MALE including major amputation rate and CD-TLR is raised after recent studies report the higher amputation rate in the paclitaxel coated balloon when compare with POBA under the particulate embolization hypothesis [27, 30, 61].

However, there are a lot of recent publication between 2020 and 2022 report the comparable result of MACE, mortality and amputation between paclitaxel delivering devices and non-drug device [82–86]. The 5-year follow-up of RCT for the safety and effectiveness of IP arterial occlusive disease report comparable risk of amputation and all-cause mortality rate between paclitaxel coated balloon and POBA in patients with CLTI [25, 85]. The independent patient-level meta-analysis revealed the safety of paclitaxel coated balloon without the relationship between level of paclitaxel exposure and mortality [84]. The recent study report no dose–response relationship between paclitaxel and mortality in drug delivering device [83]. In addition, the ET with drug delivering technology in patients with claudication are safety and effectiveness without increasing of mortality rate or MACE [86].

For the paclitaxel eluting stent, no difference in mortality between a DES and bare metal stent. Currently, ongoing study of polymer-coated DES had demonstrated the 1-year safety and efficacy with better patency when compare with bare metal stent [60]. As the United States Food and Drug Administration (FDA) and others have recommended follow patients to 5 years to collect safety and efficacy data, the result of long-term safety of DES is not completely concluded. The systematic review and meta-analysis report no significant difference in 12-month all-cause mortality between DES and DCB. Primary patency and freedom from CD-TLR are also comparable between the two groups [23].

For the local complications of drug delivering device, there are only few reports about aneurysmal degeneration, vascular fibrinoid necrosis, small vessel inflammation, and downstream skeletal muscle necrosis after paclitaxel agent device in ET. The risk of local complication for drug delivering technology in CLTI patients are not well identified. The further study is required to concluded about the local complication of DCB and DES in PAD [28–30, 78].

The limitation of meta-analysis and RCTs about the DCB and DES include: (1) most RCTs did not report the mortality rate, MACE or major amputations as the primary outcome or main outcome. So, the imprecision due to inadequate power of study can occurred and induced the error of the study result, (2) The heterogeneity of

patient's characteristic and demographic data such as ratio of CLTI and claudicants, (3) The different of the paclitaxel dose, paclitaxel crystallinity, balloon platforms and coating of agent technology. Low dose balloons may demonstrate the better outcome in safety with same efficacy due to the small number of events and lack of adequate statistical power to detect a true effect, (4) Lack of actual cause of death and the clinical indications to major amputation, (5) The chronology bias due to the long period to published of all RCTs. The improvements in MACE and co-morbidities management and the different in the design of newer paclitaxel coated balloon platforms over time, (6) Some RCT report the mortality outcome and analyzed under subgroup analysis and post-hoc analysis. The patient level time to event data should be extracted and analyzed with a one stage model to increase power and precision and there was also consistent size and direction of the summary effect in the various subgroups and sensitivity tests.

Due to the controversy result of the paclitaxel coated balloon related MACE and limitation of the previous studies, the additional patient-level, adequately powered meta-analyses with larger RCT data sets will be needed to confirm the correlation between paclitaxel and MACE. For the new drug coating balloon to avoid the possible adverse event and paclitaxel related MACE, sirolimus is promising the safety and efficacy of short-term period. However, to conclude the outcome of sirolimus coated device, the large RCT with long-term follow up is necessary.

## **6. Conclusion**

Cardiovascular disease is the life-threatening condition with high morbidity and mortality rate. The PAD is the vascular disease which has a strong relationship with the MACE. The revascularization is usually indicated in CLTI patients who have a high risk of perioperative MACE. The revascularization procedure in patients with CLTI to salvage a functional limb with aggressive best medical treatment can reduce MACE during the revascularization. Because of the physiologic changes and the auto-regulation process after revascularization procedure by decreasing of the peripheral vascular resistance are the burden to the cardiovascular system. The cardiac reserve and response after lower limb revascularization, the anatomic distribution and severity of lower limb arterial occlusive disease as well as the type of revascularization are the important predictive factors of perioperative MACE.

The minimally invasive fashion of revascularization by endovascular-first strategy can reduce perioperative MACE by decreasing risk of anesthesia and operative risk. The drug-delivering technology including DCB, and DES can improve the long-term patency of ET in CLTI patients. However, the paclitaxel effect on the MACE and MALE are still debatable. The decision making of physicians under the individual patients-based approach and determine the strategies to offer the drug delivering technology in CLTI patients who undergo ET is a key to success in both short-term and long-term safety and efficacy of revascularization in PAD.

## **Acknowledgements**

We would like to thank the Research group in surgery, Faculty of Medicine, Thammasat University.

## **Conflict of interest**

The authors declare no conflict of interest. All industry-sponsored of endovascular device and drug delivering technology are not involved to contribute this chapter.

IntechOpen

IntechOpen

## **Author details**


Saritphat Orrapin

Faculty of Medicine, Vascular Surgery Division, Department of Surgery, Thammasat University Hospital, Thammasat University, Pathum Thani, Thailand

\*Address all correspondence to: sam3\_orra@hotmail.com

## **IntechOpen**

---

© 2022 The Author(s). Licensee IntechOpen. This chapter is distributed under the terms of the Creative Commons Attribution License (<http://creativecommons.org/licenses/by/3.0>), which permits unrestricted use, distribution, and reproduction in any medium, provided the original work is properly cited. 

## References

- [1] Dosluoglu HH. Chapter 108 Lower Extremity Arterial Disease: General Considerations. In: Cronenwett JL, Johnston KW, editors. Rutherford's vascular surgery. 8th ed. Philadelphia: Elsevier; 2014. p 1660-1674
- [2] Tendera M, Aboyans V, Bartelink ML, Baumgartner I, Clement D, Collet JP, et al. ESC guidelines on the diagnosis and treatment of peripheral artery diseases: Document covering atherosclerotic disease of extracranial carotid and vertebral, mesenteric, renal, upper and lower extremity arteries: The task force on the diagnosis and treatment of peripheral artery diseases of the European Society of Cardiology (ESC). *European Heart Journal*. 2011;32:2851-2906
- [3] Conte MS, Bradbury AW, Kolh P, White JV, Dick F, Fitridge R, et al. Global vascular guidelines on the management of chronic limb-threatening ischemia. *European Journal of Vascular and Endovascular Surgery*. 2019;58:S1-S109
- [4] Orrapin S, Rerkasem K. Carotid endarterectomy for symptomatic carotid stenosis. *Cochrane Database of Systematic Reviews*. 2017;6:CD001081
- [5] Gallino A, Aboyans V, Diehm C, Cosentino F, Stricker H, Falk E, et al. Non-coronary atherosclerosis. *European Heart Journal*. 2014;35:1112-1119
- [6] Owens CD. Chapter 5: Atherosclerosis. In: Cronenwett JL, Johnston KW, editors. Rutherford's vascular surgery. 8th ed. Philadelphia: Elsevier; 2014. p. 66-77
- [7] Orrapin S, Reanpang T, Orrapin S, Arwon S, Kattipathanapong T, Lekwanavijit S, et al. Case series of HIV infection-associated arteriopathy: Diagnosis, management, and outcome over a 5-year period at Maharaj Nakorn Chiang Mai hospital, Chiang Mai University. *The International Journal of Lower Extremity Wounds*. 2015;14:251-261
- [8] Kullo IJ, Rooke TW. Clinical practice. Peripheral artery disease. *The New England Journal of Medicine*. 2016;374:861-871
- [9] Brunicki FC. *Schwartz's Principle of Surgery*. 10th ed. New York: The McGraw-Hill Companies Inc.; 2015
- [10] Kroger K, Stang A, Kondratieva J, Moebus S, Beck E, Schmermund A, et al. Prevalence of peripheral arterial disease—Results of the Heinz Nixdorf recall study. *European Journal of Epidemiology*. 2006;21:279-285
- [11] Crawford F, Welch K, Andras A, Chappell FM. Ankle brachial index for the diagnosis of lower limb peripheral arterial disease. *The Cochrane Database of Systematic Reviews*. 2016;9:CD010680
- [12] Mutirangura P, Ruangsetakit C, Wongwanit C, Sermsathanasawadi N, Chinsakchai K. Atherosclerosis obliterans of the lower extremities in Thai patients. *Journal of the Medical Association of Thailand*. 2006;89:1612-1620
- [13] Mills JL Sr, Conte MS, Armstrong DG, Pomposelli FB, Schanzer A, Sidawy AN, et al. The society for vascular surgery lower extremity threatened limb classification system: Risk stratification based on wound, ischemia, and foot infection (WIFI). *Journal of Vascular Surgery*. 2014;59:220-234
- [14] Norgren L, Hiatt WR, Dormandy JA, Nehler MR, Harris KA, Fowkes FG. Inter-society consensus for the management



of peripheral arterial disease (TASC II). *Journal of Vascular Surgery*. 2007;**45**(Suppl. S):S5-S67

[15] Carmo GA, Calderaro D, Gualandro DM, Pastana AF, Yu PC, Marques AC, et al. The ankle-brachial index is associated with cardiovascular complications after noncardiac surgery. *Angiology*. 2016;**67**:187-192

[16] Alberts MJ, Bhatt DL, Mas JL, Ohman EM, Hirsch AT, Rother J, et al. Three-year follow-up and event rates in the international REduction of atherothrombosis for continued health registry. *European Heart Journal*. 2009;**30**:2318-2326

[17] Aboyans V, Criqui MH, Abraham P, Allison MA, Creager MA, Diehm C, et al. Measurement and interpretation of the ankle-brachial index: A scientific statement from the American Heart Association. *Circulation*. 2012;**126**:2890-2909

[18] Bosco E, Hsueh L, McConeghy KW, Gravenstein S, Saade E. Major adverse cardiovascular event definitions used in observational analysis of administrative databases: A systematic review. *BMC Medical Research Methodology*. 2021;**21**:241

[19] Conte MS, Geraghty PJ, Bradbury AW, Hevelone ND, Lipsitz SR, Moneta GL, et al. Suggested objective performance goals and clinical trial design for evaluating catheter-based treatment of critical limb ischemia. *Journal of Vascular Surgery*. 2009;**50**:1462-1473

[20] Saraidaridis JT, Patel VI, Lancaster RT, Cambria RP, Conrad MF. Applicability of the Society for Vascular Surgery's objective performance goals for critical limb ischemia to current practice of lower-extremity bypass. *Annals of Vascular Surgery*. 2016;**30**:59-65

[21] Zhen Y, Ren H, Chen J, Chang Z, Wang C, Zheng J. Systematic review and Meta-analysis of drug-coated balloon angioplasty for In-stent restenosis in femoropopliteal artery disease. *Journal of Vascular and Interventional Radiology*. 2022;**33**:368-374.e366

[22] Dominguez Yulanka C, Pichert M, Alabi O, Huang J, Arham A, Brice A, et al. Predictors of drug-coated balloon and drug-eluting stent use in femoropopliteal endovascular interventions. Insights from the vascular quality initiative. *Journal of the American College of Cardiology*. 2021;**77**:1005-1005

[23] Wang J, Chen X, Zhao J, Zhang WW. Systematic review and meta-analysis of the outcomes of drug eluting stent versus drug coated balloon angioplasty for lower extremity peripheral artery diseases. *Annals of Vascular Surgery*. 11 May 2022;**S0890-S5096**(22):00225-00224

[24] Zeller T, Rastan A, Macharzina R, Tepe G, Kaspar M, Chavarria J, et al. Drug-coated balloons vs. drug-eluting stents for treatment of long femoropopliteal lesions. *Journal of Endovascular Therapy*. 2014;**21**:359-368

[25] Shishehbor MH, Schneider PA, Zeller T, Razavi MK, Laird JR, Wang H, et al. Total IN.PACT drug-coated balloon initiative reporting pooled imaging and propensity-matched cohorts. *Journal of Vascular Surgery*. 2019;**70**:1177-1191. e1179

[26] Iida O, Fujihara M, Kawasaki D, Mori S, Yokoi H, Miyamoto A, et al. 24-month efficacy and safety results from Japanese patients in the IMPERIAL randomized study of the eluvia drug-eluting stent and the Zilver PTX drug-coated stent. *Cardiovascular and Interventional Radiology*. 2021;**44**:1367-1374

- [27] Katsanos K, Spiliopoulos S, Teichgräber U, Kitrou P, Del Giudice C, Björkman P, et al. Risk of major amputation following application of paclitaxel coated balloons in the lower limb arteries: A systematic review and meta-analysis of randomised controlled trials. *European Journal of Vascular and Endovascular Surgery*. 2022;**63**:60-71
- [28] Tsujimura T, Iida O, Asai M, Masuda M, Okamoto S, Ishihara T, et al. Aneurysmal degeneration of fluoropolymer-coated paclitaxel-eluting stent in the superficial femoral artery: A rising concern. *CVIR Endovascular*. 2021;**4**:56-56
- [29] Altaf N, Ariyaratne TV, Peacock A, Deltetto I, El-Hoss J, Thomas S, et al. A budget impact model for the use of drug-eluting stents in patients with symptomatic lower-limb peripheral arterial disease: An Australian perspective. *Cardiovascular and Interventional Radiology*. 2021;**44**:1375-1383
- [30] Katsanos K, Spiliopoulos S, Kitrou P, Krokidis M, Paraskevopoulos I, Karnabatidis D. Risk of death and amputation with use of paclitaxel-coated balloons in the Infrapopliteal arteries for treatment of critical limb ischemia: A systematic review and Meta-analysis of randomized controlled trials. *Journal of Vascular and Interventional Radiology*. 2020;**31**:202-212
- [31] Beckman JA, White CJ. Paclitaxel-coated balloons and eluting stents: Is there a mortality risk in patients with peripheral artery disease? *Circulation*. 2019;**140**:1342-1351
- [32] Siablis D, Kitrou PM, Spiliopoulos S, Katsanos K, Karnabatidis D. Paclitaxel-coated balloon angioplasty versus drug-eluting stenting for the treatment of Infrapopliteal long-segment arterial occlusive disease: The IDEAS randomized controlled trial. *JACC Cardiovascular Interventions*. 2014;**7**:1048-1056
- [33] Katsanos K, Spiliopoulos S, Kitrou P, Krokidis M, Karnabatidis D. Risk of death following application of paclitaxel-coated balloons and stents in the femoropopliteal artery of the leg: A systematic review and Meta-analysis of randomized controlled trials. *Journal of the American Heart Association*. 2018;**7**:e011245
- [34] Ross R. The pathogenesis of atherosclerosis: A perspective for the 1990s. *Nature*. 1993;**362**:801-809
- [35] Aboyans V, Ricco JB, Bartelink ML, Björck M, Brodmann M, Cohnert T, et al. 2017 ESC guidelines on the diagnosis and treatment of peripheral arterial diseases, in collaboration with the European Society for Vascular Surgery (ESVS). *European Journal of Vascular and Endovascular Surgery*. 2018;**55**:305-368
- [36] Naylor AR, Ricco JB, de Borst GJ, Debus S, de Haro J, Halliday A, et al. Management of atherosclerotic carotid and vertebral artery disease: 2017 clinical practice guidelines of the European Society for Vascular Surgery (ESVS). *European Journal of Vascular and Endovascular Surgery*. 2018;**55**:3-81
- [37] Sidawy AN, Perler BA. *Rutherford's Vascular Surgery and Endovascular Therapy*. 9th ed. Philadelphia: Elsevier; 2019
- [38] Pearson TA, Mensah GA, Alexander RW, Anderson JL, Cannon RO, Criqui M, et al. Markers of inflammation and cardiovascular disease. *Circulation*. 2003;**107**:499
- [39] Gerhard-Herman MD, Gornik HL, Barrett C, Barshes NR, Corriere MA, Drachman DE, et al. 2016 AHA/ACC guideline on the management of patients

- with lower extremity peripheral artery disease: Executive summary: A report of the American College of Cardiology/ American Heart Association task force on clinical practice guidelines. *Circulation*. 2017;**135**:e686-e725
- [40] Steinberg D. Thematic review series: The pathogenesis of atherosclerosis. An interpretive history of the cholesterol controversy: Part I. *Journal of Lipid Research*. 2004;**45**:1583-1593
- [41] Pittman RN. Chapter 2: The circulatory system and oxygen transport. In: *Regulation of Tissue Oxygenation [Internet]*. San Rafael, CA: Morgan & Claypool Life Sciences; 2011 Available from: <https://www.ncbi.nlm.nih.gov/books/NBK54112/>
- [42] Fashandi AZ, Mehaffey JH, Hawkins RB, Kron IL, Upchurch GR Jr, Robinson WP. Major adverse limb events and major adverse cardiac events after contemporary lower extremity bypass and infrainguinal endovascular intervention in patients with claudication. *Journal of Vascular Surgery*. 2018;**68**:1817-1823
- [43] Farber A, Rosenfield K, Menard M. The BEST-CLI trial: A multidisciplinary effort to assess which therapy is best for patients with critical limb ischemia. *Techniques in Vascular and Interventional Radiology*. 2014;**17**:221-224
- [44] Yokokawa K, Hamashima S, Shibata M. In vivo evaluation of peripheral vascular resistance based on Poiseuille's law. *Transactions of Japanese Society for Medical and Biological Engineering*. 2014;**52**:O-432-O-433
- [45] Suter SP, Skalak R. The history of Poiseuille's law. *Annual Review of Fluid Mechanics*. 1993;**25**:1-20
- [46] Lin JH, Brunson A, Romano PS, Mell MW, Humphries MD. Endovascular-first treatment is associated with improved amputation-free survival in patients with critical limb ischemia. *Circulation. Cardiovascular Quality and Outcomes*. 2019;**12**:e005273
- [47] Wiseman JT, Fernandes-Taylor S, Saha S, Havlena J, Rathouz PJ, Smith MA, et al. Endovascular versus open revascularization for peripheral arterial disease. *Annals of Surgery*. 2017;**265**:424-430
- [48] Abu Dabrh AM, Steffen MW, Asi N, Undavalli C, Wang Z, Elamin MB, et al. Bypass surgery versus endovascular interventions in severe or critical limb ischemia. *Journal of Vascular Surgery*. 2016;**63**:244-253
- [49] Mayor J, Branco BC, Chung J, Montero-Baker MF, Koungias P, Mills JL Sr, et al. Outcome comparison between open and endovascular management of TASC II D aortoiliac occlusive disease. *Annals of Vascular Surgery*. 2019;**61**:65-71
- [50] Shishehbor MH, Jaff MR. Percutaneous therapies for peripheral artery disease. *Circulation*. 2016;**134**:2008-2027
- [51] Schneider P. *Endovascular Skills: Guidewire and Catheter Skills for Endovascular Surgery*. 4th ed. Boca Raton: CRC Press; 2019
- [52] Thukkani AK, Kinlay S. Endovascular intervention for peripheral artery disease. *Circulation Research*. 2015;**116**:1599-1613
- [53] Lindquist J, Schramm K. Drug-eluting balloons and drug-eluting stents in the treatment of peripheral vascular disease. *Seminars in Interventional Radiology*. 2018;**35**:443-452
- [54] Mills JL, Conte MS, Murad MH. Critical review and evidence implications

of paclitaxel drug-eluting balloons and stents in peripheral artery disease. *Journal of Vascular Surgery*. 2019;**70**:3-7

[55] Ang H, Koppa TR, Cassese S, Ng J, Joner M, Foin N. Drug-coated balloons: Technical and clinical progress. *Vascular Medicine*. 2020;**25**:577-587

[56] Brodmann M, Keirse K, Scheinert D, Spak L, Jaff MR, Schmahl R, et al. Drug-coated balloon treatment for femoropopliteal artery disease: The IN.PACT global study De novo In-stent restenosis imaging cohort. *JACC: Cardiovascular Interventions*. 2017;**10**:2113-2123

[57] Zeller T, Baumgartner I, Scheinert D, Brodmann M, Bosiers M, Micari A, et al. Drug-eluting balloon versus standard balloon angioplasty for infrapopliteal arterial revascularization in critical limb ischemia: 12-month results from the IN.PACT DEEP randomized trial. *Journal of the American College of Cardiology*. 2014;**64**:1568-1576

[58] Thieme M, Lichtenberg M, Brodmann M, Cioppa A, Scheinert D. Lutonix® 014 DCB global below the knee registry study: Interim 6-month outcomes. *The Journal of Cardiovascular Surgery*. 2018;**59**:232-236

[59] Spiliopoulos S, Vasiniotis Kamarinos N, Brountzos E. Current evidence of drug-elution therapy for infrapopliteal arterial disease. *World Journal of Cardiology*. 2019;**11**:13-23

[60] Goueffic Y. Editor the EMINENT study: Primary results of the randomized trial of eluvia DES vs bare metal stents. In: *Vascular InterVentional advances (VIVA)*. Las Vegas, NV: TCT MD; 2021

[61] Katsanos K, Spiliopoulos S, Diamantopoulos A, Karnabatidis D, Sabharwal T, Siablis D. Systematic review of Infrapopliteal drug-eluting stents: A

meta-analysis of randomized controlled trials. *Cardiovascular and Interventional Radiology*. 2013;**36**:645-658

[62] Zhang J, Xu X, Kong J, Xu R, Fan X, Chen J, et al. Systematic review and meta-analysis of drug-eluting balloon and stent for infrapopliteal artery revascularization. *Vascular and Endovascular Surgery*. 2017;**51**:72-83

[63] Duda SH, Bosiers M, Lammer J, Scheinert D, Zeller T, Tielbeek A, et al. Sirolimus-eluting versus bare nitinol stent for obstructive superficial femoral artery disease: The SIROCCO II trial. *Journal of Vascular and Interventional Radiology*. 2005;**16**:331-338

[64] Dake MD, Ansel GM, Jaff MR, Ohki T, Saxon RR, Smouse HB, et al. Durable clinical effectiveness with paclitaxel-eluting stents in the femoropopliteal artery. *Circulation*. 2016;**133**:1472-1483

[65] Iida O, Takahara M, Soga Y, Nakano M, Yamauchi Y, Zen K, et al. 1-year results of the ZEPHYR registry (Zilver PTX for the femoral artery and proximal popliteal artery): Predictors of restenosis. *JACC: Cardiovascular Interventions*. 2015;**8**:1105-1112

[66] Kichikawa K, Ichihashi S, Yokoi H, Ohki T, Nakamura M, Komori K, et al. Zilver PTX post-market surveillance study of paclitaxel-eluting stents for treating femoropopliteal artery disease in Japan: 2-year results. *Cardiovascular and Interventional Radiology*. 2019;**42**:358-364

[67] Müller-Hülsbeck S, Benko A, Soga Y, Fujihara M, Iida O, Babaev A, et al. Two-year efficacy and safety results from the IMPERIAL randomized study of the eluvia polymer-coated drug-eluting stent and the Zilver PTX polymer-free drug-coated stent. *Cardiovascular and Interventional Radiology*. 2021;**44**:368-375

- [68] Gray WA, Keirse K, Soga Y, Benko A, Babaev A, Yokoi Y, et al. A polymer-coated, paclitaxel-eluting stent (eluvia) versus a polymer-free, paclitaxel-coated stent (Zilver PTX) for endovascular femoropopliteal intervention (IMPERIAL): A randomised, non-inferiority trial. *Lancet*. 2018;**392**:1541-1551
- [69] Feng Z, Yang S, Sang H, Xue G, Ni Q, Zhang L, et al. One-year clinical outcome and risk factor analysis of directional atherectomy followed with drug-coated balloon for femoropopliteal artery disease. *Journal of Endovascular Therapy*. 2021;**28**:927-937
- [70] Zeller T, Langhoff R, Rocha-Singh KJ, Jaff MR, Blessing E, Amann-Vesti B, et al. Directional atherectomy followed by a paclitaxel-coated balloon to inhibit restenosis and maintain vessel patency: Twelve-month results of the DEFINITIVE AR study. *Circulation. Cardiovascular Interventions*. 2017;**10**:e004848
- [71] Grotti S, Liistro F, Angioli P, Ducci K, Falsini G, Porto I, et al. Paclitaxel-eluting balloon vs standard angioplasty to reduce restenosis in diabetic patients with In-stent restenosis of the superficial femoral and proximal popliteal arteries: Three-year results of the DEBATE-ISR study. *Journal of Endovascular Therapy*. 2015;**23**:52-57
- [72] van den Berg JC, Pedrotti M, Canevascini R, Chevili SC, Giovannacci L, Rosso R. In-stent restenosis: Mid-term results of debulking using excimer laser and drug-eluting balloons: Sustained benefit? *The Journal of Invasive Cardiology*. 2014;**26**:333-337
- [73] Vallabhajosyula S, Greenberg-Worisek AJ, Gulati R, Vallabhajosyula S, Windebank AJ, Misra S, et al. Paclitaxel-coated balloons and stents for lower extremity peripheral arterial disease interventions: A regulatory perspective for the practicing clinician. *Mayo Clinic Proceedings*. 2020;**95**:1569-1573
- [74] Krawisz AK, Secemsky EA. The safety of paclitaxel-coated devices for patients with peripheral artery disease. *Current Cardiology Reports*. 2021;**23**:48
- [75] Klumb C, Lehmann T, Aschenbach R, Eckardt N, Teichgräber U. Benefit and risk from paclitaxel-coated balloon angioplasty for the treatment of femoropopliteal artery disease: A systematic review and meta-analysis of randomised controlled trials. *eClinicalMedicine*. 2019;**16**:42-50
- [76] Han X, Zhou Y, Liu W. Precision cardio-oncology: Understanding the cardiotoxicity of cancer therapy. *NPJ Precision Oncology*. 2017;**1**:31
- [77] Osman M, Elkady M. A prospective study to evaluate the effect of paclitaxel on cardiac ejection fraction. *Breast Care (Basel)*. 2017;**12**:255-259
- [78] Farb A, Malone M, Maisel WH. Drug-coated devices for peripheral arterial disease. *The New England Journal of Medicine*. 2021;**384**:99-101
- [79] Choke E, Tang TY, Peh E, Damodharan K, Cheng SC, Tay JS, et al. MagicTouch PTA sirolimus coated balloon for femoropopliteal and below the knee disease: Results from XTOSI pilot study up to 12 months. *Journal of Endovascular Therapy*. Oct 2022;**29**(5):780-789
- [80] Tang TY, Sulaiman MSB, Soon SXY, Yap CJQ, Patel A, Chong TT. Slow-flow phenomena following lower limb paclitaxel- and sirolimus-coated balloon angioplasty in the setting of chronic limb threatening ischaemia—A case series. *Quantitative Imaging in Medicine and Surgery*. 2022;**12**:2058-2065

[81] Teichgräber U, Ingwersen M, Platzer S, Lehmann T, Zeller T, Aschenbach R, et al. Head-to-head comparison of sirolimus- versus paclitaxel-coated balloon angioplasty in the femoropopliteal artery: Study protocol for the randomized controlled SIRONA trial. *Trials*. 2021;**22**:665

[82] Gray WA, Jaff MR, Parikh SA, Ansel GM, Brodmann M, Krishnan P, et al. Mortality assessment of paclitaxel-coated balloons: Patient-level meta-analysis of the ILLUMENATE clinical program at 3 years. *Circulation*. 2019;**140**:1145-1155

[83] Schahab N, Prengel A-K, Mahn T, Schaefer C, Fimmers R, Nickenig G, et al. Long-term clinical outcome and mortality risks after paclitaxel-coated balloon angioplasty in patients with peripheral artery disease: An observational clinical study. *Health Science Reports*. 2021;**4**:e236-e236

[84] Schneider PA, Laird JR, Doros G, Gao Q, Ansel G, Brodmann M, et al. Mortality not correlated with paclitaxel exposure: An independent patient-level Meta-analysis of a drug-coated balloon. *Journal of the American College of Cardiology*. 2019;**73**:2550-2563

[85] Zeller T, Micari A, Scheinert D, Baumgartner I, Bosiers M, Vermassen Frank EG, et al. The IN.PACT DEEP clinical drug-coated balloon trial. *JACC. Cardiovascular Interventions*. 2020;**13**:431-443

[86] Schneider PA, Brodmann M, Mauri L, Laird J, Soga Y, Micari A, et al. Paclitaxel exposure: Long-term safety and effectiveness of a drug-coated balloon for claudication in pooled randomized trials. *Catheterization and Cardiovascular Interventions*. 2020;**96**:1087-1099